

## FRACTURES OF THE PROXIMAL EXTREMITY OF THE FEMUR: CURRENT DIAGNOSTIC AND THERAPEUTIC CLASSIFICATION OVERVIEW.

Massimiliano Gallo, Salvatore Morello, Valeria Burgio,  
Antonino Sanfilippo, Michele D'Arienzo.

### SUMMARY

Fracture of the proximal (upper) extremity of the femur is a very common occurrence, especially in the elderly population. This type of injury causes pain and complete functional impairment, and the overall incidence of such fractures has been increasing notably. Surgical treatment of these fractures is considered the gold standard approach to minimize the bed rest period and ensure a very early mobilization and weight bearing, restoring patients' autonomy and function as close as possible to their pre-fracture levels. In this article, we illustrate the epidemiological aspects of fractures of the proximal third of the femur, different classification systems and available treatment options depending on the type of fracture and conditions of the patient.

### Introduction

Fractures of the proximal extremity of the femur are the most frequently encountered lesions in traumatology departments. Due to the progressive aging of the population, the incidence of these fractures is increasing in most Western populations (Fig. 1) to the point of reaching epidemic proportions and threatening to undermine the balance of many health care systems due to excessive treatment costs (1).

These extremely common fractures are characteristically diagnosed in two patient groups:

- In *adults*, more rarely, caused by high-energy trauma, mostly due to traffic or work accidents, or occurring during sports activities.

- *The elderly*, with greater frequency, caused by low-energy trauma. In most cases, the traumatic event is an accidental fall; in some cases, when the patient is confused and poorly cooperative, it may even be impossible to determine the etiology of the fracture.

The elderly, especially women, are predisposed to this type of injuries due to osteoporosis, which weakens the bone tissue by reducing the bone mass, particularly at the femoral neck and trochanteric region (2). The World Health Organization has estimated that in 2050, 6.3 million (4.6 million more than in 1990) femur fractures will occur, and it is estimated that in Italy, between 70 000 and 90 000 femur fractures are treated each year. In industrialized countries, the incidence of femur fractures is constantly increasing (by 1-3% per year), almost exclusively in the elderly population. The "lifetime risk" for hip fractures is currently about 18% for women and 6% for men. The prevalence increases by about 3% for women between 65 and 74 years of age, and by 12.6% for women older than 85.

### Address of the authors

Orthopedic and Traumatology Unit, University of Palermo, Italy.

*Send correspondence to: Dr. Massimiliano Gallo, massimilianogallo5@gmail.com*

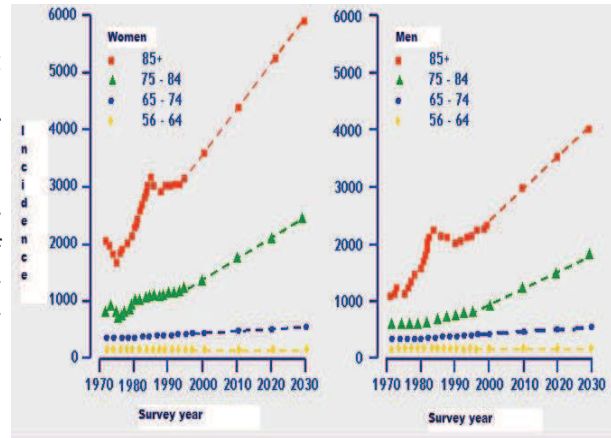
*Received: March 28th, 2012 — Revised: April 24th, 2012 — Accepted: May 1th, 2012*

### Classification

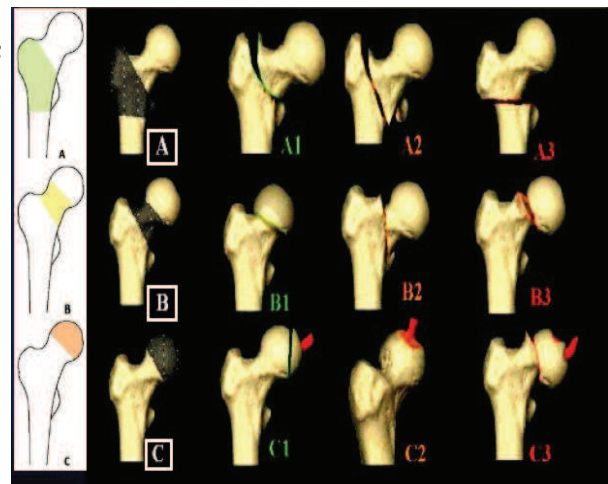
The AO classification (Arbeitsgemeinschaft für osteosynthese fragen) divides hip fractures into three groups: extracapsular fractures, fractures of the femoral neck, and fractures of the femoral head (Figure 2) (3). Each of these three groups is further divided into three subgroups, each of which, in turn, comprises three sub-subgroups. Although this classification includes 27 groups, it does not allow to properly distinguish between trochanteric and subtrochanteric fractures (4). Therefore, we prefer to use a more practical classification system, that allows to orientate the treatment in an effective manner distinguishing between medial and lateral fractures in relation to the joint capsule.

- **Medial fractures:** these are subdivided into *subcapital* and *transcervical* fractures. They can also be classified, according to the Garden system (Figure 3), into: incomplete fractures with valgus impaction (*type I*); complete fractures without displacement (*type II*); complete fractures with partial varus displacement (*type III*); and complete fractures with total displacement (*type IV*). The first two types are considered stable or directly stabilizable (through osteosynthesis); the III and IV type fractures are considered unstable, or stabilizable only by reduction.

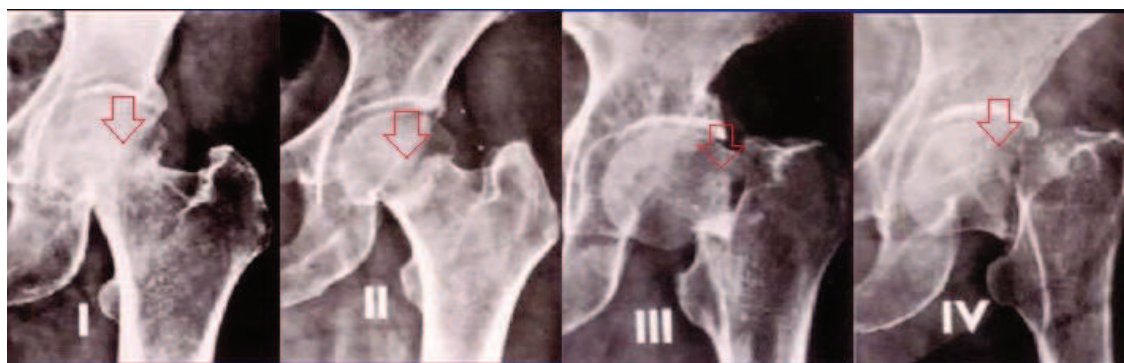
- **Lateral fractures:** these are subdivided into *basical*, *intertrochanteric* and *subtrochanteric* (below the lesser trochanter) fractures. Depending on the number of fragments and the obliquity of the fracture, lateral fractures are divided into stable and unstable (comminuted) fractures.



**Figure 1:** The steady increase in the incidence of femur fractures (1-3% per year) in most Western populations. This increase affects almost exclusively the elderly population (reproduced with modifications from: Cochrane Database Syst Rev 2009).



**Figure 2:** The AO classification system of proximal femur fractures (reproduced with modifications from: [www.gpini.it](http://www.gpini.it)).



**Figure 3:** The anato-radiological Garden classification system (reproduced with modifications from: [www.gpini.it](http://www.gpini.it)).

### Diagnosis

During the diagnostic phase, it is essential to obtain a detailed medical history and perform a thorough physical examination. It is important to investigate how the eventual fall happened in order to immediately identify any underlying pathological origin. Hip fractures are typically characterized by external rotation and shortening of the lower limb, associated with pain and inability to bear weight. However, impacted or non-displaced femoral neck fractures, as well as isolated fractures of the lesser or greater trochanter, can present as pain in the groin or trochanter area with no apparent deformity or functional impairment. In most cases, anteroposterior and lateral radiographs centered on the hip joint, together with an anteroposterior one of the entire pelvis, can be used to determine the diagnosis. If physical examination is inconclusive (presenting groin pain during mobilization of the hip without apparent cause), but radiographic findings result negative, a CT scan can be performed (1).

### Treatment

Treatment goals differ depending on the age of the patient. In fact, in younger patients, the aim is to perform a reconstruction that is as anatomically correct as possible for an optimal functional recovery. In the elderly, however, treatment is aimed at mobilizing the patient as quickly as possible, to avoid the risks related to prolonged bed rest (thromboembolic disease, urinary tract infections, hypostatic pneumonia and bedsores). When choosing the most appropriate treatment approach, it is essential to take into account, apart from the age of the patient the type of fracture, keeping in mind that generally the prognosis of medial fractures is poorer than that of the lateral ones, due to the diverse vascularity of these two areas.

The femoral head in adults is vascularized by the intracapsular terminal branches of the lateral and medial circumflex femoral arteries, intraosseous vessels within the femoral neck and the round ligament artery, which tends to become obliterated in the elderly.

A medial fracture can disrupt intraosseous vessels and damage or compress intracapsular vessels due to the pressure exerted by the hematoma. This causes a high risk

of aseptic necrosis of the femoral head, especially if the fracture is displaced. Furthermore, medial fractures, in particular basicervical ones, occur in an area of cortical bone tissue with reduced repair potential, with the consequent additional risk of delayed union and pseudarthrosis (2,5).

### *Treatment of impacted and compound medial fractures (Garden type I and II)*

The surgical treatment consists in reduction and fixation, allowing for early mobilization and minimizing complications related to prolonged bed rest; this has become the treatment of choice for femoral neck fractures, with the exclusion of patients with high surgical risk.

Surgical approach options:

- Osteosynthesis with cancellous bone screws: a non-displaced or valgus impacted fracture should be stabilized with internal fixation by three parallel cancellous bone screws.

- Sliding screw plate: this has greater biomechanical stability compared to cancellous bone screws and minimizes the risk of a subsequent subtrochanteric fracture, linked to the concentration of tensile stress, in addition to offering the possibility to compress the fracture at the time of reduction. The disadvantages include: the requirement for a larger surgical access, and the chance of causing a poor rotational alignment of the femoral head upon insertion of the screw.

### *Treatment of displaced medial fractures (Garden III and IV)*

The treatment of these fractures consists in partial or total hip replacement, depending on the more or less advanced age of the patient. In older subjects, the replacement of the femoral epiphysis with a prosthesis may be sufficient (Figure 4): in order to reduce hypermobility and friction at the interface between the metal head of the prosthesis and the acetabular articular cartilage, that causes a progressive deterioration of the latter, bi-articular prostheses may be employed. These are equipped with a second articulation inside the head. If life expectancy is still relatively long, it is preferable to use a total hip prosthesis (5). In younger patients (under 60 years of age), fracture reduction followed by osteosynthesis with multiple screws should be attempted in order to preserve the natural articulation.

### Treatment of lateral fractures

Lateral fractures are extracapsular and located in an area of cancellous bone with high repair capabilities: aseptic necrosis and non-union are thus very rare. Therefore, these fractures are treated with reduction and internal fixation. In the case of stable fractures, basicervical or pertrochanteric fractures with two fragments, sliding screw plates are recommended. In unstable fractures, with multiple fragments and disruption of the medial wall or reverse obliquity, cephalomedullary distal locking screws are preferred (Figure 5); their use allows obtaining a greater stability with osteosynthesis, enabling immediate mobilization and full weight bearing (6). An intramedullary prosthesis has several advantages: this type of implant offers a more efficient load distribution than a sliding plate device; reduction of tension on the implant, thanks to the shortened lever arm, with a consequent decrease in the risk of failure. The insertion of the intramedullary implant requires less time and causes less soft tissue damage, thus reducing morbidity. More specifically, a study by Audige, Hanson and Swiontkowski, comparing intramedullary systems involving single or double cephalic screws, concluded that there are significant differences in terms of recovery and healing. Cut-out phenomena are more common with the single screw device, while secondary varus angulation was more common with the double screw implant (7).

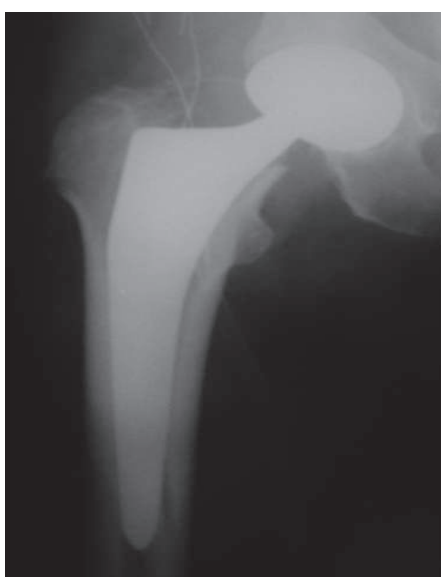

Figure 4: Biarticular endoprosthesis.

### Complications

Fracture of the femoral neck is one of the leading causes of death in the elderly (Figure 6). The mortality rate in such patients varies from 14 to 30% during the first year, whilst after the first year, the mortality rate approaches that of the similarly aged population (8-11). The risk of death is greater in the perioperative period, and gradually decreasing with time; however, it still remains high during the first six months following surgery (11). A serious complication with a high mortality rate associated with femoral neck fractures is pulmonary embolism resulting from deep vein thrombosis. Post-operative infection incidence varies from 2 to 20% (12).

When *medial fractures* are treated by internal fixation, pseudarthrosis, malunion, aseptic necrosis of the femoral head, pain and arthritis may occur. The incidence of secondary displacement or pseudarthrosis during the first two years following osteosynthesis of a displaced medial fracture of the femoral neck has been estimated at between 5 and 37% (1). In younger subjects, it is 5-15%, while in patients aged over 80 years, the incidence is 25-30% (13). Necrosis of the femoral head during the first two years following osteosynthesis occurs in approximately 7-24% of patients (1, 8). In case of joint replacement, dislocation or loosening of the implant can occur (table 1).

In *lateral fractures*, the incidence of failure of fixation reaches 20% in unstable frac-

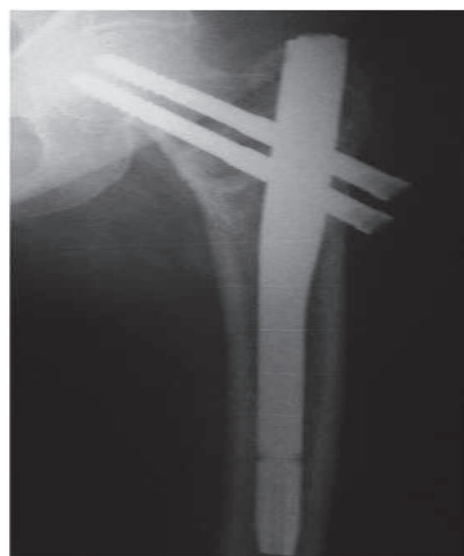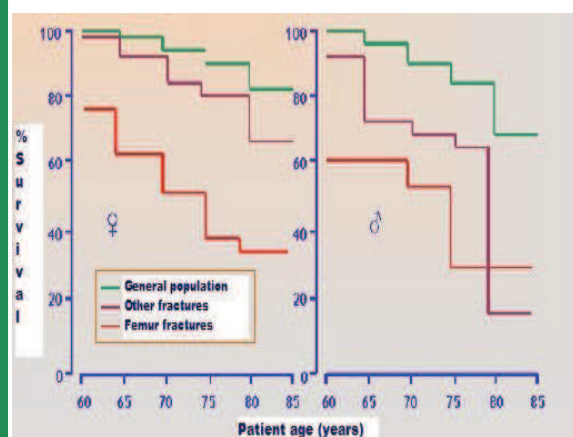


Figure 5: Endovis implant: double parallel cephalic screws.

tures. Failure of sliding compression screw plates or intramedullary nail devices is commonly characterized by a varus collapse of the proximal femoral fragment and a subsequent cut-out of the cephalic screw from the femoral head. Nonunion following the surgical treatment of a pertrochanteric fracture occurs in less than 2% of patients (12, 14); this is due to the fact that these fractures are located in well-vascularized cancellous bone. The incidence of nonunion is rather high in unstable lateral fractures. The most frequent cause of malrotation deformity presenting after the fixation of a pertrochanteric fracture is internal rotation of the distal fragment during surgery, while osteonecrosis of the femoral head is rare in this type of fracture (12).

### Conclusions

These fractures represent a major health complication in developed countries, where prevention is a key health care objective. The aim of treatment is to restore to often elderly patients, a function and a motion range as similar as possible to his/her pre-fracture abilities, using the least aggressive approach possible, in the shortest possible time, and as economically as possible. Understanding and identification of risk factors for each individual patient allows the application of personalized



**Figure 6:** High mortality rates: up to 35% during the first year. High morbidity rates: losing self-sufficiency and need for assisted living arrangements for over one year in 25% of patients. Of all fractures, femur fractures have the greatest prognostic impact (reproduced with modifications from: Journal of the American Geriatrics Society 2003).

treatment plans, and can lead to a more favorable end result. The current differences in treatment reflect the lack of adequate evidence on the benefits of one treatment approach over another, as well as diverse clinical experience, approaches and cultural preferences of the health care professionals.

### References

1. Scheerlinck T, Haentjens P: Fractures de l'extrémité supérieure du fémur chez l'adulte, Cap. 14, Edition Scientifiques et Médicales Elsevier SAS (Paris), 2003.
2. Grassi F A, Pazzaglia U, Pilato G, Zatti G: Manuale di ortopedia e traumatologia, Cap. 17, Elsevier Masson, 2007.
3. Müller ME, Nuzarian S, Koch P, Schotzker J: The comprehensive classification of fractures of long bones, Springer-Verlag, 1990.
4. Blundell CM, Parker MJ, Pryor GA, Hopkinson-Woolley J, Bhonsle SS: Assessment of the AO classification of intracapsular fractures of the proximal femur. J Bone Joint Surg Br 1998; 80:679-683.
5. Benazzo F, Ceccarelli F, Cerulli G, D'Arienza M, De Palma L, Franchin F, Gatto S, Guzzanti V, Mora R, Patella V, Ronca D, Rosa M A, Sessa G, Tarantino U, Villani C: Ortopedia e Traumatologia, Cap. 54, Monduzzi Editore, 2010.
6. Kuntscher G: Trochanter implantation by means of straight intermedullary nailing of the femur. Z Orthop Ihre Grenzgeb 1957; 89:406-409.
7. Audige L, Hanson B, Swiontkowski MF: Implant related complications in the treat-

Complications of femoral neck fractures	
Early complications	Late complications
Mortality	Pseudarthrosis
Infection	Aseptic necrosis
Deep vein thrombosis, with or without pulmonary embolism	Heterotopic ossification
Dislocation	Persistent pain

**Table 1:** Early and late complications of femoral neck fractures.

- ment of unstable intertrochanteric fractures: meta-analysis of dynamic screw plate versus dynamic screw-intramedullary nail devices. *Int Orthop* 2003; 27:197-203.
8. Lu-Yao GL, Keller RB, Littenberg B, Wennberg JE: Outcomes after displaced fractures of the femoral neck: a meta-analysis of one hundred and six published reports. *J Bone Joint Surg Am* 1994; 76:15-25.
  9. Nilsson LT, Johansson A, Strömqvist B: Factors predicting healing complications in femoral neck fractures: 138 patients followed for 2 years. *Acta Orthop Scand* 1993; 64:175-177.
  10. Nilsson LT, Strömqvist B, Thorngren KG: Nailing of femoral neck fracture: clinical and sociologic 5-year follow-up of 510 consecutive hips. *Acta Orthop Scand* 1988; 59:365-371.
  11. Ohman U, BJORKEGREN N, FAHLSTROM G: Fracture of the femoral neck. *Acta Chir Scand* 1969; 135:27-42.
  12. Heckman, Bucholz, Court-Brown: *Rockwood & Green's fractures in adults*, Cap. 44, Lippincott, Williams & Wilkins, 2009.
  13. Parker MJ: The cervical hip fracture. *Eur Instr Course Lect* 2001; 5:67-77.
  14. Altner PC. Reasons for failure in treatment of intertrochanteric fractures. *Orthop Rev* 1982; 11:117.