

Antiendomysium antibodies assay in the culture medium of intestinal mucosa: an accurate method for celiac disease diagnosis

Antonio Carroccio^a, Giuseppe Iacono^b, Lidia Di Prima^c, Giuseppe Pirrone^c, Francesca Cavataio^b, Giuseppe Ambrosiano^c, Carmelo Sciumè^d, Girolamo Geraci^d, Ada Florena^e, Saverio Teresi^b, Franco Barbaria^f, Ilenia Pepe^c, Giuseppina Campisi^e, Pasquale Mansueto^c, Maurizio Soresi^c and Gaetana Di Fede^c

Background Celiac disease (CD) diagnosis is becoming more difficult as patients with no intestinal histology lesions may also be suffering from CD.

Aim To evaluate the diagnostic accuracy of antiendomysium (EmA) assay in the culture medium of intestinal biopsies for CD diagnosis.

Patients and methods The clinical charts of 418 patients with CD and 705 non-CD controls who had all undergone EmA assay in the culture medium were reviewed.

Results EmA assay in the culture medium had a higher sensitivity (98 vs. 80%) and specificity (99 vs. 95%) than serum EmA/antibodies to tissue transglutaminase (anti-tTG) assay. All patients with CD who were tested as false-negatives for serum EmA and/or anti-tTG (32 adults and 39 children) carried the human leukocyte antigen alleles associated to CD. Furthermore, during the follow-up, four patients with negative-serum EmA/anti-tTG, normal villi architecture, and positive-EmAs in the culture medium, developed villous atrophy and

underwent gluten-free diet with consequent resolution of the symptoms and complete intestinal histology recovery.

Conclusion EmA assay in the culture medium should be included in the diagnostic criteria for CD diagnosis in 'seronegative' patients. *Eur J Gastroenterol Hepatol* 00:000–000 © 2011 Wolters Kluwer Health | Lippincott Williams & Wilkins.

European Journal of Gastroenterology & Hepatology 2011, 00:000–000

Keywords: celiac disease, culture system, diagnosis, intestinal histology, serum antiendomysium

^aDepartment of Internal Medicine, Ospedali Civili Riuniti, Sciacca (AG), ^bDepartment of Pediatric Gastroenterology, Di Cristina Hospital, ^cDepartment of Internal Medicine, ^dDepartments of Thoracic Surgery, ^ePathology and ^fGastroenterology Unit, University of Palermo, Palermo, Italy

Correspondence to Professor Antonio Carroccio, MD, Department of Internal Medicine, Ospedali Civili Riuniti, Sciacca (AG), Italy
Tel: +39 0925 962492; fax: +39 0925 84757;
e-mail: acarroccio@hotmail.com

Received 31 March 2011 Accepted 8 June 2011

Introduction

Celiac disease (CD) diagnosis is still anchored to the criteria established by the European Society of Pediatric Gastroenterology Hepatology and Nutrition in 1990 [1]. These require the mandatory presence of (a) villous atrophy with crypt hyperplasia and increased intraepithelial lymphocytes (IEL) count when the patient is eating gluten and (b) a full clinical remission after elimination of gluten from the diet. However, 20 years after those diagnostic criteria were established, there is now growing evidence that at least two other factors must be considered. First, symptomatic gluten sensitivity and malabsorption may coexist with a normal-looking mucosa [2–4]. Second, the finding of circulating IgA antibodies to tissue transglutaminase (anti-tTG) or endomysium (EmA) at diagnosis is an extremely accurate diagnostic instrument [5,6]. As a consequence, in many gastroenterology centers CD diagnosis is nowadays also being done in symptomatic patients presenting with a normal-looking

mucosa but with a high titer of serum anti-tTg or EmA antibodies [7]. However, patients with minimal or no intestinal histology lesions pose a considerable problem, as serum anti-tTG and EmA are known to be often negative in patients with CD with mild intestinal damage [8,9].

In this study, we retrospectively reviewed our 12-year experience of using EmA assay in the culture medium of duodenal biopsies in patients with suspected CD, expanded our previous data [9] and showed the clinical characteristics of some patients with CD who, at the first observation, were positive for EmA assay in the culture medium but did not fulfill the CD diagnostic criteria and successively developed intestinal villi atrophy.

Patients and methods

The study included patients referred between May 1997 and December 2007 to two centers in Palermo: adults at

the Internal Medicine Department of the University Hospital and children at the Pediatric Gastroenterology Department of the Di Cristina Hospital. We reviewed the clinical records of all patients who, during the previous 10 years, had undergone in-vitro study for EmA production in cultured duodenal mucosa samples for suspected CD.

Inclusion criteria comprised one or more of the following symptoms: weight loss, anemia, chronic diarrhea or constipation, abdominal pain, dyspepsia, alternating bowel habits, cryptogenetic hypertransaminasemia, recurrent aphthosis, dental enamel defects, thyroiditis, joints pain, and dermatitis. Patients with a family history of CD were included in this study only if they showed one or more of the above symptoms. Patients with IgA deficiency were excluded from the study.

In all the patients, CD diagnosis was made according to the following criteria: (a) in symptomatic patients with positive-serum EmA and/or anti-tTG and evidence of intestinal histology damage (grade 1–3 [10]) at first evaluation on the basis of the disappearance of both symptoms and serum antibody positivity on a gluten-free diet (GFD); (b) in symptomatic patients with negative-serum antibodies (EmA and anti-tTG) and evidence of intestinal histology damage on the basis of the disappearance of symptoms and histology improvement after at least 12 months of GFD. Furthermore, these ‘seronegative’ patients underwent human leukocyte antigen (HLA) typing for DQ2 and DQ8 alleles determination and CD diagnosis was confirmed exclusively in those carrying these alleles.

CD-specific serum antibody assays and EmA assay in the culture system

Serum IgA was measured by enzyme-linked immunosorbent assay to exclude IgA deficiency. Serum IgA recombinant antihuman tTG antibody and IgA EmA concentrations were determined with commercial methods as described previously [11].

A duodenal biopsy specimen was cultured for 72 h at 37°C in the presence of the 31–43 gliadin peptide (0.1 g/l), included in the set, with a commercial kit (EmA-biopsy, Eurospital, Trieste, Italy), as described previously [9]. IgA EmA antibodies in undiluted supernatants were assayed with the same commercial reagent set used for serum EmA.

Duodenal histology evaluation

At least six forceps biopsy specimens were obtained from the second duodenal portion during gastroduodenoscopy: at least four for histology and two for culture. Specimens adequate in size were immediately oriented and subsequently embedded in paraffin. The slides were stained with hematoxylin and eosin and graded according to the standardized scheme reported by Oberhuber *et al.* [10]. All samples collected before the publication of the Oberhuber’s article had been re-evaluated after the year

1999 and graded according to that report [10] for our database. In cases with patchy villous atrophy were classified as grade 3; in cases showing concomitant different degree of atrophy (3a, 3b, 3c), the most severe grade was considered. Villous height/crypt depth ratio was measured and a ratio of less than 2.0 was regarded as Oberhuber’s grade 3 and compatible with CD. The number of IELs per 100 villous epithelial cells was assessed by immunohistochemical staining: CD3+ IELs were stained with monoclonal antibody Leu-4. The upper limit of the reference interval in our laboratory is 25 IELs/100 epithelial cells. In all cases, histology analysis was carried out by an examiner unaware of the clinical condition and laboratory test results of the patients.

Human leukocyte antigen testing

Patients with a clinical suspicion of CD but negative for serum EmA and anti-tTG were typed for HLA-DQ phenotypes by polymerase chain reaction using sequence-specific primers. DNA was extracted from fresh peripheral blood using the standard phenol–chloroform extraction procedure. Typing was done using a DR and DQ sequence-specific primers kit (Unipath SpA, Milan, Italy) or, since March 2006, a rapid method (DQ-CD Typing Plus by BioDiaGene, Palermo, Italy), following the recommended procedures [12].

Statistical analysis

The sensitivity and specificity of the methods examined were calculated by standard statistical methods. Median and range values were calculated for age and duration of symptoms. Percentage and the 95% confidence interval were given for the frequency. The χ^2 -test was used to compare the sensitivity and the specificity of the serum and ‘culture medium’ CD antibodies. For this purpose, serum anti-tTG and serum EmA were considered as a single test: positivity in one of them was considered ‘positive serology’, negativity in either was ‘negative serology’.

All the patients, or the children’s parents, included gave their informed consent and the study was approved by the Ethics Committee of the University Hospital of Palermo.

Results

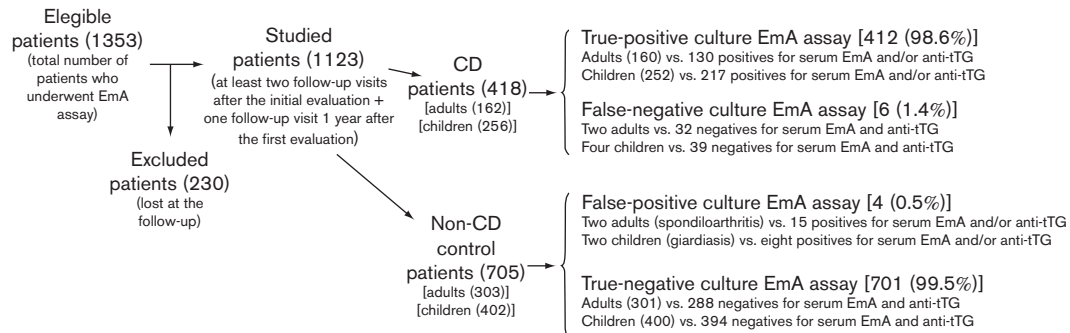
A review of the CD records and clinical records showed that during the study period 1353 patients had undergone duodenal biopsies for tissue culture and EmA assay in the culture medium. However, we considered only those patients who had one follow-up visit at least 1 year after the first evaluation (median follow-up duration of 8 years, range: 2–13 years).

In this way, 1123 patients were considered. There were 658 children (302 boys, 356 girls; age range: 1–17 years, median: 3 years) and 465 adults (171 males, 294 females; age range: 18–79 years, median: 39 years). All these

Table 1 Clinical and serological characteristics of 418 patients with CD and 705 non-CD patients who had undergone EmA assay in the culture medium of the duodenal biopsy at diagnosis

	Adult CD (n=162)	Pediatric CD (n=256)	Adult non-CD (n=303)	Pediatric non-CD (n=402)
Main reason for endoscopy				
Abdominal symptoms	97 (60%)	205 (80%)	132 (44%)	282 (70%)
Malabsorption/anemia	49 (30%)	38 (15%)	150 (49%)	104 (26%)
Extraintestinal symptoms	16 (10%)	13 (5%)	21 (7%)	16 (4%)
Family history of CD	32 (20%)	55 (21%)	12 (4%)	20 (5%)
Symptoms duration median (range)	4 years (1–36 years)	7 months (0–36 months)	4.5 years (1–40 years)	6 months (0–39 months)

CD, celiac disease; EmA, antiendomysium.

Fig. 1

Study design and summary of the main results. anti-tTG, antibodies to tissue transglutaminase; CD, celiac disease; EmA, antiendomysium.

patients had undergone a complete study for suspected CD, including serum antibodies (EmA and anti-tTG) assay, duodenal histology study, and HLA study for DQ2 and DQ8 determination.

Clinical characteristics of the study groups

A final diagnosis of CD had been reached in 418 of these patients: 162 adults (60 males, 102 females; age range: 18–79 years, median: 34 years) and 256 children (106 boys, 150 girls; age range: 1–17 years, median: 4.8 years).

Seven-hundred and five patients had a final diagnosis other than CD. Among the 303 non-CD adults we had found one or more of the following diagnoses for each patient: irritable bowel syndrome in 180 cases, sideropenic anemia in 204 cases, peptic ulcer in 51 cases, lactose intolerance in 30 cases, aphthous stomatitis in 20 cases, multiple food allergy in 37 cases, Crohn's disease in 10 cases, osteoporosis in 17 cases, chronic hepatitis in seven cases, autoimmune thyroiditis in 21 cases, dental enamel defects in nine cases, rheumatoid arthritis in six cases, Sjogren's syndrome in four cases, spondyloarthritis in nine cases, and gynecological disorders in six cases. Among the 402 non-CD children, we had found one or more of the following diagnoses for each: cow's milk allergy in 151 cases, multiple food allergy in 114 cases, irritable bowel syndrome in 42 cases, short stature in 41 cases, sideropenic anemia in 87 cases, intestinal giardiasis in eight cases, aphthous stomatitis in 28 cases, neurologic symptoms in three cases, liver steatosis with increase in

liver enzyme levels in 18 cases, and type I diabetes mellitus in seven cases.

Table 1 shows the clinical characteristics of the patients at diagnosis and Fig. 1 summarizes the study design and the main results of the study.

Table 2 shows the results of the EmA assay in the culture medium and in the serum. All patients with CD who were tested as false-negative for serum EmA and/or anti-tTG (32 adults and 39 children) carried the HLA alleles associated to CD, 50 patients showed the DQ2 haplotype and 21 the DQ8 haplotype.

False-positive results for serum CD antibodies were found in 15 adults and eight children not suffering from CD; in 20 of these 23 cases, we found positive-anti-tTG and negative-EmA assays. All these patients underwent an accurate follow-up, and serology became negative after some time (6 months–2 years) while the patients still were eating gluten.

Two adult patients (female, aged: 32 and 40 years) and two children were false-positive for EmA in the culture medium, both adults were suffering from spondyloarthritis and both children had intestinal giardiasis.

During the study period, 10 'culture EmA positive patients with CD', all with normal villi architecture (histology grade: 0–2), had decided against commencing GFD at the initial evaluation as they did not fulfill the

Table 2 Results of the EmA assay in the culture medium and in the sera of the adult and pediatric patients. Sensitivity and specificity values (c.i.) in CD diagnosis are also indicated

Adults	CD Patients (n. 162)	Non-CD Patients (n. 303)
Positive EmA in culture	160 (99%)	2 (0.5%)
Negative EmA in culture	2 (1%)	301 (99.5%)
Sensitivity	99% (97–100) ^a	–
Specificity	99.5% (98.4–100) ^b	–
Positive serum EmA	130 (80%)	15 (5%)
Negative serum EmA	32 (20%)	288 (95%)
Sensitivity	80% (78.1–83) ^a	–
Specificity	95% (92.6–97.5) ^b	–
Children	CD Patients (n. 256)	Non-CD Patients (n. 404)
Positive EmA in culture	252 (98.4%)	2 (0.5%)
Negative EmA in culture	4 (1.5%)	402 (99.5%)
Sensitivity	98.4% (96–99) ^c	–
Specificity	99.5% (98–100)	–
Positive serum EmA	217 (85%)	8 (2%)
Negative serum EmA	39 (15%)	394 (98%)
Sensitivity	85% (80.4–89.1) ^c	–
Specificity	98% (96.6–99.3)	–

Statistical analysis

^a $\chi^2=27.6 P<0.0001$ (sensitivity in adults).

^b $\chi^2=8.7 P=0.004$ (specificity in adults).

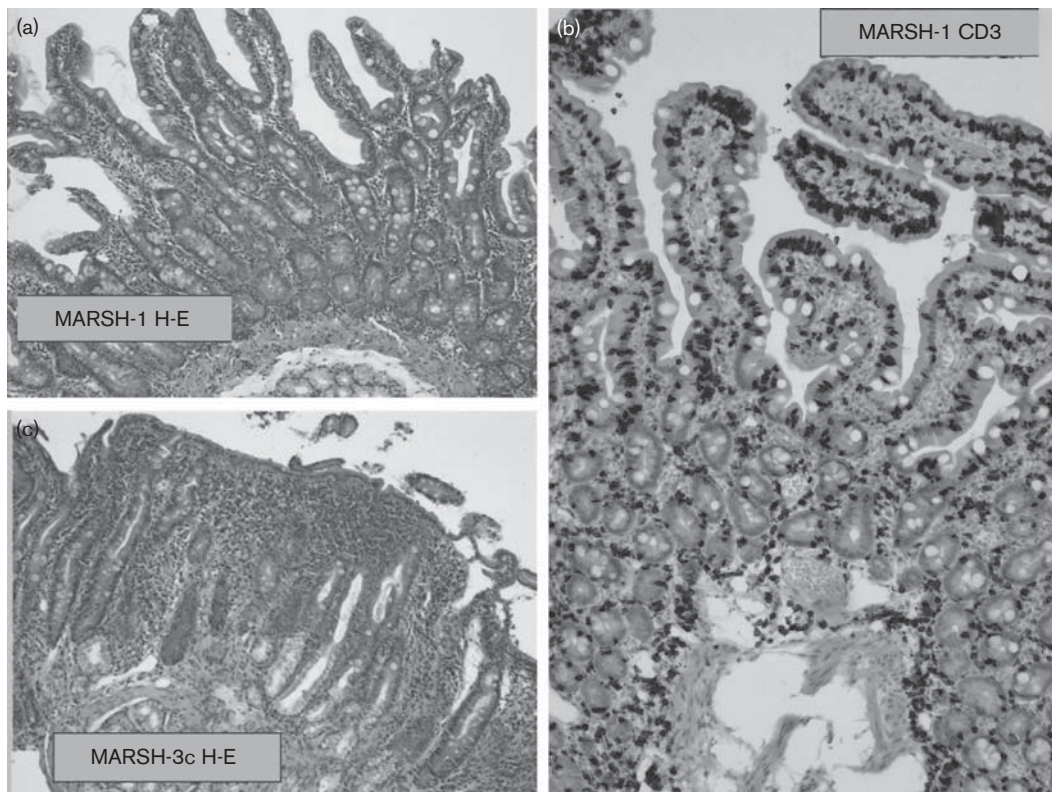
^c $\chi^2=29.3 P=0.0001$ (sensitivity in children).

CD diagnostic criteria. However, on a gluten-containing diet, they had continued to suffer from various troubles and all had undergone yearly further serologic and histology evaluations. Four of them had become positive for serum EmA-anti-tTG in a median time of 3 years (range: 1–5 years) and at that time intestinal histology had shown villous atrophy in all cases (grade 3A–3B) (Fig. 2), and they had commenced a GFD.

The other six patients remained negative for serum CD antibodies but at subsequent intestinal evaluations had shown persistent positivity for EmA in the culture medium, although histology severity was unchanged (histology grade: 0–2). However, these six patients also decided to adhere to a strict GFD (a median time of 3.5 years after the first evaluation, range: 1–6 years), as their symptoms had worsened with time.

Seven of these 10 patients carried the HLA DQ2 genotype whereas the remaining three patients carried the HLA DQ8 genotype. On GFD, all became asymptomatic without anemia or other signs of malabsorption. Intestinal histology re-evaluated after commencing GFD

Fig. 2



Histology pictures of one of the patients with positive-antiendomysium (EmA) in the culture medium and negative-serum EmA, at first evaluation [(a) hematoxylin and eosin, 40 × ; (b) anti-CD3 staining], an infiltrative pattern without villous atrophy is shown. The duodenal histology of the same patient after 2 years, at the time of re-evaluation, when serum EmA became positive [(c) hematoxylin and eosin, 40 ×], intestinal villous atrophy is now evident.

Table 3 Clinical and histological characteristics of 10 patients negative for serum anti-tTG/EmA and without evidence of intestinal villi atrophy, but positive for EmA in the culture medium of the intestinal biopsies, at the time of the first evaluation^a

	Histology at the first evaluation	Histology at the time of the decision of commencing GFD	Histology after 14–24 months of GFD diet	Hb values at the first evaluation (g/dl)	Hb values after 14–24 months of GFD diet (g/dl)	Abdominal pain/diarrhea at the first evaluation	Abdominal pain/diarrhea after 14–24 months of GFD diet
Male, age=19 years	Grade 1	Grade 3A	Grade 0	10	12.6	Yes/No	No/No
Female, age=32 years	Grade 1	Grade 3B	Grade 1	10.8	13.0	Yes/Yes	No/No
Female, age=26 years	Grade 0	Grade 3B	Grade 0	12.2	12.8	Yes/Yes	No/No
Female, age=56 years	Grade 1	Grade 3A	Grade 1	11.1	13.1	Yes/Yes	No/No
Female, age=26 years	Grade 1	Grade 1	Grade 1	8.9	12.0	Yes/Yes	No/No
Female, age=27 years	Grade 0	Grade 1	Grade 0	13.1	12.3	Yes/Yes	No/No
Male age=36 years	Grade 1	Grade 1		9.9	12.4	Not/Yes	Not/Not
Female, age=3 years	Grade 2	Grade 1		10.8	12.8	Yes/Yes	Not/Not
Male age=6 years	Grade 1	Grade 0		11	12.7	Yes/Not	Not/Not
Female, age=2 years	Grade 0	Grade 1		12.1	13.5	Yes/Not	Not/Not

EmA, antiendomysium; GFD, gluten-free diet

^aA comparison between gluten-containing diet period and GFD period is shown.

(after a median time of 1.5 years, range: 14–24 months) showed a consistent improvement, that is, all had normal or inflamed mucosa (grade 0–1 of Oberhuber's classification) without villous atrophy (Table 3). At this time, EmA assay in the culture medium resulted in being negative in seven out of the 10 patients.

Discussion

The growing contribution of serology to CD diagnosis has been recently underlined by Kurppa *et al.* [7,13], both in adults and in children. These investigators concluded that the diagnostic criteria for CD need to be re-evaluated and that EmA positivity without atrophy warrants dietary treatment. Other studies have shown that gluten sensitivity and malabsorption may coexist with a normal-looking mucosa [2–4].

However, positive-serum antibodies have been shown to correlate with degree of villous atrophy, and patients with CD with less severe histological damage can be seronegative for CD [14–16]. Thus, it is highly likely that symptomatic patients with CD with minimal histology lesions and negative-serology remain undiagnosed. Obviously, the actual size of this patient group is unknown but the prevalence of gluten sensitivity in an architecturally normal small bowel is known to be increasing [17,18]. In contrast, it is now well-known that villous atrophy could be detected only in duodenal bulb [19] and this could determine a bias in the studies, including the present, in which the duodenal biopsies were performed in the second part of the duodenum.

Our study poses its basis on the evidence that EmA antibodies are produced in the intestinal mucosa [20], and recently Stenman *et al.* [21] showed that secretion of CD autoantibodies after in-vitro gliadin challenge is dependent on small-bowel mucosal transglutaminase 2-specific IgA deposits. Furthermore, recent findings suggest that these TG2-targeted mucosal IgA-autoantibody deposits are already present in the early phases of the disease before autoantibodies appear in the serum [22,23].

This evaluation of more than 1000 patients referred to our centers for suspected CD confirmed that EmA assay in a simple culture system has a significantly higher sensitivity than serum anti-tTG/EmA assays. Although we must underline the limitation that our data were derived from a retrospective study, we included the most numerous group of patients considered in studies evaluating the diagnostic accuracy of the antibodies assays in CD diagnosis. We showed that, both in adults and in children, EmA in a culture medium had a sensitivity of 99%, compared with 80–85% in the serum. The sensitivity of serum anti-tTG and EmA, which we found in our study, could be considered low, but we agree with the opinion of Catassi and Fasano who affirmed that 'Seronegative CD is likely to be underestimated due to the tendency to perform small-intestinal biopsy only in patients with positive-CD serum markers (so-called self-fulfilling prophecy)' [24].

It is very interesting that in a small group of patients (first four of Table 3), the comparison of the histology pictures at the first evaluation, when EmAs were positive in the culture medium but not in the serum, and subsequently when EmAs became positive also in the serum, showed a progression in severity of the lesions, from a 'simple inflammation' to villous atrophy. This progression has also been shown in studies [21,22], which demonstrated anti-TG antibody deposits in the small-bowel mucosa even when absent in the serum. On the basis of those studies, it has been suggested that the immunohistochemistry demonstration of anti-tTG deposits can be used in the diagnosis of seronegative CD, when histology is equivocal. Similarly, we would suggest that EmAs positivity in the culture medium of the biopsy could be used in the CD diagnosis of seronegative patients. Obviously, a prospective study including a consistent number of these patients needs to further confirm the usefulness of EmA assay in the culture medium.

In an era in which intestinal histology evaluation can no longer be considered, the corner stone of CD diagnosis and 'microscopic enteritis' has been included in the

possible pictures of patients with CD [25], clinicians need to evaluate symptoms, serology, histology, genetics and, eventually, respond to GFD. This diagnostic puzzle is, however, very difficult to piece together in an increasing number of cases.

The data of this study indicated that no more than one biopsy for the culture system and EmA assay in the medium culture increased the sensitivity and specificity of CD diagnosis, revealing a number of patients with CD who could have remained undiagnosed, and avoiding a number of 'probable CD' diagnoses which would have been proved to be wrong over time.

Acknowledgements

The authors thank Miss Carole Greenal for her precious help in revising the English. This study was supported by a Grant of the University of Palermo (MIUR-Ricerca Scientifica di Ateneo, ex quota 60%, anni 2005 e 2006).

Conflicts of interest

There is no conflict of interest to declare.

References

- Walker-Smith JA, Guandalini S, Schmitz J, Shmerling DH, Visakorpi JK. Revised criteria for diagnosis of coeliac disease. *Arch Dis Child* 1990; **65**:909-911.
- Sbarbati A, Valletta E, Bertini M, Cipolli M, Morroni M, Pinelli L, et al. Gluten sensitivity and 'normal' histology: is the intestinal mucosa really normal? *Dig Liver Dis* 2003; **35**:768-773.
- Maki M, Holm K, Collin P, Savilahti E. Increase in gamma/delta T cell receptor bearing lymphocytes in normal small bowel mucosa in latent coeliac disease. *Gut* 1991; **32**:1412-1414.
- Paparo F, Petrone E, Tosco A, Maglio M, Borrelli M, Salvati VM, et al. Clinical, HLA, and small bowel immuno-histochemical features of children with positive serum antiendomysium antibodies and architecturally normal small intestinal mucosa. *Am J Gastroenterol* 2005; **100**:2294-2298.
- Sulkanen S, Halttunen T, Laurila K, Kolho KL, Korponay-Szabó IR, Sarnesto A, et al. Tissue transglutaminase autoantibody enzyme-linked immunosorbent assay in detecting coeliac disease. *Gastroenterology* 1998; **115**:1322-1328.
- Rostom A, Dubé C, Cranney A, Saloojee N, Sy R, Garrity C, et al. The diagnostic accuracy of serologic tests for coeliac disease: a systematic review. *Gastroenterology* 2005; **128**:S38-S46.
- Kurppa K, Collin P, Viljamaa M, Haimila K, Saavalainen P, Partanen J, et al. Diagnosing mild enteropathy coeliac disease: a randomized, controlled clinical study. *Gastroenterology* 2009; **136**:816-823.
- Rostami K, Kerckhaert J, Tiemessen R, von Blomberg BM, Meijer JW, Mulder CJ. Sensitivity of antiendomysium and anti gliadin antibodies in untreated coeliac disease: disappointing in clinical practice. *Am J Gastroenterol* 1999; **94**:888-894.
- Carroccio A, Di Prima L, Pirrone G, Scalici C, Florena AM, Gasparin M, et al. Anti-transglutaminase antibody assay of the culture medium of intestinal biopsy specimens can improve the accuracy of coeliac disease diagnosis. *Clin Chem* 2006; **52**:1175-1180.
- Oberhuber G, Granditsch G, Vogelsang H. The histopathology of coeliac disease: time for a standardized report scheme for pathologists. *Eur J Gastroenterol Hepatol* 1999; **11**:1185-1194.
- Carroccio A, Vitale G, Di Prima L, Chifari N, Napoli S, La Russa C, et al. Comparison of anti-transglutaminase ELISAs and antiendomysial antibody assay in the diagnosis of coeliac disease: a prospective study. *Clin Chem* 2002; **48**:1546-1550.
- Alarida K, Harown J, Di Pierro MR, Drago S, Catassi C. HLA DQ2 and -DQ8 genotypes in coeliac and healthy Libyan children. *Dig Liver Dis* 2010; **42**:425-427.
- Kurppa K, Ashorn M, Iltanen S, Koskinen LL, Saavalainen P, Koskinen O, et al. Coeliac disease without villi atrophy: a prospective study. *J Pediatr* 2010; **157**:373-380.
- Rostami K, Kerckhaert JP, Tiemessen R, Meijer JW, Mulder CJ. The relationship between anti-endomysium antibodies and villous atrophy in coeliac disease using both monkey and human substrate. *Eur J Gastroenterol Hepatol* 1999; **11**:439-442.
- Dahele A, Kingstone K, Bode J, Anderson D, Ghosh S. Antiendomysial negative coeliac disease: does additional serological testing help? *Dig Dis Sci* 2001; **46**:214-221.
- Dickey W, Hughes DF, McMillan SA. Sensitivity of serum tissue transglutaminase antibodies for endomysial antibody positive and negative coeliac disease. *Scand J Gastroenterol* 2001; **36**:511-514.
- Mahadeva S, Wyatt JI, Howdle PD. Is a raised intraepithelial lymphocyte count with normal duodenal villous architecture clinically relevant? *J Clin Pathol* 2002; **55**:424-428.
- Wahab PJ, Crusius JB, Meijer JW, Mulder CJ. Gluten challenge in borderline gluten-sensitive enteropathy. *Am J Gastroenterol* 2001; **96**:1464-1469.
- Evans KE, Aziz I, Cross SS, Sahota GR, Hopper AD, Hadjivassiliou M, et al. A prospective study of duodenal bulb biopsy in newly diagnosed and established adult coeliac disease. *Am J Gastroenterol* 2011 [Epub ahead of print]
- Picarelli A, Maiuri L, Frate A, Greco M, Auricchio S, Londei M. Production of antiendomysial antibodies after in-vitro gliadin challenge of small intestine biopsy samples from patients with coeliac disease. *Lancet* 1996; **348**:1065-1067.
- Stenman SM, Lindfors K, Korponay-Szabó IR, Lohi O, Saavalainen P, Partanen J, et al. Secretion of coeliac disease autoantibodies after in vitro gliadin challenge is dependent on small-bowel mucosal transglutaminase 2-specific IgA deposits. *BMC Immunol* 2008; **9**:6.
- Salmi TT, Collin P, Korponay-Szabó IR, Laurila K, Partanen J, Huhtala H, et al. Endomysial antibody-negative coeliac disease: clinical characteristics and intestinal autoantibody deposits. *Gut* 2006; **55**:1746-1753.
- Kaukinen K, Peräaho M, Collin P, Partanen J, Woolley N, Kaartinen T, et al. Small-bowel mucosal transglutaminase 2-specific IgA deposits in coeliac disease without villous atrophy: a prospective and randomized clinical study. *Scand J Gastroenterol* 2005; **40**:564-572.
- Catassi C, Fasano A. Coeliac disease diagnosis: simple rules are better than complicated algorithms. *Am J Med* 2010; **123**:691-693.
- Rostami K, Villanacci V. Microscopic enteritis: novel prospect in coeliac disease clinical and immuno-histogenesis. Evolution in diagnostic and treatment strategies. *Dig Liver Dis* 2009; **41**:245-252.