

Dupuytren's contracture as result of prolonged administration of Phenobarbital

M. TRIPOLI, A. CORDOVA, F. MOSCHELLA

Reconstructive and Plastic Surgery, Dipartimento di Discipline Chirurgiche ed Oncologiche, Palermo University (Italy)

Abstract. – Dupuytren's disease is a fibroproliferative condition involving the superficial palmar fascia, leading to a progressive and irreversible flexion of the fingers. In literature, there are different opinions regarding the phenobarbital, a common antiepileptic drug, and its effective role in the genesis and development of Dupuytren's disease.

In this retrospective investigation the association between phenobarbital and Dupuytren's contracture is discussed. Three patients in treatment with phenobarbital who had no others significant risk factors for Dupuytren's contracture were included in this study. The disease occurred after one to four years of drug therapy, at dosage of 100 mg/day. After surgery, Dupuytren's disease showed different evolutions in relation to dosage and type of antiepileptic drug used.

Phenobarbital causes a dose and time-dependent profibrotic effect. A clinical regression was observed when phenobarbital was substituted by carbamazepine, maintaining the same dosage (100 mg/day). This data confirms that not all the antiepileptic drugs are implicated in palmar fibrosis, and suggests that, according to the efficacy and adverse effects, the administration of benzodiazepine reduces the risk of Dupuytren's recurrence.

Key Words:

Phenobarbital, Dupuytren's contracture, Epilepsy.

Introduction

Dupuytren's disease is a fibroproliferative condition involving the superficial palmar fascia, leading to a progressive and irreversible flexion of the fingers. The aetiology of some aspects is still unclear. Many factors are already known to be implicated, such traumas of the hand, alcohol, diabetes, smoking, as well as different molecular

factors like Interleukin 1 (IL 1), free radicals and Transforming Growth Factor- β (TGF- β)¹. In recent studies is discussed the role of the genetic predisposition, demonstrating the association with some polymorphic genes of TGF- β and its receptor². These studies clearly demonstrate the complex oligogenic rather than monogenic condition of Dupuytren's disease which segregates into multiple modes of inheritance. There are different opinions regarding the association with the phenobarbital used for the antiepileptic treatment and its effective role in the genesis and development of Dupuytren's disease.

Our case reports show clearly the association between phenobarbital and Dupuytren's contracture.

Methods

From January 2006 to December 2009, 63 patients, 41 men, 22 women with Dupuytren's contracture underwent to surgical correction in the Department of Plastic and Reconstructive Surgery of the University of Palermo, Italy. Nine patients (14.2%), six women, three men, presented neurological disorders in treatment with phenobarbital. Among them three were manual workers, two smoked and one patient had diabetes mellitus. These patients were excluded from this investigation. At final review only three patients in treatment with phenobarbital, who had no other significant risk factors, were included in the study.

Case 1

A 43-years-old man, with a familiar history of neurologic abnormalities, affected from epilepsy and slight mental retardation, was treated with phenobarbital (100 mg/day) since seven years. In the patient history the palmar contracture oc-

curred after three years of treatment, worsening progressively. We observed the Dupuytren's disease bilaterally at the fourth finger: at stage III for the left hand, at stage II for the right one (predominant) according to the Tubiana's classification system³, which is based on the total passive extension deficit of each ray (stage I: 0°- 45°, stage II: 45°-90°, stage III: 90°-135°, stage IV: 135°-180°). At the left hand we realized a Brunner incision, then the selective fasciectomy. He underwent the physical therapy (3 sessions for 30 min/week, up to 7 weeks) and put a dynamic splint all day for two months, obtaining a significant result in hand function and finger extension. After three months from the operation the patient had an aggressive recurrence with palmar skin shrinkage, needing to carry out a full-thickness skin graft. The disease occurred again after one month, along the margin of the graft. The right hand, not operated, worsened slowly to stage III. During this period the patient did not change the dosage of phenobarbital.

Case 2

A 49-year-old right hand dominant man, with a history of prior cerebral ischemic episode, was started on a drug therapy with phenobarbital (100 mg/day). After one year of treatment the palmar fibromatosis developed at the fourth finger of the left hand, and in few months it settled at stage II.

He underwent selective fasciectomy, applying a Skoog incision (Figure 1), and starting, as soon as possible, physical therapy (3 sessions for 30 min/week, up to 8 weeks with home exercises) with the improvement of the finger extension (Figure 2). Four months after surgery a palmar recurrence in nodule shape occurred (Figure 3).

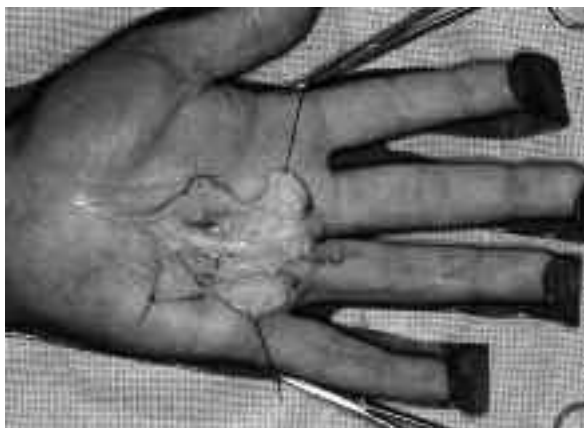

Figure 1. Intra-operative view.

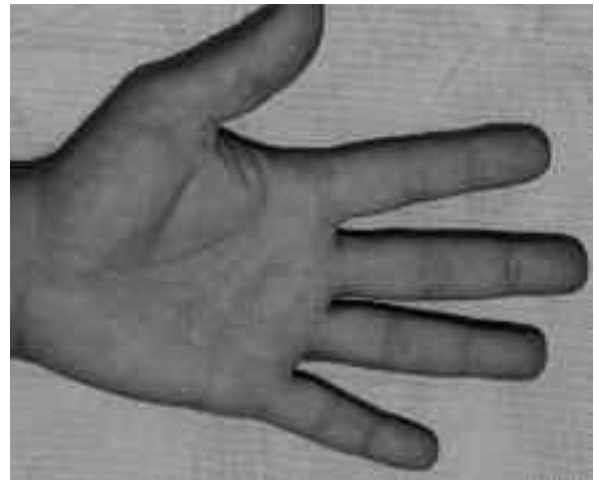


Figure 2. Post-operative view, after two months from the surgery.

At the same time, after several electroencephalographies which showed the absence of neurologic disorders, phenobarbital's dosage was reduced to 50 mg/day, and this therapy continued for 18 months about.

During this period we noticed a progressive, complete resolution of the palmar fibromatosis (Figure 4).

Case 3

A 64-year-old right hand dominant woman, in treatment with phenobarbital (100 mg/day), after experiencing a convulsive syndrome due to a cranial trauma for a car accident she had four years earlier. The palmar contracture developed after two years, at the third finger of the predominant hand, at stage II when the patient was visited. We

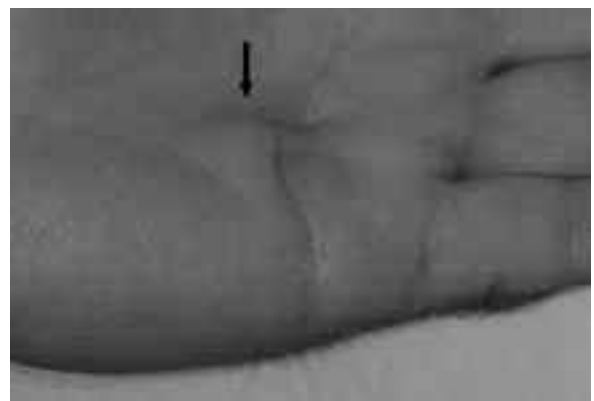


Figure 3. The shape nodule recurrence, after three months from the surgery.

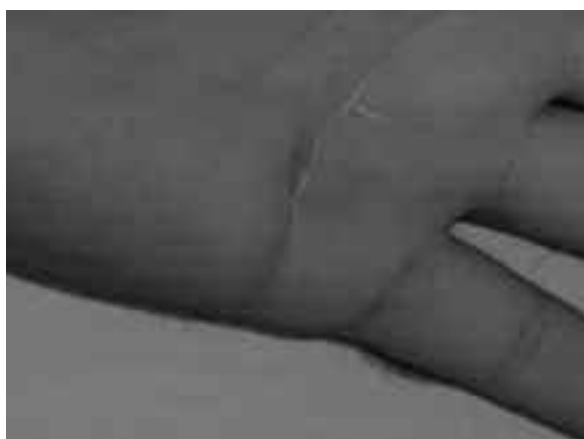

Figure 4. Regression of the nodule after phenobarbital replacement with carbamazepine.

performed a selective fasciectomy, removing the cord and a palmar nodule. A nodule shape recurrence appeared at the palm after three months from the surgery. At the same time, the neurologist replaced the phenobarbital therapy with carbamazepine (100 mg/day), to reduce side-effect regarding sedation of cognitive functions. The nodule disappeared and no other recurrence of fibromatosis developed to date.

Discussion

Epilepsy is one of the most serious neurological disorders, occurring in different types of cerebral lesions: head injury, stroke, cerebral arteriovenous malformation and cerebral tumour⁴⁻⁵. It is historically associated to Dupuytren's disease. The first description of a reliable relation was made by Lund⁶. Skoog⁷ described a prevalence of 42% of Dupuytren's contracture in 207 patients treated for epilepsy. This was confirmed by later studies⁸⁻¹⁰. Critchley et al¹¹ in a study of chronic epileptics recorded a 56% prevalence of Dupuytren's disease, symmetrical, bilateral and associated with knuckle pads and plantar nodules. According to James¹² and Quintana Guitian¹³, this percentage is much lower, between 2% and 3%, versus 0.8% to 1.8% in the general population. Male patients with epilepsy would be five times more likely to develop Dupuytren's contracture than the population without epilepsy, in women this risk would be 11-fold. With regard to the coincidence between epilepsy and palmar fibrosis

two hypotheses prevail. The first is that both these diseases are inherited disorders; This hypothesis is supported by the fact that the palmar fibrosis is often associated with the idiopathic more than with the post-traumatic epilepsy^{14,15}.

The second is the probable side-effect of antiepileptic therapy. According to a study of the collateral effects of antiepileptics on 197 patients, the frequency of Dupuytren's disease is 7,9%, but there would be no significant differences between cases and control groups¹⁶. The limit of this study is having included any kind of antiepileptic drugs, while today it seems that not all of them are implicated in the genesis of palmar contracture. Phenobarbital is the most commonly used of barbiturate drugs. There are few cases reported in literature about phenobarbital's administration and Dupuytren's disease with variable results. In the study of Arafa et al¹⁷, the prevalence of Dupuytren's disease among the residents of two epileptic centres was analyzed. The distribution of the disease in epileptic patients treated with phenobarbital was similar to patients without epilepsy (control group), but the Dupuytren's disease process was more severe compared to the control population. The study suggests that phenobarbital could be associated to Dupuytren's contracture but this is only a trend and not statistically significant.

Our case load demonstrates this association. In the first patient we noticed the recurrence of palmar fibrosis after three months from the first surgery and after one month from the full-thickness skin graft. This aggressive development was directly proportional to prolonged phenobarbital's administration without dose modification. In the second case the reduction of phenobarbital's dosage from 100 mg/day to 50 mg/day applied at early stage of a recurrence showed the complete resolution of the palmar fibrosis. This demonstrates that the dosage probably have a role in the genesis of Dupuytren's contracture only at the proliferative stage, characterized by nodules with proliferation of perivascular hyperplastic fibroblasts¹⁸. The numerous myofibroblasts at the involucional stage, and the mature collagen fiber stroma of the residual stage probably are less sensitive to dosage, but we have no sufficient data to confirm it.

In the third patient we noticed the clinical regression of a nodule shape recurrence when phenobarbital was substituted by carbamazepine, maintaining the same dosage (100 mg/day). This data confirms that not all the antiepileptic drugs

are implicated in palmar fibrosis, and also suggests that, according to the antiepileptic efficacy and adverse effects, the administration of carbamazepine reduces the risk of Dupuytren's recurrence.

Our case reports demonstrate that phenobarbital cause a dose and time-dependent profibrotic effect, and the carbamazepine seems to be not involved in the genesis of Dupuytren's contracture. To date no prospective analysis has proven a significant statistical correlation between the phenobarbital and the palmar fibrosis, the few retrospective studies are not reliable, due to the difficulty to select patients without other risk factors for Dupuytren's disease. Many other studies are necessary to understand if phenobarbital determines palmar fibrosis through the modulation of the well known profibrotic biomolecular factors, or through other unclear mechanisms. Regard to the benzodiazepines, they are not correlated to an increased risk of arrhythmogenic potential, sudden unexpected death (SUD) and abnormalities of bone metabolism as for phenobarbital¹⁹⁻²¹. Some trials have no found significant difference in efficacy between phenobarbital and carbamazepine²². For this reason, in presence of patients treated with phenobarbital with an high risk to develop the Dupuytren's contracture or its recurrence it is advisable his substitution with not profibrotic antiepileptic drugs like the benzodiazepines.

References

- 1) AL-QATTAN MM. Factors in the pathogenesis of Dupuytren's contracture. *J Hand Surg (Br)* 2006; 31A: 1527-1534.
- 2) BAYAT A, STANLEY JK, WATSON JS, FERGUSON MWJ, OLLIER WE. Genetic susceptibility to Dupuytren's disease: transforming growth factor beta receptor (TGF β R) gene polymorphisms and Dupuytren's disease. *Br J Plast Surg* 2003; 56: 328-333.
- 3) TUBIANA R. La maladie de Dupuytren. In: Tubiana R. *Traité de chirurgie de la main* (Vo. 6). 2nd ed. France: Masson; 1998.
- 4) LEMESLE-MARTIN M. Traitements antiépileptiques dans les lésions cérébrales: quelles sont les indications et les principales attitudes pratiques? *Ann Fr Anesth Réanim* 2001; 20: 115-122.
- 5) BALDY-MOULINIER M, CRESPEL A. Physiopathologie de crises et de états de mal épileptiques. *Ann Fr Anesth Réanim* 2001; 20: 97-107.
- 6) LUND M. Dupuytren's contracture and epilepsy. *Acta Psychiat Scand* 1941; 16: 465-468.
- 7) SKOOG T. Dupuytren's contraction with special reference to aetiology and improved surgical treatment. Its occurrence in epileptics-note on knuckle pads. *Acta Chir Scand* 1948; 96(Suppl. 139): 1.
- 8) HUESTON JT. The incidence of Dupuytren's contracture. *Med J Aust* 1960; 2: 999-1002.
- 9) EARLY PF. Population studies in Dupuytren's contracture. *J Bone Joint Surg (Br)* 1962; 44: 602-613.
- 10) POJER J, RADIVOJEVIC M, WILLIAM TF. Dupuytren's disease-its association with abnormal liver function in alcoholism and epilepsy. *Arch Intern Med* 1972; 129: 561-566.
- 11) CRITCHLEY EM, VAKIL SD, HAYWARD HM, OWEN WM. Dupuytren's disease in epilepsy: result of prolonged administration of anticonvulsants. *J Neurol Neurosurg Psychiatry* 1976; 39: 498-503.
- 12) JAMES JIP. The genetic pattern of Dupuytren's disease and idiopathic epilepsy. In: Hueston JT, Tubiana R: *Dupuytren's disease*. Edinburgh: Churchill: Livingstone; 1985.
- 13) QUINTANA GUITIAN A. Various epidemiologic aspects of Dupuytren's disease. *Ann Chir Main* 1988; 7: 256-262.
- 14) BRENNER P, RAYAN GM. Theories concerning etiology and pathogenesis. In: Brenner P, Rayan GM. *Dupuytren's disease*. Wien-New York: Springer; 2003.
- 15) HURST LC, BADALAMENTE M. Associated diseases. In: McFarlane RM, McGrouther DA, Flint MH. *Dupuytren's disease. Biology and treatment*. Edinburgh-London-Melbourne: Churchill Livingstone. 1990, pp. 253-260.
- 16) CORAL P, ZANATTA A, TEIVE HA, CORREA NETO Y, NOVAK EM, WERNEK LC. Dupuytren's and Ledderhose's diseases associated with chronic use of anticonvulsants. Case report. *Arquiv Neuro-Psiquiatria* 1999; 57B: 860-862.
- 17) ARAFA M, NOBLE J, ROYLE SG, TRAIL IA, ALLEN J. Dupuytren's and epilepsy revisited. *J Hand Surg (Br)* 1992; 17: 221-224.
- 18) LUCK JV. Dupuytren's contracture: a new concept of pathogenesis correlated with surgical management. *J Bone Joint Surg (Br)* 1959; 41A: 625-634.
- 19) PELLOCK JM. Treatment considerations: traditional antiepileptic drugs. *Epilepsy Behav* 2002; 3S: 18-23.
- 20) PACK AM, MORREL MJ. Epilepsy and bone health in adults. *Epilepsy Behav* 2004; 5(S): 24-29.
- 21) DANIELSSON B, LANSDELL K, PATMORE L, TOMSON T. Phenytoin and phenobarbital inhibit human HERG potassium channels. *Epilepsy Res* 2003; 55: 147-157.
- 22) BROGLIN D. États épileptique: bases pharmacocinétiques du traitement antiépileptique chez l'adulte. *Ann Fr Anesth Réanim* 2001; 20: 159-170.