

Case Reports & Case Series (CRP)

Impasse in the management of recurrent basal cell carcinoma of the skull with sagittal sinus erosion



Rosario Maugeri, M.D., P.h.D., Luigi Basile, M.D., Antonella Giugno, M.D.,
Francesca Graziano, M.D., Domenico Gerardo Iacopino, M.D., P.h.D. *

Department of Experimental Biomedicine and Clinical Neurosciences, School of Medicine, Neurosurgical Clinic, University of Palermo, Via del Vespro 129, 90100, Palermo, Italy

ARTICLE INFO

Article history:

Received 28 April 2015

Revised 13 July 2015

Accepted 18 July 2015

Keywords:

Basal cell carcinoma

Conservative management

Superior sagittal sinus

ABSTRACT

Basal cell carcinoma (BCC) is a non melanocytic skin cancer that arises from basal cells, affecting commonly fair-skinned human beings. Although the tumor is well known for local recurrences, extension into the intracranial space is reported. A case of a giant BCC of the scalp invading the middle and posterior third of the superior sagittal sinus (SSS) is reported. A 70-year-old male with a basal cell carcinoma history presented with a massive bleeding from the SSS invaded by the tumor. Since the patient refused surgery the bleeding was managed through direct compression by applying a thrombin-based hemostatic agents and sterile dressings. This procedure was performed daily in order to stimulate the spontaneous thrombosis of the dural sinus and development of collateral circle. BCC invading the SSS is rarely reported. A technical description of this case is provided. This case underscores the importance of early and appropriate treatment for high risk BCC, and whenever surgical procedure is not suitable appropriate conservative treatment may be efficacious.

© 2015 The Authors. Published by Elsevier B.V. This is an open access article under the CC BY-NC-ND license (<http://creativecommons.org/licenses/by-nc-nd/4.0/>).

1. Introduction

Basal cell carcinoma (BCC) is the most common malignancy in Caucasian people, with a reported incidence of 1–2% per year. More than 1 million cases of non-melanoma skin cancer (basal or squamous cell) occur in the United States every year and the incidence of BCC increases by approximately 5% annually [1]. These lesions affect mainly the head and neck region because of the high cumulative chronic ultraviolet light exposure. Common predisposing conditions include lightly pigmented skin, family history of skin cancer and immunodeficiency conditions. These tumors generally give ulcerative lesions with indurated margins on the skin and tend to be slow-growing and indolent. However they can be locally invasive if left untreated for a long period of time [2]. Malignant skin cancer of the scalp with skull invasion, dural infiltration and brain involvement is an uncommon lesion. Such an occurrence can be encountered in patients with underestimated scalp lesions and the prognosis is poor [3]. We report a case of a massive infiltration of the SSS by a skin cancer managed conservatively.

2. Case report

2.1. History and physical

A 70-year-old male was initially referred to the Department of Plastic Surgery of our University in 2003 for the excision of a histopathologically-confirmed basal cell carcinoma of the parieto-occipital region. The lesion was operated several times since recurrences were observed over 10 years. Post-operative radiation therapy was performed with a total dose of 40 Gy delivered in 20 fractions over a period of 48 days. At once the patient was reluctant in attending the follow-up examinations and the lesion significantly enlarged and eroded the skull. The patient was finally referred to our Neurosurgical Unit in 2014. At admission the clinical examination revealed a large, exophytic, irregular bordered and ulcerated tumor, extending bilaterally over the parieto-occipital area of the scalp (Fig. 1).

Brain CT and MRI examinations were scheduled. While the patient was undergoing contrast-enhanced brain CT scan a massive venous bleeding through the skin lesion from the SSS occurred. A surgical procedure was attempted in order to stop the bleeding. A mechanical hemostasis was performed through compression by applying a thrombin-based hemostatic agent (FloSeal® Haemostatic Matrix and Vivostat® autologous fibrin glue) to the bleeding site until the hemorrhage was stopped. TachoSil® slices were placed along the borders of the ulcerated area, and a medication with several sterile dressings was performed. The neurological examination was unremarkable.

Abbreviations: BCC, Basal cell carcinoma; MRI, Magnetic resonance imaging; CT, Computed tomography.

* Corresponding author. Tel.: +39 03280410463; fax: +39 0916552393.

E-mail address: gerardo.iacopino@unipa.it (D.G. Iacopino).

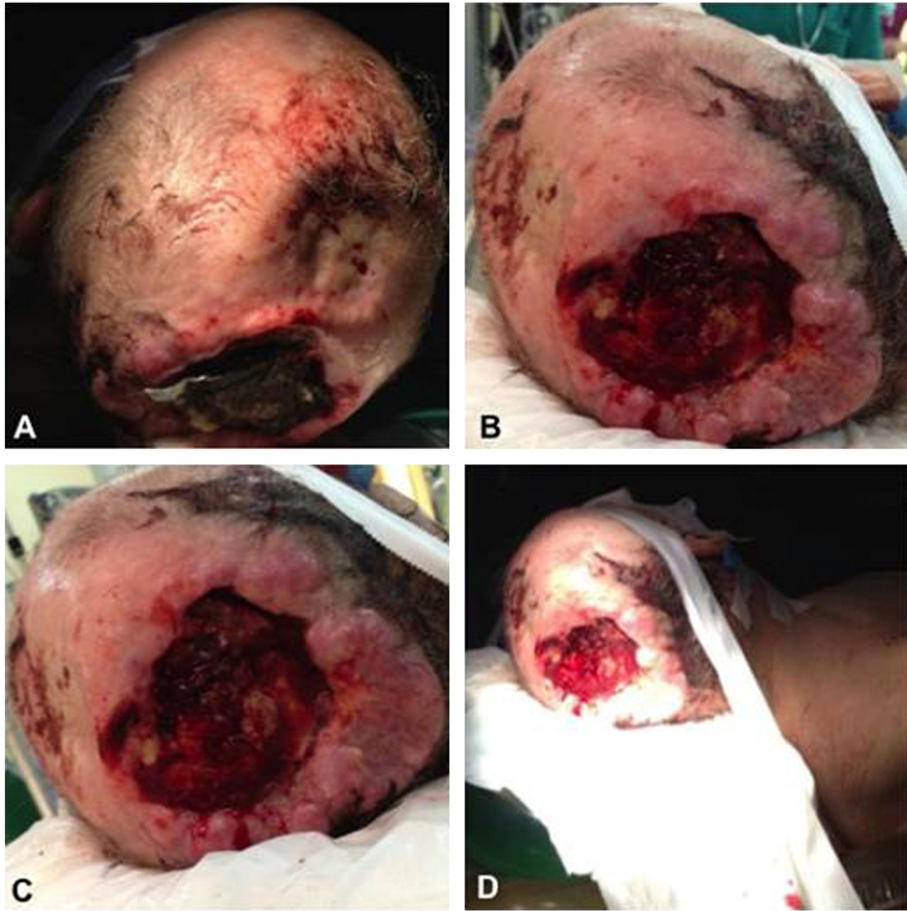


Fig. 1. A, The large crater-like soft tissue defect, covered by sterile dressings. Anteriorly to this lesion, a scar with a skin minus is depicted, represented by the previously treated parietal cutaneous malignant lesion. B–D, After the dressing is totally removed, the crater-like soft tissue defect is depicted surrounded by the exophytic mass of the malignant cutaneous lesion.

2.2. Neuroradiological investigations

Following general stabilization, a contrast-enhanced CT scan of the brain and angio-CT demonstrated an intracranial extension of the tumor on both sides of the falx cerebri affecting the SSS

(Figs. 2 and 3). MRI showed an extensive extra-intradural lesion straddling the midline (Fig. 4). There was a bone destruction affecting the inner table with neoplastic tissue infiltrating the posterior and middle third of the SSS which was, however, not fully patent, but not already closed.

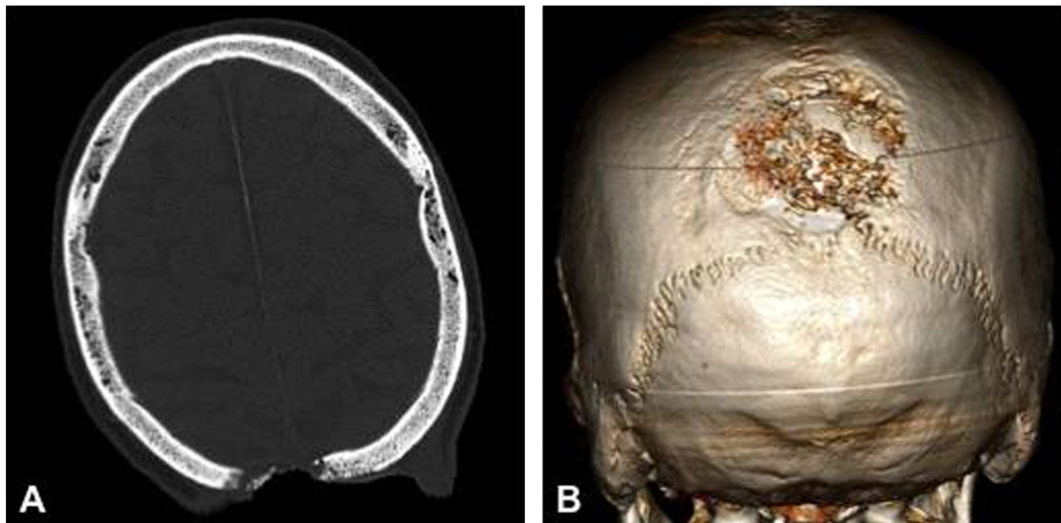


Fig. 2. A, Pre-operative CT scan showing the bone defect in the middle parieto-occipital region. B, 3-dimensional CT scan depicting the bone defect over the vertex.

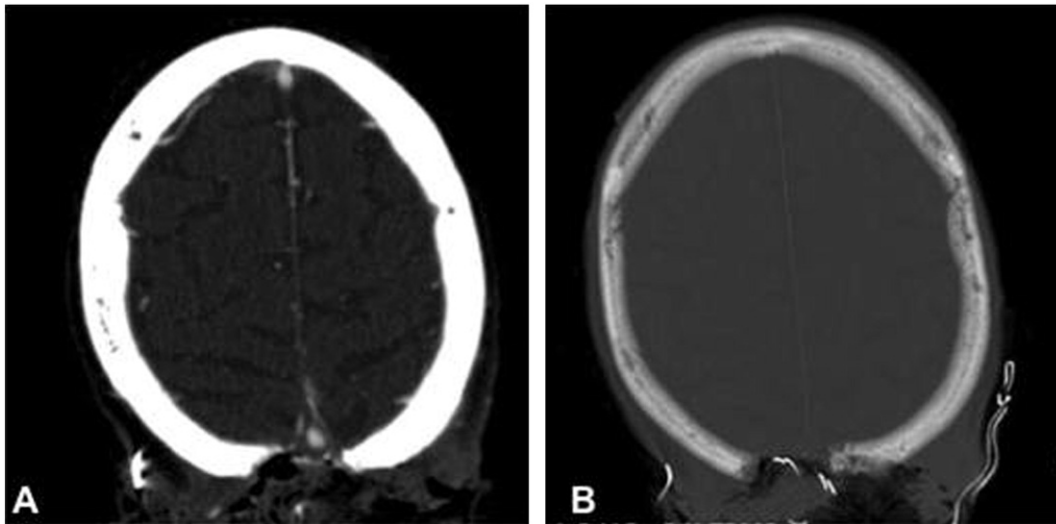


Fig. 3. A, Angio-CT showing the involvement of the superior sagittal sinus; B, The bone-window depicts the complete bone erosion.

2.3. Patient's course and outcome

The week following the surgical treatment the patient suffered three other episodes of massive bleeding, which were treated with the same

mechanical compression. A consultation with oncologists, plastic surgeons and neuroradiologists was performed to establish an adequate decision making process. Considering the massive infiltration into the adjacent tissues, which were severely damaged by the effects of

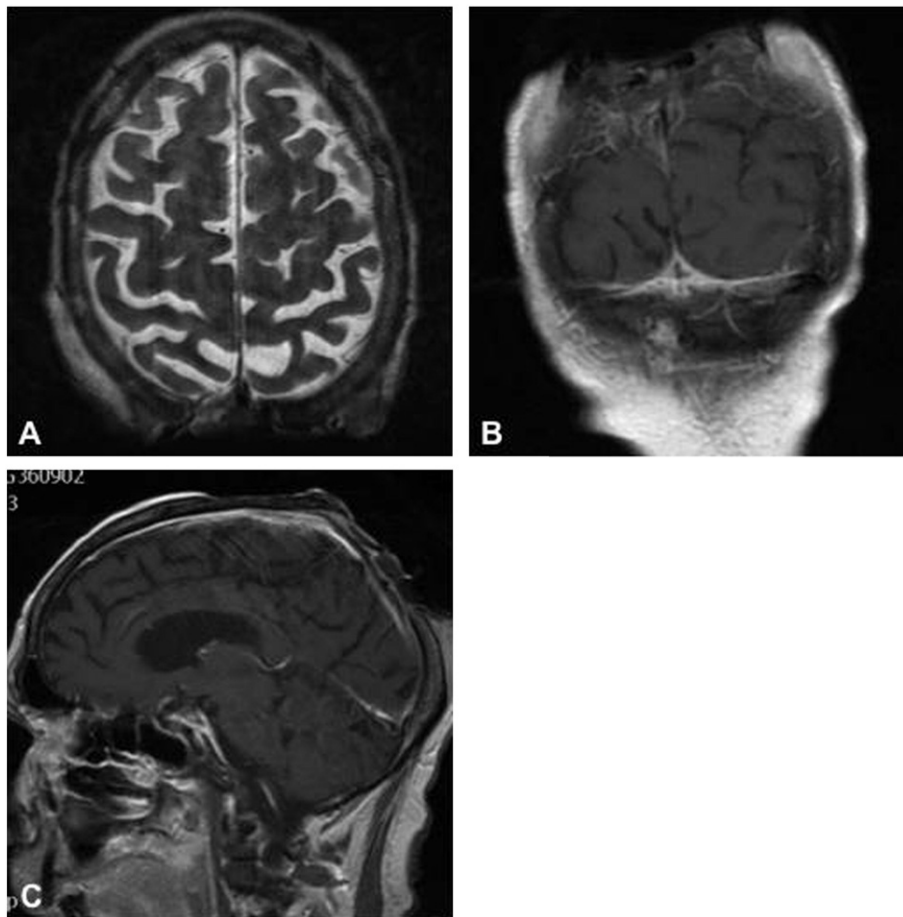


Fig. 4. A, MRI T2-weighted axial view. A large defect of the soft tissues is depicted, and the involvement of the superior sagittal sinus is also visible; B, The post-contrast T1-weighted coronal view depicts the large extension of the soft tissues and bone defect and the erosion of underlying structures; C, Post-contrastographic T1-weighted sagittal view showing the invasion of the lesion into the superior sagittal sinus.

radiotherapy, a plastic surgery treatment to cover the scalp defect was ruled out. A bypass of the sagittal sinus was considered, although highly hazardous on the basis of the massive extension of the tumor infiltration in the middle and posterior third of SSS with a major risk of a venous thrombosis. The patient was fully informed about the risks and refused the surgical procedure and further diagnostic studies. When general conditions were stable, he was discharged and suggested for palliative treatment. The patient did not experience more any bleeding from the skull in the next weeks. We presume for the progressive closure of SSS. The patient died ultimately after 6 months for a massive pulmonary embolism, due to his inactivity and infectious state, fatal consequence from his complicated BCC.

3. Discussion

BCCs are common malignant lesions of the skin which generally have an indolent course. They have a locally invasive behavior, rapidly infiltrating the underlying cranium and occasionally the dura if left untreated for a long period of time [4,5].

The reconstruction of the scalp defect following the resection of a large tumor usually poses a challenge especially when the defects over the convexity are very large [6,7]. In these cases there is not enough skin to provide proper coverage of the cranium and the options include local rotational flaps, local tissue rearrangement, vascularized flaps and other less common reconstructive options. Bone defects can be managed by either an autograft or an allograft (metals, calcium ceramics, polymers such as methyl methacrylate) to cover intracranial contents and restore the calvarial contour. When the scalp defect cannot be covered the co-operation of several specialists is required [3]. Only few cases of BCC of the scalp with intracranial invasion have been reported. Most of these patients did not seek medical attention and allowed the tumors to slowly progress over years [1,8].

In our case a clear invasion of the middle and posterior SSS was observed. The patient refused the surgical treatment and a conservative management was undertaken. Massive and infiltrating tumors invading the SSS preclude a complete resection because of the significant risk of venous thrombosis and venous infarction. Furthermore, an effective skin reconstruction was difficult to be achieved considering the poor quality of the left skin [4,9,10]. Our patient presented with a long history of prolonged cycles of radiotherapy to treat the tumor and its recurrences affecting the fronto-parietal site of the scalp. BBC recurrence after radiation is reported in a range varying from 1% to 35%. The radiotherapy treatment may prevent or reduce in the healing process of the skin and bone defect and in our case led to extension of the tumor into nervous structures [11].

Findings reported in our case suggest that early and appropriate treatment of BCC of the scalp should be undertaken rapidly following the diagnosis. Recurrences should be managed properly also by a judicious radiotherapy treatment. Although the gold standard therapy for BCC invading the scalp and the underlying structures would be a complete surgical excision, the involvement of the major veins or nervous tissue may prevent from such radical treatment. In these cases a conservative treatment has to be considered as reported in our experience, and patients may die from ultimately a fatal consequence from his complicated BCC which underscores the nastiness of these tumors!

4. Conclusions

Although BCC is a common tumor, its extension to the scalp is almost rare. In this clinical situation diagnosis should be undertaken through inspective exam and neuroradiological examinations in order to detect any intracranial extensions. Surgical treatment may be a demanding procedure that should be planned. Conservative treatment should be taken into account in inoperable patients or when the surgical treatment is refused. Strict follow-up and timely diagnosis are crucial since these lesions present life-threatening complications.

References

- [1] C.L. Kovarik, D. Stewart, J.J. Barnard, Lethal basal cell carcinoma secondary to cerebral invasion, *J. Am. Acad. Dermatol.* 52 (1) (2005) 149–151.
- [2] D. Mathieu, D. Fortin, Intracranial invasion of a basal cell carcinoma of the scalp, *Can. J. Neurol. Sci.* 32 (4) (2005) 546–548.
- [3] P.F. Soma, S. Chibbaro, O. Makiese, M. Marsella, P. Diemidio, M. Fricia, M. Passanisi, V. Catania, P. Siragò, F. Ventura, Aggressive scalp carcinoma with intracranial extension: a multidisciplinary experience of 25 patients with long-term follow-up, *J. Clin. Neurosci.* 15 (9) (2008) 988–992.
- [4] B.T. Andrews, M. Dujovny, H.G. Mirchandani, J.I. Ausman, Microsurgical anatomy of the venous drainage into the superior sagittal sinus, *Neurosurgery* 24 (4) (1989) 514–520.
- [5] U. Wollina, Y. Bayyoud, T. Kittner, E. Dürig, Giant tricholemmal squamous cell carcinoma with cranial infiltration, *J. Clin. Aesthet. Dermatol.* 4 (4) (2011) 34–37.
- [6] A. Giugno, R. Maugeri, S. D'Arpa, M. Visocchi, D.G. Iacopino, Complex reconstructive surgery following removal of extra-intracranial meningiomas, including the use of autologous fibrin glue and a pedicle muscle flap. *Interdisciplinary Neurosurgery* 1 (4) (2014) 84–87.
- [7] F. Graziano, F. Certo, L. Basile, R. Maugeri, G. Grasso, F. Meccio, M. Ganau, D.G. Iacopino, Autologous fibrin sealant (Vivostat®) in the neurosurgical practice: Part I: Intracranial surgical procedure, *Surg. Neurol. Int.* 6 (2015) 77.
- [8] M. Schroeder, R. Kestmeier, J. Schlegel, A.E. Trappe, Extensive cerebral invasion of a basal cell carcinoma of the scalp, *Eur. J. Surg. Oncol.* 27 (5) (2001) 510–511.
- [9] S.M. Raza, G.L. Gallia, H. Brem, J.D. Weingart, D.M. Long, A. Olivi, Perioperative and long-term outcomes from the management of parasagittal meningiomas invading the superior sagittal sinus, *Neurosurgery* 67 (4) (2010) 885–893.
- [10] M.P. Sindou, J.E. Alvernia, Results of attempted radical tumor removal and venous repair in 100 consecutivemeningiomas involving the major dural sinuses, *J. Neurosurg.* 105 (4) (2006) 514–525.
- [11] Y. Kleydman, S. Manolidis, D. Ratner, Basal cell carcinoma with intracranial invasion, *J. Am. Acad. Dermatol.* 60 (6) (2009) 1045–1049.