

Porcine Model for Internal Mammary Vessels Harvesting: Anatomy and Technique

Marta Cajozzo, MD*
Salvatore D'Arpa, MD, PhD*†
Tiziana Roggio, MD*
Pierluigi Tos, MD, PhD‡
Giorgio De Santis, Full Professor§
Davide Ciclamini, MD¶
Francesco Moschella, Full Professor*
Adriana Cordova, Full Professor*
Marco Pignatti, MD§

BACKGROUND

Recipient vessels selection is crucial for successful microsurgical breast reconstruction. The internal mammary vessels (IMVs) have gained great popularity, and they are often selected as first choice recipient vessels. The IMVs can be exposed for microvascular anastomosis through a rib-removing (trans-costal) or a rib-sparing (intercostal) approach.¹⁻³ Because the vessels are located between the rib cage and the parietal pleura, adequate training is needed to avoid and eventually manage bleedings and pleural perforation. This training is better performed in a nonhuman model.

Our aim was to investigate the pig as a surgical model for IMVs harvesting to be used in training.^{4,5}

METHODS

The procedure was performed on an adult common-breed female pig (*Sus scrofa domestica*), weighing 25 kg, under general anesthesia and in the supine position. The rib-sparing technique was performed first (Fig. 1), followed by rib resection and further vessel dissection (Fig. 2) to simulate both techniques. An arterial side branch was

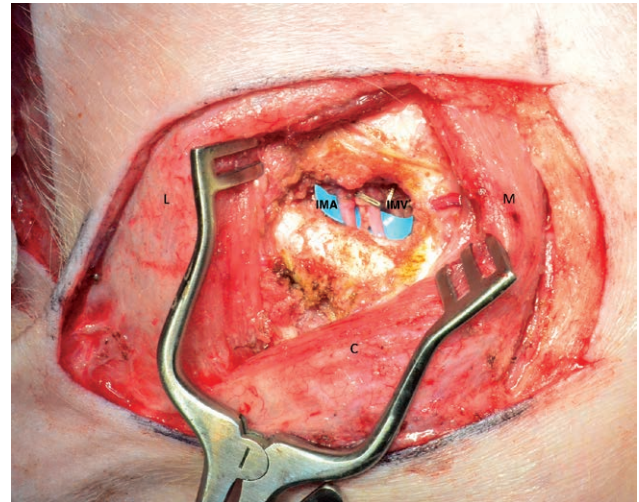


Fig. 1. Close up view of the right breast of a pig (head below, axilla on the left hand side). The surgical scenario of a mastectomy is reproduced by breast skin removal. The pectoralis major muscle is split along its fibers, which are held open with Weitlaner retractors to expose the third intercostal space. Between the 2 ribs, on the blue background, the IM artery and IMV are exposed. C, cranial; L, lateral; M, medial.

deliberately cut without ligation to simulate accidental bleeding.

The procedure was recorded by means of a GoPro camera and simultaneously with a head mounted (4× magnification) Loupecam system. Photographs were taken using 2 cameras during surgery at relevant time points.

RESULTS

Under a more prominent anterior thoracic wall, pigs' IMVs showed to be slightly larger and more resistant to manipulation than those in humans. The planes of dissection are quite similar to the human model, with the exception of a thinner adipose tissue layer and the presence of a panniculus carnosus, a rudimental layer of striated muscle deep to the panniculus adiposus.

Disclosure: The authors have no financial interest to declare in relation to the content of this article. The Article Processing Charge was paid for by the authors.

SICPRE: SICPRE, Società Italiana di Chirurgia Plastica Ricostruttiva ed Estetica, national meeting, in Turin on September 21-24, 2016.

From the *Plastic and Reconstructive, Department of Surgical, Oncological and Oral Sciences, University of Palermo, Palermo, Italy; †Department of Plastic and Reconstructive Surgery, Gent University Hospital, Ghent, Belgium; ‡Microsurgery and Hand Surgery Unit – ASST Gaetano Pini – CTO Milano, Milano, Italy; §Department of Plastic and Reconstructive Surgery, Azienda Ospedaliera-Universitaria Policlinico di Modena, Modena, Italy; and ¶Orthopaedic and Traumatology 2, Hand and Microsurgery Unit, A.O.U. Città della Salute e della Scienza, C.T.O. Hospital, Torino, Italy.
Copyright © 2018 The Authors. Published by Wolters Kluwer Health, Inc. on behalf of The American Society of Plastic Surgeons. This is an open-access article distributed under the terms of the Creative Commons Attribution-Non Commercial-No Derivatives License 4.0 (CCBY-NC-ND), where it is permissible to download and share the work provided it is properly cited. The work cannot be changed in any way or used commercially without permission from the journal. *Plast Reconstr Surg Glob Open* 2018;6:e1664; doi: 10.1097/GOX.0000000000001664; Published online 20 February 2018.

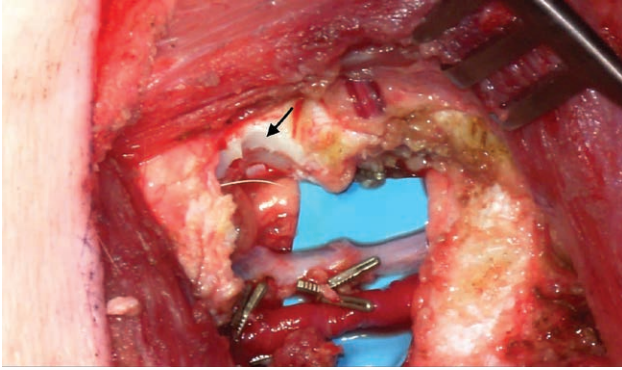


Fig. 2. Close up view of the internal mammary vessels (medial above, head on the right hand side). When the intercostal space is too narrow to perform microvascular anastomosis, a segment of the third or fourth rib cartilage can be removed (arrow) using a bone rongeur after dissecting the perichondrium off the cartilage.

The simulated bleeding was managed through side branch identification and ligation with no relevant blood loss, providing a great teaching material for the creation of our living training model.

CONCLUSIONS

Harvesting of the IMVs in the pig closely resembles the clinical scenario. The pig allows performance of both the rib-sparing and the rib-resecting techniques on the same side of the thorax at least once (which means at least 4 dissections per animal) but with the potential for harvest at multiple intercostal spaces on each side.

We believe that the pig model can be very useful because it allows training on a living (and bleeding)

model—better simulating the clinical scenario than a cadaver—and avoids the risks related to learning and training in humans.

Marta Cajazzo

Division of Plastic and Reconstructive Surgery
Department of Surgical, Oncological and Oral Sciences
University of Palermo
Via del Vespro 129
Palermo 90127, Italy
E-mail: mcajazzo@gmail.com

ACKNOWLEDGMENTS

The article processing charge was paid for by Egle Muti for Aldo Fontana.

REFERENCES

1. Parrett BM, Caterson SA, Tobias AM, et al. The rib-sparing technique for internal mammary vessel exposure in microsurgical breast reconstruction. *Ann Plast Surg.* 2008;60:241–243.
2. Ninković M, Anderl H, Hefel L, et al. Internal mammary vessels: a reliable recipient system for free flaps in breast reconstruction. *Br J Plast Surg.* 1995;48:533–539. Available at <http://www.ncbi.nlm.nih.gov/pubmed/8548152>. Accessed November 14, 2016.
3. Rosich-Medina A, Bouloumpasis S, Di Candia M, et al. Total ‘rib’-preservation technique of internal mammary vessel exposure for free flap breast reconstruction: a 5-year prospective cohort study and instructional video. *Ann Med Surg (Lond).* 2015;4:293–300.
4. Nistor A, Ionac M, Spano A, et al. Mastering the approach of internal mammary vessels: a new training model in pigs. *Plast Reconstr Surg.* 2013;131:859e–861e.
5. Bodin F, Diana M, Koutsomanis A, et al. Porcine model for free-flap breast reconstruction training. *J Plast Reconstr Aesthet Surg.* 2015;68:1402–1409.