

Case Report Clinical Pathology

Medication-related osteonecrosis of the jaw in a cancer patient receiving lenvatinib

**R. Mauceri¹, V. Panzarella¹,
I. Morreale², G. Campisi¹**

¹Department of Surgical, Oncological, and Oral Sciences, Sector of Oral Medicine “Valerio Margiotta”, University of Palermo, Palermo, Italy; ²Clinical Pharmacology Unit, Sicilian Regional Centre of Pharmacovigilance, Azienda Ospedaliera Universitaria Policlinico P. Giaccone, University of Palermo, Palermo, Italy*Address: Giuseppina Campisi, Department of Surgical, Oncological and Oral Sciences, University of Palermo, Via del Vespro 129, Palermo 90127, Italy. Tel/Fax: +39 091 23864244.

Abstract. Medication-related osteonecrosis of the jaw (MRONJ) is an adverse drug reaction that affects the mandible and maxilla of patients exposed to bone-targeting agents such as anti-resorptive and anti-angiogenic agents. Several MRONJ cases have been reported after dental extractions in patients under treatment with anti-angiogenic agents, including receptor activator of nuclear factor κ B ligand (RANKL) inhibitor, anti-vascular endothelial growth factor (anti-VEGF) monoclonal antibody, mammalian target of rapamycin (mTOR) inhibitors, and tyrosine kinase inhibitors (TKIs). The aim of this article was to describe an original case of lenvatinib-related osteonecrosis of the jaw in a patient affected by thyroid cancer. A 58-year-old man diagnosed with Hurthle cell thyroid cancer, who was undergoing treatment with lenvatinib, developed maxillary osteonecrosis after a dental extraction. No other concomitant local or systemic risk factors for MRONJ were present. With new cancer therapies applied every year, it is important to note this novel case of lenvatinib osteonecrosis of the jaw in a patient undergoing cancer treatment.

Key words: lenvatinib; osteonecrosis of the jaw; MRONJ; dental extraction.

Accepted for publication
Available online 2 August 2019

Medication-related osteonecrosis of the jaw (MRONJ) is a relatively uncommon adverse drug reaction, described as the progressive destruction and death of bone. It affects the mandible and maxilla of patients exposed to several medications that are known to increase the risk of disease.

MRONJ often develops after exposure to anti-resorptive drugs. These agents, defined as bone-targeting agents, are usually applied in oncology for the prevention of skeletal-related events in patients with

bone metastases or myeloma. The anti-resorptive agents mainly include bisphosphonates and denosumab. However, new bone-targeting agents with no anti-resorptive properties have been introduced in recent years, including anti-angiogenic agents (e.g., receptor activator of nuclear factor κ B ligand (RANKL) inhibitor, anti-vascular endothelial growth factor (anti-VEGF) monoclonal antibody, mammalian target of rapamycin (mTOR) inhibitors, and small molecule tyrosine kinase inhi-

bitors (TKIs)), and anti-angiogenic agents have also been associated with the development of MRONJ^{1–5}.

The diagnosis of MRONJ is based on the patient's medical and medication history and on the clinical–radiological features of necrotic bone (exposed or not exposed)^{1,3,6,7}.

The case of a patient under treatment with lenvatinib for progressive Hurthle cell thyroid cancer, who developed MRONJ with no history of anti-resorptive treatment, is described below.

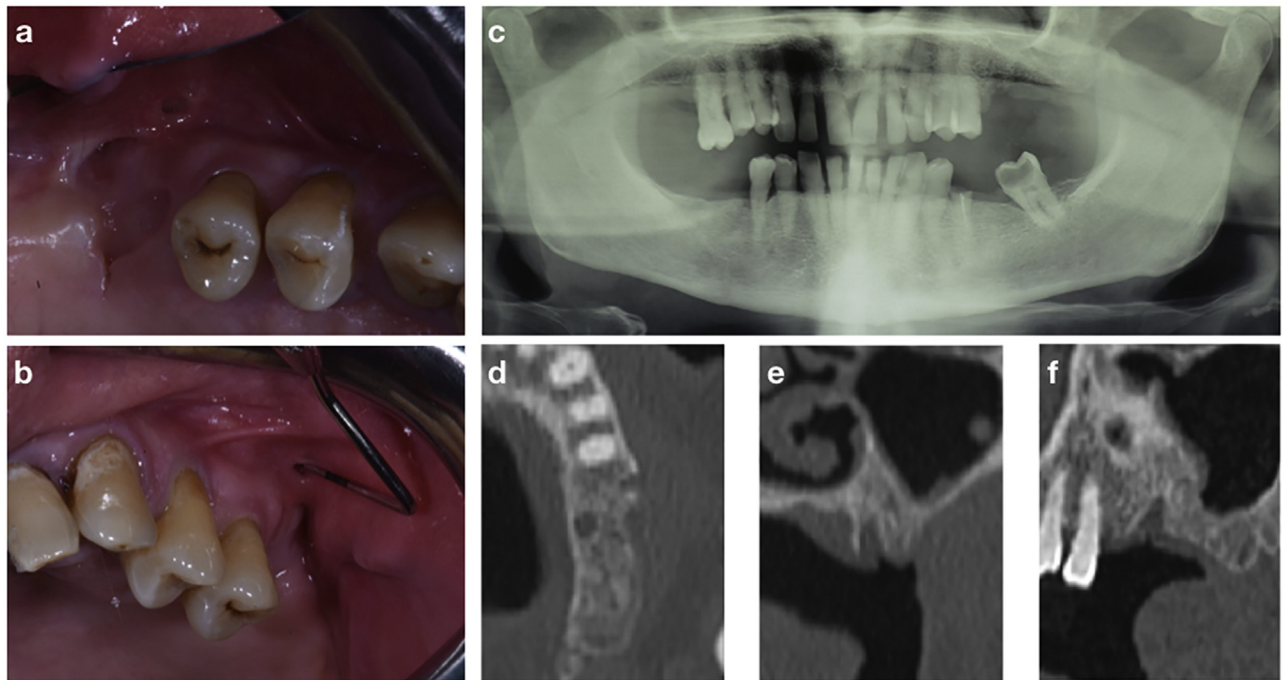


Fig. 1. Left-sided maxillary MRONJ: (a) (b) clinical views; (c) panoramic X-ray; (d) (e) (f) computed tomography scan sections.

Case report

A 58-year-old man was referred by his dentist for a long-standing non-healing socket in the maxilla after a dental extraction. In 2015, the patient had been diagnosed with Hurthle cell thyroid cancer and had undergone a total thyroidectomy, followed by adjuvant radiotherapy. The following year, the patient had developed pulmonary metastases identified by dual positron emission tomography/computed tomography (PET/CT) scan and confirmed by lung biopsy. Subsequently the patient was subjected to first-line chemotherapy (i.e., doxorubicin and cisplatin-based), and he was given oral cyclophosphamide and methotrexate from April 2016.

In February 2017, due to progressive disease of the lungs, the patient was treated with lenvatinib (24 mg orally once daily for 1 month). Then, due to the development of severe arthralgia and muscle cramps with ambulation difficulties, the lenvatinib dose was reduced to 14 mg once daily. After 12 months of lenvatinib intake, the maxillary left first molar was extracted because of deep caries. Healing of the socket was never achieved.

Two months after the dental extraction, intraoral examination revealed clinical signs of MRONJ. Bone that could be probed through two intraoral fistulas was present, associated with purulent exudation and chronic pain (Fig. 1a, b). A panoramic X-ray showed incomplete bone remodelling in the post-extraction socket

(Fig. 1c). Further assessment by CT scan showed focal osteosclerosis of the jaw associated with persisting alveolar socket and cortical disruption (Fig. 1d–f). These signs were consistent with MRONJ, which was classified as stage I according to the American Association of Oral and Maxillofacial Surgeons (AAOMS) criteria and also the Italian consensus^{3,6,7}.

Treatment with lenvatinib was discontinued by the oncologist and the patient was treated medically with a combination of ampicillin and sulbactam (1 g intramuscularly twice daily for 7 days) and metronidazole (500 mg orally three times daily for 7 days), associated with the use of chlorhexidine 0.2% mouthwash (30 ml swished for up to 60 seconds, three times daily for 14 days) and sodium hyaluronate (local application three times daily for 14 days). At the latest follow-up, after 6 months, the patient was asymptomatic and the intraoral fistulas had healed.

Discussion

Since 2003, most cases of MRONJ have been related to the use of bisphosphonates. However, recent studies have shown that other anti-resorptive agents (i.e., denosumab) and anti-angiogenic agents (e.g., inhibitors or TKIs) can be associated with MRONJ^{1–5}. To date, the majority of MRONJ cases described in the literature have been related to local risk factors, commonly dental extraction^{1,3,8}. However, in the presence of dental diseases that cannot

otherwise be resolved, tooth extraction with standardized protocols may actually decrease the risk of MRONJ development^{8,9}.

Lenvatinib is a small-molecule inhibitor that inhibits receptor tyrosine kinases (RTKs) of vascular endothelial growth factor receptors (e.g., VEGFR1, VEGFR2, VEGFR3), as well as other RTKs including fibroblast growth factor receptor, platelet-derived growth factor receptor alpha, KIT, and RET. These RTKs are responsible for pathogenic angiogenesis, tumour growth, and cancer progression.

In Europe, lenvatinib was first approved for the treatment of adult patients with progressive, locally advanced or metastatic, differentiated (e.g., papillary/follicular/Hurthle cell) thyroid carcinoma that is refractory to radioactive iodine, in 2015. This approval was based on the results of the pivotal phase 3 study of lenvatinib (E7080) in differentiated cancer of the thyroid (SELECT), where lenvatinib significantly prolonged progression-free survival vs. placebo (median progression-free survival 18.3 vs. 3.6 months; hazard ratio 0.21, 99% confidence interval 0.14–0.31; $P < 0.001$).¹⁰ In the SELECT trial, nearly all of the 392 patients enrolled experienced an adverse event.

The most common adverse effects of lenvatinib are headache, hypertension, proteinuria, dysphonia, palmar-plantar erythrodysesthesia syndrome, arthralgia or myalgia, decreased appetite, and gastrointestinal disturbances. Serious events, including QT prolongation, posterior reversible

leukoencephalopathy syndrome, hepatic, renal, or cardiac failure, intracranial tumour haemorrhage, gastrointestinal perforation or fistula, and arterial thromboembolism, have also been reported. Of note, delayed wound healing is also a recognized adverse effect of lenvatinib^{10,11}.

Within the group of TKIs, sorafenib, sunitinib, and cabozantinib already carry a recognized risk of MRONJ development^{2,4,5}. The patient case presented here is novel and appears to be the first published case of lenvatinib-associated osteonecrosis of the jaw. This patient developed the common clinical-radiological features of MRONJ, without prior exposure to anti-resorptive and/or anti-angiogenic drugs related to osteonecrosis of the jaw. The patient was only exposed to dental extraction and had no other concomitant recognized local or systemic risk factors for MRONJ. While awaiting new reports to confirm the occurrence of lenvatinib-associated osteonecrosis of the jaw, it is considered that due to its mechanism of action, lenvatinib may be a further anti-cancer agent associated with this condition.

Side effects of lenvatinib can be observed at any time following lenvatinib initiation, and these side effects are caused by the effects of lenvatinib on VEGF inhibition¹⁰. VEGF is an important mediator of the angiogenic process; it is required for bone formation and repair and is the main signal between osteoblast cells and endothelial cells. In addition, the high bone turnover of the jaws makes this area reliant on the effective function of osteoblasts and osteoclasts.

The data presented herein are consistent with those of other reports highlighting the important role of anti-angiogenic drugs that act directly on VEGF (e.g., bevacizumab) in predisposing patients to osteonecrosis of the jaw, regardless of their association with bisphosphonates.

As new drugs with multi-target actions are applied in anticancer therapy every year, clinicians need to pay attention to oral health problems and their management during the use of these new therapies, in order to reduce outbreaks of MRONJ and consequently improve the quality of life of patients who are already afflicted by serious primary pathologies.

Funding

The study has been funded by the PSN 2014 project, action 5.37 “Consolidamento e ampliamento network teleconsulto per la medicina orale”.

Competing interests

The authors declare no conflicts of interest.

Ethical approval

All procedures performed in this study that involved human participants were in accordance with the ethical standards of the institutional and/or national research committee and with the 1964 Helsinki Declaration and its later amendments or comparable ethical standards.

Patient consent

Written consent was obtained for publication.

Acknowledgements. The authors want to thank Professor Olga Di Fede for his active clinical assistance during the study.

References

- Campisi G, Fedele S, Fusco V, Pizzo G, Di Fede O, Bedogni A. Epidemiology, clinical manifestations, risk reduction and treatment strategies of jaw osteonecrosis in cancer patients exposed to antiresorptive agents. *Future Oncol* 2014;**10**:257–75. <http://dx.doi.org/10.2217/fon.13.211>.
- Fusco V, Santini D, Armento G, Tonini G, Campisi G. Osteonecrosis of jaw beyond antiresorptive (bone-targeted) agents: new horizons in oncology. *Expert Opin Drug Saf* 2016;**15**:925–35. <http://dx.doi.org/10.1080/14740338.2016.1177021>.
- Ruggiero SL, Dodson TB, Fantasia J, Goodday R, Aghaloo T, Mehrotra B, O’Ryan F, American Association of Oral and Maxillofacial Surgeons, et al. American Association of Oral and Maxillofacial Surgeons position paper on medication-related osteonecrosis of the jaw—2014 update. *J Oral Maxillofac Surg* 2014;**72**:1938–56. <http://dx.doi.org/10.1016/j.joms.2014.04.031>.
- Nicolatou-Galitis O, Kouri M, Papadopoulou E, Vardas E, Galiti D, Epstein JB, Elad S, Campisi G, Tsoukalas N, Bektas-Kayhan K, Tan W, Body JJ, Migliorati C, Lalla RV, MASCC Bone Study Group. Osteonecrosis of the jaw related to non-antiresorptive medications: a systematic review. *Support Care Cancer* 2019;**27**(2):383–94. <http://dx.doi.org/10.1007/s00520-018-4501-x>.
- Pimolbutr K, Porter S, Fedele S. Osteonecrosis of the jaw associated with antiangiogenics in antiresorptive-naïve patient: a comprehensive review of the literature. *Biomed Res Int* 2018;**2018**:1–14. <http://dx.doi.org/10.1155/2018/8071579>.
- Bedogni A, Fedele S, Bedogni G, Scoletta M, Favia G, Colella G, Agrillo A, Bettini G, Di Fede O, Oteri G, Fusco V, Gabriele M, Ottolenghi L, Valsecchi S, Porter S, Petrucci M, Arduino P, D’Amato S, Ungari C, Fung Polly PL, Saia G, Campisi G. Staging of osteonecrosis of the jaw requires computed tomography for accurate definition of the extent of bony disease. *Br J Oral Maxillofac Surg* 2014;**52**:603–8. <http://dx.doi.org/10.1016/j.bjoms.2014.04.009>.
- Fedele S, Bedogni G, Scoletta M, Favia G, Colella G, Agrillo A, Bettini G, Di Fede O, Oteri G, Fusco V, Gabriele M, Ottolenghi L, Valsecchi S, Porter S, Fung PP, Saia G, Campisi G, Bedogni A. Up to a quarter of patients with osteonecrosis of the jaw associated with antiresorptive agents remain undiagnosed. *Br J Oral Maxillofac Surg* 2015;**53**:13–7. <http://dx.doi.org/10.1016/j.bjoms.2014.09.001>.
- Otto S, Tröltzsch M, Jambrovic V, Panya S, Probst F, Ristow O, Ehrenfeld M, Pautke C. Tooth extraction in patients receiving oral or intravenous bisphosphonate administration: a trigger for BRONJ development? *J Craniomaxillofac Surg* 2015;**43**:847–54. <http://dx.doi.org/10.1016/j.jcms.2015.03.039>.
- Di Fede O, Panzarella V, Mauceri R, Fusco V, Bedogni A, Lo Muzio L, Sipmo Onj Board, Campisi G. The dental management of patients at risk of medication-related osteonecrosis of the jaw: new paradigm of primary prevention. *Biomed Res Int* 2018;**2018**:1–10. <http://dx.doi.org/10.1155/2018/2684924>.
- Schlumberger M, Tahara M, Wirth LJ, Robinson B, Brose MS, Elisei R, Habra MA, Newbold K, Shah MH, Hoff AO, Gianoukakis AG, Kiyota N, Taylor MH, Kim SB, Krzyzanowska MK, Dutcu CE, de las Heras B, Zhu J, Sherman SI. Lenvatinib versus placebo in radioiodine-refractory thyroid cancer. *N Engl J Med* 2015;**372**:621–30. <http://dx.doi.org/10.1056/NEJMoa1406470>.
- European Medicines Agency. *Lenvima*. EMA; 2019 [Accessibility verified July 15, 2019] <https://www.ema.europa.eu/en/medicines/human/EPAR/lenvima>.

R. Mauceri¹
V. Panzarella¹
I. Morreale²
G. Campisi^{1*}

¹ Department of Surgical, Oncological, and Oral Sciences, Sector of Oral Medicine “Valerio Margiotta”, University of Palermo, Palermo, Italy

² Clinical Pharmacology Unit, Sicilian Regional Centre of Pharmacovigilance, Azienda Ospedaliera Universitaria Policlinico P. Giaccone, University of Palermo, Palermo, Italy

*Address: Giuseppina Campisi, Department of Surgical, Oncological and Oral Sciences, University of Palermo, Via del Vespro 129, Palermo 90127, Italy.
Tel/Fax: +39 091 23864244.
E-mail address: campisi@odonto.unipa.it
(V. Panzarella)