

HEAD AND NECK

The immunohistochemical peptidergic expression of leptin is associated with recurrence of malignancy in laryngeal squamous cell carcinoma

L'espressione peptidergica immunoistochimica della leptina è associata con la recidiva del carcinoma squamoso laringeo

S. GALLINA¹, F. SIRECI¹, F. LORUSSO¹, D.V. DI BENEDETTO¹, R. SPECIALE¹, D. MARCHESE¹, C. COSTANTINO², G. NAPOLI², V. TESSITORE³, D. CUCCO³, A. LEONE³, G. BONAVENTURA³, M.L. UZZO³, G.F. SPATOLA³

¹Otorhinolaryngology Section, Department of Experimental Biomedicine and Clinical Neurosciences, (BioNeC), University of Palermo; ²Department of Science for Health Promotion and Mother to Child Care "G. D'Alessandro", University of Palermo; ³Histology and Embryology Section, Department of Experimental Biomedicine and Clinical Neurosciences, (BioNeC), University of Palermo

SUMMARY

Leptin is a peptide that plays a key role in the control of satiety, energy expenditure, food intake and various reproductive processes. In the last years, the expression of leptin had been found in malignant cells of various origins. The aim of this study is to evaluate leptin expression in human laryngeal squamous cell carcinoma (SCC) and to investigate its possible role in predicting prognosis. Leptin expression was determined by immunohistochemistry in pathological and healthy tissue specimens from 24 patients with laryngeal SCC. Specimens were stained with an anti-leptin antibody. All measurements were performed using a computer-based image analysis system and scale of staining intensity was determined. All tumoural specimens showed significant immunoreactivity for leptin compared to healthy tissues ($p \leq 0.05$), but showed different immunoreactivity that was related to clinicopathological features. High leptin expression was not significantly related with TNM, histological grading (HG) or advanced (III and IV) clinical stage ($p > 0.05$). Recurrence of malignancy was found to be significantly related with high expression of leptin by Spearman's rank correlation test ($\rho = 0.59$; $p = 0.002$), Fisher's test ($p = 0.017$) and Kaplan-Meier product-limit estimate (Log-rank test, $p \leq 0.05$). In particular, multivariate logistic regression analysis showed that recurrences were significantly related with nodal involvement, HG and leptin expression ($p \leq 0.05$). These preliminary results suggest that leptin may be a valuable parameter for predicting prognosis in laryngeal SCC.

KEY WORDS: Leptin • Laryngeal carcinoma • Malignancy recurrence

RIASSUNTO

La leptina è un peptide che svolge un ruolo chiave nel controllo della sazietà, del dispendio energetico, dell'assunzione di cibo, e in vari processi riproduttivi. Negli ultimi anni, la leptina è stata trovata espressa nelle cellule maligne di varia origine. Lo scopo di questo studio è quello di valutare l'espressione di leptina nel carcinoma a cellule squamose della laringe umana (SCC) e di ricercare un suo possibile ruolo prognostico. L'espressione di leptina è stata determinata mediante immunoistochimica in campioni di tessuto patologico e sano di 24 pazienti con SCC laringea. I campioni sono stati colorati con anticorpo monoclonale anti-leptina. La valutazione dell'espressione immunoistochimica è stata eseguita da un sistema computerizzato che analizzava le immagini e stabiliva una scala di intensità di colorazione. Tutti i campioni tumorali esaminati hanno mostrato immunoreattività significativa per la leptina rispetto ai tessuti sani ($p \leq 0,05$), ma è stata mostrata una diversa correlazione tra immunoreattività e caratteristiche clinico-patologiche. L'alta espressione della leptina non è correlata in modo statisticamente significativo con stadiazione TNM, grading istologico (HG) e stadio clinico avanzato ($p > 0,05$). L'insorgenza di recidive è risultata significativamente correlata con alta espressione di leptina tramite il test di correlazione di Spearman ($\rho = 0,59$, $p = 0,002$), test di Fisher ($p = 0,017$) e analisi di Kaplan-Meier (log-rank test, $p \leq 0,05$). In particolare, l'analisi di regressione logistica multivariata ha dimostrato che le recidive erano significativamente correlate con il coinvolgimento linfonodale (N), HG e l'espressione di leptina ($p \leq 0,05$). I nostri risultati preliminari suggeriscono che la leptina può essere un utile parametro prognostico.

PAROLE CHIAVE: Leptina • Carcinoma della laringe • Recidiva

Introduction

Leptin is a peptide produced by peptidergic cells or those able to process and secrete peptides. Originally, this function was considered proper and exclusive of certain neurons of the magnocellular and parvocellular hypothalamus¹⁻³. For the first time, Pearse found cells with monoaminergic function (amine precursor uptake and decarboxylation system, APUD) in the gastro-entero-pancreatic system (GEP)^{4,5}. Later, it was demonstrated that these cells originated from a common precursor, namely neural crest cells, which have the ability to produce hormonal neuropeptides⁶. From this primitive neuroectodermal site, cells migrate to other organs: GEP, lung, heart, reproductive and urinary system^{7,8}. Therefore, the APUD system was renamed as the Diffuse Neuro-Endocrine System (DNES)⁹.

Leptin (167 amino acids with a molecular mass of 16 kDa) is considered the typical neuropeptide with anorexigenic function, and is also called the “satiety hormone” because it plays a key role in control of energy expenditure and food intake. Leptin was identified for the first time in white and brown adipocytes¹⁰. The plasmatic levels of leptin are representative of adipose tissue and increases are related in a logarithmic fashion with an increase in body mass in mice^{11,12}. Leptin acts on the hypothalamic receptor (OBR) where it exerts the control of food intake and body weight through a negative feedback mechanism (anorexigenic function)¹³. Although initially thought to be exclusively expressed and secreted by adipocytes, leptin has been identified in other tissues related with nutritional homeostasis, such as gastric¹⁴ and salivary glands¹⁵⁻¹⁹. Leptin was later identified in organs unrelated with nutritional balance such as the placenta²⁰, mammary epithelial cells²¹ and lung²², where it performs a different functional role.

In addition, leptin or its receptors have been observed in gastric, colorectal and breast cancers. It is believed to have a role in stimulating cell proliferation, and is associated with a risk of developing cancer as well as progression and invasiveness²³⁻²⁵.

To date, the role of leptin in the development of the carcinoma of the larynx has not been investigated. Laryngeal cancer represents 20.8% of head and neck squamous cell carcinoma (HNSCC)²⁶, and although a large variety of malignancies may occur in the larynx, 85-95% of laryngeal malignancies are squamous cell carcinoma (SCC), arising from the epithelial lining of the larynx²⁷.

Patients with HNSCC have greatly benefited from the recent advances in surgical techniques, radiation therapy and chemotherapy. However, the survival rates for SCC have not improved significantly over the past two decades²⁸.

The principal endpoint of this study was to evaluate peptidergic immunohistochemical expression of leptin in la-

ryngeal SCCs and secondly to investigate its possible role in predicting prognosis and loco-regional recurrences.

Materials and methods

Patients

A consecutive series of 24 patients affected by laryngeal SCC were identified at the Section of Otolaryngology of Palermo University between 2010 and 2012. Selected patients had an age between 43 and 85 years, with mean age 62.3 years (SD 13.53). Informed consent was obtained from each patient. All patients were male and heavy smokers (> 20 cigarettes/day). All patients were examined with a flexible fiberoptic laryngoscopy. Subsequently, all patients underwent head and neck computerised tomography (CT) to highlight extension of the tumour and nodal involvement. Patients were biopsied by suspension microlaryngoscopy (DML). The Department of Human Pathology concluded that biopsy specimens were compatible with laryngeal SCC.

All patients underwent partial or total laryngectomy. In 22 (91.6%) cases, neck dissection was also performed. Ten (41.6%) patients underwent also post-operative radiotherapy. All specimens were sent to the Histology and Embryology Section of the University of Palermo. For each patient, two samples were collected from different locations: tumour (central portion of lesion without necrosis signs) and healthy epithelium (> 1 cm distance to the tumour margin resulting negative for malignancy at histological examination). Healthy laryngeal tissues were used as controls. All patients were subjected to follow-up. Mean follow-up time (calculated in months from treatment completion to the last otolaryngological control) was 32.25 months (range 13-39 months). Pathological staging according to the Tumor, Lymph Node, Metastases TNM system of the Union for International Cancer Control (7th edition) and histological grade was determined according to the degree of differentiation of the tumour. The characteristics of the patients studied and clinic-pathological features are shown in Table I.

Tissue preparation

All tissues were fixed in 10% buffered formalin and after 12-24 hours depending on the size of the sample were subjected to a wash cycle in H₂O and then dehydrated with increasing grade alcohol solutions (70%, 95%, 100%) and cleared in xylene before inclusion in paraffin. Samples were cut and processed for immunohistochemistry using monoclonal antibodies against leptin and revealed using an En Vision + System-HRP detection kit with AEC as the substrate (Dako).

Immunohistochemistry

Serial sections 8 m thick were cut with a Leica microtome RM2145, dried overnight at 37°C and then stored at room

Table I. Clinicopathologic characteristics of 24 patients with laryngeal squamous cell carcinoma and correlation with expression of leptin.

Parameter	N (%)	Leptin		p value	
		Low	High		
Cases	24	8 (33.3)	16 (66.6)		
Age (years)	≤ 59	8 (33.3)	4 (50)	0.17	
	> 59	16 (66.6)	4 (25)		
pT1	-	-	-		
pT2	6 (25)	4 (66.6)	2 (33.3)		
pT3	12 (50)	4 (33.3)	8 (66.6)		
PT4	6 (25)	-	6 (100)		
T stage (early/advanced)					
	T1-T2 (early)	6 (25)	4 (66.6)	0.062	
	T3-T4 (advanced)	18 (75)	4 (22.2)		
pN0		14 (58.3)	4 (28.6)	10 (71.4)	
pN1		2 (8.3)	-	2 (100)	
pN2		6 (25)	4 (66.6)	2 (33.3)	
pN3		2 (8.3)	-	2 (100)	
Tot			8 (33.3)	16 (66.6)	
N0 and N+ category					
	N0	14 (58.3)	4 (28.6)	10 (71.4)	0.43
	N+	10 (41.6)	4 (40)	6 (60)	
Stage I		-	-	-	
Stage II		4 (16.6)	2 (50)	2 (50)	
Stage III		8 (33.3)	2 (25)	6 (75)	
Stage IV		12 (50)	4 (33.3)	8 (66.6)	
Stage (early/advanced)					
	Early (I-II)	4 (16.6)	2 (50)	2 (50)	0.47
	Advanced (III-IV)	20 (83.3)	6 (30)	14 (70)	
Grading (early and advanced)					
G1		4 (16.6)	-	4 (100)	0.17
G2		10 (41.6)	4 (40)	6 (60)	
G3		10 (41.6)	4 (40)	6 (60)	
	Early (G1)	4	-	4	
	Advanced (G2-G3)	20	8	12	
Loco-regional recurrence					
	No	16 (66.6)	8 (50)	8 (50)	0.017
	Yes	8(33.3)	-	8 (100)	

temperature. The day after, slides were dewaxed and re-hydrated by sequential immersion in a graded series of alcohols and transferred into water for 5 min; to inhibit any endogenous peroxidase activity slides were treated for 5 min with Peroxidase Block in hydrated incubation enclosure at room temperature. Subsequently, sections were transferred in PBS (Na_2HPO_4 , KH_2PO_4 , KCl, NaCl pH 7.4-7.6) at room temperature. The protocol was performed using the kit En-Vision + System HRP with AEC as the substrate (Dako). After rinsing with PBS for 4 min, sections were incubated overnight at 4°C with polyclonal anti-leptin (Ob A-20) (Santa Cruz Biotechnology, Inc)

diluted 1:100. After the incubation, any excess antibody was removed by washing with PBS for 5 min. Sections were incubated with peroxidase-labelled polymer conjugated to goat anti-rabbit immunoglobulin in Tris-HCl buffer containing stabilising protein and an antimicrobial agent. Unbound polymer was removed by washing (2x with PBS, 5 min each) and subsequently AEC chromogen in substrate buffer was then added for 5 min and the reaction was stopped in distilled water. Slides were removed from water and one drop of aqueous mounting medium (DAKO Faramount) and a coverslip, were applied to tissue sections.

Negative controls were performed by omission of primary antibody, and by incubating sections with antiserum saturated with homologous antigen.

Image analysis

Immunohistochemical specimens were examined using a Leica Laborlux S Microscope (Leica Microsystem GmbH Wetzlar, Germany) with a Nikon DSL2 photo digital system (Nikon Corp, Tokyo, Japan). Each sample was analysed with a double-blind system with two different operators. Moreover, the results were compared to an image analysis obtained from digital TIF files. Adobe Photoshop CS6 extended (Adobe Systems Inc., San Jose, CA) was used to elaborate images. Choosing the image in a field of $\times 40$, we converted the image colour profile from RGB to CMYK. Next, we chose the yellow channel because the literature indicates that it has the best linear response to colour intensity and thus to the presence of protein.

The images were processed and coded by the software in a grey intensity scale according to colour luminance (from 0 to 256 grey values in our measurements). In particular, 0 is white colour and corresponds to lowest value of intensity, while 256 is black colour and corresponds to highest value of intensity. The staining was scored as 0 (0-50 grey value) if there was no immunoreactivity, 1 (51-100 grey value) if staining was slight, 2 (101-150 grey value) if staining was moderate, 3 (151-200 grey value) if staining was high and 4 (201-256 grey value) if staining was maximum.

Statistical analysis

All statistical analyses were performed using the R statistical software package version 2.2.0. Fisher's exact test was used for comparison between categorical variables and correlation with clinical data was evaluated by Spearman correlation coefficient. Time-to-event analyses were calculated using the Kaplan-Meier product-limit estimate. Multivariate logistic regression analysis was also applied to evaluate the association between malignancy recurrence after treatment, leptin expression and other pathological features. We considered a $p \leq 0.05$ to be significant; values in the following range $0.10 > p > 0.05$ were considered to indicate a statistical trend.

Results

Clinicopathologic and histological characteristics of patients

All 24 patients included in this study were affected by SCC and were male, with a mean age of 62.3 years (SD 13.5; range 43-85 years) (Table I). Following guidelines of laryngeal cancer treatment proposed by the Italian Society of Otorhinolaryngology and Cervicofacial Surgery²⁹, total laryngectomy was performed in 10 (41.6%) cases and partial laryngectomy in 14 (58.3%), of which 10 pa-

tients with horizontal supraglottic laryngectomy (HSL), two with frontal-lateral laryngectomy (FLL) and two with cricothyroidopexy (CHP). Six patients had a T2 pathological tumour stage, 12 had T3 and six had T4. Twenty-two (91.6%) patients received selective neck dissection simultaneously to removal of the primary tumour and lymph node metastasis were present in 10 (41.6%) cases (pN+). There were no distant metastases.

Six (25%) patients had early cancer (Stage I or II) and 18 (75%) had advanced cancer (Stage III or IV). Four patients had a well differentiated tumour (G1), 10 had a moderately differentiated tumour (G2) and 10 a poorly differentiated tumour (G3).

Ten (41.6%) patients underwent postoperative radiotherapy. Mean follow-up time (calculated in months from treatment completion to the last otolaryngological control) was 32.25 months (range 13-39 months). During follow-up, 8 (33.3%) patients developed a malignancy recurrence (4 local recurrences, 4 recurrences to neck lymph nodes) after a mean period of 14.25 months (SD 7.10 months).

All tumour tissues showed significant expression of leptin ($p \leq 0.05$) compared with healthy control tissues (Table II). In particular, 8 cases showed low immunoreactivity (33%) and 16 cases showed high immunoreactivity (66.6%). High expression was seen in the neoplastic mucosal epithelium and in solid nests of tumour cells infiltrating connective underlying structures (Fig. 5a). The glandular epithelium showed negative immunohistochemistry (Fig. 5b). Cytoplasmic staining was predominant in all tissues. Among the healthy control tissues, only 6 cases (25%) showed a low immunoreactivity (1 according to our score) (Fig. 5c).

Comparing the immunohistochemical features of each case, we found a different expression of leptin in relation to different clinicopathological features.

Leptin and TNM staging

18 (75%) patients with advanced stage (T3-T4) showed immunoreactivity for leptin. In particular, 14 (77%) of these had high expression of leptin, showing a statistical trend, but without a significant difference compared with patients with early stage tumours ($p = 0.062$). In the 10 cases that were pN+, Fisher's test did not reveal any significant difference ($p = 0.43$) between patients with high expression of leptin (60%) compared with pN+ cases with low expression (40%). Spearman's rank correlation test showed a statistical trend between leptin and T isolated

Table II. Expression of leptin in laryngeal squamous cell carcinoma and normal laryngeal tissues.

	Cases	Controls	p value
Leptin			
Yes	24	6	0.001
No	0	18	

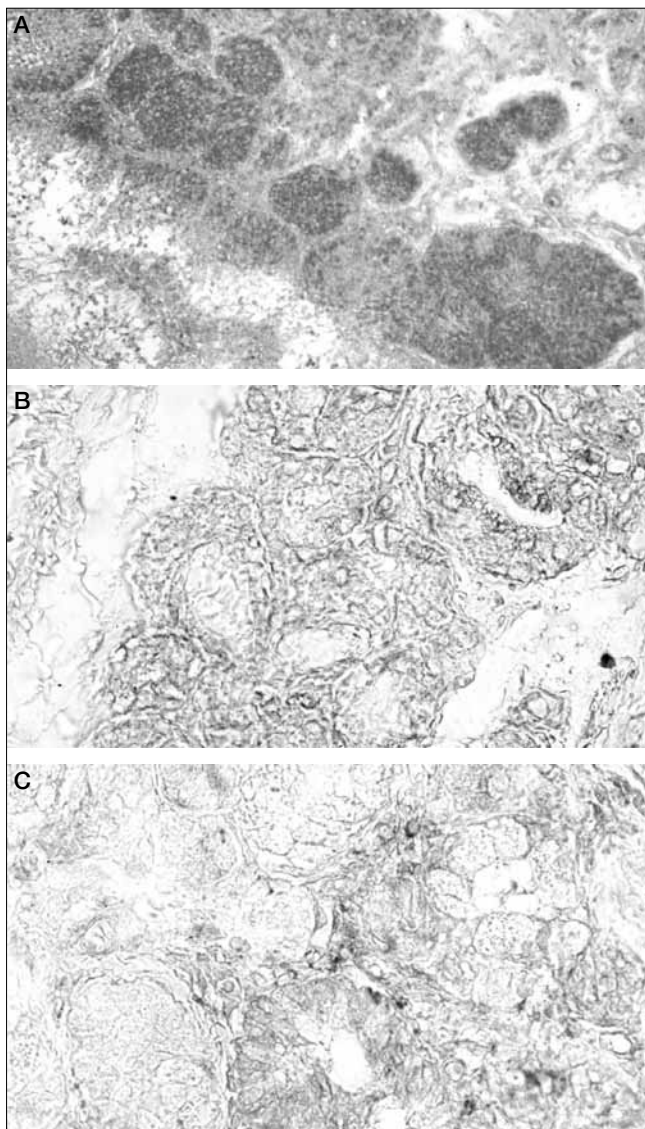


Fig. 1. **A:** High leptin immunoreactivity in solid nests of tumour cells infiltrating underlying connective structures (x10); **B:** lack of leptin immunoreactivity in glandular epithelium (x40); **C:** low leptin expression in normal laryngeal mucosa (x40).

stage ($\rho = 0.39$; $p = 0.055$), while no significant correlation with N isolated stage was seen ($\rho = 0.19$; $p = 0.35$).

Analysing the complete disease stage, there were no statistical differences between patients with high expression of leptin in advanced stage (70%) and those with high expression in early stage (50%) ($p = 0.47$). Spearman's rank correlation test did not show any significant correlation between leptin and stage ($\rho = 0$; $p = 1$).

Leptin and grading

In the advanced grade group (G2-G3), 14 (70%) patients shown high expression of leptin without significant relation with grading ($p = 0.47$). Spearman's rank correlation test showed a statistical trend between leptin expression and grading ($\rho = 0.4$; $p = 0.055$).

Leptin and tumour recurrence

The eight cases that developed recurrence were all associated with high immunoreactivity for leptin ($p = 0.017$). In particular, the Log-rank test showed a significant relation between high levels of leptin and risk of recurrence ($p = 0.0322$) (Fig. 2).

Spearman's rank correlation test showed significant correlation between leptin expression and recurrence ($\rho = 0.59$; $p = 0.002$).

Multivariate logistic regression analysis showed the following results (Table III): recurrence of malignancy was significantly related to leptin expression (odds ratio [OR] = 4.41; $p = 0.0003$; 95% confidence interval [CI] 1.68-4.75), to pN+ (OR = 3.73; $p = 0.001$; 95%CI 0.58 - 4.09) and to HG (OR = 2.95; $p = 0.008$; 95% CI 0.56-3.33).

Discussion

To the best of our knowledge, leptin expression in the head and neck cancers has been poorly investigated and there are no studies with which to compare our results. The few references concern salivary gland tumours. In particular, Schapher et al.³⁰ found that leptin was expressed in much higher amounts in human salivary gland tumours than in healthy tissues and hypothesised that the analysis of leptin concentrations in saliva samples might be used as a diagnostic marker to identify these tumours.

For the first time, we demonstrated the immunohistochemical expression of leptin in laryngeal SCC and its possible role in malignant recurrence.

Our results highlighted the expression of leptin and showed a statistically significant difference with control tissues (Table II). In consideration of this result, we focused on the relation between leptin expression and laryngeal SCC (TNM and grading).

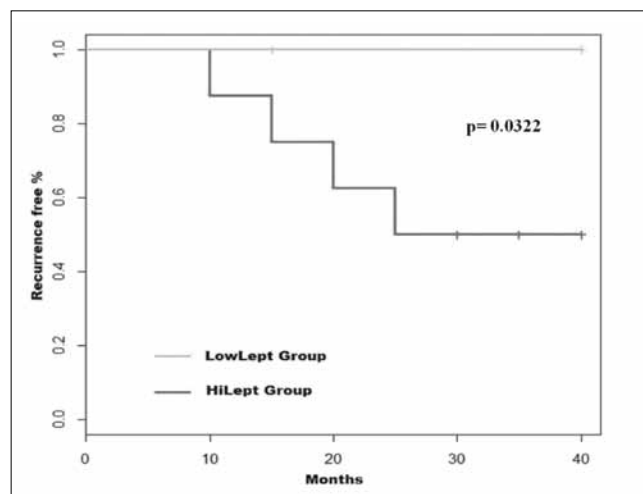


Fig. 2. Kaplan-Meier recurrence-free curves categorised by leptin expression (high versus low intensity). P values were estimated using the log-rank test.

Table III. Multivariate logistic regression analysis for loco-regional recurrences.

Parameter	Odds ratio	p value	95% Confidence interval
T	0.53	0.59	0.20-2.02
N	3.73	0.001	0.58-4.09
Stage	0.98	0.33	0.86-2.37
Histological grade	2.95	0.008	0.56-3.33
Leptin	4.41	0.0003	1.68-4.75

We first analysed variations in leptin as related to TNM and found no correlation considering the complete TNM staging. However, by studying individual clinicopathological features we obtained interesting results. Concerning T stage, we observed higher expression in cases of advanced tumour, although this did not reach statistical significance compared with early T stages. In our opinion, the lack of statistical significance could be explained by the small size of our sample. Considering categories N0 and N+, no significant differences in leptin expression were seen. Indeed, there appears to be slightly higher leptin expression in N0 tumours. These results on TNM and leptin expression could indicate a presence of leptin in primary tumours, not as a factor promoting lymph node metastasis, but as a growth factor mainly related to size and malignant degeneration of the tumour.

A similar result was also obtained investigating grading, where leptin expression, although not statistically significant, was increased in cases of advanced grade. Again, this statistical trend leads us to consider leptin as a growth factor involved in tumour growth.

In this regard, many authors have demonstrated a possible role for leptin. In particular, in physiological conditions it has been reported that proliferation of cells in salivary glands is reduced in the presence of leptin³¹. Goren et al.³² noted that *in vivo* leptin stimulates the proliferation of murine and human oral keratinocytes. It has also been proposed that leptin acts as a growth factor in epithelial cells colonic mucosa³³, in human and murine thacheo-bronchial cells³⁴ and in cultured preadipocyte cells³⁵. Martin-Romero et al. showed that human leptin stimulates the production of IL-2 and IFN-gamma, stimulating murine peritoneal macrophages and human monocytes as well as T lymphocytes³⁶. Finally, Wolf et al. reported that the infusion of recombinant leptin stimulates the expression of TGF-beta 1 in cultures of glomerular endothelial cells, and therefore leptin could be a growth factor for renal endothelial cells³⁷.

In pathological conditions, leptin and its receptor have been identified in malignant cells of diverse origins, including lung and gastric carcinomas and leukaemic cells, and the expression of leptin in pituitary adenomas has been correlated to greater tumour invasiveness^{38,39}.

In addition, an autocrine function of leptin has been hypothesised because it promotes the increase of its expres-

sion through self-stimulation and increases the expression of its own receptor⁴⁰. Unfortunately, this autocrine pathway has not been demonstrated in laryngeal SSC, but our study suggests that this is likely, also because Kowalczyk et al. have shown that expression of leptin in samples of laryngeal SCC is not related to serum leptin concentrations, and for this reason it is considered a possible paracrine product of the cancer, and not a product of other tissues⁴¹.

During follow-up, 8 patients developed loco-regional recurrence, which was significantly associated with high expression of leptin ($p = 0.017$) compared to tumours with low expression (Log-rank test, $p < 0.05$). Moreover, Spearman's rank correlation test also showed a statistically significant result ($r = 0.59$; $p = 0.002$) demonstrating that, in all cases of recurrence, the primary tumour had high expression of leptin.

In fact, Kaplan-Meier curves have shown a significant presence of recurrences in cases with high expression of leptin. This could be explained by the fact that leptin is probably expressed in advanced stages of cancer, where we found a statistical trend, playing a key role in spreading and survival of tumour cells. We also observed high focal expression of leptin in solid nests of tumour cells infiltrating the underlying connective.

For this reason, we believe that leptin may be a useful histological marker for predicting recurrence of malignancy. The results of our immunohistochemical study and literature data, supporting the involvement of leptin in other neoplastic diseases, lead us to believe that this neuropeptide may play a role in tumorigenesis and increase the risk of recurrence, and therefore could become an important cancer biomarker in the larynx.

Conclusions

Although this study has several weaknesses such as different treatments in a small cohort inhomogeneous for stage, our preliminary results suggest that leptin in primary laryngeal SCCs may be a valuable parameter for predicting patients at increased risk of recurrence after treatment. This evidence may be potentially relevant for implementation of closer follow-up protocols, to establish alternative therapeutic regimens in patients with high expression of leptin in laryngeal SCC and to use this peptide as a cancer marker.

Acknowledgements

The authors have no acknowledgements or financial support to declare.

References

- 1 Scharrer E, Scharrer B. *Hormones produced by neurosecretory cells*. Recent Prog Horm Res 1954;10:193-240.
- 2 Martini L. *Recent advances in the study of the Hypothalamic Releasing Factors*. In: Knowels F, Vollrath L, editors. *Neurosecretion The Final Neuroendocrine Pathway*. Berlin: Springer-Verlag; 1974. p. 135-47.
- 3 Tessitore V. *Il neurone monoaminergico e il neurone peptidergico*. Ital J Anat Embryol 1978;83:25-101.
- 4 Pearse AG. *Common cytochemical properties of cells producing polypeptide hormones, with particular reference to calcitonin and the thyroid C cells*. Vet Rec 1966;79:587-90.
- 5 Bloom SR, Polak JM. *Gut hormone overview*. In: Bloom SR, editor. *Gut Hormones*. London: Churchill and Livingstone; 1978. p. 3-18.
- 6 Le Douarin NM. *The embryological origin of the endocrine cells associated with the digestive tract*. In: Bloom SR, editor. *Gut Hormones*. London: Churchill and Livingstone; 1978. p. 49-56.
- 7 Evsukova EV. *APUD cells. The human pulmonary neuroendocrine system*. Fiziol Cheloveka 2006;32:121-30.
- 8 Lindheim SR, Sauer MV, Carmina E, et al. *Circulating leptin levels during ovulation induction: relation to adiposity and ovarian morphology*. Fertil Steril 2000;73:493-8.
- 9 Pearse AGE, Polak JM. *The diffuse neuroendocrine system and the APUD concept*. In: Bloom SR, editor. *Gut Hormones*. London: Churchill and Livingstone; 1978. p. 33-9.
- 10 Cinti S, Frederich RC, Zingaretti MC, et al. *Immunohistochemical localization of leptin and uncoupling protein in white and brown adipose tissue*. Endocrinology 1997;138:797-804.
- 11 Collins S, Kuhn C, Petro AE, et al. *Role of leptin in fat regulation*. Nature 1996;380:677.
- 12 Dagogo-Jack S, Fanelli C, Paramore D, et al. *Plasma leptin and insulin relationship in obese and nonobese humans*. Diabetes 1996;45:695-8.
- 13 Malik KF, Young WS 3rd. *Localization of binding sites in the central nervous system for leptin (OB protein) in normal, obese (ob/ob), and diabetic (db/db) C57BL/6J mice*. Endocrinology 1996;137:1497-500.
- 14 Cinti S, De Matteis R, Picó C, et al. *Secretory granules of endocrine and chief cells of human stomach mucosa contain leptin*. Int J Obes Relat Metab Disord 2000;24:789-93.
- 15 Bonaventura G, Cucco D, Leone A, et al. *The role of new neurocrine and neuroendocrine messengers on the regulation of the function of major salivary glands in some mammals. An immunohistochemical study*. Ital J Anat Embryol 2008;113:40.
- 16 Gröschl M, Topf HG, Kratzsch J, et al. *Salivary leptin induces increased expression of growth factors in oral keratinocytes*. J Mol Endocrinol 2005;34:353-66.
- 17 Bohlender J, Rauh M, Zenk J, et al. *Differential distribution and expression of leptin and the functional leptin receptor in major salivary glands of humans*. J Endocrinol 2003;178:217-23.
- 18 Leone A, Spatola GF, Cucco D, et al. *Immunohistochemical expression and distribution of orexin, orphanin and leptin in the major salivary glands of some mammals*. Folia Histochem Cytobiol 2012;50:504-12.
- 19 De Matteis R, Puxeddu R, Riva A, et al. *Intralobular ducts of human major salivary glands contain leptin and its receptor*. J Anat 2002;201:363-70.
- 20 Hoggard N, Hunter L, Duncan JS, et al. *Leptin and leptin receptor mRNA and protein expression in the murine fetus and placenta*. Proc Natl Acad Sci USA 1997;94:11073-8.
- 21 Smith-Kirwin SM, O'Connor DM, De Johnston J, et al. *Leptin expression in human mammary epithelial cells and breast milk*. J Clin Endocrinol Metab 1998;83:1810-3.
- 22 Bonaventura G, Cucco D, Spatola GF, et al. *Leptin immunohistochemical expression in rat respiratory system*. In: Gerbino A, Zummo G, Cresciamanno G, editors. *Experimental Medicine Reviews*. Vol. 2/3. Palermo: Plumelia; 2009. p. 57.
- 23 Frankenberry KA, Skinner H, Somasundar P, et al. *Leptin receptor expression and cell signaling in breast cancer*. Int J Oncol 2006;28:985-93.
- 24 Cascio S, Bartella V, Auriemma A, et al. *Mechanism of leptin expression in breast cancer cells: role of hypoxia inducible factor-1alpha*. Oncogene 2008;27:540-7.
- 25 Chia VM, Newcomb PA, Lampe JW, et al. *Leptin concentrations, leptin receptor polymorphisms, and colorectal adenoma risk*. Cancer Epidemiol Biomarkers Prev 2007;16:2697-703.
- 26 Cooper JS, Porter K, Mallin K, et al. *National Cancer Database report on cancer of the head and neck: 10-year update*. Head Neck;31:748-58.
- 27 Barnes L, Tse LY, Hunt JL, et al. *Tumours of the hypopharynx, larynx and trachea: introduction*. In: Barnes L, Eveson J, Reichart P, et al., editors. *World Health Organization Classification of Tumours. Pathology and Genetics of Head and Neck Tumours*. Lyon: IARC Press; 2005. p. 111-17.
- 28 Forastiere A, Koch W, Trotti A, et al. *Head-and-neck cancer*. N Engl J Med 2001;345:1890-900.
- 29 Società Italiana di Otorinolaringoiatria e Chirurgia Cervico-Facciale (SIOeChC-F). *Linee guida sul "Cancro della Laringe"*. Argomenti Acta Otorhinolaryngol Ital 2008;II:33-49.
- 30 Schapher M, Wendler O, Gröschl M, et al. *Salivary leptin as a candidate diagnostic marker in salivary gland tumors*. Clin Chem 2009;55:914-22.
- 31 Higa M, Shimabukuro M, Fukuchi M, et al. *Atrophic change of rat salivary gland during adenovirus-induced hyperleptinemia*. Biochem Biophys Res Commun 2002;291:675-9.
- 32 Goren I, Pfeilchifter J, Frank S. *Determination of leptin signalling pathways in human and murine keratinocytes*. Biochem Biophys Res Commun 2003;303:1080-5.
- 33 Hardwick JC, Van Den Brink GR, Offerhaus GJ, et al. *Leptin is a growth factor for colonic epithelial cells*. Gastroenterology 2001;121:79-90.
- 34 Tsuchiya T, Shimizu H, Hori T, et al. *Expression of leptin receptor in lung: leptin as a growth factor*. Eur J Pharmacol 1999;365:273-9.

- ³⁵ Zwirska-Korczala K, Adamczyk-Sowa M, Sowa P, et al. *Role of leptin, ghrelin, angiotensin II and orexins in 3T3 L1 preadipocyte cells proliferation and oxidative metabolism.* J Physiol Pharmacol 2007;58(Suppl 1):53-64.
- ³⁶ Martin-Romero C, Santos- Alvarez J, Goberna R, et al. *Human leptin enhances activation and proliferation of human circulating T lymphocytes.* Cell Immunol 2000;199:15-24.
- ³⁷ Wolf G, Hamann A, Han DC, et al. *Leptin stimulates proliferation and TGF-beta expression in renal glomerular endothelial cells: potential role in glomerulosclerosis (secoments).* Kidney Int 1999;56:860-72.
- ³⁸ Mix H, Widjaja A, Jandl O, et al. *Expression of leptin receptor isoforms in the human stomach.* Gut 2000;47:481-6.
- ³⁹ Hino M, Nakano T, Yamane T, et al. *Leptin receptor and leukemia.* Leuk Lymphoma 2000;36:457-61.
- ⁴⁰ Chen C, Chang YC, Liu CL, et al. *Leptin-induced growth of human ZR-75-1 breast cancer cells is associated with up-regulation of cyclin D1 and c-Myc and down-regulation of tumor suppressor p53 and p21WAF1/CIP1.* Breast Cancer Res Treat 2006;98:121-32.
- ⁴¹ Kowalczyk A, Wiecek A, Franek E, et al. *[Plasma concentration of leptin, neuropeptide Y and tumor necrosis factor alpha in patients with cancers, before and after radio- and chemotherapy].* Pol Arch Med Wewn 2001;106:657-68.

Received: December 21, 2013 - Accepted: April 29, 2014