

# Laparotomic vs laparoscopic ovariectomy: comparing the two methods. The ovariectomy in the bitch in laparoscopic era

Giovanni Cassata<sup>1,2</sup>, Vincenzo Davide Palumbo<sup>2,4</sup>, Luca Cicero<sup>1</sup>, Giuseppe Damiano<sup>2</sup>, Antonio Maenza<sup>1</sup>, Aldo Migliazzo<sup>1</sup>, Giocchino Di Paola<sup>3</sup>, Domenico Vicari<sup>1</sup>, Salvatore Fazzotta<sup>2</sup>, Attilio Ignazio Lo Monte<sup>2</sup>

<sup>1</sup>Istituto Zooprofilattico Sperimentale della Sicilia "A. Mirri", Palermo, Italia; <sup>2</sup>Dipartimento di Discipline Chirurgiche, Oncologiche e Stomatologiche, Università degli Studi di Palermo, Italia; <sup>3</sup>Dipartimento di Scienze Statistiche e Matematiche, Università degli Studi di Palermo, Italia; <sup>4</sup>Istituto Euromediterraneo di Scienza e Tecnologia (IEMEST), Palermo, Italia

**Summary.** *Background and aim:* The aim of the present work is to evaluate the effectiveness of the use of ultrasound scalpel during laparoscopic ovariectomy in the bitch. *Methods:* Two groups of 10 subjects each, of different races and ages, were compared. In the first group, ovariectomy was performed laparoscopically, using harmonic scalpel to remove ovary. In the second group surgery was performed by means of classical laparotomy. *Results:* Pre-operative time was similar in both groups. Total operative time, from incision to skin suture, showed significant difference between the two groups, being laparoscopy faster than laparotomy. Partial operative time for bilateral oophorectomy resulted lower using open technique, but, considering each ovary, there was no significant difference in both groups. *Conclusions:* The use of harmonic scalpel to perform ovariectomy during laparoscopy is an effective time-sparing surgical approach compared to the already great practicality of laparotomy. ([www.actabiomedica.it](http://www.actabiomedica.it))

**Key words:** oophorectomy, laparotomy, laparoscopy, harmonic scalpel

## Introduction

Preventive ovariectomy (OVE) is the most common surgical operation performed in veterinary medicine, because it represents the preferred method for the suppression of heats and the control of births, apart from being the solution for diminishing the incidence of uterus infections, mammary neoplasms, cysts and placental trauma (1).

In Europe and Italy, OVE is usually preferred to the most invading ovariohysterectomy, because the decrease in hormonal production that follows, leads to a uterine involution. In those conditions the risks of uterine diseases are very low (1).

The OVE is a minimally invasive surgical procedure commonly used for the sterilization of fe-

male dogs. In the last decade the laparoscopic OVE (LapOVE) has been considered a valid alternative to conventional surgery (2).

The advantages that it offers are:

- short size abdominal incisions (3-5 mm);
- "magnification" of abdominal structures and a better visualization of abdominal organs;
- a more accurate, specific and delicate manipulation of organs;
- a reduction in post-operative pain and post-surgical adhesions;
- a shorter convalescence and a faster recovery;
- using appropriate surgical equipment, surgery may be performed in very short surgical time.

Once the abdomen is insufflated with carbon dioxide, a micro-camera (laparoscope) is inserted

through an inlet of 5-10 mm in length, in order to identify ovaries.

In the same way, other two trocars are placed in the midline, through which a grasping forceps and an ultrasonic or laser instrument are inserted; this allows the surgeon to localize ovaries easily and, at the same time, guarantees an optimal visualization of organs and an effective control of bleeding.

Ovaries are then removed from the abdomen. Surgical incision are closed usually by means of a biological glue or absorbable sutures. This technique does not require large incisions of the abdomen and minimizes tissue manipulation, resulting in a lower post-operative pain, a lower recovery time and an excellent aesthetic profile (2).

The use of an ultrasonic scalpel has brought many advantages to the surgeon. Ultrasounds produce the clinical effects of cavitation, protein fusion, coagulation and cutting (3). Harmonic scalpel is a cutting, hemostasis and dissection system, that acts at the resonance frequency of 55.5 KHz. The more power is selected, the higher is the cutting speed; the lower is the power to the generator, the greater is the capacity of hemostasis (4).

## Materials and methods

For the study, twenty dogs were divided into two groups. Animal of both groups were ovariectomized, laparoscopically in the first group (group A), and with standard laparotomy in the second one (group B). Group A included dogs weighing from 16 to 21 Kg, aged 8-16 months. In group B were included dogs weighing from 15 to 18 kg, aged 9-16 months. All animals were examined to assess their health status and establish the American Society of Anaesthesiology (ASA) score. In the two groups ASA ranged between I and III. Preoperatively, subjects were premedicated with medetomidine (10 µg/kg intravenously), tramadol (3 mg/kg intravenously) and robenacoxib (2 mg/kg subcutaneously). Propofol 2 mg/Kg iv was administered to induct the anaesthesia, whereas the maintenance was performed with isoflurane (5). All animals were submitted to abdominal trichotomy and the skin disinfected with chlorhexidine. A deep jugular vein

**Table 1.** Group A features (race, age and weight)

Group A – Laparoscopy			
Cases	Race	Age (Months)	Weight (Kg)
Case 1	Beagle	16	16
Case 2	Crossbreed	17	18
Case 3	Crossbreed	9	17
Case 4	English Cocker Spaniel	12	18
Case 5	Crossbreed	13	16
Case 6	Labrador Retriever	8	29
Case 7	Crossbreed	14	21
Case 8	American Pit Bull Terrier	13	18
Case 9	German shepherd	8	25
Case 10	Segugio Italiano	9	20

**Table 2.** Group B features (race, age and weight)

Group B – Laparotomy			
Cases	Race	Age (Months)	Weight (Kg)
Case 1	Crossbreed	9	15
Case 2	Crossbreed	10	17
Case 3	Crossbreed	9	18
Case 4	Irish Setter	13	19
Case 5	Cirneco dell'Etna	17	16
Case 6	Beagle	16	20
Case 7	Labrador Retriever	9	30
Case 8	Crossbreed	10	14
Case 9	Beagle	13	18
Case 10	American Pit Bull Terrier	11	17

was cannulated surgically (6). A xyphopubic median incision was performed; once the right ovary was isolated, the ovarian ligament and the caudal pole of the ovary, including the fallopian tube, were ligated. Both ligatures were performed with a braided absorbable 0 wire. Ovariectomy was continued dissecting the connective tissue of the ovary and severing the vascular structures between the two ligature previously affixed. The same technique was used for the left ovary.

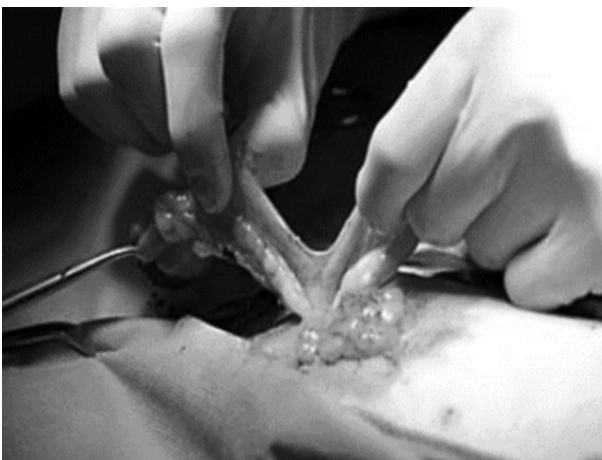The breach was then sutured: first, the fascia was sutured in a continuous fashion, using an absorbable braided 0 wire; the subcutaneous tissue was closed applying a simple continuous suture with an absorbable braided 2-0 wire; finally, an intradermal suture was performed with an absorbable braided 2-0 wire. Surgical time, from skin incision to skin closure, was monitored. The time of removal of each ovary was also

recorded: for group A, time was calculated from the first incision with harmonic scalpel; for group B, recording started once first ligature was applied. Time was recorded in seconds. During intervention, some vital parameters, such as blood pressure, oxygen partial pressure, carbon dioxide volume in the exhaled and the cardiac rhythm, were evaluated. The one-way variance analysis was performed using ANOVA system, followed by Tukey's test in case of significant difference ( $p < 0.05$ ) between groups. The evaluation between the two groups for each time was made using the t-student test for unpaired data, considering a  $p < 0.05$  as statistically significant. The software used was R 3.02

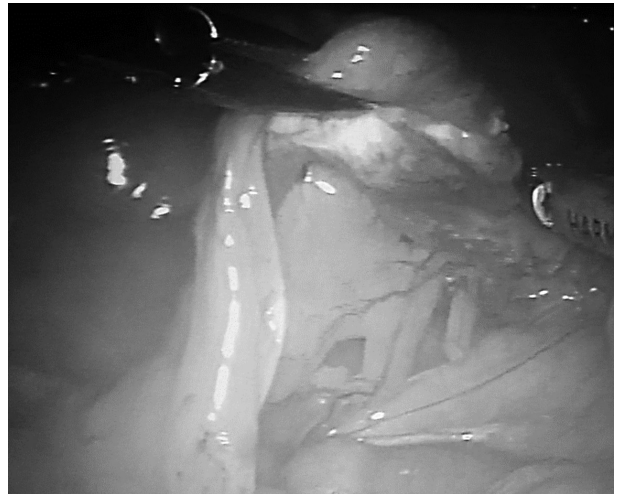
## Results

All subjects enrolled for the study showed neither surgical complications or side effects due to anaesthesia (7). The time elapsed from premedication to skin incision was 965.05 s, in both groups. The time of removal for both ovaries in group A was 295.8 s (95% confidence interval: 265.5-326.1), whereas in group B it was 179 (95% confidence interval: 161.5-196.5).

Total operative time was 1049.7 s (95% confidence interval: 1014.4-1085) for group A, whereas it was 1355.2 (95% confidence interval: 1298.8-1411.6) for group B. The time of removal was 40% higher in group A than group B, with a  $p$  value  $< 0.001$  (Fig. 1).



**Figure 1.** Standard open ovariectomy in the bitch. Ovaries, uterine horns and cervix are in evidence

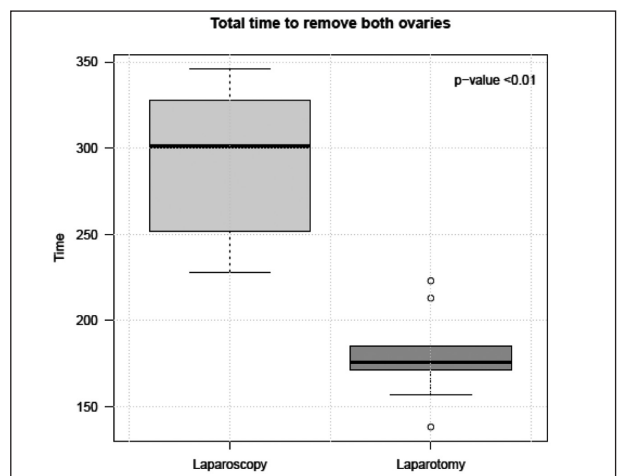


**Figure 2.** Laparoscopic ovariectomy. In the picture, a minimally invasive surgical procedure is shown, to sterilize a bitch. Uterine horns and the ovarian bursa are in evidence

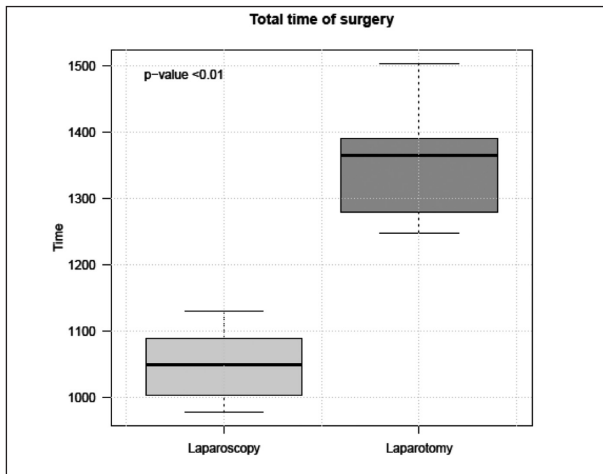
In graph 2 total operative time between the two groups is statistically compared. In this case, group A showed values 27% lower than group B ( $p < 0.001$ ).

## Discussion

The aim of this study was to evaluate the effectiveness of laparoscopic ovariectomy in the bitch. The use of harmonic scalpel brought many advantages, firstly the reduction of the operative time.



**Figure 3.** The graph analyses differences in term of total time for the removal of both ovaries between the two groups



**Figure 4.** The graph analyses differences in term of total operative time between the two groups

Ultrasonic scalpel allows using a single tool for grasping, cutting and coagulating; interestingly, there was no significant blood loss from severed vessels, making vascular ligatures unnecessary. Preoperative time was similar for both groups, and both techniques resulted effective and exempt from complications. However, surgical time was different between two groups: the time of ovary removal in group A was lower than in group B, and the overall operative time was significantly lower in laparoscopy group than in laparotomy group.

## Conclusions

Laparoscopy is a reliable and time-sparing approach for the ovariectomy in the bitch. Furthermore, the use of ultrasonic scalpel increases considerably the speed of performance, avoiding the use of other tools, such as laparoscopic scissors or ligatures. Laparoscopic ovariectomy reduces postoperative pain considering the small gaps used for the introduction of trocars. This

affect in a smaller manner the operative time, since laparotomy needs much more time to be performed. Also isolation of the ovaries is easier, because laparoscopy does not require blind search, as often happens in laparotomy. Furthermore, working with a closed abdomen a higher degree of sterility is expected.

## References

1. Noakes DE, Parkinson TJ, England GCW. Ovariectomy. In: Arthur's. *Ostetricia e Riproduzione Veterinaria* 8/ed. Giraldi Editore, Bologna, 2008.
2. Dupré G, Fiorbianco V, Skalicky M, Gultiken N, Serhat S, Findik M. Laparoscopic ovariectomy in dogs: comparison between single portal and two-portal access. *Vet Surg* 2009; 38: 818-24.
3. Barzan L, Antonio J, Santini S, et al. Submandibular approach and use of the harmonic instrument in lateral oral cavity and oropharyngeal oncologic surgery. *Acta Otorhinolaryngol Ital* 2010; 30: 277-80.
4. Tirelli G, Del Piero GC, Perrino F. Ultracision harmonic scalpel in oral and oropharyngeal cancer resection. *J Cranio-maxillofac Surg* 2014; 42(5): 544-7.
5. Bubalo V, Moens YP, Holzmann A, Coppens P. Anaesthetic sparing effect of local anaesthesia of the ovarian pedicle during ovariohysterectomy in dogs. *Vet Anaesth Analg* 2008; 35: 537-42.
6. Lombardo C, Damiano G, Cassata G, et al. Surgical vascular access in the porcine model for long-term repeated blood sampling. *Acta Biomed* 2010; 81: 101-3.
7. Reisner IR. Differential diagnosis and management of human-directed reactivity in dogs. *Vet Clin North Am Small Anim Pract* 2003; 33: 303-20.

Received: 4 December 2015

Accepted: 12 May 2016

Correspondance:

Dr. Vincenzo Davide Palumbo

Dipartimento di Discipline Chirurgiche, Oncologiche e Stomatologiche, Università degli Studi di Palermo, Italia

Tel. +39 091 6552666

Fax +39 091 6552666

E-mail: vincenzodavide.palumbo@unipa.it