

Shot-dead CT-virtopsy: our experience

Poster No.: C-0745
Congress: ECR 2016
Type: Educational Exhibit
Authors: S. Serraino¹, L. Scopelliti¹, D. Picone¹, F. Vernuccio¹, E. Murmura², F. Midiri¹, F. Li Pomi¹, S. Salerno¹, G. Lo Re¹;
¹Palermo/IT, ²Sciacca/IT
Keywords: Forensic / Necropsy studies, CT, Computer Applications-3D, Computer Applications-General, Computer Applications-Virtual imaging, Forensics
DOI: 10.1594/ecr2016/C-0745

Any information contained in this pdf file is automatically generated from digital material submitted to EPOS by third parties in the form of scientific presentations. References to any names, marks, products, or services of third parties or hypertext links to third-party sites or information are provided solely as a convenience to you and do not in any way constitute or imply ECR's endorsement, sponsorship or recommendation of the third party, information, product or service. ECR is not responsible for the content of these pages and does not make any representations regarding the content or accuracy of material in this file.

As per copyright regulations, any unauthorised use of the material or parts thereof as well as commercial reproduction or multiple distribution by any traditional or electronically based reproduction/publication method is strictly prohibited.

You agree to defend, indemnify, and hold ECR harmless from and against any and all claims, damages, costs, and expenses, including attorneys' fees, arising from or related to your use of these pages.

Please note: Links to movies, ppt slideshows and any other multimedia files are not available in the pdf version of presentations.

www.myESR.org

Learning objectives

1. To illustrate the potential of CT-virtopsy (CT-v) as a valid help in post-mortem evaluation in gunshot-dead people.
2. To explain as it can support, complete and, in some special cases, be a substitute of body-opening autopsy.
3. To stress its role in establishing cause of death, in dating the succession of lethal events occurred in the body and, possibly, in identifying the corpse.

Background

Basal CT-v is the most largely used non-invasive radiological technique, for both the rapidity of images acquisition and the possibility of editing images with MPR and 3D reconstruction of organs, body surface and bones.

It could be considered as an alternative or previous evaluation in gunshot-dead people before "body-opening" autopsy in forensic medicine and it can provide information about the cause of death by ordering, in terms of timing, the lethal findings.

Furthermore CT-v images can help in body recognition by studying the main general anatomic features of the body and even pathologic peculiar findings, whereas identifiable.

Findings and procedure details

We analyzed 18 patients between July 2010 and October 2015; because of legal reasons, we are not in possess of the age of each person; generally they could be placed in a young-middle age range. All of the bodies belonged to male individuals.

Each corpse was firstly brought to the Department of Forensic Science to be recognized, if possible, and recorded; in a second time it was carried to our Department of Radiology, hidden in an isolatig bag, by the responsible Coroner.

We positioned the corpse in our 128-slice CT-scan; then we programmed the scout scansion and generally performed a whole-body exam comprehending all of the body components; in one case only brain-Ct evaluation was performed, in agreement with the Coroner.

Exam data were usually standardized (Table.1) and sometimes more than one scout was required.

Images were obtained with a "soft tissue" window and then reformatted both in thinner slices with bone+ filtered protocol (lung and bone study), and through MPR and VR retro-reconstruction.

Each report consisted of evaluation of brain and neck structures, lungs and mediastinum, parenchymal abdominal organs, bones, soft subcutaneous tissues and the correspondent alteration; each pathological finding, or even anatomic variant, was described.

In each exam we were able to estimate:

- number and final placement of the bullets retained in the body; a total of 12 bullets were reported; this kind of information could be particularly useful as previous evaluation to body-opening autopsy, whereas the body manipulation by the Coroner could accidentally cause a repositioning of the bullet or of a sliver;
- entrance and exit wound, where present, and bullet trajectory through the body, by recognizing a number of indirect signs such as organ lesions and millimeter put in-a-row air-bubble;
- possible organic lesions due to the passage of the bullet, such as parenchymal lacerations, fistulas, adjacent blood loss, etc..;
- number and localization of bone fractures (a total of 49 bone fractures of different etiology have been reported), being able to recognize and distinguish between lesions linked to impact with the bullet, traumatic lesions secondary to "peri-mortem" corpse mistreatment or traumatic past-lesions;
- specific morphologic features such as anatomic variants, morphology of skull or teeth, useful in the event of an identification;
- further soft tissues modifications linked to other death-related events, such as disarticulation or burning.

Images for this section:

Ward: 39-
 Physician:
 Operator:

Total mAs 8976 Total DLP 1987 mGycm

	Scan	kV	mAs / ref.	CTDIvol* mGy	DLP mGycm	TI s	cSL mm
Patient Position F-SP							
Topogramma	1	120	35 mA	0.29 S	46	16.1	0.6
Topogramma	2	120	35 mA	0.29 S	30	10.4	0.6
Topogramma	3	120	35 mA	0.29 S	57	19.9	0.6
Addome basale	4	120	163 / 200	11.01 L	1854	0.5	0.6

Table 1: Our CT-v standard protocol data.

© - Palermo/IT

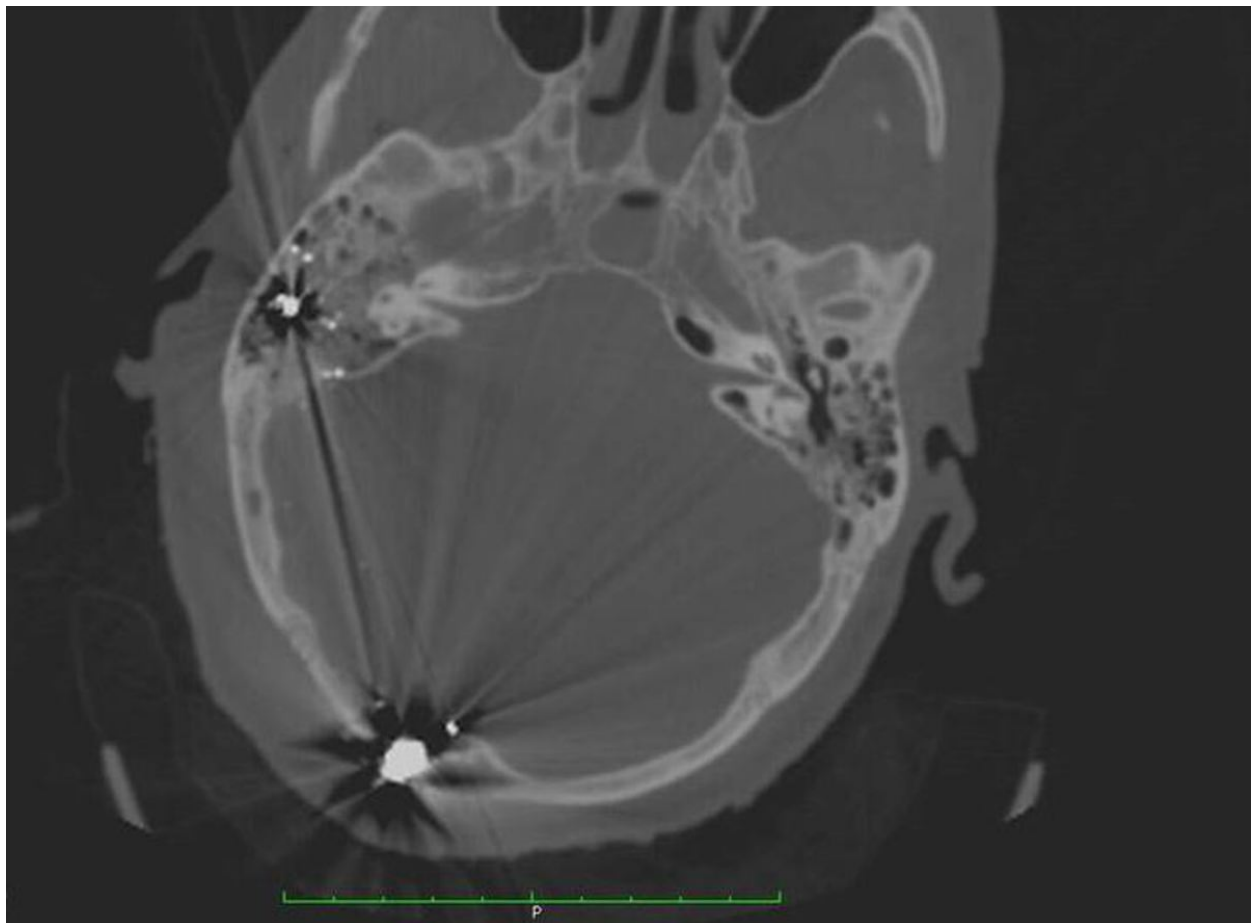


Fig. 1: Bullet in posterior cranial fossa, strictly adjacent to occipital bone, fractured; a small fragment can also be seen into mastoid. Bullet is seen as a hyper-attenuating structure surrounded by beam-hardening artifacts due to its material.

© - Palermo/IT

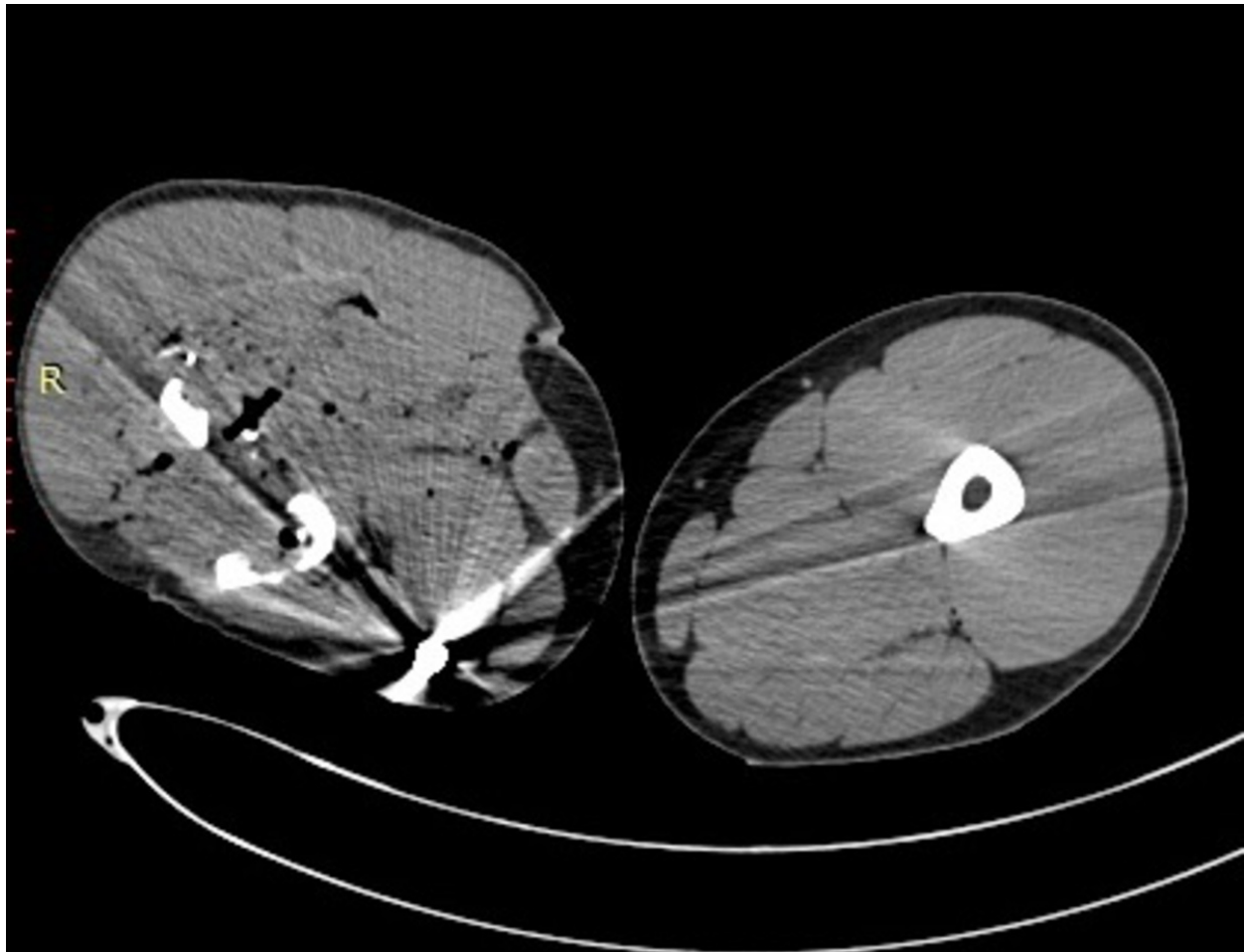


Fig. 2: Compound femur fracture with multiple bone fragments and the bullet on the medial soft tissues of the leg, that appears larger than contralateral, because of blood and fat bone-marrow spreading.

© - Palermo/IT

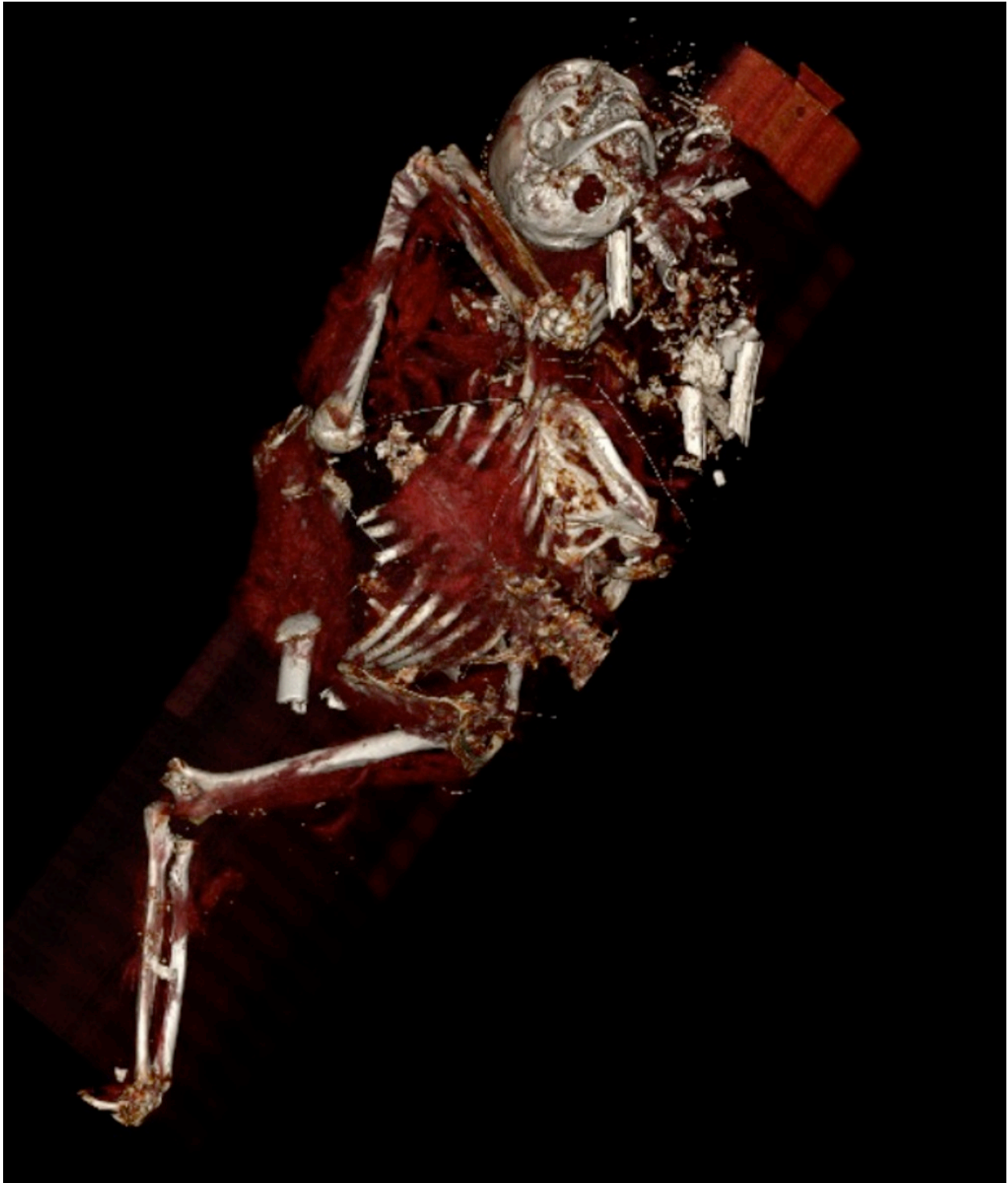

Fig. 3: Disarticulated corpse reformatted in VR with bone stressing in a gunshot individual, who was burnt after killing; numerous bone fragments can be recognized anomalously positioned, with shreds of body tissue still attached.

© - Palermo/IT

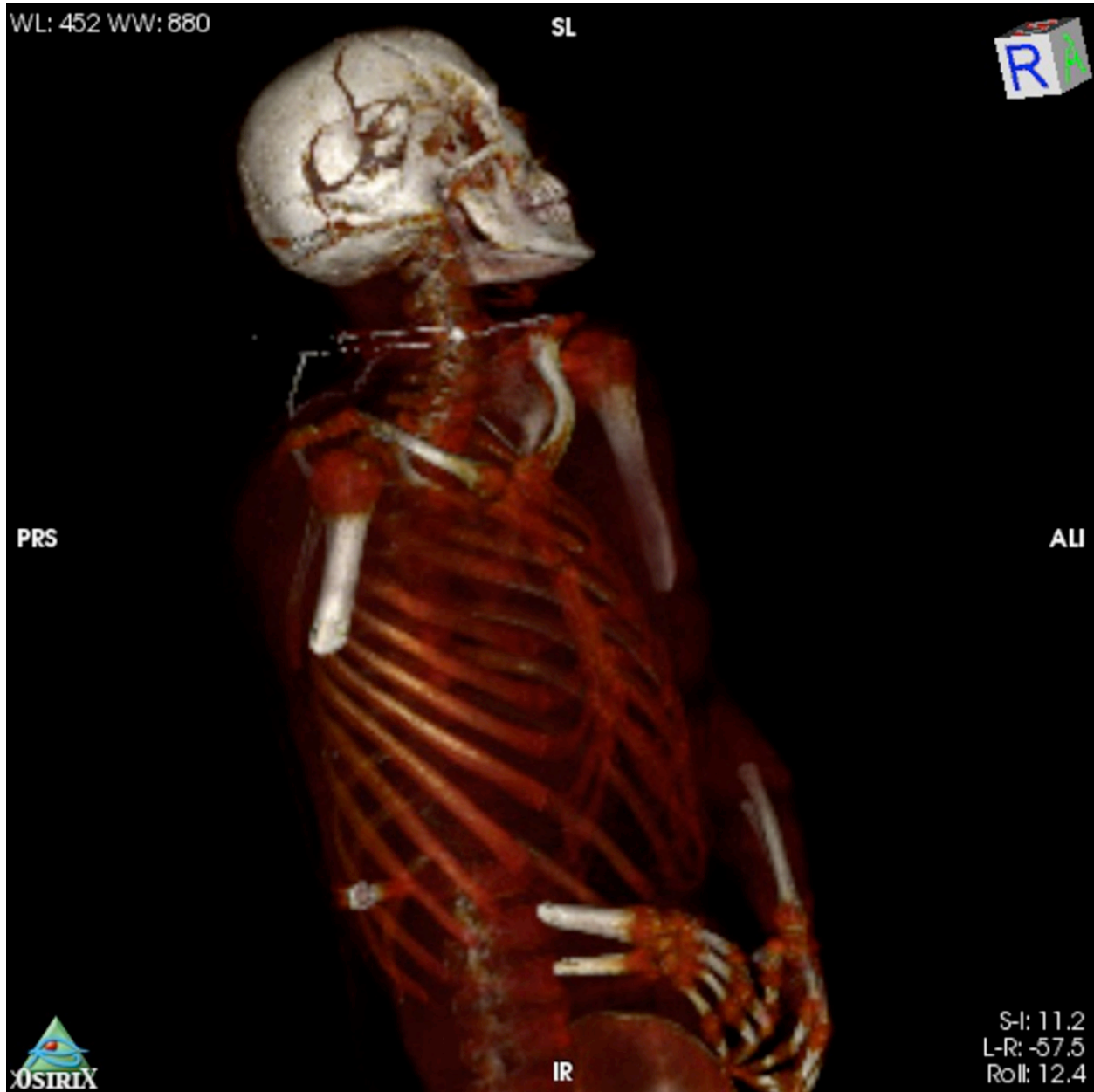

Fig. 5: 3d VR

© - Palermo/IT

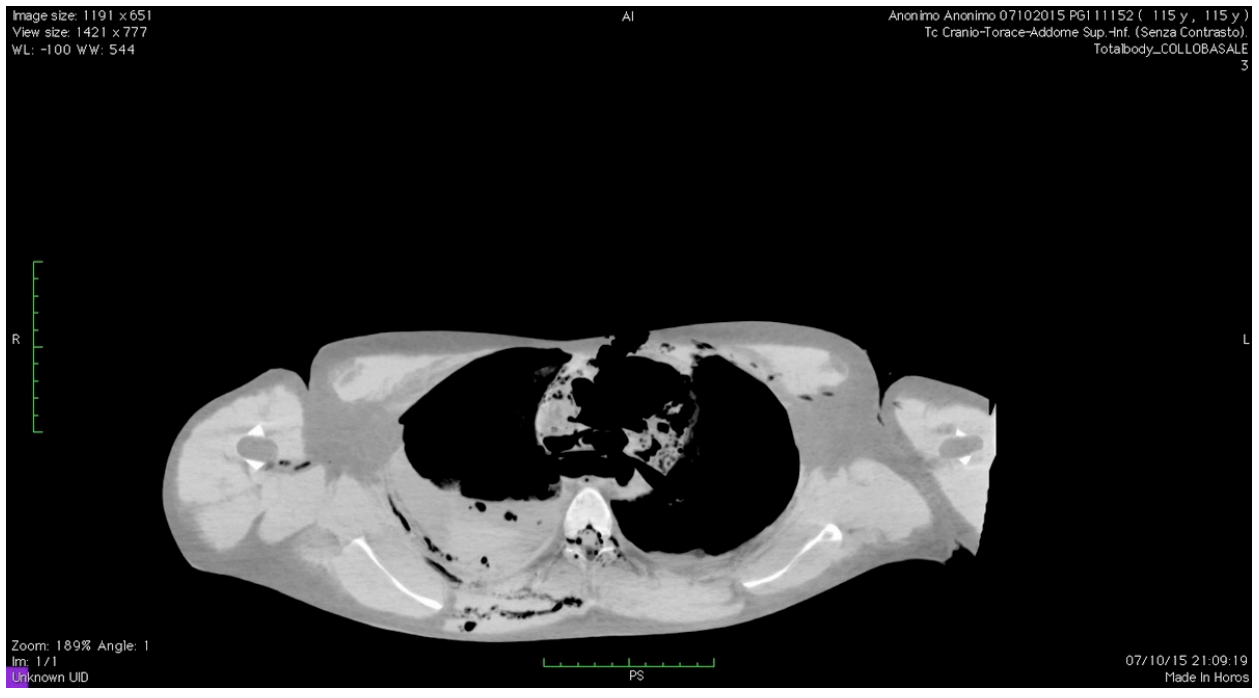
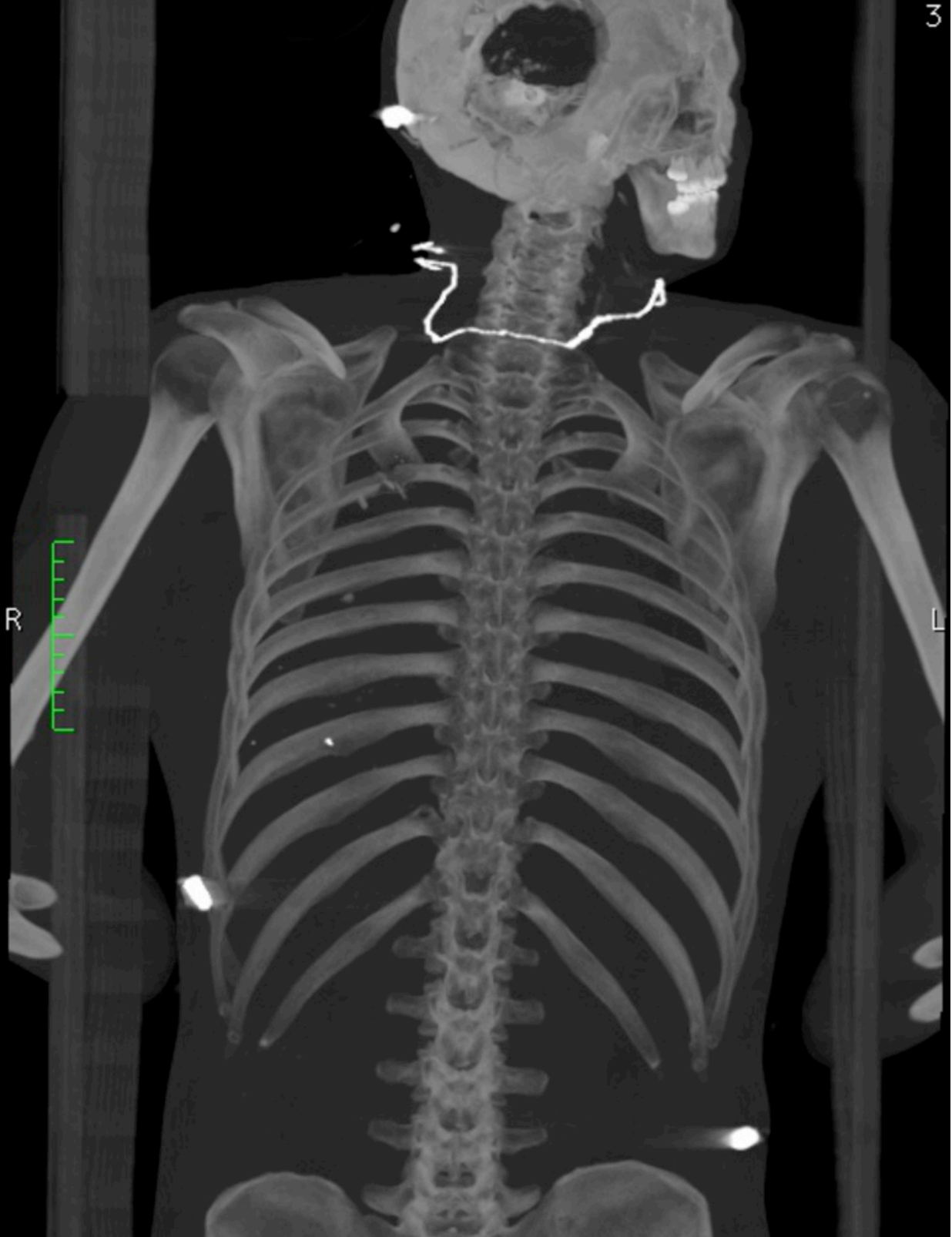


Fig. 6: CT Axial MIP reconstruction of bullet trajectory through the chest

© - Palermo/IT

Image size: 512 x 768
View size: 485 x 768
WL: 1316 WW: 3236
Totalbody_COLLOBASALE
3



Zoom: 92% Angle: 0
Im: 236-363/512 (A → P)
Unknown UID
Thickness: 125.00 mm Location: -102.51 mm
07/10/15 21:09:39
Made In Horos

Fig. 4: MIP coronal reconstruction of whole body with bullets

© - Palermo/IT

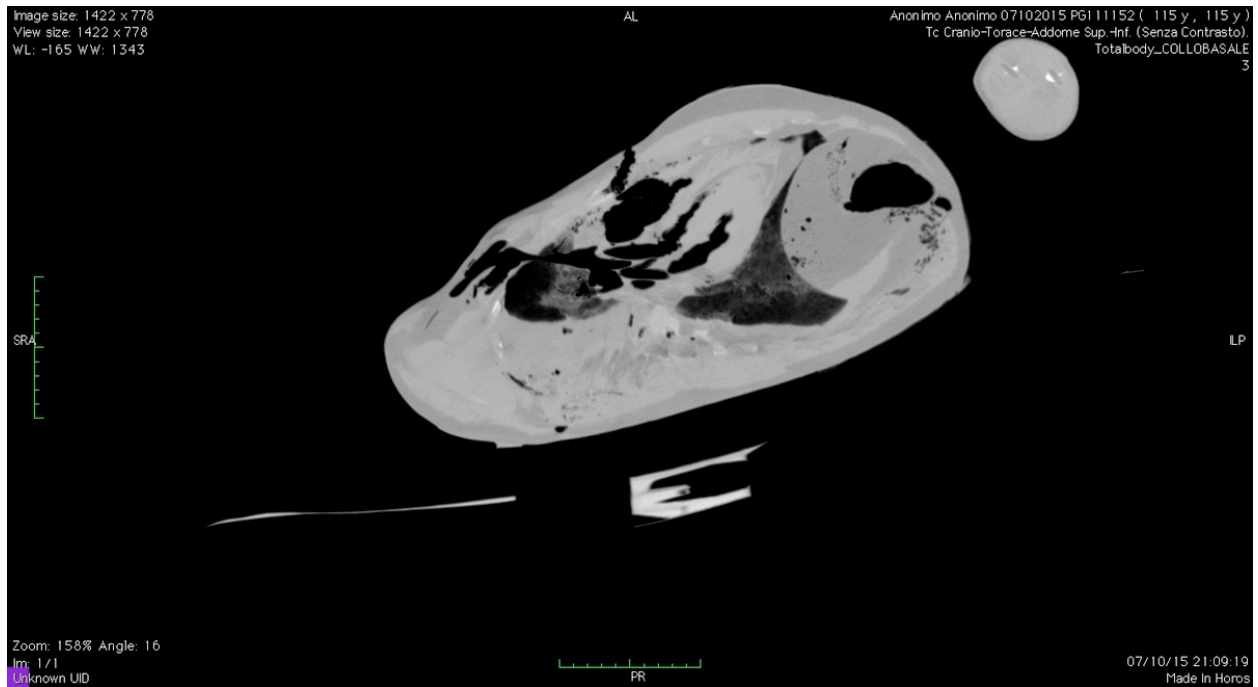


Fig. 7: CT oblique MIP reconstruction of bullet trajectory through the chest

© - Palermo/IT

Conclusion

CT-v is a fast, investigator independent, objective and non-invasive technique. It should be performed as most rapidly as possible after death, so as to provide very useful details regarding the cause of the death and the presence of other pathologic/potentially lethal findings, but also to describe in the most detailed way important anatomic and physiologic information, in order to help in identification of the body.

It is really thought to lead to qualitative improvements in forensic pathologic investigation, in association to body-opening autopsy, with an optimal accuracy and in short time.

Personal information

Salvatore Serraino, salvatoreserraino@hotmail.it

Giuseppe Lo Re, giuseppe.lore12@gmail.com

Laura Scopelliti, laura.scopelliti@gmail.com

Dario Picone, dariopicone@hotmail.it

Federica Vernuccio, federicavernuccio@gmail.com

Elena Murmura, elenamurmura@hotmail.com

Sergio Salerno, sergio.salerno@unipa.it

References

1. Black, S., & Ferguson, E. Forensic anthropology 2000 to 2010. Boca Raton: Taylor and Francis Group, LLC; 2011.
2. Bolliger SA, Thali MJ, Ross S, Buck U, Naether S, Vock P. Virtual autopsy using imaging: bridging radiologic and forensic sciences. A review of the Virtopsy and similar projects. Eur Radiol. 2008;18:273-82.

3. Brogdon BG, editor. Forensic radiology. 1st edn. Boca Raton: CRC Press; 1998.
4. Christe A, Flach P, Ross S, Spendlove D, Bolliger S, Vock P, Thali MJ. Clinical radiology and postmortem imaging (Virtopsy) are not the same: Specific and unspecific postmortem signs. *Leg Med* . 2010;12:215-22.
5. Cox, J. and Kirkpatrick, R. C., The new photography with report of a case in which a bullet was photographed in the leg, *Montreal Med. J.* , 24, 661, 1896.
6. Dirnhofer R, Jackowski C, Vock P, Potter K, Thali MJ. VIRTOPSY: minimally invasive, imaging-guided virtual autopsy. *Radiographics*. 2006;26:1305-33.
7. Hassel B, Farman AG. Skeletal maturation evaluation using cervical vertebrae. *Am J Orthod Dentofacial Orthop*. 1995;107:58-66.
8. Hollerman JJ1, Fackler ML, Coldwell DM, Ben-Menachem Y. Gunshot wounds: 2. *Radiology. AJR Am J Roentgenol*. 1990;155:691-702.
9. Krogman, W. M. and Iscan, M.Y., *The Human Skeleton in Forensic Medicine*, 2nd ed., Charles C Thomas, Springfield, IL, 1986.
10. Kurihara, Y., Kurihara, Y., Ohashi, K., Kitagawa, A., Miyasaki, M., Okamoto, E., and Ishikawa, T., Radiologic evidence of sex differences: is the patient a woman or a man? *AJR Am J Roentgenol*. 1996;167:1037-40.
11. Kvaal, S.I., Kolltveit, K.M., Thomsen, I.O., Solheim, T., Age estimation of adults from dental radiographs, *Forensic Science International* 1995;74:175-85.
12. Navsaria PH, Nicol AJ, Edu S, Gandhi R, Ball CG. Selective Nonoperative Management in 1106 Patients With Abdominal Gunshot Wounds: Conclusions on Safety, Efficacy, and the Role of Selective CT Imaging in a Prospective Single-Center Study. *Ann Surg*. 2014 Sep 1. [Epub ahead of print]
13. Thali MJ, Jackowski C, Oesterhelweg L, Ross SG, Dirnhofer R. VIRTOPSY - the Swiss virtual autopsy approach. *Leg Med*. 2007;9:100-4.
14. Thali MJ, Yen K, Schweitzer W, Vock P, Boesch C, Ozdoba C, Schroth G, Ith M, Sonnenschein M, Doernhoefer T, Scheurer E, Plattner T, Dirnhofer R. Virtopsy, a new imaging horizon in forensic pathology: virtual autopsy by postmortem multislice computed tomography (MSCT) and magnetic resonance imaging (MRI)--a feasibility study. *J Forensic Sci*. 2003;48:386-403.
15. Wullenweber R, Schneider V, Grumme T. A computer- tomographical examination of cranial bullet wounds. *Z Rechtsmed* 1977;80:227- 246.