European Heart Journal (1995) **16**, 253–256

Cardiac involvement in rheumatoid arthritis: evidence of silent heart disease

S. Corrao, L. Salli', S. Arnone, R. Scaglione, V. Amato, M. Cecala, A. Licata, and G. Licata

Institute of Internal Medicine, University of Palermo, Palermo, Italy

KEY WORDS: Rheumatoid arthritis, cardiac abnormalities, echocardiography.

Background: *Rheumatoid arthritis (RA) is a systemic disease involving many organ systems and is frequently accompanied by cardiac alterations. However, there is considerable disagreement concerning the cardiac abnormalities found in patients with RA.*

The purpose of our investigation was to determine, by a non-invasive method such as echocardiography, the nature and extent of cardiac involvement in RA patients with no symptoms of cardiac disease, in comparison with a control sample.

Methods: *We selected 35 patients affected by rheumatoid arthritis (five men, 30 women), aged 51 ± 11 years. No patient had either symptoms of cardiac disease or extra cardiac complaint.*

As a control group we studied 52 volunteers, aged 51 ± 12 years, randomly selected among a larger group of subjects with no symptoms, signs andlor clinical findings of extra cardiac diseases. All were in sinus rhythm and without any cardiac symptom.

Standard two-dimensional, M-mode and Doppler echocardiographic examination was carried out on each subject.

Results: *In RA patients we found a higher prevalence of several abnormalities. We found no statistically significant differences between the groups of RA patients based on the stage and duration of disease. We found no correlation between cardiac abnormalities and inflammatory indices or drug therapy.*

Discussion: *At least three alterations seem to be typical of RA patients in the absence of any symptom of cardiac disease: (1) posterior pericardial effusion, (2) aortic root alterations and (3) valvular thickening. The prevalence of MVP is controversial and needs further investigation. These alterations are variously combined in each patient, and for this reason we think that it is possible to represent such a heart involvement as 'silent rheumatoid heart disease'.*

Moreover the knowledge of the presence of unrecognised cardiac abnormalities can be very important for the correct assessment and management of the RA patient.

Introduction

Rheumatoid arthritis (RA) is a systemic disease involving many organ systems[1–3] and is frequently accompanied by cardiac alterations[4]. However, there has been considerable disagreement concerning the cardiac abnormalities found in patients with RA.

Originally, lesions associated with RA were confused with those caused by rheumatic fever; but in recent years rheumatoid cardiac involvement has become a well-recognised pathological entity[5–7]. However, there are contrasting data about the significance and prevalence of pathological findings.

Necropsy studies reveal a high incidence of pericardial, myocardial and endocardial involvement in patients affected by RA[8,9], and such involvement is often called rheumatoid heart disease[10–13]. However, cardiac disease is often clinically inconspicuous and is rarely a severe life-threatening complication of RA.

Submitted for publication on 7 January 1994, in revised form 6 May 1994, and accepted 1 August 1994.

Correspondence: Salvatore Corrao, MD Cattedra di Patologia Medica I (Dir. G. Licata), Piazza Delle Cliniche, 2, 90127 Palermo, Italy.

Echocardiography is a sensitive and non-invasive method of detecting cardiac abnormalities. Therefore it may be the best means of evaluating both the association between cardiac involvement and rheumatoid disease, and the prevalence of cardiac abnormalities in patients with RA.

Current data on this topic are unsatisfactory. A major problem is the lack of a correct experimental design, where both strict recruitment criteria and comparison with a control group are fundamental. Necropsy studies provide limited information on cardiac involvement in the rheumatoid population, evaluating only patients with the worst prognosis.

The purpose of our investigation was to determine the nature and extent of cardiac involvement in RA patients in comparison with a control sample, by a non-invasive method such as echocardiography.

Patients and methods

SUBJECT SELECTION AND STUDY PROCEDURE

We selected 35 subjects (five males, 30 females — aged 51 ± 11 years), from patients referred to our rheumatological outpatient clinic. All the subjects gave informed

0195-668X/95/020253+04 $08.00/0

consent, and the study was also approved by the Ethics Committee of our Institution. All patients fulfilled the revised American Rheumatism Association criteria for the diagnosis of RA[14] and were free of symptoms of cardiac disease. Patient evaluation included a complete history, physical examination, a 12-lead electrocardiogram and a standard echocardiogram. All patients had routine laboratory studies including complete blood count, erythrocyte sedimentation rate by the Westergren method and the latex test to determine if there was a positive rheumatoid factor. All patients were considered to be in functional class II or III on the basis of their joint disease, according to Steinbrocker criteria[15].

We had excluded from the study all patients with a history and/or clinical findings of rheumatic fever, arterial hypertension, arterial hypotension, diabetes mellitus, primary cardiomyopathy, congenital heart diseases and other connective tissue diseases (congenital and inflammatory).

As a control group we studied 52 volunteers, aged 51 ± 12 years, randomly selected from a larger group of subjects without symptoms, signs and/or clinical findings of extra cardiac diseases. They were chosen from a group of subjects undergoing a clinical check-up. Thus, verification as regards their freedom from extra cardiac diseases and cardiac symptoms, could be established. All of them were in sinus rhythm.

The two study groups, homogeneous for sex, age, body mass index and life style, were compared. However, more analyses were performed on RA patients: they were grouped according to functional class and duration of disease and then compared.

ECHOCARDIOGRAPHIC EXAMINATION

Between 0800 and 1100h standard two-dimensional, M-mode and Doppler echocardiographic examinations were carried out on each subject while in the partial left lateral decubitus position. An Esaote Biomedica computer aided ultra-sonoscope, equipped with 2·5 and 3·5 MHz phased-array transducers and a standard VHS video format, were used to record the information. The transducers had pulsed and continuous Doppler capability, a moveable Doppler cursor and an adjustable sample volume size. The sample volume size was set at 4 mm for this study.

The two-dimensional echocardiographic study was performed on the parasternal long- and short-axis views, and on the apical four- and two-chamber views. Standard M-mode echocardiographic examination, guided by two-dimensional echocardiography from the left parasternal window, was performed to assess LV mass. Measurements were made according to the Penn convention described by Devereux and Reichek[16,17]: LV mass (g) = 1·04 [(LVID + VST + PWT)3 − (LVID)3] − 13·6; where LVID = diastolic LV internal diameter; VST = diastolic ventricular septal thickness, and PWT = diastolic posterior wall thickness. Measurement points were taken at the peak of the R wave on a simultaneous electrocardiogram from an average of four cycles.

Mitral valve prolapse (MVP) was defined as at least 3 mm of systolic displacement, behind the mitral valve ring of one or both mitral leaflets in the parasternal long-axis view on two-dimensional echocardiography[18]. Prolapse was confirmed from at least one orthogonal view. We also carried out a standard pulsed and continuous Doppler echocardiographic examination to assess the spectral flow pattern of the heart valves[19]. Each study was read independently by two observers without knowledge of clinical data. In the event of a disagreement, the two reviewers reached a consensus by a joint review of the study.

ECHOCARDIOGRAPHIC ABNORMALITIES

Abnormal echocardiographic findings were described as pericardial and valvular alterations, left ventricle wall motion abnormalities, and aortic root dysfunctions. M-mode echocardiographic examination guided by two-dimensional echocardiography was performed from the parasternal window to evaluate pericardial abnormalities. These were described as minimal pericardial effusion (end-diastolic pericardial–epicardial separation up to 4 mm) or overt pericardial effusion (end-diastolic pericardial–epicardial separation more than 4 mm).

The epicardium was identified from the parasternal long-axis view by progressive decrease in damping. A tracing was taken from multiple cardiac cycles, with various degrees of damping, in order to assess pericardial–epicardial separation and diminished pericardial motion. The measurement of separation was made on M-mode images at end diastole.

Valvular lesions were grouped into four categories: (1) MVP without Doppler signs of mitral regurgitation; (2) MVP with Doppler signs of mitral regurgitation; (3) isolated valvular regurgitation; (4) valvular thickening (excluding subjects with mitral valve prolapse).

We considered as tricuspidal regurgitation only those cases in which the trans-valvular spectral flow-pattern showed a high velocity regurgitation flow detectable in the right atrium by pulsed Doppler examination. Myocardial dysfunction was described as global or regional hypokinesis or akinesis. Finally, aortic root alterations were described as overt enlargement (3 mm minimum) of almost one sinus of Valsalva (Fig. 1).

DATA ANALYSIS

The patients were divided into three groups according to the duration of the disease: ≤2 years, 2–8 years and ≥8 years. Interval measurements are reported as mean ± standard deviation. A two-tailed unpaired t-test was used for comparison of means and the Pearson Chi-square statistic and z-test were used for comparison of proportions. The partial correlation coefficient technique was performed to examine the relationship between cardiac abnormalities and inflammatory indices or drug therapy, controlling for the effects of age and sex. A value of $P<0·05$ was assumed as statistically significant.

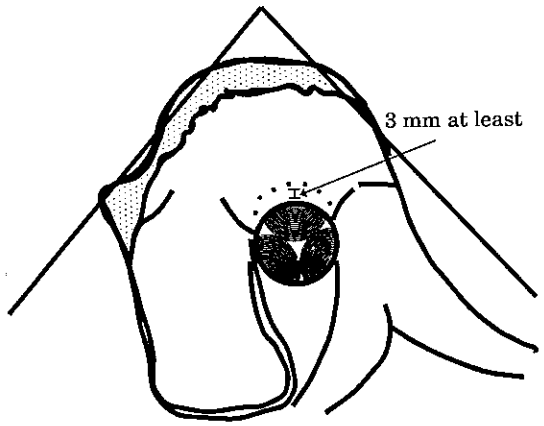

Figure 1 Parasternal short-axis view at aortic valve level: significant dilatation of at least one sinus of Valsalva (schematic representation).

Results

There were no differences between the two groups as regards left ventricular mass, even when it was normalized to height and body surface area. We found a higher prevalence of pericardial effusion, MVP, aortic root alterations and valvular thickening and/or calcification in RA patients, as reported in Table 1. None of the controls and only one rheumatoid patient had left ventricular wall motion abnormalities. When we compared the subgroups of RA patients (according, respectively, to different stages and duration of the disease), we found no statistically significant differences as regards all the considered variables. Some relevant data about these comparisons are shown in Tables 2 and 3. We found no correlation between cardiac abnormalities and inflammatory indices or drug therapy.

Table 1 Descriptive data and prevalence of cardiac abnormalities in the RA patients: comparison with the control group

	RA patients	Controls	*P*<
n	35	52	
Age (years)	51 ± 11	51 ± 12	ns
BMI (kg . m^{-2})	25 ± 4	25 ± 5	ns
Wall motion abnormalities	1 (2·9%)	0	ns
MVP	12 (34·3%)	2 (3·8%)	0·001
MVP+MR	6 (17·1%)	1 (1·9%)	0·03
Isolated MVP	6 (17·1%)	1 (1·9%)	0·03
Mitral valve thickening and/or calcification	8 (22·9%)	2 (3·8%)	0·02
Aortic valve thickening and/or calcification	7 (20%)	1 (1·9%)	0·03
Aortic root alterations	12 (34·3%)	2 (3·8%)	0·001
Pericardial involvement	20 (57·1%)	2 (3·8%)	0·001
minimal PE	15 (42·9%)	2 (3·8%)	0·001
overt PE	5 (14·3%)	0	0·02
TR	2 (5·7%)	0	ns
Isolated MR	2 (5·7%)	1 (1·9%)	ns
AR	2 (5·7%)	1 (1·9%)	ns
Combined valvular alterations	4 (11·4%)	1 (1·9%)	ns
LVM (g)	132 ± 32	135 ± 51	ns
LVM/h (g . m^{-1})	86 ± 21	80 ± 28	ns
LVMI (g . m^{-2})	85 ± 20	76 ± 22	ns

BMI=body mass index; MVP=mitral valve prolapse; MR=mitral regurgitation; PE=pericardial effusion; TR=tricuspidal regurgitation; AR=aortic regurgitation; LVM=left ventricular mass; LVM/h=left ventricular mass/height; LVMI=left ventricular mass index.

Table 2 Comparison between subgroups of RA patients according to the staging of disease

	Stage II	Stage III
n	17	18
F/M	15/2	15/3
Age (years)	50 ± 12	52 ± 11
Duration of the disease (months)	60 ± 60	96 ± 69
Mitral valve prolapse	6 (35·3%)	6 (33·3%)
Aortic root alterations	3 (17·6%)	9 (50%)
Pericardial involvement	9 (52·9%)	11 (61·1%)
minimal PE	7 (41·2%)	8 (44·4%)
overt PE	2 (11·7%)	3 (16·7%)

Differences were not statistically significant.
PE=pericardial effusion.

Discussion

The major feature of our study was the selection of RA patients with no cardiac symptoms and/or clinical evidence of extra cardiac complaints. This was in order to establish the prevalence of cardiac abnormalities in the absence of an apparent heart disease and to correlate them to rheumatoid arthritis, thereby without confounding factors. The second feature was the comparison of rheumatoid patient data with those of a control group. This was in order to remove calculation mistakes due to the lack of a point of reference. Thus, the goal of our study was to detect unrecognised cardiac alterations caused by the extra-articular inflammatory process.

Fundamentally, the results of our study indicated the presence of various significant cardiac alterations in RA patients. Pericardial effusion was the most frequent abnormality, as previously reported by Prakash *et al.* in a classic study[20]. Our data underline the common occurrence of pericardial involvement, a finding which may be important when taking into account the recruitment criteria of our patient series. The extra-articular inflammatory process frequently and insidiously seems to involve the pericardium, even in the absence of symptoms. Finally, the above-mentioned criteria explain the lack of a significant pericardial effusion in our patients.

The other main alterations were mitral and aortic valve thickening, mitral valve prolapse and aortic root abnormalities. The abnormal valve echoes in RA patients might be due to fibrosis of the valve structures because of the extra-articular inflammatory process. However, the high MVP prevalence is more difficult to interpret. It might be that MVP has a time-dependent inflammatory basis. We found the higher prevalence of MVP in patients with a longer duration of disease, but it was not statistically significant, probably because of the

Table 3 Comparison among subgroups of RA patients according to the duration of disease

	Group A	Group B	Group C
n	7	16	12
Age (years)	53·0 ± 12·0	49·1 ± 11·8	52·2 ± 10·5
Duration of disease (months)	0·6 ± 0·3	4·4 ± 1·6	13·6 ± 4·4
Pericardial involvement	2 (28·57%)	10 (62·5%)	8 (66·67%)
Mitral valve prolapse	2 (28·57%)	4 (25·0%)	6 (50%)
Mitral regurgitation	—	1 (6·25%)	1 (8·33%)
Aortic regurgitation	1 (14·29%)	—	1 (8·33%)
Combined valvular alterations	—	2 (12·5%)	2 (16·67%)
Aortic root alterations	2 (28·57%)	4 (25%)	6 (50%)

Group A: duration of disease ≤2 years.
Group B: duration of disease between 2 and 8 years.
Group C: duration of disease ≥ 8 years.

small subgroup patient number. Therefore, we think that this particular aspect needs further investigation with a larger patient cohort.

Aortic root alterations, i.e. enlargement of almost one sinus of Valsalva, seem to be another characteristic lesion in RA patients. We found no association between these abnormalities and aortic regurgitation. Thus, aortic root alterations might be the result of a relatively non-malignant lesion. However the patients in this study were recruited without cardiac symptoms.

Three alterations at least seem to be typical of RA patients without any symptom of cardiac disease: (1) posterior pericardial effusion, (2) aortic root alterations and (3) valvular thickening. MVP prevalence is controversial and needs further investigation. All these alterations are variously combined in each patient. Hence, we believe it is possible to represent such a heart involvement as 'silent rheumatoid heart disease'.

In conclusion, we found a significant cardiac involvement in RA patients compared with a control sample. We think that the knowledge of the presence of unrecognised cardiac abnormalities can be very important for the correct assessment and management of the RA patient. Therefore, every patient should be submitted to a cardiological assessment (in particular echocardiographic) in order that the cardiac involvement can be detected early and treated, and more severe disease prevented.

References

[1] Fingerman DL, Andrus FC. Visceral lesions associated with Rheumatoid Arthritis. Ann Rheum Dis 1943; 3: 168–78.

[2] Bevans M, Nadell J, Demartini F, Ragan C. Systemic lesions of malignant rheumatoid arthritis. Am J Med 1954; 16: 197–211.

[3] Sinclair RJG, Cruickshank B. A clinical and pathological study of 16 cases of rheumatoid arthritis with extensive visceral involvement (rheumatoid disease). Q J Med 1956; 25: 313–32.

[4] Pizzarello RA, Goldberg J. The heart in rheumatoid arthritis. In: Utsinger PD, Zvaifler NJ, Ehrlich GE, eds. Rheumatoid Arthritis. Etiology, diagnosis, management. Philadelphia: J. B. Lippincott, 1985: 431–40.

[5] Weintraub AM, Zvaifler NJ. The occurrence of valvular and myocardial disease in patients with chronic joint deformity. A spectrum. Am J Med 1963; 35: 145–62.

[6] Goldenberg J, Ferraz MB, Pessoa AP *et al.* Symptomatic cardiac involvement in juvenile rheumatoid arthritis. Int J Cardiol 1992; 34: 57–62.

[7] Rowe IF, Gibson DG, Keat AC, Brewerton DA. Echocardiographic diastolic abnormalities of left ventricle in inflammatory joint disease. Ann Rheum Dis 1991; 50: 227–30.

[8] Kirk J, Cosh J. The pericarditis of rheumatoid arthritis. Q J Med 1969; 38: 397–423.

[9] Lebowitz WB. The heart in rheumatoid arthritis (rheumatoid disease). A clinical and pathological study of 62 cases. Ann Intern Med 1963; 58: 102–23.

[10] Baggenstoss AH, Rosenberg EF. Cardiac lesions associated with chronic infectious arthritis. Arch Int Med 1941; 67: 241–58.

[11] Sokoloff L. The heart in rheumatoid arthritis. Am Heart J 1953; 45: 635–43.

[12] Levine M, Kaplan L, Marcus S *et al.* The heart in rheumatoid arthritis. A clinical pathological correlation of 43 autopsied patients. Ann Rheum Dis 1955; 14: 430.

[13] Cruikshank B. Heart lesions in rheumatoid disease. J Pathol Bacteriol 1958; 76: 223–40.

[14] Arnett FC, Edworthy SM, Bloch DA *et al.* The American Rheumatism Association 1987 revised criteria for the classification of Rheumatoid Arthritis. Arthritis Rheum 1988; 31: 315–24.

[15] Steinbrocker O, Traeger CH, Battermann RC. Therapeutic criteria in Rheumatoid Arthritis. JAMA 1949; 140: 659–62.

[16] Devereux RB, Reichek N. Echocardiographic determination of left ventricular mass in man. Anatomic validation of the method. Circulation 1977; 55: 613–8.

[17] Devereux RB, Alonso DR, Lutas EM *et al.* Echocardiographic assessment of left ventricular hypertrophy: comparison to necropsy findings. Am J Cardiol 1986; 57: 450–8.

[18] Devereux RB, Kramer-Fox R, Shear MK, Kligfield P, Pini R, Savage DD. Diagnosis and classification of severity of mitral valve prolapse: methodologic, biologic and prognostic considerations. Am Heart J 1987; 113: 1265–80.

[19] Missri J. Clinical Doppler echocardiography. Spectral and color flow imaging. McGraw-Hill Information Services Company 1990; 28–42.

[20] Prakash R, Atassi A, Poske R, Rosen MK. Prevalence of pericardial effusion and mitral valve involvement in patients with Rheumatoid Arthritis without cardiac symptoms. An Echocardiographic evaluation. N Eng J Med 1973; 289: 597–600.