

# Guidelines How to Integrate Surgery and Targeted Therapy with Biologics for the Treatment of Hidradenitis Suppurativa: Delphi Consensus Statements from an Italian Expert Panel

Annamaria Offidani<sup>a</sup> Angelo Valerio Marzano<sup>b,c</sup> Ketty Peris<sup>d,e</sup>  
Elisa Molinelli<sup>a</sup> Vincenzo Bettoli<sup>f</sup> Cristina Magnoni<sup>g</sup> Luca Vaienti<sup>h</sup>  
Giovanni Pappagallo<sup>i</sup> Paolo Amerio<sup>j</sup> Laura Atzori<sup>k</sup> Anna Balato<sup>l</sup>  
Luca Bianchi<sup>m</sup> Maria Rita Bongiorno<sup>n</sup> Federico Contedini<sup>o</sup> Paolo Dapavo<sup>p</sup>  
Giovanni Di Benedetto<sup>q</sup> Valentina Dini<sup>r</sup> Massimo Donini<sup>s</sup>  
Gabriella Fabbrocini<sup>t</sup> Luca Fania<sup>u</sup> Caterina Foti<sup>v</sup> Alessandro Gatti<sup>w</sup>  
Claudio Guarneri<sup>x</sup> Giovanna Malara<sup>y,z</sup> Marco Manfredini<sup>A</sup> Pietro Morrone<sup>B</sup>  
Luigi Naldi<sup>C</sup> Aurora Parodi<sup>D</sup> Concetta Potenza<sup>E</sup> Sandra Schianchi<sup>F</sup>  
Luca Stingeni<sup>G</sup> Emanuele Trovato<sup>H</sup> Fabrizio Vaira<sup>I</sup> Mario Valenti<sup>J,K</sup>  
Marina Venturini<sup>L</sup> Andrea Chiricozzi<sup>d,e</sup> Francesca Prignano<sup>M</sup>

<sup>a</sup>Dermatological Unit, Department of Clinical and Molecular Sciences, Polytechnic Marche University, Ancona, Italy; <sup>b</sup>Dermatology Unit, Fondazione IRCCS Ca' Granda Ospedale Maggiore Policlinico, Milan, Italy; <sup>c</sup>Department of Pathophysiology and Transplantation, Università Degli Studi di Milano, Milan, Italy; <sup>d</sup>UOC of Dermatology, Department of Medical and Surgical Sciences, Fondazione Policlinico Universitario A. Gemelli – IRCCS, Rome, Italy; <sup>e</sup>Dermatology, Department of Translational Medicine and Surgery, Università Cattolica del Sacro Cuore, Rome, Italy; <sup>f</sup>Section of Dermatology and Infectious Diseases, Department of Medical Sciences, University of Ferrara, Ferrara, Italy; <sup>g</sup>Department of Dermatology, Surgical, Medical and Dental Department of Morphological Sciences Related to Transplant, Oncology and Regenerative Medicine, University of Modena and Reggio Emilia, Modena, Italy; <sup>h</sup>Department of Reconstructive and Aesthetic Plastic Surgery, University of Milan, I.R.C.C.S. Istituto Ortopedico Galeazzi, Milan, Italy; <sup>i</sup>School of Clinical Research Methodology, IRCCS “Sacro Cuore – Don Calabria Hospital”, Negrar di Valpolicella, Italy; <sup>j</sup>Dermatologic Clinic, G. D’Annunzio University, Chieti, Italy; <sup>k</sup>Unit of Dermatology, Department of Medical Sciences and Public Health, University of Cagliari, Cagliari, Italy; <sup>l</sup>Dermatology Unit, University of Campania “Luigi Vanvitelli”, Naples, Italy; <sup>m</sup>UOSD of Dermatology, Policlinico Tor Vergata, Department of Systems Medicine, University of Rome Tor Vergata, Rome, Italy; <sup>n</sup>Department of Health Promotion Sciences, Internal Medicine and Medical Specialties, University of Palermo, Palermo, Italy; <sup>o</sup>Department of Plastic Surgery, S. Orsola-Malpighi Hospital, Bologna, Italy; <sup>p</sup>Section of Dermatology, Department of Medical Sciences, University of Turin, Turin, Italy; <sup>q</sup>Clinic of Plastic and Reconstructive Surgery, Department of Experimental and Clinical Medicine, Marche Polytechnic University Medical School, Ancona, Italy; <sup>r</sup>Department of Dermatology, University of Pisa, Pisa, Italy; <sup>s</sup>Department of Dermatology, SS Giovanni e Paolo Civil Hospital,

A.V.M., A.O., and K.P. share first co-authorship.  
A.C. and F.P. share last co-authorship.

Venice, Italy; <sup>t</sup>Section of Dermatology, Department of Clinical Medicine and Surgery, University of Naples Federico II, Naples, Italy; <sup>u</sup>Dermatology Unit, IDI-IRCCS, Rome, Italy; <sup>v</sup>Department of Precision and Regenerative Medicine and Ionian Area, Unit of Dermatology, University of Bari Aldo Moro, Bari, Italy; <sup>w</sup>Department of Dermatology, AULSS2 Marca Trevigiana, Hospital Ca' Foncello, Treviso, Italy; <sup>x</sup>Department of Biomedical and Dental Sciences and Morphofunctional Imaging, University of Messina, Messina, Italy; <sup>y</sup>Dermatology Unit, Hospital "Bianchi Melacrino Morelli", Reggio Calabria, Italy; <sup>z</sup>Department of Dermatology, Papardo Hospital, Messina, Italy; <sup>A</sup>Dermatology Unit, Department of Surgical, Medical, Dental and Morphological Sciences with Interest in Transplant, Oncological and Regenerative Medicine, University of Modena and Reggio Emilia, Modena, Italy; <sup>B</sup>Unit of Dermatology, Mariano Santo Hospital, Cosenza, Italy; <sup>C</sup>Division of Dermatology, San Bortolo Hospital, Vicenza, Italy; <sup>D</sup>Unit of Dermatology, San Martino Policlinico Hospital, IRCCS for Oncology and Neurosciences, Genoa, Italy; <sup>E</sup>Dermatology, Polo Pontino, Sapienza University, Latina, Italy; <sup>F</sup>Department of Dermatology, 'M Bufalini' Hospital, Cesena, Italy; <sup>G</sup>Dermatology Section, Medical and Surgical Department, University of Perugia, Perugia, Italy; <sup>H</sup>Dermatology Unit, Department of Medical, Surgical and Neurological Sciences, University of Siena, Siena, Italy; <sup>I</sup>Unit of Dermatology, IRCCS Ospedale San Raffaele, Milan, Italy; <sup>J</sup>Department of Biomedical Sciences, Humanitas University, Pieve Emanuele, Italy; <sup>K</sup>Dermatology Unit, IRCCS Humanitas Research Hospital, Rozzano, Italy; <sup>L</sup>Section of Dermatology, Department of Clinical and Experimental Sciences, University of Brescia, Brescia, Italy; <sup>M</sup>Department of Health Science, Section of Dermatology, University of Firenze, Firenze, Italy

---

## Keywords

Acne inversa · Biologic · Hidradenitis suppurativa · Surgery · Wide local excision

---

## Abstract

Hidradenitis suppurativa (HS) is a chronic inflammatory skin disease characterized by recurrent and painful nodules and abscesses in intertriginous skin areas, which can progress to sinus tract formation, tissue destruction, and scarring. HS is highly debilitating and severely impairs the psychological well-being and quality of life of patients. The therapeutic approach to HS is based on medical therapy and surgery. First-line medical therapy includes topical antibiotics, systemic antibiotics, and biologics. Main surgical procedures include deroofting, local excision, and wide local excision. Despite the availability of multiple therapeutic options, the rates of disease recurrence and progression continue to be high. In recent years, the possibility of combining biologic therapy and surgery has raised considerable interest. In a clinical trial, the perioperative use of adalimumab has been associated with greater response rates and improved inflammatory load and pain, with no increased risk of postoperative infectious complications. However, several practical aspects of combined biologic therapy and surgery are poorly defined. In June 2022, nine Italian HS experts convened to address issues related to the integration of biologic therapy and surgery in clinical practice. To this purpose, the experts identified 10 areas of interest based on published evidence and personal experience: (1) patient profiling

(diagnostic criteria, disease severity classification, assessment of response to treatment, patient-reported outcomes, comorbidities); (2) tailoring surgery to HS characteristics; (3) wide local excision; (4) presurgery biologic treatment; (5) concomitant biologic and surgical treatments; (6) pre- and postsurgery management; (7) antibiotic systemic therapy; (8) biologic therapy after radical surgery; (9) management of adverse events to biologics; and (10) management of postoperative infectious complications. Consensus between experts was reached using the Estimate-Talk-Estimate method (Delphi Method). The statements were subsequently presented to a panel of 27 HS experts from across Italy, and their agreement was assessed using the UCLA Appropriateness Method. This article presents and discusses the consensus statements.

© 2024 The Author(s).

Published by S. Karger AG, Basel

## Introduction

Hidradenitis suppurativa (HS), also known as acne inversa, is a chronic inflammatory skin disease characterized by the recurrent formation of painful nodules and abscesses that can evolve into sinus tracts, tissue destruction, and scarring [1, 2]. HS predominantly affects intertriginous skin areas, such as axillae, breast folds, inguinal folds, and the anogenital area, with a great heterogeneity in lesion appearance and site involvement [1–3]. The pathogenesis of HS is complex and incompletely understood; hair follicle disruption and

dysregulated immune responses have been implicated [1, 4]. The prevalence of HS ranges from 0.7% to 1.2% in the European and US population [2]. HS usually develops in the third and fourth decade of life and is associated with cardiovascular risk factors (metabolic syndrome, obesity, smoking) and other comorbidities [5]. It is a highly debilitating disease that severely impairs the psychological well-being and quality of life of affected individuals [6–8]. This skin disease is challenging also for clinicians, from diagnosis to treatment decisions. Indeed, several reports have described substantial delays between disease onset and diagnosis (up to 10 years) and substantial rates of undertreated or inadequately treated patients [9–11].

The therapeutic approach to HS is based on medical therapy and surgical procedures and is tailored to disease severity [12, 13]. First-line medical therapy consistently recommended across the existing guidelines includes topical antibiotics (clindamycin), systemic antibiotics (oral clindamycin/rifampicin, tetracycline), and biologics [14–18]. Main surgical procedures include deroofing, local excision, and wide local excision (radical resection of all involved tissues) [14–18]. Lifestyle modifications (smoking cessation, weight loss), pain management, and treatment of superinfections are generally recommended as adjuvant therapies [14–18].

Despite the availability of multiple therapeutic options, the rates of disease recurrence and progression continue to be high [19]. In recent years, the possibility of combining therapeutic strategies to increase efficacy has raised considerable interest. The promising results from clinical trials with biologics targeting inflammatory pathways [20, 21] have led to the hypothesis that the immunosuppressive action of biologics and surgery may have synergistic effects [19, 22–24]. However, several practical issues related to the combination of surgery and therapy with biologics need to be defined for the implementation of this strategy in the management of patients with HS.

To address open questions related to the integration of biologic and surgical therapy, nine Italian HS experts met virtually in June 2022. Their primary objective was to issue a consensus document to provide physicians with updated information and guidance on the combination of medical therapy with biologics and surgical therapy for patients with moderate to severe HS. To this purpose, the experts identified 10 relevant items based on published evidence and personal experience and formulated a statement for each item. Consensus was reached using the Delphi method, with the involvement of an expert panel from across Italy. Here, we present the results of this effort.

## Methods

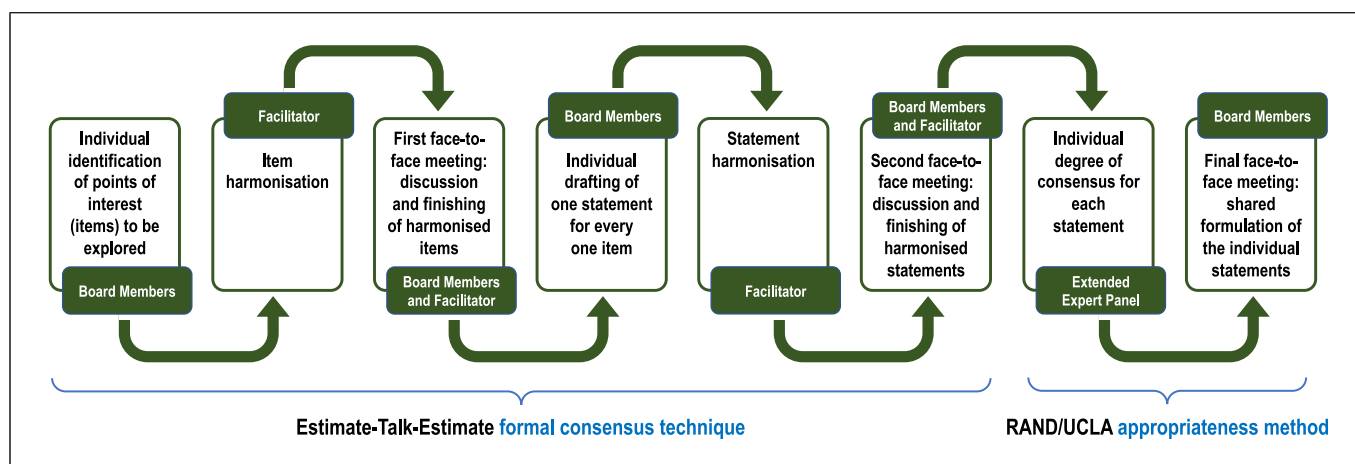
Figure 1 shows the workflow of the consensus process, which started using the Estimate-Talk-Estimate method [25, 26]. Estimate-Talk-Estimate (a formal means of reaching consensus that was developed to overcome some of the negative aspects of group dynamics) facilitates group decision making by combining assembling of expert opinions on an anonymous basis during surveys with open exchange during workshops by a facilitator [27, 28]. First, nine experts (the steering committee) involved in medical care of patients with HS individually identified 45 points of interest (hereafter: items), which, in their opinion, deserved exploration and discussion. These were then harmonized and grouped by a senior clinical epidemiologist (Giovanni Pappagallo) trained in developing group consensus (the facilitator) into 10 items that were proposed to the board members at a face-to-face meeting. The harmonized items were discussed to reach agreement between the facilitator's work and the experts' opinions, after which the board members individually drew up one statement for each item. Each statement was subsequently harmonized by the facilitator. At a second face-to-face meeting, the board members and the facilitator reviewed and further discussed the harmonized statements, and finally agreed on statements. The statements generated in this way were then presented via an online scoring platform to the 27 members of an extended panel of dermatology and surgery specialists with advanced training in the treatment of HS, who expressed their degree of consensus by means of a RAND 9-point numerical rating scale ranging from 1 = totally disagree to 9 = totally agree. Consensus about the appropriateness of a statement was reached when the median score was  $\geq 7$  without disagreement, according to the RAND/UCLA Appropriateness Method User's Manual [29]. A final face-to-face meeting allowed the members of the board to come to a final shared formulation of the 10 statements.

## Results and Discussion

The consensus statements covering relevant issues of combined therapy for HS are shown in Table 1, along with the results of the extended panel voting, with all statements achieving the predefined level of consensus. In the following sections, the statements are discussed for each item, along with the evidence supporting them.

### *Patient Profiling*

A comprehensive patient assessment is crucial for ensuring optimal HS management. According to the Dessau definition, three simple criteria are mandatory for the diagnosis of HS: presence of typical lesions, typical location of the lesions, and chronicity [14]. Assessments of disease severity and response to treatment with validated tools are essential for guiding therapeutic decisions. The presence of comorbidities and patient-reported outcomes, including quality of life and pain/itching, are also relevant components of the comprehensive evaluation of patients with HS.



**Fig. 1.** Workflow of the consensus process.

In the setting of primary care, asking patients with suspected HS about the repeated occurrence of “boils” over the past 6 months in skin fold areas has proven a useful screening question [2, 5]. Obligatory Dessau criteria for the diagnosis of HS that are endorsed by all current guidelines [13] include: primary skin lesions appearing as follicular papules/pustules, nodules, abscesses and secondary lesions like cysts, fistula and sinus tracts, double pseudo-comedones, and scars; location of lesions at the axillae, submammary/intramammary folds in women, groin, perineum, and buttocks; and chronicity of lesions, defined as the occurrence of painful or purulent lesions more than twice over 6 months [5]. Other (nonobligatory) criteria include family history of HS and microbiological examination confirming the presence of normal skin microorganisms at primary lesions [5].

Imaging techniques, including ultrasound and thermography, are emerging as highly sensitive tools and as complementary tests in HS evaluation [5, 30–32]. These techniques allow to assess deep-seated lesions, early stages of morphological follicular changes, subclinical inflammation and fibrosis, the progression of sinus tracts in advanced HS, and changes associated with biologic therapy. Thermography, distinguishing health tissues and inflammatory sites, could be used to delineate the excision margins and to optimize a surgical procedure, confirming the total excision of inflammatory lesions and avoiding postoperative recurrence [33, 34].

Color Doppler ultrasound, in particular, has been shown in recent studies to provide detailed information about the presence and morphology of fistulous tracts [35]. This approach also allows to assess vascularization, an inflammation-related parameter, and fibrosis of HS lesions, for example during treatment with biologics [32, 36]. Magnetic resonance imaging is also playing an in-

creasingly important role in the assessment of HS lesions, especially in the anoperineal area, in differential diagnosis, and preoperative evaluations [37].

The Hurley classification of HS, originally designed for guiding treatment choices, is the oldest and most commonly used disease staging system; it is easy to use and is recommended across all guidelines [13, 38]. Over the years, the Hurley classification has been refined [5, 39]. According to Zouboulis et al. [5], stage I is defined by “individual primary lesions and/or cysts without fistulae or scarring”; stage II by “individual primary lesions and/or cysts with presence of fistulae and scarring”; and stage III by “confluent primary and secondary lesions at involved surface(s) with fistulae and scars”.

The International Hidradenitis Suppurativa 4 (IHS4) assessment tool has been recently developed and validated for the cross-sectional evaluation of disease severity [40]. The IHS4 total score is obtained by adding the following numbers: number of nodules, number of abscesses multiplied by 2, and number of draining tunnels (fistulae/sinuses) multiplied by 4. A total score  $\leq 3$  indicates mild HS, a score of 4–10 indicates moderate HS, and a score  $\geq 11$  indicates severe HS [40]. Notably, the presence of a single draining tunnel is sufficient to classify HS as moderate, according to this score, allowing an early start of systemic therapy, before tissues have been irreversibly damaged.

The currently used outcome measure in clinical trials is the Hidradenitis Suppurativa Clinical Response (HiSCR) developed and validated by Kimball and coworkers [41]. Response to anti-inflammatory treatment is defined by a  $\geq 50\%$  decrease in the number of abscesses and inflammatory nodules, no increase in the number of abscesses, and no increase in the number of draining fistulae from baseline. The HiSCR is however limited by the fact

**Table 1.** Results of extended panel voting

Statements	Median score
1. Patient profiling Before starting any treatment, a correct diagnosis should be performed, based on the modified Dessau criteria Assessment of disease severity and treatment monitoring should include Hurley classification, IHS4, IHS4-55, HS-DLQI, pain, and itch assessment Screening for comorbidities and risk factors, together with preoperative imaging, provide dermatologic surgeons with relevant information for optimal surgery planning	9
2. Surgery according to HS clinics Surgical therapy should be used, alone or combined/sequentially to other treatments, in both early and advanced disease, tailoring the surgical approach to HS severity, number, type, and site of lesions	9
3. Wide local excision The choice of wide surgical treatments depends on the extent of disease, presence of long-standing lesions, affected site, prior surgery and scars, patient comorbidities, and preferences Wide excision should be performed during remission of the inflammatory process to improve surgical and postsurgical outcomes	8
4. Presurgery biologic treatment Presurgery biologic therapy is indicated to reduce skin inflammation and drainage, for a minimum of 12 weeks	8
5. Concomitant biologic and surgical treatments Biologics should be continued during surgery, with the exception of conditions that could negatively affect surgical outcome	8
6. Pre- and postsurgery management The preparation of the HS patient candidate for surgical therapy follows the standard indications in terms of presurgical antiseptics and antibiotic prophylaxis Postsurgery management of HS should follow the general recommendations for the same postsurgery wounds in other disease contexts	9
7. Antibiotic systemic therapy Wide-spectrum or targeted systemic antibiotics should be considered before surgical treatment in order to reduce inflammation and/or bacterial infection Systemic antibiotics should not be administered routinely after surgery	8
8. Biologic therapy after radical surgery Biologic therapy can be used as maintenance therapy regardless of the involvement of other anatomical areas Biologic therapy can be suspended after radical surgery in case of complete and lasting resolution of the disease	8
9. Management of adverse events to systemic therapy Adverse events caused by systemic treatments in HS are in line with other chronic immune-mediated skin diseases In case of adverse events to the systemic therapy adopted, surgical therapy will be considered once the adverse event has been resolved	8
10. Management of infectious, postsurgery complications In selected cases of postoperative infectious complications, the biologic therapy should be suspended for at least 5 times the half-life of the drug	8

that it does not consider a decrease in the number of draining fistulae and is unsuitable for evaluating patients with <3 abscess and nodule counts. To overcome these limitations, Tzellos and colleagues have recently developed the IHS4-55, a dichotomous score for the assessment of response to treatment [42, 43]. IHS4-55 was developed and validated based on the data from the phase

III PIONEER-I and II studies of adalimumab for the treatment of HS [21, 42]. Based on the analysis of the PIONEER I and II data, the best cutoff for discriminating between patients treated with adalimumab or placebo was a 55% reduction of the IHS4 score (IHS4-55) from baseline to 12 weeks [42]. Achieving an IHS4-55 response was associated with significantly lower counts of nodules,

abscesses, and draining tunnels [42]. The IHS4-55 score has been recently validated also for evaluating the response to systemic antibiotics [43]. Based on these data, we recommend the IHS4-55 score for response assessment.

Quality of life is severely impaired in patients with HS, as consistently shown by studies using different scoring systems [2]. HS appears to affect patient quality of life more profoundly than other chronic dermatologic conditions, including psoriasis [44]. The Dermatology Life Quality Index (DLQI) is a widely used, self-administered, simple, 10-question measure addressing the impact of skin disease over the last week [45]. Efforts to develop HS-specific tools, able to capture more effectively outcomes of this complex population of dermatologic patients, have been reported by several authors [46–48]. Notably, pruritus of mild-to-moderate intensity is a common symptom that adversely affects patient quality of life [49]. Pain is also a relevant chronic symptom experienced by patients with HS. Evidence shows that it is inadequately treated [2]. Pain can be assessed using a Numerical Rating Scale (NRS) or a Visual Analog Scale (VAS) and should be treated according to severity [16]. Controlling inflammation with systemic therapies including biologics has been reported to be an effective strategy for pain relief [2].

Similar to other chronic, inflammatory diseases, HS is associated with several comorbidities [50, 51]. Frequently reported comorbidities include obesity, metabolic syndrome, diabetes mellitus, cardiovascular disease, polycystic ovary syndrome, inflammatory bowel disease, spondyloarthritis, rheumatoid arthritis, psoriasis, depression, and generalized anxiety disorder [52]. There is an increasing consensus about the need for comorbidity screening in patients with HS, to ensure a strategy of comprehensive care [42, 51]. The US and Canadian Hidradenitis Suppurativa Foundations have recently published recommendations directed to dermatologists for comorbidity screening in HS, based on a systematic review of the literature [51].

#### *Surgery according to HS Clinics*

Surgery is a widely used therapeutic option for HS; it can be performed at all disease stages, alone or combined with other treatments [53, 54]. Surgical procedures recommended by current guidelines [15, 16] range from minor palliative interventions, such as incision and drainage or deroofing, to curative wide local excision. However, few studies have evaluated these techniques and no consensus exists on the optimal strategy [15, 55]. A personalized approach is therefore needed, which should

consider disease severity and extension, recurrence rate, affected area, presence of comorbidities, history of previous surgery, and patient expectations and preferences [15, 56].

The available evidence shows that incision and drainage, while effective in providing acute relief, are associated with elevated rates of recurrence (nearly 100%) [15, 16]. Deroofing and wide local excision have been associated with lower recurrence rates (approximately 20%–40%) [15, 16]. A meta-analysis published in 2015 estimated recurrence rates at 27% following deroofing, 22% following local excision, and 13% following wide excision [57]. Although there is no consensus on the definition of recurrence of HS following surgery, it is generally accepted that a more extensive resection is associated with a lower risk of recurrence [58].

#### *Wide Local Excision*

Wide local excision is recommended by all guidelines as a surgical intervention for the treatment of advanced regional disease [15, 16]. This procedure consists in the resection of the entire affected area, including a lateral disease-free margin of 1–2 cm; however, there is no consensus as to whether subcutaneous fat should be removed partially or completely in the deep margin. As indicated by Manfredini et al. [59], the deep margin which includes the skin, its appendages, and the subcutaneous tissue should be removed only until soft, normal-appearing subcutaneous fat remains [12, 53].

In the deep margin, excision can usually be limited to a superficial subcutaneous plane, with the muscular fascia being reached only in the most severe HS lesions [60]. Wide local excision can result in a disease-free state where the resection has been performed [16, 61]. The decision to perform radical surgery should take into account characteristics of skin lesions including anatomical area, extension, presence of scarring, previous procedures, and the potential morbidity of the intervention [16, 62]. Patient comorbidities and preferences should also guide this decision. To ensure optimal outcomes, wide local excision should be performed once inflammation has been reduced or disease remission has been achieved by preoperative treatment with biologics and/or systemic antibiotics [53].

There is no consensus about the optimal reconstructive technique following wide local excision and various approaches are described in the literature, including healing by secondary intention [62], primary closure [63], local and regional flaps, split-thickness skin grafting, and dermal substitute with a subsequent skin graft [16, 53, 56].

Of note, the evidence suggests that treatment outcomes are influenced by the extent of the excision, and not by the wound closure procedure [15].

#### *Presurgery Biologic Treatment*

Evidence from clinical trials in patients with HS shows that biologic therapy for  $\geq 12$  weeks is associated with lower tissue inflammation and drainage from skin lesions [20, 21, 24]. Preoperative treatment with a biologic may therefore be able to establish the optimal conditions required for performing radical surgery.

Evidence of significantly elevated levels of proinflammatory cytokines in HS lesions has prompted studies of biologics targeting inflammatory pathways for the treatment of HS [21]. Adalimumab (an anti-TNF- $\alpha$  monoclonal antibody) is so far the only biologic approved for HS and is indicated for the treatment of adults with moderate to severe HS, who have failed to respond to conventional systemic treatments [64]. In the PIONEER I and II trials leading to the approval of adalimumab for HS, HiSCR response rates at 12 weeks were significantly higher in patients treated with adalimumab than in patients treated with placebo (41.8%–58.9% vs. 26.0%–27.6%,  $p < 0.001$ ) [21]. Pain, together with other secondary outcomes, also significantly improved [21]. Reported adverse events were similar between treatment groups [21]. Recently, the results of two multicenter, randomized, placebo-controlled, double-blind phase 3 trials (SUNRISE and SUNSHINE) assessing the efficacy of secukinumab (an anti-IL17 monoclonal antibody) in patients with moderate-to-severe HS at 16 and 52 weeks were published [65]. They showed that secukinumab, currently approved for HS, was able to rapidly improve signs and symptoms of HS with a favorable safety profile (the most common adverse event was headache in both trials) and with a sustained response for up to 52 weeks of treatment [65]. Other biologics, including infliximab (anti-TNF- $\alpha$ ), anakinra (anti-IL1), ustekinumab (anti-IL12/23), brodalumab (anti-IL17-receptor), and bimekizumab (anti-IL17), are currently used off-labels based on the evidence from small studies and case reports [22, 66–69]. Evidence suggesting that biologic therapy prior to surgery may improve the outcomes of radical resection is available for infliximab and secukinumab [22, 70, 71].

Due to the increased risk of infections associated with immunomodulatory biologics, patients should be screened for latent infections, before starting treatment [70, 72]. With regard to the concomitance of biologic therapy and surgery, the North American guidelines for

the management of HS point out that the risk of surgical complications “is likely higher from poorly controlled disease than from medications” [16].

#### *Concomitant Biologic and Surgical Treatments*

Evidence shows that combined biologic therapy and surgery are feasible, with no need to discontinue the biologic agent in most cases. The recent, phase IV, Safety and Efficacy of Adalimumab for Hidradenitis Suppurativa Peri-Surgically (SHARPS) study in adults with moderate to severe HS was the first to evaluate the efficacy and safety of a biologic therapy (adalimumab) in conjunction with surgery (wide-excision surgery followed by secondary intention healing) [24]. Patients received adalimumab or placebo continuously, for 12 weeks before surgery, for 2 weeks perioperatively, and for 10 weeks following surgery. The treatment with adalimumab was associated with a greater proportion of patients achieving a clinical response across all affected body regions and improved inflammatory load and pain, versus placebo. Of note, no increased risk of postoperative infectious complications was reported in patients treated with the biologic [24].

Infectious complications of immunomodulatory therapies have been comprehensively reviewed in a recent publication [73]. Safety issues related to the perioperative use of biologics have been extensively addressed in therapeutic areas in which biologics have been used for longer than in HS [74, 75]. Evidence from these therapeutic areas suggests that biologics prior to surgical procedures are not associated with an increased risk of postoperative complications, wound infection, delayed wound healing, and prolonged hospital stay [76, 77]. Therefore, the interruption of biologics prior to surgery (in particular low-risk or bloodless surgery) is not generally recommended [74, 76]. Overall, decisions about the interruption of biologic therapy prior to surgery should primarily consider patient characteristics, including an increased risk of infections or a history of infectious complications [18]. Finally, it should be reminded that the abrupt discontinuation of biologics may result in disease flare (or recurrence, defined as exacerbation of preexisting lesions at the same body regions) or onset of new HS lesions in other body areas [75, 77].

#### *Pre- and Postsurgery Management*

Preoperative care for patients with HS is aimed at controlling inflammation and preventing disease flares. In a recent review about surgical interventions for HS, Manfredini and colleagues [59] pointed out that preoperative care and medical therapy (with systemic



antibiotics and/or biologics) should be administered over the 4 weeks preceding surgery, so as to treat or prevent disease flares. Pre- and perioperative issues of dermatologic surgery have been comprehensively reviewed [78]. In the postoperative setting, local wound care is crucial for ensuring rapid wound healing and optimal outcomes [59]. Management of surgical wounds in HS patients depends on the anatomical area affected, patient characteristics, the extent of resection, and the adopted reconstruction technique [59]. Systemic antibiotics should not be routinely administered postoperatively, while pain medications may be required during the first week following the intervention [59]. Overall, the standard of preoperative and postoperative care of patients with HS receiving surgical treatment for their skin lesions is similar to that recommended for patients undergoing similar interventions due to other conditions [12, 16, 59, 78].

#### *Antibiotic Systemic Therapy*

Similar to biologics, systemic antibiotics can be administered before surgery for HS to reduce inflammation and to treat or prevent bacterial infections. The decision about the prescription of systemic antibiotics depends on the current clinical scenario and its possible evolution.

Systemic antibiotics (oral tetracycline, oral clindamycin-rifampicin) have been long the mainstay of HS treatment; patients' refractory to oral antibiotics can be treated with intravenous ertapenem or other antibiotics (e.g., dalbavancin) based on microbiological analysis [13, 17, 79–81]. A short-term course of intravenous clindamycin can be considered as an additional option [82]. The mechanism of action of antibiotics includes both anti-inflammatory and antibacterial effects [13]. Response rates ranging from 70% to over 90% have been reported in small studies in HS patients [17].

Given the significant risk of developing resistance to antibiotics, the use of targeted antibiotic treatment based on microbiological analysis may be preferable over an empirical approach [83]. However, not all centers may be adequately equipped to perform such analyses. Interestingly, recent microbiology studies have highlighted a correlation between specific bacterial flora within HS lesions and Hurley stages, suggesting that different antimicrobial treatments, targeting stage-specific bacteria, may be required for different disease stages [1].

#### *Biologic Therapy after Radical Surgery*

Evidence from small retrospective studies suggests that biologics can have a role (as maintenance therapy) in the management of patients with HS also after wide local excision [19, 71]. Adequate duration of biologic therapy in

this setting is currently unknown. In the presence of complete and sustained disease remission, and in the absence of other disease sites (in addition to those successfully treated by surgery), biologic therapy may be discontinued. The concept of maintenance therapy with a biologic following surgery is still a debated issue in HS and a widely accepted definition of maintenance therapy is lacking.

#### *Management of Adverse Events to Systemic Therapy with Biologics*

Clinical trials with biologics in patients with HS have shown that the profile of adverse events is similar to that reported for other chronic immune-mediated inflammatory skin diseases (psoriasis, for example) [20, 21, 72]. Real-life evidence is limited. A recent retrospective analysis of a real-life cohort of 389 patients with HS treated with adalimumab reported three cases of severe infections probably related to adalimumab (2 cases of septicemia and one case of pneumonia caused by *Aspergillus fumigatus*) [84]. Paradoxical reactions to biologics, particularly to anti-TNF- $\alpha$  agents and usually presenting as psoriasiform skin eruptions, have also been described in patients with HS [84–86]. A recent systematic review has highlighted the favorable risk-benefit balance of immunomodulatory therapies for HS [70]. However, long-term efficacy and safety data of biologic therapies are largely lacking; in addition, it should be noted that the dosing regimens used for HS treatment are more intensive than those recommended for other inflammatory diseases and may therefore be less tolerable in the long term. Surgical procedure should be performed only after resolution of adverse events associated with systemic therapy. Biologic-related adverse events should be managed as recommended in the Summary of Product Characteristics of each agent [64].

#### *Management of Infectious Postsurgery Complications*

In case of severe postoperative infectious events, or infectious events that may have severe consequences on surgery outcomes, including deep-seated erysipelas, fasciitis, and abscesses, the biologic should be interrupted for  $\geq 5$  times its half-life. Data describing postoperative infections in patients with HS, especially those treated concomitantly with biologics and surgery, are limited. Reported complications of wide local excision in HS include wound dehiscence, infection, and bleeding [53]. The analysis of the long-term outcomes of wide local excision in 107 patients with HS (median postoperative follow-up was 3 years) reported an overall rate of complications of 17.8%; wound infections were reported in a minority of patients (3.7%) [87]. A recent



retrospective study analyzed the data of 4,020 patients (670 with HS and 3,350 control patients) who underwent common surgical procedures that required skin incision (appendectomy, cholecystectomy, coronary artery bypass grafting, spinal fusion, total knee replacement) [88]. The study found significantly higher rates of comorbidities and perioperative antibiotic use in patients with HS compared with control patients. Patients with HS were 8.4 times more likely than control patients to develop surgical site infections. The odds ratio for surgical site infections remained significantly greater for patients with HS also after adjusting for comorbidities and perioperative antibiotic use, for all procedures as well as for each individual procedure. Thus, HS appeared to increase the risk of surgical site infections regardless of perioperative antibiotic use and comorbidities. According to the authors of the study, a dysregulation of immune responses and/or an altered skin microbiota in patients with HS may explain these findings [88].

## Conclusions

HS has long been an underdiagnosed and undertreated disease with a devastating impact on the life of affected individuals. In recent years, the awareness and understanding of this complex disease have improved, resulting in substantial advances in patient management. Although much remains to be done, we believe that simplified diagnostic criteria, newer diagnostic techniques, comprehensive severity rating, and improved clinical outcome measures including patient reported outcomes, along with the availability of biologic therapies, will ensure early, adequate, personalized, and effective treatment for HS. We provide here consensus-based statements to guide physicians in the management of patients with HS, from diagnosis to treatment and follow-up, with an emphasis on the combination of biologic therapy and surgery (wide local excision). Combining therapeutic strategies is crucial for improving the effectiveness of HS treatment and for preventing severe and irreversible complications. Equally important for the proper management of HS, which is complicated by the presence of relevant comorbidities, is the involvement of a multidisciplinary team.

## Acknowledgments

Prof. Luca Vaianti, Prof. Alessandro Gatti, and Prof. Giovanna Malara were not available to confirm co-authorship, but the corresponding author Dr. Elisa Molinelli affirms that Prof. Luca

Vaianti, Prof. Alessandro Gatti, and Prof. Giovanna Malara contributed to the paper, had the opportunity to review the final version to be published, and guarantees Prof. Luca Vaianti, Prof. Alessandro Gatti, and Prof. Giovanna Malara co-authorship status and the accuracy of the author contribution and conflict of interest statements.

## Conflict of Interest Statement

Angelo Valerio Marzano reports consultancy/advisory boards disease-relevant honoraria from AbbVie, Boehringer-Ingelheim, Novartis, Pfizer, Sanofi, and UCB. Federico Contedini was a speaker and/or advisor for and/or has received research funding from Novartis, Lilly, Sanofi-Regeneron, AbbVie, LeoPharma, and Pfizer. The other authors have no conflicts of interest to declare.

## Funding Sources

This study and editorial assistance during manuscript preparation were funded by Novartis Farma, Italy. Editorial assistance in the preparation of this article was provided by Edra, Italy.

## Author Contributions

All named authors meet the International Committee of Medical Journal Editors (ICMJE) criteria for authorship for this article, take responsibility for the integrity of the work as a whole, and have given their approval for this version to be published. Annamaria Offidani, Angelo Valerio Marzano, and Ketty Peris: conceptualization, project administration, supervision, and writing – review and editing. Elisa Molinelli: conceptualization, supervision, data curation, and writing – review and editing. Vincenzo Bettoli, Andrea Chiricozzi, Cristina Magnoni, Francesca Prignano, and Luca Vaianti: data curation, methodology, and writing – review and editing. Giovanni Pappagallo: methodology, supervision, and formal analysis. Paolo Amerio, Laura Atzori, Anna Balato, Luca Bianchi, Maria Rita Bongiorno, Federico Contedini, Paolo Dapavo, Giovanni Di Benedetto, Valentina Dini, Massimo Donini, Gabriella Fabbrocini, Luca Fania, Caterina Foti, Alessandro Gatti, Claudio Guarneri, Giovanna Malara, Marco Manfredini, Pietro Morrone, Luigi Naldi, Aurora Parodi, Concetta Potenza, Sandra Schianchi, Luca Stingeni, Emanuele Trovato, Fabrizio Vaira, Mario Valenti, and Marina Venturini: methodology, data curation, and validation.

## Data Availability Statement

All data generated or analyzed during this study are included in the article. Further enquiries can be directed to the corresponding author.

## References

- Zouboulis CC, Benhadou F, Byrd AS, Chandran NS, Giamarellos-Bourboulis EJ, Fabbrocini G, et al. What causes hidradenitis suppurativa? 15 years after. *Exp Dermatol*. 2020;29(12):1154–70. <https://doi.org/10.1111/exd.14214>
- Nguyen TV, Damiani G, Orenstein LAV, Hamzavi I, Jemec GB. Hidradenitis suppurativa: an update on epidemiology, phenotypes, diagnosis, pathogenesis, comorbidities and quality of life. *J Eur Acad Dermatol Venereol*. 2021;35(1):50–61. <https://doi.org/10.1111/jdv.16677>
- Cazzaniga S, Pezzolo E, Bettoli V, Abeni D, Marzano AV, Patrizi A, et al. Characterization of hidradenitis suppurativa phenotypes: a multidimensional latent class analysis of the national Italian registry IRHIS. *J Invest Dermatol*. 2021;141(5):1236–42.e1. <https://doi.org/10.1016/j.jid.2020.08.032>
- Frew JW, Marzano AV, Wolk K, Join-Lambert O, Alavi A, Lowes MA, et al. A systematic review of promising therapeutic targets in hidradenitis suppurativa: a critical evaluation of mechanistic and clinical relevance. *J Invest Dermatol*. 2021;141(2):316–24.e2. <https://doi.org/10.1016/j.jid.2020.06.019>
- Zouboulis CC, Del Marmol V, Mrowietz U, Prens EP, Tzellos T, Jemec GB. Hidradenitis suppurativa/acne inversa: criteria for diagnosis, severity assessment, classification and disease evaluation. *Dermatology*. 2015;231(2):184–90. <https://doi.org/10.1159/000431175>
- von der Werth JM, Jemec GB. Morbidity in patients with hidradenitis suppurativa. *Br J Dermatol*. 2001;144(4):809–13. <https://doi.org/10.1046/j.1365-2133.2001.04137.x>
- Matusiak Ł, Bieniek A, Szepietowski JC. Hidradenitis suppurativa markedly decreases quality of life and professional activity. *J Am Acad Dermatol*. 2010;62(4):706–8.e1. <https://doi.org/10.1016/j.jaad.2009.09.021>
- Fabbrocini G, Ruina G, Giovanardi G, Dini V, Raone B, Venturini M, et al. Hidradenitis suppurativa in a large cohort of Italian patients: evaluation of the burden of disease. *Dermatology*. 2022;238(3):487–97. <https://doi.org/10.1159/000517412>
- Saunte DM, Boer J, Stratigos A, Szepietowski JC, Hamzavi I, Kim KH, et al. Diagnostic delay in hidradenitis suppurativa is a global problem. *Br J Dermatol*. 2015;173(6):1546–9. <https://doi.org/10.1111/bjd.14038>
- Garg A, Neuren E, Cha D, Kirby JS, Ingram JR, Jemec GBE, et al. Evaluating patients' unmet needs in hidradenitis suppurativa: results from the global survey of impact and healthcare needs (VOICE) project. *J Am Acad Dermatol*. 2020;82(2):366–76. <https://doi.org/10.1016/j.jaad.2019.06.1301>
- Bettoli V, Pasquinucci S, Caracciolo S, Piccolo D, Cazzaniga S, Fantini F, et al. The Hidradenitis suppurativa patient journey in Italy: current status, unmet needs and opportunities. *J Eur Acad Dermatol Venereol*. 2016;30(11):1965–70. <https://doi.org/10.1111/jdv.13687>
- Orenstein LAV, Nguyen TV, Damiani G, Sayed C, Jemec GBE, Hamzavi I. Medical and surgical management of hidradenitis suppurativa: a review of international treatment guidelines and implementation in general dermatology practice. *Dermatology*. 2020;236(5):393–412. <https://doi.org/10.1159/000507323>
- Hendricks AJ, Hsiao JL, Lowes MA, Shi VY. A comparison of international management guidelines for hidradenitis suppurativa. *Dermatology*. 2021;237(1):81–96. <https://doi.org/10.1159/000503605>
- Gulliver W, Zouboulis CC, Prens E, Jemec GB, Tzellos T. Evidence-based approach to the treatment of hidradenitis suppurativa/acne inversa, based on the European guidelines for hidradenitis suppurativa. *Rev Endocr Metab Disord*. 2016;17(3):343–51. <https://doi.org/10.1007/s11154-016-9328-5>
- Alikhan A, Sayed C, Alavi A, Alhusayen R, Brassard A, Burkhart C, et al. North American clinical management guidelines for hidradenitis suppurativa: a publication from the United States and Canadian Hidradenitis Suppurativa Foundations: Part I: diagnosis, evaluation, and the use of complementary and procedural management. *J Am Acad Dermatol*. 2019;81(1):76–90. <https://doi.org/10.1016/j.jaad.2019.02.067>
- Alikhan A, Sayed C, Alavi A, Alhusayen R, Brassard A, Burkhart C, et al. North American clinical management guidelines for hidradenitis suppurativa: a publication from the United States and Canadian Hidradenitis Suppurativa Foundations: Part II: topical, intralesional, and systemic medical management. *J Am Acad Dermatol*. 2019;81(1):91–101. <https://doi.org/10.1016/j.jaad.2019.02.068>
- Zouboulis CC, Bechara FG, Dickinson-Blok JL, Gulliver W, Horváth B, Hughes R, et al. Hidradenitis suppurativa/acne inversa: a practical framework for treatment optimization—systematic review and recommendations from the HS ALLIANCE working group. *J Eur Acad Dermatol Venereol*. 2019;33(1):19–31. <https://doi.org/10.1111/jdv.15233>
- Maronese CA, Moltrasio C, Genovese G, Marzano AV. Biologics for Hidradenitis suppurativa: evolution of the treatment paradigm. *Expert Rev Clin Immunol*. 2023;22:1–21.
- DeFazio MV, Economides JM, King KS, Han KD, Shanmugam VK, Attinger CE, et al. Outcomes after combined radical resection and targeted biologic therapy for the management of recalcitrant hidradenitis suppurativa. *Ann Plast Surg*. 2016;77(2):217–22. <https://doi.org/10.1097/SAP.0000000000000584>
- Kimball AB, Kerdel F, Adams D, Mrowietz U, Gelfand JM, Gnaniadecki R, et al. Adalimumab for the treatment of moderate to severe Hidradenitis suppurativa: a parallel randomized trial. *Ann Intern Med*. 2012;157(12):846–55. <https://doi.org/10.7326/0003-4819-157-12-201212180-00004>
- Kimball AB, Okun MM, Williams DA, Gottlieb AB, Papp KA, Zouboulis CC, et al. Two phase 3 trials of adalimumab for hidradenitis suppurativa. *N Engl J Med*. 2016;375(5):422–34. <https://doi.org/10.1056/NEJMoa1504370>
- Van Rappard DC, Mekkes JR. Treatment of severe hidradenitis suppurativa with infliximab in combination with surgical interventions. *Br J Dermatol*. 2012;167(1):206–8. <https://doi.org/10.1111/j.1365-2133.2012.10807.x>
- Shanmugam VK, Mulani S, McNish S, Harris S, Buescher T, Amdur R. Longitudinal observational study of hidradenitis suppurativa: impact of surgical intervention with adjunctive biologic therapy. *Int J Dermatol*. 2018;57(1):62–9. <https://doi.org/10.1111/ijd.13798>
- Bechara FG, Podda M, Prens EP, Horváth B, Giamarellos-Bourboulis EJ, Alavi A, et al. Efficacy and safety of adalimumab in conjunction with surgery in moderate to severe hidradenitis suppurativa: the SHARPS randomized clinical trial. *JAMA Surg*. 2021;156(11):1001–9. <https://doi.org/10.1001/jamasurg.2021.3655>
- Gustafson DH, Shukla RK, Delbecq A, Walster GW. A comparative study of differences in subjective likelihood estimates made by individuals, interacting groups, Delphi groups, and nominal groups. *Organ Behav Hum Perform*. 1973;9(2):280–91. [https://doi.org/10.1016/0030-5073\(73\)90052-4](https://doi.org/10.1016/0030-5073(73)90052-4)
- Rowe G, Wright G. Expert opinions in forecasting: role of the Delphi technique. In: Armstrong JS, editor. *Principles of forecasting*. Norwell, MA: Kluwer Academic Press; 2001.
- Jones J, Hunter D. Consensus methods for medical and health services research. *BMJ*. 1995;311(7001):376–80. <https://doi.org/10.1136/bmj.311.7001.376>
- Kaplan MF. The influencing process in group decision making. In: Hendrick C, editor. *Review of personality and social psychology, group processes*. Sage Publications, Inc; 1987. p. 189–212.
- Fitch K, Bernstein SJ, Aguilar MD, Burnand B, LaCalle JR, Lazaro P, et al. The RAND/UCLA appropriateness method User's manual. RAND Corporation; 2001. Available from: [https://www.rand.org/pubs/monograph\\_reports/MR1269.html](https://www.rand.org/pubs/monograph_reports/MR1269.html)
- Martorell A, Wortsman X, Alfageme F, Roustán G, Arias-Santiago S, Catalano O, et al. Ultrasound evaluation as a complementary test in hidradenitis suppurativa: proposal of a standardized report. *Dermatol Surg*. 2017;43(8):1065–73. <https://doi.org/10.1097/DSS.0000000000001147>

- 31 Nazzaro G, Moltrasio C, Marzano AV. Infrared thermography and color Doppler: two combined tools for assessing inflammation in hidradenitis suppurativa. *Skin Res Technol*. 2020;26(1):140–1. <https://doi.org/10.1111/srt.12750>
- 32 Chiricozzi A, Giovanardi G, Garcovich S, Malvaso D, Caldarola G, Fossati B, et al. Clinical and ultrasonographic profile of adalimumab-treated hidradenitis suppurativa patients: a real-life monocentric experience. *Acta Derm Venereol*. 2020;100(13):adv00172. <https://doi.org/10.2340/00015555-3520>
- 33 Zouboulis CC, Nogueira da Costa A, Jemec GBE, Trebing D. Long-wave medical infrared thermography: a clinical biomarker of inflammation in hidradenitis suppurativa/acne inversa. *Dermatology*. 2019;235(2):144–9. <https://doi.org/10.1159/000495982>
- 34 Derruau S, Renard Y, Pron H, Taiar R, Abdi E, Polidori G, et al. Combining Magnetic Resonance Imaging (MRI) and Medical Infrared Thermography (MIT) in the pre- and peri-operating management of severe Hidradenitis Suppurativa (HS). *Photodiagnosis Photodyn Ther*. 2018;23:9–11. <https://doi.org/10.1016/j.pdpdt.2018.05.007>
- 35 Wortsman X, Castro A, Figueroa A. Color Doppler ultrasound assessment of morphology and types of fistulous tracts in Hidradenitis Suppurativa (HS). *J Am Acad Dermatol*. 2016;75(4):760–7. <https://doi.org/10.1016/j.jaad.2016.05.009>
- 36 Nazzaro G, Calzari P, Passoni E, Vaianti S, Moltrasio C, Barbareschi M, et al. Vascularization and fibrosis are important ultrasonographic tools for assessing response to adalimumab in hidradenitis suppurativa: prospective study of 32 patients. *Dermatol Ther*. 2021;34(1):e14706. <https://doi.org/10.1111/dth.14706>
- 37 Jabbari Lak F, Mazinani M, Heverhagen JT, Hunger RE, Daneshvar K, Seyed Jafari SM. Non-contrast-enhanced 3-tesla magnetic resonance imaging using surface-coil and sonography for assessment of hidradenitis suppurativa lesions. *Acta Derm Venereol*. 2020;100(18):adv00317. <https://doi.org/10.2340/00015555-3639>
- 38 Hurley H. Axillary hyperhidrosis, apocrine bromhidrosis, hidradenitis suppurativa, and familial benign pemphigus: surgical approach. In: Roenigk RK, Roenigk Jr HK, editors. *Dermatologic surgery*. New York: Marcel Dekker; 1989. p. 729–39.
- 39 Horváth B, Janse ICJ, Blok JL, Driessen RJB, Boer J, Mekkes JR, et al. Hurley staging refined: a proposal by the Dutch hidradenitis suppurativa expert group. *Acta Derm Venereol*. 2017;97(3):412–3. <https://doi.org/10.2340/00015555-2513>
- 40 Zouboulis CC, Tzellos T, Kyrgidis A, Jemec GBE, Bechara FG, Giamarellos-Bourboulis EJ, et al. Development and validation of the International Hidradenitis Suppurativa Severity Score System (IHS4), a novel dynamic scoring system to assess HS severity. *Br J Dermatol*. 2017;177(5):1401–9. <https://doi.org/10.1111/bjd.15748>
- 41 Kimball AB, Jemec GB, Yang M, Kageleiry A, Signorovitch JE, Okun MM, et al. Assessing the validity, responsiveness and meaningfulness of the Hidradenitis Suppurativa Clinical Response (HiSCR) as the clinical endpoint for hidradenitis suppurativa treatment. *Br J Dermatol*. 2014;171(6):1434–42. <https://doi.org/10.1111/bjd.13270>
- 42 Tzellos T, van Straalen KR, Kyrgidis A, Alavi A, Goldfarb N, Gulliver W, et al. Development and validation of IHS4-55, an IHS4 dichotomous outcome to assess treatment effect for hidradenitis suppurativa. *J Eur Acad Dermatol Venereol*. 2023;37(2):395–401. <https://doi.org/10.1111/jdv.18632>
- 43 van Straalen KR, Tzellos T, Alavi A, Benhadou F, Cuenca-Barrales C, Daxhelet M, et al. External validation of the IHS4-55 in a European antibiotic-treated hidradenitis suppurativa cohort. *Dermatology*. 2023;239(3):362–7. <https://doi.org/10.1159/000528968>
- 44 Hamzavi IH, Sundaram M, Nicholson C, Zivkovic M, Parks-Miller A, Lee J, et al. Uncovering burden disparity: a comparative analysis of the impact of moderate-to-severe psoriasis and hidradenitis suppurativa. *J Am Acad Dermatol*. 2017;77(6):1038–46. <https://doi.org/10.1016/j.jaad.2017.07.027>
- 45 Finlay AY, Khan GK. *Dermatology Life Quality Index (DLQI): a simple practical measure for routine clinical use*. *Clin Exp Dermatol*. 1994;19(3):210–6. <https://doi.org/10.1111/j.1365-2230.1994.tb01167.x>
- 46 Peris K, Lo Schiavo A, Fabbrocini G, Dini V, Patrizi A, Fusano M, et al. HIDRADisk: validation of an innovative visual tool to assess the burden of hidradenitis suppurativa. *J Eur Acad Dermatol Venereol*. 2019;33(4):766–73. <https://doi.org/10.1111/jdv.15425>
- 47 Kirby JS, Thorlacius L, Villumsen B, Ingram JR, Garg A, Christensen KB, et al. The Hidradenitis Suppurativa Quality of Life (HiSQOL) score: development and validation of a measure for clinical trials. *Br J Dermatol*. 2020;183(2):340–8. <https://doi.org/10.1111/bjd.18692>
- 48 Otten M, Augustin M, Blome C, Topp J, Niklaus M, Hilbring C, et al. Measuring quality of life in hidradenitis suppurativa: development and validation of a disease-specific patient-reported outcome measure for practice and research. *Acta Derm Venereol*. 2023;103:adv00859. <https://doi.org/10.2340/actadv.v102.2485>
- 49 Matusiak Ł, Szczech J, Kaaz K, Lelonek E, Szepietowski JC. Clinical characteristics of pruritus and pain in patients with hidradenitis suppurativa. *Acta Derm Venereol*. 2018;98(2):191–4. <https://doi.org/10.2340/00015555-2815>
- 50 Tzellos T, Zouboulis CC. Which hidradenitis suppurativa comorbidities should I take into account? *Exp Dermatol*. 2022;31(Suppl 1):29–32. <https://doi.org/10.1111/exd.14633>
- 51 Garg A, Malviya N, Strunk A, Wright S, Alavi A, Alhusayen R, et al. Comorbidity screening in hidradenitis suppurativa: evidence-based recommendations from the US and Canadian hidradenitis suppurativa Foundations. *J Am Acad Dermatol*. 2022;86(5):1092–101. <https://doi.org/10.1016/j.jaad.2021.01.059>
- 52 Pinter A, Sarlak M, Zeiner KN, Malisiewicz B, Kaufmann R, Romanelli M, et al. Co-prevalence of hidradenitis suppurativa and psoriasis: detailed demographic disease severity and comorbidity pattern. *Dermatology*. 2021;237(5):759–68. <https://doi.org/10.1159/000511868>
- 53 Chawla S, Toale C, Morris M, Tobin AM, Kavanagh D. Surgical management of hidradenitis suppurativa: a narrative review. *J Clin Aesthet Dermatol*. 2022;15(1):35–41.
- 54 Taylor EM, Hamaguchi R, Kramer KM, Kimball AB, Orgill DP. Plastic surgical management of hidradenitis suppurativa. *Plast Reconstr Surg*. 2021;147(3):479–91. <https://doi.org/10.1097/PRS.00000000000007677>
- 55 Riddle A, Westerkam L, Feltner C, Sayed C. Current surgical management of hidradenitis suppurativa: a systematic review and meta-analysis. *Dermatol Surg*. 2021;47(3):349–54. <https://doi.org/10.1097/DSS.0000000000002892>
- 56 Shukla R, Karagaiah P, Patil A, Farnbach K, Ortega-Loayza AG, Tzellos T, et al. Surgical treatment in hidradenitis suppurativa. *J Clin Med*. 2022;11(9):2311. <https://doi.org/10.3390/jcm11092311>
- 57 Mehdizadeh A, Hazen PG, Bechara FG, Zwingerman N, Moazenzadeh M, Bashash M, et al. Recurrence of hidradenitis suppurativa after surgical management: a systematic review and meta-analysis. *J Am Acad Dermatol*. 2015;73(5 Suppl 1):S70–7. <https://doi.org/10.1016/j.jaad.2015.07.044>
- 58 Ocker L, Racher NB, Seifert C, Scheel C, Bechara FG. Current medical and surgical treatment of hidradenitis suppurativa: a comprehensive review. *J Clin Med*. 2022;11(23):7240. <https://doi.org/10.3390/jcm11237240>
- 59 Manfredini M, Garbarino F, Bigi L, Pellacani G, Magnoni C. Hidradenitis suppurativa: surgical and postsurgical management. *Skin Appendage Disord*. 2020;6(4):195–201. <https://doi.org/10.1159/000507297>
- 60 Danby WF, Hazen PG, Boer J. New and traditional surgical approaches to hidradenitis suppurativa. *J Am Acad Dermatol*. 2015;73(5 Suppl 1):S62–5. <https://doi.org/10.1016/j.jaad.2015.07.043>
- 61 Menderes A, Sunay O, Vayvada H, Yilmaz M. Surgical management of hidradenitis suppurativa. *Int J Med Sci*. 2010;7(4):240–7. <https://doi.org/10.7150/ijms.7.240>
- 62 Humphries LS, Kueberuwa E, Beederman M, Gottlieb LJ. Wide excision and healing by secondary intent for the surgical treatment of hidradenitis suppurativa: a single-center experience. *J Plast Reconstr Aesthet Surg*. 2016;69(4):554–66. <https://doi.org/10.1016/j.bjps.2015.12.004>

- 63 van Rappard DC, Mooij JE, Mekkes JR. Mild to moderate hidradenitis suppurativa treated with local excision and primary closure. *J Eur Acad Dermatol Venereol.* 2012;26(7):898–902. <https://doi.org/10.1111/j.1468-3083.2011.04203.x>
- 64 Adalimumab EMA summary of Product characteristics. Available from: [https://www.ema.europa.eu/en/documents/product-information/humira-epar-product-information\\_en.pdf](https://www.ema.europa.eu/en/documents/product-information/humira-epar-product-information_en.pdf)
- 65 Kimball AB, Jemec GBE, Alavi A, Reguiat Z, Gottlieb AB, Bechara FG, et al. Secukinumab in moderate-to-severe hidradenitis suppurativa (SUNSHINE and SUNRISE): week 16 and week 52 results of two identical, multi-centre, randomised, placebo-controlled, double-blind phase 3 trials. *Lancet.* 2023; 401(10378):747–61. [https://doi.org/10.1016/S0140-6736\(23\)00022-3](https://doi.org/10.1016/S0140-6736(23)00022-3)
- 66 Lim SYD, Cheong EC, Oon HH. Management of severe hidradenitis suppurativa with biologic therapy and wide excision. *Arch Plast Surg.* 2019;46(3):272–6. <https://doi.org/10.5999/aps.2018.00339>
- 67 Glatt S, Jemec GBE, Forman S, Sayed C, Schmieder G, Weisman J, et al. Efficacy and safety of bimekizumab in moderate to severe hidradenitis suppurativa: a phase 2, double-blind, placebo-controlled randomized clinical trial. *JAMA Dermatol.* 2021;157(11):1279–88. <https://doi.org/10.1001/jamadermatol.2021.2905>
- 68 Kimball AB, Loesche C, Prens EP, Bechara FG, Weisman J, Rozenberg I, et al. IL-17A is a pertinent therapeutic target for moderate-to-severe hidradenitis suppurativa: combined results from a pre-clinical and phase II proof-of-concept study. *Exp Dermatol.* 2022;31(10):1522–32. <https://doi.org/10.1111/exd.14619>
- 69 Zouboulis CC, Frew JW, Giamarellos-Bourboulis EJ, Jemec GBE, Del Marmol V, Marzano AV, et al. Target molecules for future hidradenitis suppurativa treatment. *Exp Dermatol.* 2021;30(Suppl 1):8–17. <https://doi.org/10.1111/exd.14338>
- 70 Lim SYD, Oon HH. Systematic review of immunomodulatory therapies for hidradenitis suppurativa. *Biologics.* 2019;13:53–78. <https://doi.org/10.2147/BTT.S199862>
- 71 Benassaia E, Boccarda D, Mimoun M, Chaouat M, Hotz C, Bachelez H, et al. Infliximab treatment before and after surgery in severe hidradenitis suppurativa: a retrospective study of 10 patients. *Ann Dermatol Venereol.* 2022;149(3):195–7. <https://doi.org/10.1016/j.annder.2021.07.012>
- 72 Zouboulis CC, Okun MM, Prens EP, Gniedeki R, Foley PA, Lynde C, et al. Long-term adalimumab efficacy in patients with moderate-to-severe hidradenitis suppurativa/acne inversa: 3-year results of a phase 3 open-label extension study. *J Am Acad Dermatol.* 2019;80(1):60–9.e2. <https://doi.org/10.1016/j.jaad.2018.05.040>
- 73 Davis JS, Ferreira D, Paige E, Gedye C, Boyle M. Infectious complications of biological and small molecule targeted immunomodulatory therapies. *Clin Microbiol Rev.* 2020;33(3):e00035–19. <https://doi.org/10.1128/CMR.00035-19>
- 74 Kerrigan N. Joint guidelines for the management of interruption of biologic therapies for elective surgery in adults and children with rheumatoid arthritis, Psoriatic Arthritis, JIA and Ankylosing Spondylitis. Version: 5. Available from: <https://www.nnuh.nhs.uk/publication/download/interruption-of-biologic-therapy-jcg0030-v5/>
- 75 Ederle A, Harrell K, Collins L. Perioperative management of biologics: to have or to hold. *Dermatol Surg.* 2022;48(1):145–6. <https://doi.org/10.1097/DSS.0000000000003290>
- 76 Kasperek MS, Bruckmeier A, Beigel F, Müller MH, Brand S, Mansmann U, et al. Infliximab does not affect postoperative complication rates in Crohn's patients undergoing abdominal surgery. *Inflamm Bowel Dis.* 2012;18(7):1207–13. <https://doi.org/10.1002/ibd.21860>
- 77 Bakkour W, Pursell H, Chinoy H, Griffiths CE, Warren RB. The risk of post-operative complications in psoriasis and psoriatic arthritis patients on biologic therapy undergoing surgical procedures. *J Eur Acad Dermatol Venereol.* 2016;30(1):86–91. <https://doi.org/10.1111/jdv.12997>
- 78 Müller CS, Hubner W, Thieme-Ruffing S, Pfohler C, Vogt T, Volk T, et al. Pre- and perioperative aspects of dermatosurgery. *J Dtsch Dermatol Ges.* 2017;15(2):117–46. <https://doi.org/10.1111/ddg.13181>
- 79 Join-Lambert O, Coignard-Biehler H, Jais JP, Delage M, Guet-Revillet H, Poirée S, et al. Efficacy of ertapenem in severe hidradenitis suppurativa: a pilot study in a cohort of 30 consecutive patients. *J Antimicrob Chemother.* 2016;71(2):513–20. <https://doi.org/10.1093/jac/dkv361>
- 80 van Straalen KR, Tzellos T, Guillem P, Benhadou F, Cuenca-Barrales C, Daxhelet M, et al. The efficacy and tolerability of tetracyclines and clindamycin plus rifampicin for the treatment of hidradenitis suppurativa: results of a prospective European cohort study. *J Am Acad Dermatol.* 2021;85(2):369–78. <https://doi.org/10.1016/j.jaad.2020.12.089>
- 81 Molinelli E, Sapigni C, D'Agostino GM, Brisgotti V, Rizzetto G, Bobyr I, et al. The effect of dalbavancin in moderate to severe hidradenitis suppurativa. *Antibiotics.* 2022;11(11):1573. <https://doi.org/10.3390/antibiotics11111573>
- 82 Nikolakis G, Kaleta KP, Vaiopoulos AG, Wolter K, Baroud S, Wojas-Pelc A, et al. Phenotypes and pathophysiology of syndromic hidradenitis suppurativa: different faces of the same disease? A systematic review. *Dermatology.* 2021;237(5):673–97. <https://doi.org/10.1159/000509873>
- 83 Bettoli V, Manfredini M, Massoli L, Carillo C, Barozzi A, Amendolagine G, et al. Rates of antibiotic resistance/sensitivity in bacterial cultures of hidradenitis suppurativa patients. *J Eur Acad Dermatol Venereol.* 2019;33(5):930–6. <https://doi.org/10.1111/jdv.15332>
- 84 Marzano AV, Genovese G, Casazza G, Moltrasio C, Dapavo P, Micali G, et al. Evidence for a “window of opportunity” in hidradenitis suppurativa treated with adalimumab: a retrospective, real-life multicentre cohort study. *Br J Dermatol.* 2021;184(1):133–40. <https://doi.org/10.1111/bjd.18983>
- 85 Garcovich S, De Simone C, Genovese G, Berti E, Cugno M, Marzano AV. Paradoxical skin reactions to biologics in patients with rheumatologic disorders. *Front Pharmacol.* 2019;10:282. <https://doi.org/10.3389/fphar.2019.00282>
- 86 Burzi L, Repetto F, Ribero S, Mastorino L, Quaglino P, Dapavo P. Paradoxical psoriasiform reactions during treatment with adalimumab for hidradenitis suppurativa: real-life experience and therapeutic response to other biological drugs. *Dermatol Ther.* 2022;35(12):e15866. <https://doi.org/10.1111/dth.15866>
- 87 Rompel R, Petres J. Long-term results of wide surgical excision in 106 patients with hidradenitis suppurativa. *Dermatol Surg.* 2000;26(7):638–43. <https://doi.org/10.1046/j.1524-4725.2000.00043.x>
- 88 Jefferson IS, Fritsche M, Maczuga SA, Allen SR, Nelson A, Kirby JS. Patients with hidradenitis suppurativa have a higher rate of postoperative infections. *J Am Acad Dermatol.* 2023;88(3):705–8. <https://doi.org/10.1016/j.jaad.2022.08.059>