

# Imaging-guided interventions modulating portal venous flow: Evidence and controversies



Roberto Cannella,<sup>1,2,3</sup> Lambros Tselikas,<sup>4,5,6</sup> Frédéric Douane,<sup>7</sup> François Cauchy,<sup>8</sup> Pierre-Emmanuel Rautou,<sup>9</sup> Rafael Duran,<sup>10</sup> Maxime Ronot<sup>1,\*</sup>

## Summary

**Portal hypertension is defined by an increase in the portosystemic venous gradient. In most cases, increased resistance to portal blood flow is the initial cause of elevated portal pressure. More than 90% of cases of portal hypertension are estimated to be due to advanced chronic liver disease or cirrhosis. Transjugular intrahepatic portosystemic shunts, a non-pharmacological treatment for portal hypertension, involve the placement of a stent between the portal vein and the hepatic vein or inferior vena cava which helps bypass hepatic resistance. Portal hypertension may also be a result of extrahepatic portal vein thrombosis or compression. In these cases, percutaneous portal vein recanalisation restores portal trunk patency, thus preventing portal hypertension-related complications. Any portal blood flow impairment leads to progressive parenchymal atrophy and triggers hepatic regeneration in preserved areas. This provides the rationale for using portal vein embolisation to modulate hepatic volume in preparation for extended hepatic resection. The aim of this paper is to provide a comprehensive evidence-based review of the rationale for, and outcomes associated with, the main imaging-guided interventions targeting the portal vein, as well as to discuss the main controversies around such approaches.**

© 2022 The Authors. Published by Elsevier B.V. on behalf of European Association for the Study of the Liver (EASL). This is an open access article under the CC BY-NC-ND license (<http://creativecommons.org/licenses/by-nc-nd/4.0/>).

## Introduction

The portal vein carries approximately 75% of total liver blood flow, explaining why portal blood flow is so important for sustaining hepatic physiology, or the total volume of functional hepatic parenchyma. Any portal blood flow impairment leads to progressive parenchymal atrophy and triggers a compensatory hepatic regeneration – and therefore volume increase – in preserved areas. This provides a robust rationale for modulating hepatic volume by portal vein occlusion to prepare for extended hepatic resection.

Portal hypertension (PH) corresponds to an increase in the portosystemic venous gradient as a result of an increase in splanchnic venous pressure.<sup>1</sup> In most clinical situations, an increase in resistance to portal blood flow – either prehepatic, intrahepatic, or post-hepatic – is the initial cause of elevated portal pressure. More than 90% of PH cases are estimated to be due to advanced chronic liver disease or cirrhosis and the resulting combination of fibrosis deposition, liver parenchymal extinction, and regeneration. When portal pressure is above a certain threshold (>10 mmHg), portosystemic shunts and complications develop, including upper digestive bleeding, ascites, spontaneous bacterial peritonitis, hepatorenal syndrome and hepatic encephalopathy (HE).<sup>2</sup>

Treatment of PH includes a wide spectrum of pharmacological and non-pharmacological options to lower portal pressure. One such option – a so-called transjugular intrahepatic portosystemic shunt (TIPS) – involves the placement of a stent graft in the hepatic parenchyma to create a shunt between the portal vein and the hepatic vein or the inferior vena cava and hence bypass hepatic resistance.

PH may also be a result of extrahepatic portal vein thrombosis or compression. The development of venous collaterals – e.g. portal cavernous transformation – partially compensates for the decrease in portal blood flow and helps lower splanchnic venous pressure. However, this is usually insufficient over time and patients may experience PH-related complications. The goal of percutaneous portal vein recanalisation (PVR) and stenting is to treat these complications by restoring the patency of the portal venous system.

The aim of this article is to discuss the 3 main portal vein imaging-guided interventions, namely TIPS, PVR and PVE by providing a comprehensive evidence-based review of the rationale, main technical considerations, evidence of effectiveness and potential complications. The current controversies around these imaging-guided portal venous interventions will also be addressed.

**Keywords:** Portal vein interventions; image guided; transjugular intrahepatic portosystemic shunt; portal vein recanalization; portal vein embolization; portal hypertension

Received 30 November 2021; received in revised form 23 March 2022; accepted 25 March 2022; available online 4 April 2022

<sup>1</sup>Université Paris Cité ; AP-HP, Hôpital Beaujon, Service de Radiologie, Clichy; Centre de Recherche sur l'inflammation Inserm, UMR 1149, Paris, France; <sup>2</sup>Section of Radiology - Department of Biomedicine, Neuroscience and Advanced Diagnostics (BiND), University Hospital "Paolo Giaccone", Via del Vespro 129, 90127 Palermo, Italy; <sup>3</sup>Department of Health Promotion Sciences Maternal and Infant Care, Internal Medicine and Medical Specialties, PROMISE, University of Palermo, 90127 Palermo, Italy; <sup>4</sup>Department of Anesthesiology, Surgery and Interventional radiology, Gustave Roussy, Villejuif, France; <sup>5</sup>Biotheris, CIC 1428 Inserm, Gustave Roussy, Villejuif, France; <sup>6</sup>Université Paris – Saclay, Saint Aubin, France; <sup>7</sup>Service de Radiologie, CHU Nantes, Nantes, France; <sup>8</sup>Université Paris Cité ; AP-HP, Hôpital Beaujon, Service de Chirurgie HBP, Clichy, France; <sup>9</sup>Université Paris Cité, AP-HP, Hôpital Beaujon, Service d'Hépatologie, DMU DIGEST, Centre de Référence des Maladies Vasculaires du Foie, FILFOIE, ERN RARE-LIVER, Centre de Recherche sur

*l'inflammation Inserm, UMR 1149, Paris, France;* <sup>10</sup>*Department of Diagnostic and Interventional Radiology, Centre Hospitalier Universitaire Vaudois (CHUV) and University of Lausanne, Lausanne, Switzerland*

· Corresponding author. Address: Hôpital Beaujon, 100 boulevard du Général Leclerc, 92119 Clichy, France; Tel.: +33 1 40 87 55 66, fax: +33 1 40 87 05 48. E-mail address: [maxime.ronot@aphp.fr](mailto:maxime.ronot@aphp.fr) (M. Ronot).

## Transjugular intrahepatic portosystemic shunt

### Rationale and indications

Careful patient selection is critical before TIPS placement, since the procedure is technically challenging and may result in deterioration of hepatic function and complications in patients with advanced chronic liver disease, which must be considered in relation to the expected clinical benefits of this treatment.

The American Association for The Study of Liver Disease practice guidelines on the role of TIPS in the management of portal hypertension,<sup>3</sup> European Association for the Study of Liver (EASL) guidelines for the management of decompensated cirrhosis,<sup>4</sup> British Society of Gastroenterology (BSG) TIPS guidelines,<sup>5</sup> and the Baveno VII consensus update<sup>6</sup> all recommend TIPS as second-line therapy for the complications of PH (Table 1).

Refractory ascites is the most common indication for TIPS.<sup>3–7</sup> TIPS is also recommended in patients with variceal bleeding for 3 main reasons: i) rescue therapy (salvage TIPS) in refractory variceal bleeding that does not respond to endoscopic and medical treatment; ii) secondary prevention of rebleeding in high-risk patients after initial endoscopic and pharmacological therapies (pre-emptive TIPS); iii) rebleeding despite optimal secondary prophylaxis.<sup>3–6</sup> In particular, pre-emptive TIPS is recommended in patients with Child-Pugh C cirrhosis with a score <14 by EASL guidelines, and Child-Pugh C or model for end-stage liver disease (MELD) score ≥19 by BSG guidelines.<sup>4,5</sup> Furthermore, the Baveno VII consensus on portal hypertension recommend pre-emptive TIPS in patients with Child-Pugh C cirrhosis and a score <14 and or Child-Pugh class B >7 with active bleeding at initial endoscopy or hepatic venous pressure gradient >20 mmHg at the time of haemorrhage.<sup>6</sup> TIPS is currently not recommended for the primary prevention of variceal bleeding since no clinical trials have compared TIPS to other therapies in these patients and because the high rate of HE and known procedural risks could outweigh the risk of variceal haemorrhage in patients without a history of bleeding.

The indications for TIPS are rapidly being extended to the treatment of symptomatic ectopic varices, hepatic hydrothorax, hepatorenal syndrome, Budd-Chiari syndrome, portal vein thrombosis, and non-cirrhotic PH, although randomised controlled trials (RCTs) are still needed for these indications.

The contraindications of TIPS are summarised in Table 1. In particular, cardiac dysfunction and severe pulmonary hypertension should be excluded before performing TIPS to avoid cardiac overload from the increase in blood volume in the right atrium.<sup>3,5</sup> The patency of the hepatic veins, the inferior vena cava, and the portal vein, as well as anatomical variants, should be evaluated before the procedure, as they are relative contraindications in patients with cirrhosis.

### Technical considerations

The TIPS procedure is safe when performed by experts. The high reported rate of technical success, which is more than 95%, and

### Key points

- There are 3 main clinical indications for TIPS: refractory ascites, secondary prophylaxis of variceal rebleeding in high-risk patients, and uncontrolled variceal haemorrhage.
- Portal vein recanalisation is performed to treat portal vein thrombosis in liver transplant recipients, and to manage the complications of cavernous transformation, acute thrombosis and portal vein stenosis (due to extrinsic compression or postoperative stenosis).
- For patients with insufficient future liver remnant, portal vein embolisation can be used to increase the number of candidates amenable to surgical resection and to prevent postoperative complications.
- Despite progress in the management of patients, controversies remain for several clinical scenarios.
- Further studies are needed to address specific controversies and to support future evidence-based recommendations.

the low rate of major intra-procedural complications, correspond to those in experienced tertiary centres.<sup>8,9</sup>

A detailed description of the TIPS procedure (Fig. 1) has been reported and is not the purpose of this review.<sup>10,11</sup> The exact procedure may vary according to patient characteristics and institutional preferences, with the possibility of using a trans-splenic approach (in patients where the portal vein approach has failed), or a direct intrahepatic portacaval shunt in adjunct or instead of the conventional TIPS technique.<sup>10,12</sup> Initial experiences were also reported with endoscopic puncture of the portal vein for portal venous pressure measurement.<sup>13</sup> The portosystemic pressure gradient is usually measured before TIPS placement and haemodynamic success is assessed by a reduction in the portosystemic pressure gradient to below 12 mmHg or >20% below baseline.<sup>14</sup> Different types of stents have been used over time. Expanded polytetrafluoroethylene-covered stents represent the current standard of care and have significantly improved stent patency and lowered the rate of TIPS revisions compared to uncovered stents.<sup>15,16</sup>

### Results and evidence

Most clinical studies and RCTs have focused on 3 main clinical applications of TIPS: refractory ascites, secondary prophylaxis of variceal bleeding, and uncontrolled variceal haemorrhage.

#### Ascites

Recommendations on TIPS for refractory ascites are supported by strong evidence, including 7 prospective RCTs and 7 meta-analyses.<sup>17,18</sup> Data consistently report a lower rate of recurrent ascites (42% in the patients treated with TIPS) than in patients managed by repeated large volume paracentesis (89%).<sup>19</sup> Although large volume paracentesis rapidly relieves abdominal tension, it does not treat the cause, and therefore cannot prevent recurrent ascites, while TIPS lowers elevated sinusoidal pressure, which contributes to the formation of ascites.<sup>18</sup> Nevertheless, the improved efficacy of TIPS compared to large volume paracentesis for refractory ascites should be balanced against a higher rate and severity of HE and its possible contraindications in patients with advanced liver disease.<sup>17</sup> Moreover, the real benefit to survival following TIPS for refractory ascites is still a subject of debate and optimal patient selection remains the key to improve survival.<sup>7</sup> Bureau *et al.* identified platelet count over 75x10<sup>9</sup>/L and bilirubin below 50 μmol/L as predictors of improved survival in patients with refractory ascites treated with TIPS.<sup>20</sup>

### Bleeding

The recommendations for TIPS as salvage therapy in refractory variceal bleeding or in patients with rebleeding have been supported by several prospective studies and meta-analyses.<sup>21,22</sup>

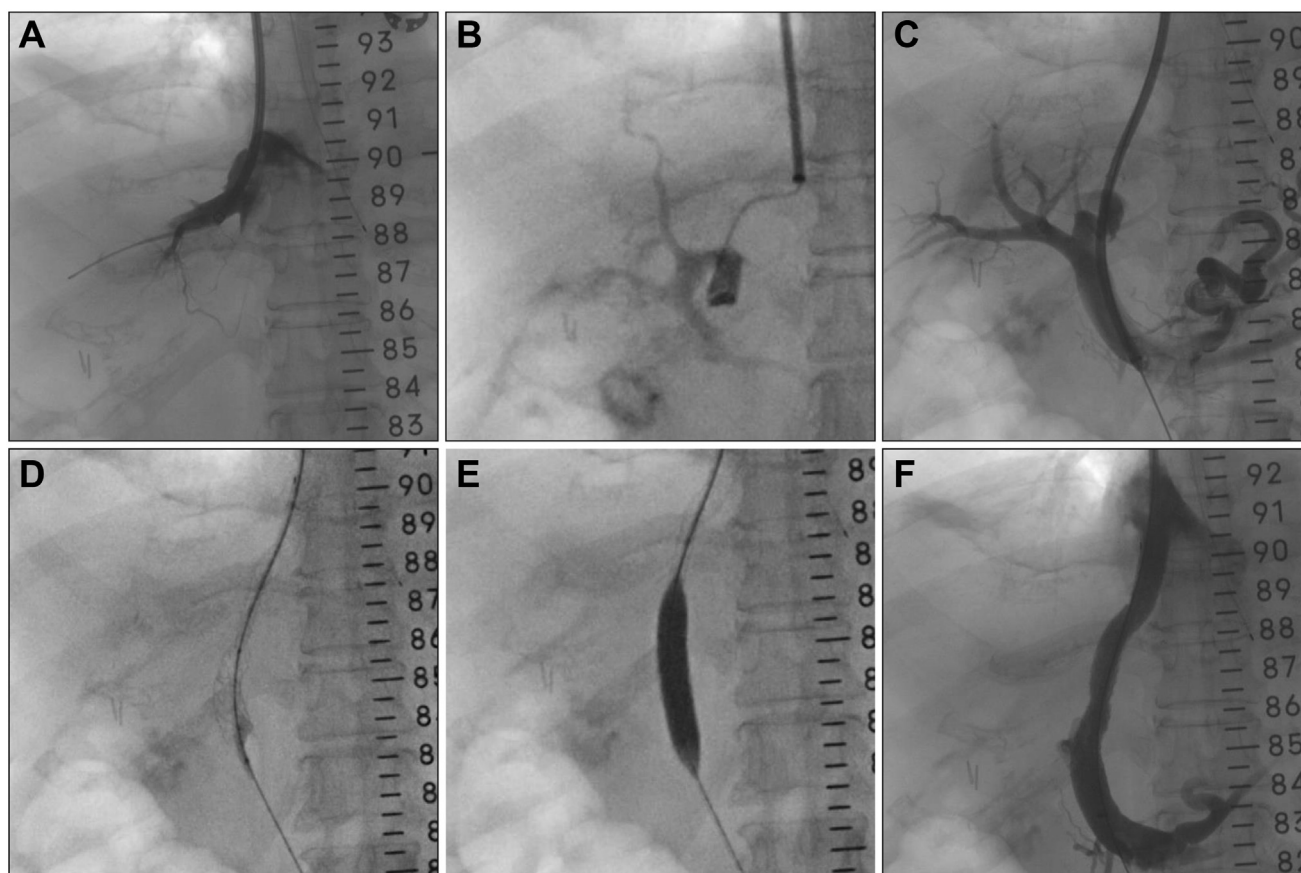
In patients with uncontrolled bleeding, the goal of TIPS is to reduce the portosystemic pressure gradient. Several studies have demonstrated the effectiveness of salvage TIPS in patients who do not respond to endoscopic and medical therapies, with a reduction in rebleeding and an improvement in overall survival.<sup>2,23</sup> Despite successful TIPS placement in controlling bleeding, the survival benefit of salvage TIPS is limited due to the development of complications, with about 13% of patients experiencing early rebleeding<sup>4</sup> and 30-day mortality rates as high as 30–44%.<sup>24,25</sup>

García-Pagán *et al.*<sup>26</sup> published the first multicentre RCT investigating the efficacy of pre-emptive TIPS compared to standard medical and endoscopic therapy. In this study, patients with a high risk of bleeding-related mortality (Child-Pugh C or B with active bleeding at endoscopy) were included. Pre-emptive TIPS was associated with a significant reduction in mortality (1-year survival 86% with early TIPS vs. 61% with standard therapy).<sup>26</sup> These results, along with other studies, suggest that pre-emptive TIPS should be considered as a first-line treatment to prevent rebleeding in a specific subset of high-risk patients, although the benefit on overall survival has not yet been demonstrated in patients with advanced cirrhosis.<sup>27–30</sup>

Acute hepatic decompensation often presents as a result of systemic inflammation.<sup>31</sup> In a large multicentric study, patients with acute-on-chronic liver failure and acute variceal bleeding treated by pre-emptive TIPS had reduced rates of rebleeding and 1-year mortality compared to patients without pre-emptive TIPS.<sup>32</sup>

### Other

Specific consideration of non-malignant portal vein thrombosis, which is strongly associated with cirrhosis, is important. TIPS can be considered in patients with portal vein thrombosis without recanalisation on anticoagulation or with progressive extension of the thrombosis.<sup>6</sup> Retrospective studies have reported similar technical success and efficacy of TIPS in patients with cirrhosis with and without non-malignant portal vein thrombosis.<sup>33–35</sup> A large retrospective study found no significant differences in the outcomes of patients with and without pre-existing portal vein thrombosis.<sup>35</sup> Moreover, complete resolution of portal vein thrombosis was observed in 57% of patients, with a low recurrence rate, and a reduction in thrombosis in 30% of cases.<sup>33</sup> There was no additional benefit to anticoagulation therapies in an RCT after TIPS in patients with portal vein thrombosis.<sup>36</sup> Finally, several teams have evaluated the role of TIPS in the prevention of hepatic decompensation following extrahepatic abdominal surgery in patients with cirrhosis, with promising results reported.<sup>37–39</sup> The rationale for preoperative TIPS is to decrease the



**Fig. 1.** 61-year-old man with decompensated cirrhosis and refractory ascites undergoing TIPS. (A) Angiography shows the middle hepatic vein venogram, (B) catheterisation of the left portal vein, (C) transhepatic portogram with opacification of the associated porto-systemic shunts, (D) insertion of the expandable covered stent graft (Viatorr, Bard), (E) angioplasty of the graft with dilatation at 10 mm, (F) final portogram showing successful TIPS placement. Pre-TIPS portosystemic pressure gradient was 23 mmHg and post-TIPS portosystemic pressure gradient was 5 mmHg. TIPS, transjugular intrahepatic portosystemic shunt.

**Table 1. Indications and contraindications for TIPS according to society guidelines.**

AASLD 2009		EASL 2018		BSG 2020	
Indications	Evidence level	Indications	Evidence/recommendation level	Indications	Evidence/recommendation level
Recurrent or refractory ascites	I	Recurrent or refractory ascites	I – strong recommendation	Recurrent or refractory ascites	High evidence, strong recommendation.
Uncontrolled variceal haemorrhage	II-3	Hepatic hydrothorax	II-2 – strong recommendation	Gastro-oesophageal variceal bleeding refractory to endoscopic and drug therapy	Moderate evidence, strong recommendation.
Secondary prevention of variceal haemorrhage after failure of pharmacologic and endoscopic therapy	I	Secondary prophylaxis (early TIPS) of variceal haemorrhage in high-risk patients (Child-Pugh class C with score <14).	I – weaker recommendation	Pre-emptive TIPS (Child-Pugh class C or MELD ≥19)	Moderate evidence, weak recommendation.
Prevention of rebleeding from gastric and ectopic varices	II-3	Persistent variceal bleeding and early rebleeding (rescue TIPS)	I – strong recommendation	Rebleeding despite optimal therapy	Low evidence, strong recommendation.
Portal hypertension gastropathy with recurrent bleeding despite the use of beta-blockers	II-3	Portal hypertensive gastropathy, if beta-blockers fail or are not tolerated	II-3 – weaker recommendation	Secondary prevention of gastric variceal bleeding	Moderate evidence, weak recommendation.
Uncontrolled hepatic hydrothorax	II-3	Hepatorenal syndrome	II-2 – weaker recommendation	Refractory bleeding from ectopic varices or portal hypertensive gastropathy	Low evidence, weak recommendation.
Budd-Chiari syndrome	II-3			Refractory hepatic hydrothorax	Moderate evidence, strong recommendation.
				Budd-Chiari syndrome	Moderate evidence, strong recommendation.
Contraindications	Contraindications	Contraindications	Contraindications	Contraindications	Contraindications
<b>Absolute contraindications:</b> primary prevention of variceal bleeding, congestive heart failure, multiple hepatic cysts, uncontrolled systemic infection or sepsis, unrelieved biliary obstruction, severe pulmonary hypertension.	Serum bilirubin >3 mg/dl and a platelet count <75 ×10 <sup>9</sup> /L, current hepatic encephalopathy grade ≥2 or chronic hepatic encephalopathy, concomitant active infection, progressive renal failure, severe systolic or diastolic dysfunction; pulmonary hypertension.			Patients with ascites with bilirubin >50 µm/L and platelets <75×10 <sup>9</sup> , pre-existing encephalopathy, active infection, severe cardiac failure or severe pulmonary hypertension; left ventricular dysfunction or severe pulmonary hypertension; significant intrinsic renal disease (stage 4/5).	
<b>Relative contraindications:</b> hepatoma especially if central, obstruction of all hepatic veins, portal vein thrombosis, severe coagulopathy (INR >5), thrombocytopenia of <20,000/cm <sup>3</sup> , moderate pulmonary hypertension.					

Level of evidence: I = randomised controlled trials; II-1 = controlled trials without randomisation; II-2 = controlled trials without randomisation; II-3 = multiple time series, dramatic uncontrolled experiments.

AASLD, American Association for the Study of Liver Disease; BSG, British Society of Gastroenterology; EASL, European Association for the Study of the Liver; INR, international normalised ratio; MELD, model for end-stage liver disease; TIPS, transjugular intrahepatic portosystemic shunt.

hepatic venous pressure gradient, which is a known predictor of decompensation after surgery.<sup>40</sup>

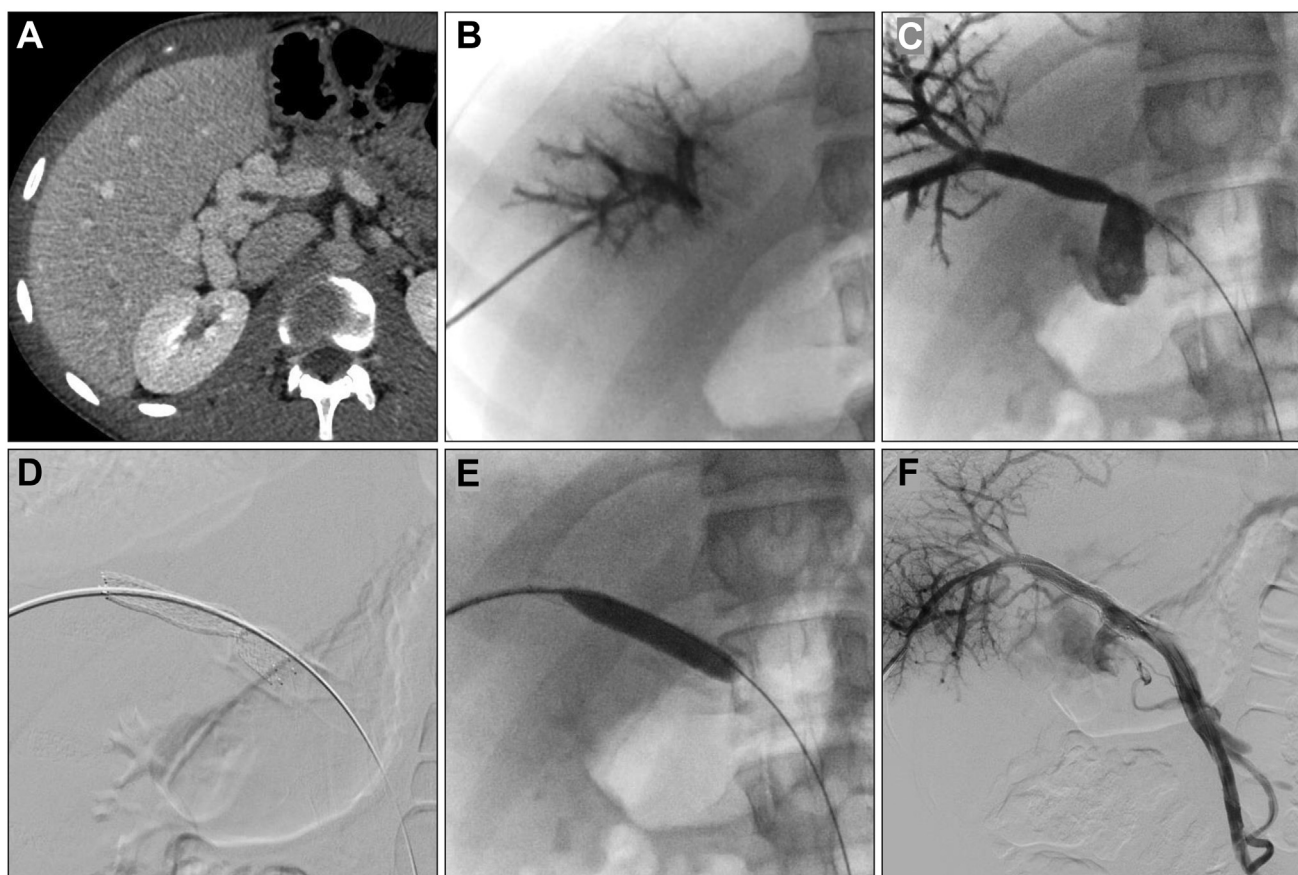
### Complications and dysfunction

Major procedure-related complications have been reported to occur in between 4% and 20% of cases.<sup>41</sup> The most frequent intra-procedural complications include capsular perforation with intraperitoneal haemorrhage, segmental liver ischaemia, hepatic failure, haemobilia, and other biliary complications.<sup>42</sup>

The main concerns after TIPS placement are the development of HE, cardiac dysfunction, and early stent dysfunction. HE is the most common complication after TIPS and is the leading cause of early hospital readmission (~27–48% at 30 days).<sup>43,44</sup> New episodes of HE occur in ~18–40% of patients, while worsening of pre-TIPS HE is reported in ~50% of patients.<sup>43–47</sup> Refractory HE can require TIPS reduction or occlusion to control the symptoms

of this complication.<sup>48</sup> Several predictive factors have been associated with the risk and prognosis of HE after TIPS, including a prior history of HE, age, Child-Pugh and MELD scores, the presence of other portosystemic shunts, high portosystemic pressure gradient reduction, and stents without controlled expansion.<sup>45,49</sup> A recent multicentre analysis of 1,871 patients has proposed the FIPS (Freiburg index of post-TIPS survival) score based on age, bilirubin, albumin, and creatinine to predict patients with a worse prognosis after elective TIPS.<sup>50</sup> A different study identified sarcopenia as an independent predictor of acute-on-chronic liver failure and death after TIPS.<sup>51</sup> Cardiac dysfunction has been reported in ~20% of patients after TIPS and was associated with cardiac parameters measured before TIPS.<sup>52</sup>

Stent stenosis or occlusion are the most common cause of TIPS dysfunction, often requiring strict surveillance and leading to a high frequency of revisions. Doppler ultrasound with



**Fig. 2. 19-year-old man with chronic portal vein thrombosis and cavernous transformation undergoing portal vein recanalisation.** (A) Pre-procedural contrast-enhanced CT shows cavernous transformation of the main portal vein. Recanalisation procedure consisting of (B) catheterisation of the segment IV portal vein branch, (C) catheterisation of the portal vein and superior mesenteric vein through the portal cavernoma, (D) stent placement, (E) dilatation of the stent at 10 mm, and (F) final portogram.

measurement of flow velocities is the primary method of assessment of TIPS stenosis and occlusion during follow-up. The patency of expanded polytetrafluoroethylene-covered stents is improved and reaches more than 90% at 1 year and 80% at 5 years, thus significantly reducing the need for TIPS revisions.<sup>41</sup> In a multicentre RCT, the 2-year rate of stent dysfunction was 44% and 63% ( $p = 0.032$ ) for covered and bare stents, respectively, with no differences in complications or patient survival.<sup>53</sup>

### Controversies

#### *Bleeding of other porto-systemic shunts (ectopic varices)*

Endoscopic or medical treatment is often ineffective in patients with bleeding ectopic varices.<sup>54</sup> Theoretically, TIPS could be used to reduce portosystemic pressure and the risk of rebleeding. Nevertheless, the value of TIPS in the treatment of ectopic varices is uncertain because rebleeding is frequent despite normalisation of the portosystemic pressure gradient. Moreover, the best available knowledge is based on small observational studies.<sup>55–58</sup> Despite good technical success (90%), a high early rebleeding rate (42%) was reported in patients without concomitant ectopic variceal embolisation.<sup>56</sup> A retrospective study in 53 patients with ectopic varices from 3 tertiary centres reported a rebleeding rate of 23% at 1 year and 32% at 5 years after TIPS.<sup>57</sup> Deipolyi *et al.*<sup>58</sup> described 10 patients with stomal variceal bleeding treated with TIPS (in combination with

embolisation in 5) resulting in recurrent bleeding in 4 cases. A meta-analysis in patients with gastric bleeding concluded that TIPS was associated with a lower risk of rebleeding (hazard ratio 0.35;  $p = 0.004$ ) than endoscopic variceal sclerotherapy.<sup>59</sup>

#### *Pre-emptive TIPS in Child-Pugh B patients*

The potential benefits of pre-emptive TIPS are still controversial in Child-Pugh B patients with active bleeding at endoscopy, and other patients who do not meet the high-risk criteria, as survival benefits reported in this subset of patients were not clear.<sup>28,29,60</sup> Although a large observational study<sup>29</sup> reported that pre-emptive TIPS led to no improvement in mortality in Child-Pugh B patients with active bleeding, a recent meta-analysis<sup>61</sup> comparing individual patient data reported a significant benefit in bleeding control and 1-year survival with pre-emptive TIPS compared to medical and endoscopic therapies in both Child-Pugh C and Child-Pugh B patients with active bleeding. In particular, pre-emptive TIPS significantly improved survival in patients with Child-Pugh B >7, while the prognosis did not change in those with Child-Pugh B7.<sup>61</sup>

Finally, while pre-emptive TIPS has been shown to be effective in selected patients, it is not systemically used in real life practice. Although approximately 35% of patients with variceal bleeding are potentially eligible for pre-emptive TIPS, access to the procedure remains limited to about 7% of patients in referral

centres, mainly due to the absence of dedicated interventional radiologists in non-referral institutions.<sup>62</sup>

#### *Embolisation of associated varices*

Embolisation of varices has become a treatment option for gastroesophageal varices in patients who are not eligible for TIPS.<sup>63</sup> Balloon-occluded retrograde transvenous obliteration has been performed in patients with bleeding from high-flow gastric varices.<sup>64</sup> The procedure has been associated with a lower rate of rebleeding and HE compared to TIPS for the management of gastric varices.<sup>65</sup> The use of concomitant TIPS and embolisation is controversial. On one hand, variceal embolisation could help reduce the risk of rebleeding in patients with TIPS. On the other hand, closing variceal shunts could worsen the portosystemic pressure gradient.<sup>66</sup> In the absence of clear recommendations, some authors have proposed embolisation if persistent variceal flow is observed on portography after TIPS, but in most cases the decision is made on a case-by-case basis.<sup>66–68</sup> In one RCT, Chen *et al.*<sup>69</sup> showed that the 6-month rate of recurrent variceal bleeding was lower in patients with TIPS and concomitant left gastric vein embolisation than with TIPS alone, but cumulative recurrence did not differ at 3 years. A meta-analysis (6 studies, 770 patients) reported that TIPS combined with variceal embolisation led to a significantly lower rebleeding rate, while no differences were observed in the occurrence of HE or shunt dysfunction compared to patients with TIPS alone.<sup>70</sup>

The benefit of partial splenic embolisation in combination with TIPS remains to be established. While it can reduce the splenic flow and portosystemic gradient, current studies did not report a survival benefit with combined TIPS and splenic embolisation.<sup>63,71,72</sup>

#### *Targeted porto-systemic gradient and stent size*

TIPS size and the portosystemic gradient are strongly associated with the control of PH-related complications and the occurrence of post-TIPS HE. A reduction in the portosystemic pressure gradient to <12 mmHg or >20% of the pre-TIPS grade has consistently been shown to be an optimal target value that is associated with a lower risk of rebleeding or ascites. This is consistent with the fact that PH-related complications almost always occur in patients with a portosystemic pressure gradient >12 mmHg following TIPS.<sup>73</sup> However, the optimal endpoint for the portosystemic pressure gradient is still a matter of debate. A reduction of the portosystemic pressure gradient to <10 mmHg has been associated with an increased risk of HE, suggesting that the optimal window for TIPS is narrow (from 10 to 12 mmHg).<sup>73,74</sup> The timing of portosystemic pressure measurements is controversial because early measurements performed immediately after TIPS may be affected by haemodynamic conditions and general anaesthesia, and may not be consistent with long-term portosystemic pressure measurements.<sup>14</sup> Repeated portosystemic pressure measurements should be considered at 24 hours after the procedure to have reliable values that correlate with clinical outcomes.<sup>14</sup>

The results of the use of small-diameter stents (8 mm) to reduce the rate of post-TIPS HE are contradictory. In an RCT by Riggio *et al.*<sup>75</sup> 8-mm stent TIPS resulted in a significantly higher portosystemic pressure gradient and higher rate of persistent ascites than 10-mm stents, but there were no differences in the occurrence of HE or in survival. These results were similar to

those of another study by Miraglia *et al.*<sup>76</sup> that evaluated a larger cohort of patients with refractory ascites. On the other hand, Trebicka *et al.*<sup>77</sup> found that 8-mm stents were associated with significantly longer survival, while Luo *et al.*<sup>78</sup> reported a lower rate of HE in patients receiving 8-mm stents.

A recent meta-analysis of 5 studies concluded that patients treated with 8-mm covered stents have a higher 1-year and 3-year overall survival, a lower rate of HE, and no difference in rebleeding rate, compared to those treated with 10-mm stents.<sup>79</sup> The study by Praktiknjo *et al.*<sup>80</sup> reported improved 1-year survival and a reduced rate of shunt-related complications in patients treated with underdilated controlled expansion stent grafts, which maintain a stable 8-mm expansion, compared to underdilated VIATORR® TIPS stent grafts.

#### *Non-cirrhotic patients*

Despite the absence of cirrhosis or other causes of chronic liver disease, the complications of non-cirrhotic PH are similar, including variceal haemorrhage, ascites, and portal vein thrombosis. The efficacy and safety of TIPS in patients with non-cirrhotic PH is not established, as only a few observational studies have been published to date. In a multicentre study by Bissonnette *et al.*<sup>81</sup> including 47 patients with idiopathic non-cirrhotic PH, variceal rebleeding and HE occurred in 28% and 34% of patients after TIPS, respectively. Significant extrahepatic comorbidities and elevated serum creatinine negatively influenced survival (27% mortality after TIPS during follow-up).<sup>81</sup>

The results of TIPS in patients with non-cirrhotic portal cavernous transformation have been reported in a few case series.<sup>82–84</sup> In a study by Fanelli *et al.* in 13 patients, TIPS implantation was successful in 10 (83%) patients with portal cavernoma without cirrhosis, leading to a significant reduction in the portosystemic pressure gradient.<sup>83</sup> However, the success rate of TIPS was only 35% in another series of 20 patients.<sup>84</sup> In a recent study on 39 patients with cavernous transformation of the portal vein, symptom improvement was observed in 87% of patients with an overall TIPS patency of 81% at 36 months.<sup>85</sup>

## **Portal vein recanalisation**

### **Rationale and indications**

Patients with portal vein occlusion or stenosis may develop venous collaterals and be at risk of life-threatening bleeding or ascites due to prehepatic PH. The rationale for PVR is to restore the physiological portal venous flow and to prevent bleeding from ectopic collaterals. The main indications for PVR are portal vein thrombosis in liver transplant recipients, the management of complications of chronic portal vein thrombosis with cavernous transformation (e.g., portal hypertension with bleeding and ascites, cholangiopathy) (Fig. 2) and acute thrombosis (e.g. bowel ischaemia), and portal vein stenosis due to extrinsic compression or postoperative stenosis.

### **Technical considerations**

Various endovascular approaches have been attempted for PVR, including transhepatic, transjugular intrahepatic, or transsplenic approaches.<sup>86</sup> In patients with portal vein thrombosis, local mechanical thrombectomy combined with pharmacological thrombolysis may be attempted to restore normal blood flow. Mechanical thrombectomy may be performed with balloon angioplasty, device-assisted thrombectomy, or sheath-directed

thrombus aspiration.<sup>87</sup> Uncovered self-expandable metallic stents may be used for long-term patency of the portal vein after the procedure, especially in patients with adjacent compressing masses. Overall, the reported technical success is 87–95% in large retrospective series.<sup>88,89</sup>

### Results and evidence

Most of the current evidence on PVR is based on case reports or small case series. Oral anticoagulant therapies are the first-line treatment in patients with portal vein thrombosis, while endovascular therapies and PVR may be attempted if medical treatment fails.<sup>90</sup> It should be noted that the small number of patients in those retrospective studies and the lack of randomised controls prevent us from drawing strong evidence-based conclusions on the role of PVR.

In liver transplant recipients complicated by portal vein stenosis, PVR with balloon angioplasty and stent placement has been shown to be an acceptable and safe procedure. A patency rate of 82% and 68% has been reported 5 and 10 years after balloon angioplasty, respectively, with a patency rate of 100% after stent placement in post-transplant portal vein stenosis.<sup>91</sup> Primary stent placement was also shown to have a significantly higher success rate than balloon angioplasty (97–100% vs. 67–69%) in a recent meta-analysis.<sup>92</sup>

Clinical improvement was reported in 92% of patients with chronic portal vein thrombosis and cavernous transformation of the portal vein following mechanical thrombectomy combined with pharmacological thrombolysis via an intrahepatic portosystemic approach.<sup>93</sup> While the recanalisation rate was only 40% in patients with acute portal vein thrombosis, this remains higher than medical therapy alone.<sup>94,95</sup>

PVR with stent placement has also been used in patients with extrinsic obstruction caused by either inflammatory conditions or malignant tumours.<sup>89,96,97</sup> Kim *et al.*<sup>89</sup> performed PVR in patients with extrahepatic portal vein obstruction for biliary or pancreatic neoplasms, with a mean patency of 30 and 21 months after stent placement in patients with benign and malignant stenosis, respectively.

### Complications and dysfunction

The possible complications following PVR include portal vein restenosis and thrombosis. Life-threatening bleeding and other complications such as hepatic abscesses and subcapsular haemorrhage are rare.<sup>93</sup>

### Controversies

#### Association with TIPS

The association of TIPS with PVR (PVR-TIPS) is controversial.<sup>98</sup> Even though TIPS may not reduce portal pressure in case of prehepatic PH without hepatic alterations, the combination of TIPS and PVR has been proposed to maintain portal vein patency in case of a persistently high portosystemic gradient after recanalisation.<sup>99</sup> Currently, there are only a few series on the clinical values of PVR-TIPS.<sup>100,101</sup> Barbier *et al.*<sup>101</sup> have reported a success rate of 85–100% with PVR-TIPS, although several interventions were required in patients with acute thrombosis, and the recurrence rate in patients with chronic thrombosis was 53%. Habib *et al.*<sup>102</sup> assessed the ability of PVR-TIPS to re-establish portal vein flow in transplant candidates with portal vein thrombosis. Despite the technical success, only 3/11 patients were finally transplanted in that study.<sup>102</sup> In a cohort of 61 liver transplantation candidates, PVR-TIPS patency was 92% at 19

months, recurrent thrombosis only occurred in 8% of patients, but only 39% of patients were finally transplanted.<sup>103</sup> Thus, improved survival and the added value of PVR-TIPS compared to other therapies has not been clearly established. Finally, there is no standard portal pressure gradient cut-off for optimal patient selection for the combined PVR-TIPS procedure.

### Portal vein embolisation

#### Rationale and indications

Postoperative liver failure is a severe complication after major hepatectomy and is associated with high morbidity and mortality. Preoperative PVE can be performed as a volume modulation procedure in patients with an insufficient future liver remnant (FLR) both to increase the number of candidates for surgical resection and to prevent postoperative complications. PVE promotes hypertrophy by redirecting portal venous flow to the non-embolised liver, increasing the ratio between the expected FLR and total liver volume. The main clinical indication for PVE is major hepatectomy in patients with malignant liver lesions and insufficient FLR (Fig. 3). PVE is generally indicated when the FLR is  $\leq 20$ – $25\%$  in a healthy liver,  $\leq 30$ – $35\%$  in patients with chronic liver disease but without cirrhosis (non-alcoholic fatty liver disease, chemotherapy-associated steatohepatitis, cholangitis) or reduced liver function, and  $\leq 40\%$  in cirrhosis or non-alcoholic steatohepatitis.<sup>104</sup>

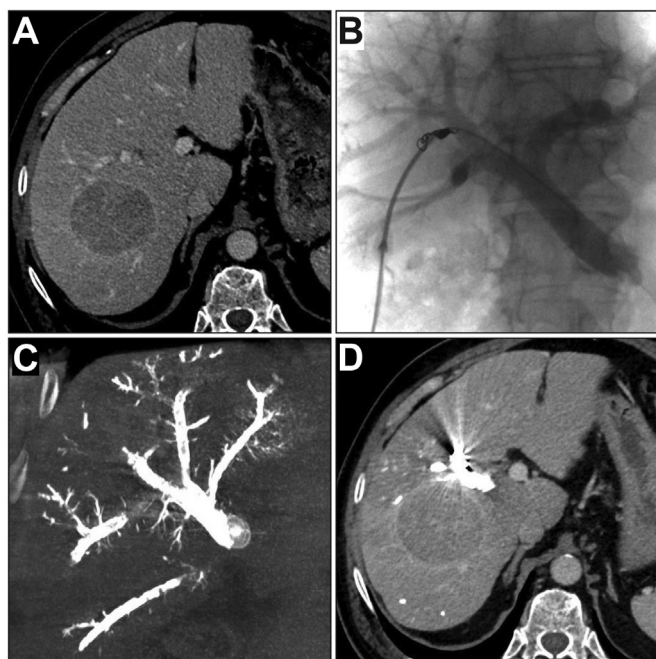
#### Technical considerations

Technical aspects of this procedure have been extensively described in prior studies.<sup>105,106</sup> Overall, the reported technical success has been reported to be between 80–100%.<sup>107</sup> Briefly, PVE can be performed by a percutaneous transhepatic contralateral approach with ultrasound-guided access to the portal vein via the FLR, a transhepatic ipsilateral approach via the future resected liver, or a trans-ileocolic venous approach.<sup>106</sup> The approach depends on the patients' anatomy and the radiologist's preference, and in relation to the possible risks of FLR injury with the contralateral approach. Numerous embolic agents can be used. Their impact on FLR hypertrophy is discussed below.

Although biliary drainage may be needed in patients with obstructive jaundice and hepatobiliary malignancies requiring preoperative PVE, there are no clear recommendations in the literature supporting routine preoperative biliary drainage in these patients, even in the presence of jaundice. One study has shown that the hypertrophy ratio was significantly higher when selective drainage of the FLR was performed instead of total liver drainage.<sup>108</sup> A recent meta-analysis has shown that FLR drainage has now become an accepted practice,<sup>109</sup> which makes sense because obstructive jaundice reduces compensatory hypertrophy of the liver. Nevertheless, in patients with FLR drainage and with worsening jaundice or cholangitis, additional drainage of the future resected liver did not decrease FLR ratios or the hypertrophy ratio after PVE.<sup>110</sup>

#### Results and evidence

PVE can induce 35–50% FLR hypertrophy, with no difference in the rates of hypertrophy, morbidity or mortality compared to portal vein ligation.<sup>111</sup> PVE is the treatment of choice in patients who do not require 2-stage hepatectomy. However, the rate of FLR hypertrophy is lower than following the associated liver partition and portal vein ligation for staged hepatectomy (ALPPS) procedure (+48–90% between stage 1 & 2).<sup>112–114</sup> In the latter,



**Fig. 3.** 66-year-old man with cirrhosis secondary to non-alcoholic fatty liver disease complicated by hepatocellular carcinoma. (A) Preoperative contrast-enhanced CT shows a 6 cm hepatocellular carcinoma. The future liver remnant was 27%. (B) Angiography shows right portogram after ipsilateral canalisation of the portal vein. Embolisation was performed with a mixture of N-butyl cyanoacrylate and lipiodol. One small anterior branch was coil embolised to avoid embolisation material migration (C) Cone beam CT angiography after portal vein embolisation shows embolic agents in the right portal vein. (D) Contrast-enhanced CT 6 weeks after portal vein embolisation shows relative hypertrophy of the left liver. The future liver remnant increased to 41%. Patients underwent successful right hepatectomy.

parenchymal transection and hepatic vein ligation further induce FLR hypertrophy.<sup>112–114</sup> ALPPS is also associated with a higher rate of completion of second stage hepatectomy than conventional 2-stage hepatectomy with PVE or ligation. However, ALPPS is also clearly associated with significantly higher perioperative morbidity and mortality.<sup>115</sup> Thus, ALPPS should be considered as an alternative option during the first stage in patients requiring conventional 2-stage hepatectomies with resection in the FLR or in patients requiring 1-stage hepatectomy with insufficient hypertrophy following PVE.

Curative-intent surgical resection is successful in 67–90% of patients who undergo preoperative PVE.<sup>116–119</sup> This is important since patients who undergo preoperative PVE and extended hepatectomy have been shown to have a better prognosis than those who do not undergo curative-intent surgery.<sup>119</sup> Drop-out is mainly due to tumour progression and not to insufficient FLR hypertrophy.

PVE can be associated with transarterial therapies (*i.e.* transarterial chemoembolisation [TACE]) to obtain greater preoperative disease control and lower the risk of tumour progression. While concomitant occlusion of both arterial and portal flow may increase patient morbidity, several retrospective studies have suggested that sequential TACE and PVE may lead to a higher rate of tumour necrosis, increased hypertrophy of FLR, and longer overall survival compared to PVE alone in patients with hepatocellular carcinoma.<sup>117,120–122</sup> In a recent study,

radioembolisation with Yttrium-90 (when performing radiation lobectomy) has been proposed as an alternative to PVE in patients with hepatocellular carcinoma, resulting in better hypertrophy and tumour control<sup>123</sup> but not increased resection rates. Furthermore, a case-controlled series showed that radioembolisation induced significantly less FLR hypertrophy than PVE in patients with secondary liver tumours.<sup>124</sup>

### Complications

Severe procedural complications have been reported in 3–16% of patients following PVE.<sup>109,116,125,126</sup> Portal vein thrombosis in the proximal or contralateral portal vein and unwanted embolisation material extending into the FLR portal branches are the most severe complications and can jeopardise FLR hypertrophy.<sup>126</sup> Other minor complications include abscesses (especially in the presence of dilated intrahepatic bile ducts), bilomas, haematomas, and hepatic insufficiency.<sup>126</sup>

### Controversies

#### Embolisation agents

There is no consensus on the best embolic agent for FLR hypertrophy. Several embolic agents have been used, including N-butyl cyanoacrylate (NBCA), gelatin sponge, coils, ethanol, nitinol plugs, or a combination of these materials. In clinical practice, the choice of the embolic agent is mainly based on the operators' experience, availability, and cost. There are very few retrospective comparisons of embolic agents and some results are contradictory.<sup>127,128</sup> In the study by Jaber *et al.*,<sup>129</sup> NBCA combined with an amplatzer vascular plug resulted in a higher rate of FLR hypertrophy than polyvinyl alcohol and coils, although no differences were observed in the surgical outcomes or the rate of complications. In a retrospective analysis, Sugawara *et al.*<sup>130</sup> reported that PVE with ethanol significantly increased the non-embolised liver volume compared to NBCA, but a recent systematic review concluded that NBCA provided greater FLR hypertrophy, with no difference in the rate of complications.<sup>131</sup> A recent RCT showed that PVE with NBCA plus iodised oil resulted in faster and greater FLR hypertrophy than PVE with PVA particles plus coils (57% vs. 37% respectively, at 28 days,  $p < 0.001$ ).<sup>132</sup> However, this was not associated with a significantly higher rate of surgical resection (80% vs. 77%, respectively,  $p = 0.75$ ) or a statistically significant better post-operative outcome (liver failure in 13% vs. 27%, respectively,  $p = 0.27$ ).<sup>132</sup>

#### Factors affecting hepatic regeneration

Inadequate FLR hypertrophy, which occurs in 10–20% of patients, is a major cause of unresectability after PVE. While hypertrophy occurs at a slower rate in fibrotic or cirrhotic livers, the rate of FLR hypertrophy is not significantly affected by the quality of the hepatic parenchyma. It has been suggested that several factors may hinder hepatic regeneration and FLR hypertrophy.<sup>133</sup> In particular, the potentially deleterious effect of neoadjuvant chemotherapy on FLR hypertrophy remains unclear.<sup>134</sup> Since angiogenesis may play a crucial role in hepatic regeneration, the effect of antiangiogenic therapies may play a role. Hypertrophy rates at 4 weeks were comparable in patients who did or did not receive bevacizumab,<sup>135</sup> while another study<sup>136</sup> showed that the rate was lower in patients treated with bevacizumab compared to chemotherapy without bevacizumab.



### Associated hepatic vein embolisation

Hepatic vein(s) embolisation performed either subsequently or concomitantly (also known as liver venous deprivation, or as simultaneous radiological portohepatic vein embolisation, RASPE) to PVE is another strategy to further increase parenchymal hypertrophy in patients with insufficient FLR.<sup>137,138</sup> Retrospective studies have reported that the combined embolisation of the portal and hepatic veins leads to greater hypertrophy compared to PVE alone.<sup>138–141</sup> In a meta-analysis by Esposito *et al.*,<sup>142</sup> the increase in FLR was 33–63% and was significantly higher when hepatic vein embolisation and PVE were performed simultaneously, rather than sequentially (54% vs. 44%,  $p = 0.008$ ). The added value of embolisation of both the right and middle hepatic veins vs. the right hepatic vein alone in addition to PVE must still be assessed. Substantial hypertrophy of segment IV can be observed when the right hepatic vein is targeted. This could be an obstacle in patients requiring right hepatectomy extended to segment IV. In this setting, embolisation of both the right and middle hepatic veins or just the middle hepatic vein could be considered in association with PVE.<sup>143,144</sup> Despite promising results, the results of RCTs are awaited to compare the 2 approaches and the added value of combined embolisation on patient outcome must be evaluated in large cohorts.<sup>145</sup> In particular, this interventional procedure should also be compared to ALPPS for 2-stage hepatectomy because it could decrease morbidity but achieve similar hypertrophy. Finally, variations in liver function should be assessed, as FLR function can improve more significantly and faster than volume.<sup>146,147</sup>

### Segment IV embolisation

PVE has been extended to segment IV in patients undergoing right hepatectomy extended to segment IV. The main advantage of this type of PVE is significantly higher hypertrophy of the left lateral segment compared to right PVE alone.<sup>148,149</sup> Segment IV embolisation is technically difficult because of the risk of unwanted reflux of embolic material and of accidental occlusion of the left portal vein branches which could affect FLR hypertrophy. This explains why most segment IV embolisations are performed with coils. There are no studies on differences in the subsequent resection rate in patients undergoing PVE extended to segment IV or not.<sup>148,149</sup> Moreover, improvement in post-operative complications and survival have not been clearly assessed.<sup>150</sup> In the study by Hammond *et al.*,<sup>151</sup> post-surgical survival did not differ between patients with and without segment IV-extended PVE.

### Tumour growth induced by PVE

Tumour progression is a major concern following PVE and it has been reported to be the main cause of dropout (accounting for unresectability in around two-thirds of patients after PVE).<sup>118,152,153</sup> The evidence of the effect of PVE on tumour growth is conflicting, and the possible effect on tumours in the embolised and non-embolised livers should be considered separately. Several studies have reported increased tumour growth in the embolised liver and the possible mechanisms for tumour growth are still under investigation.<sup>154</sup> Simoneau *et al.*<sup>155</sup> observed a high rate of tumour progression and increased tumour volume after PVE in 77% of patients with colorectal liver metastases treated with chemotherapy +/- bevacizumab. In patients with hepatocellular carcinoma, Loveday *et al.*<sup>153</sup> reported an increase in tumour volume in 25 out of 31 patients leading to a change in treatment plan in approximately a quarter of patients. However, the effect of tumour progression after PVE on long-term patient outcome is a subject of debate. In a recent study, disease progression after PVE did not affect long-term overall survival in patients with hepatocellular carcinoma, even though the increase in tumour burden was significantly associated with shorter disease-free survival.<sup>156</sup> In colorectal liver metastases, a meta-analysis<sup>157</sup> concluded that PVE did not negatively affect progression-free survival or overall survival.

Tumour growth in the non-embolised lobe is more of a concern because it could prevent curative-intent surgery and influence patient prognosis, especially in case of the occurrence of new lesions in the non-embolised liver. In patients with bilobar tumours, retrospective studies showed no differences in the tumour progression rate in embolised and non-embolised livers.<sup>158,159</sup>

Studies have addressed the effect of chemotherapy on tumour progression after PVE.<sup>134</sup> The proportion of hepatic resection after PVE was comparable in patients with and without chemotherapy, but the PVE with chemotherapy group had a lower rate of progression (18.9% vs. 34.2%;  $p = 0.03$ ) and better 5-year survival (49% vs. 24%;  $p = 0.006$ ).<sup>134</sup>

## Conclusion

Image-guided interventions involving the portal vein positively influence the management and outcomes of patients with portal hypertension or hepatic tumours. Significant progress has been made, in particular regarding the standardisation of techniques and patient selection. Nevertheless, certain controversies remain and need to be evaluated in further studies.

## Abbreviations

ALPPS, associating liver partition and portal vein ligation for staged hepatectomy; BSG, British Society of Gastroenterology; EASL, European Association for the Study of the Liver; FLR, future liver remnant; HE, hepatic encephalopathy; NCBA, N-butyl cyanoacrylate; PH, portal hypertension; PVE, portal vein embolisation; PVR, portal vein recanalisation; RCT, randomised controlled trial; TACE, trans-arterial chemoembolization; TIPS, transjugular intrahepatic portosystemic shunt.

## Financial support

The authors received no financial support to produce this manuscript.

## Conflict of interest

The authors declare no conflicts of interest that pertain to this work.

Please refer to the accompanying ICMJE disclosure forms for further details.

## Authors' contributions

Conceptualization: LT, RD, MR. Methodology: RC, LT, RD, MR. Supervision: FD, FC, PER, MR. Validation: LT, FD, FC, PER, RD. Writing – original draft: RC. Writing – review & editing: All Authors.

## Supplementary data

Supplementary data to this article can be found online at <https://doi.org/10.1016/j.jhepr.2022.100484>.

## References

- [1] Sanyal AJ, Bosch J, Blei A, Arroyo V. Portal hypertension and its complications. *Gastroenterology* 2008;134:1715–1728. <https://doi.org/10.1053/j.gastro.2008.03.007>.
- [2] García-Tsao G, Abraldes JG, Berzigotti A, Bosch J. Portal hypertensive bleeding in cirrhosis: risk stratification, diagnosis, and management: 2016 practice guidance by the American Association for the study of liver diseases. *Hepatology* 2017;65:310–335. <https://doi.org/10.1002/hep.28906>.
- [3] Boyer TD, Haskal ZJ, American Association for the Study of Liver Diseases. The role of Transjugular Intrahepatic Portosystemic Shunt (TIPS) in the management of portal hypertension: update 2009. *Hepatology* 2010;51:306. <https://doi.org/10.1002/hep.23383>.
- [4] European Association for the Study of the Liver. EASL Clinical Practice Guidelines for the management of patients with decompensated cirrhosis. *J Hepatol* 2018;69:406–460. <https://doi.org/10.1016/j.jhep.2018.03.024>.
- [5] Tripathi D, Stanley AJ, Hayes PC, Travis S, Armstrong MJ, Tsochatzis EA, et al. Transjugular intrahepatic portosystemic stent-shunt in the management of portal hypertension. *Gut* 2020;69:1173–1192. <https://doi.org/10.1136/gutjnl-2019-320221>.
- [6] de Franchis R, Bosch J, Garcia-Tsao G, Reiberger T, Ripoll C, Baveno VII Faculty. Baveno VII - renewing consensus in portal hypertension. *J Hepatol* 2021. <https://doi.org/10.1016/j.jhep.2021.12.022>.
- [7] Biggins SW, Angeli P, Garcia-Tsao G, Ginès P, Ling SC, et al. Diagnosis, evaluation, and management of ascites, spontaneous bacterial peritonitis and hepatorenal syndrome: 2021 practice guidance by the American Association for the Study of Liver Diseases. *Hepatology* 2021;74:1014–1048. <https://doi.org/10.1002/hep.31884>.
- [8] Saad WE, Darwish WM, Davies MG, Kumer S, Anderson C, Waldman DL, et al. Transjugular intrahepatic portosystemic shunts in liver transplant recipients: technical analysis and clinical outcome. *AJR Am J Roentgenol* 2013;200:210–218. <https://doi.org/10.2214/AJR.11.7653>.
- [9] Sarwar A, Zhou L, Novack V, Tapper EB, Curry M, Malik R, et al. Hospital volume and mortality after transjugular intrahepatic portosystemic shunt creation in the United States. *Hepatology* 2018;67:690–699. <https://doi.org/10.1002/hep.29354>.
- [10] Fidelman N, Kwan SW, LaBerge JM, Gordon RL, Ring EJ, Kerlan Jr RK. The transjugular intrahepatic portosystemic shunt: an update. *AJR Am J Roentgenol* 2012;199:746–755. <https://doi.org/10.2214/AJR.12.9101>.
- [11] Keller FS, Farsad K, Rösch J. The transjugular intrahepatic portosystemic shunt: technique and instruments. *Tech Vasc Interv Radiol* 2016;19:2–9. <https://doi.org/10.1053/j.tvir.2016.01.001>.
- [12] Artru F, Moschouri E, Denys A. Direct intrahepatic portocaval shunt (DIPS) or transjugular transcaval intrahepatic portosystemic shunt (TTIPS) to treat complications of portal hypertension: indications, technique, and outcomes beyond Budd-Chiari syndrome. *Clin Res Hepatol Gastroenterol* 2022;101858. <https://doi.org/10.1016/j.clinre.2022.101858>.
- [13] Zhang W, Peng C, Zhang S, Huang S, Shen S, Xu G, et al. EUS-guided portal pressure gradient measurement in patients with acute or sub-acute portal hypertension. *Gastrointest Endosc* 2021;93:565–572. <https://doi.org/10.1016/j.gie.2020.06.065>.
- [14] Silva-Junior G, Turon F, Baiges A, Cerda E, García-Criado Á, Blasi A, et al. Timing affects measurement of portal pressure gradient after placement of transjugular intrahepatic portosystemic shunts in patients with portal hypertension. *Gastroenterology* 2017;152:1358–1365. <https://doi.org/10.1053/j.gastro.2017.01.011>.
- [15] Sommer CM, Gockner TL, Stampfl U, Bellemann N, Sauer P, Ganten T, et al. Technical and clinical outcome of transjugular intrahepatic portosystemic stent shunt: bare metal stents (BMS) versus viatorr stent-grafts (VSG). *Eur J Radiol* 2012;81:2273–2280. <https://doi.org/10.1016/j.ejrad.2011.06.037>.
- [16] Gupta AC, Wang W, Shah C, Sands MJ, Bullen J, Remer EM, et al. Added value of covered stents in transjugular intrahepatic portosystemic shunt: a large single-center experience. *Cardiovasc Intervent Radiol* 2017;40:1723–1731. <https://doi.org/10.1007/s00270-017-1694-1>.
- [17] European Association for the Study of the Liver. EASL clinical practice guidelines on the management of ascites, spontaneous bacterial peritonitis, and hepatorenal syndrome in cirrhosis. *J Hepatol* 2010;53:397–417. <https://doi.org/10.1016/j.jhep.2010.05.004>.
- [18] Madoff DC, Cornman-Homonoff J, Fortune BE, Gaba RC, Lipnik AJ, Yarmohammadi H, et al. Management of refractory ascites due to portal hypertension: current status. *Radiology* 2021;298:493–504. <https://doi.org/10.1148/radiol.2021201960>.
- [19] Salerno F, Cammà C, Enea M, Rössle M, Wong F. Transjugular intrahepatic portosystemic shunt for refractory ascites: a meta-analysis of individual patient data. *Gastroenterology* 2007;133:825–834. <https://doi.org/10.1053/j.gastro.2007.06.020>.
- [20] Bureau C, Métivier S, D'Amico M, Péron JM, Otal P, Pagan JC, et al. Serum bilirubin and platelet count: a simple predictive model for survival in patients with refractory ascites treated by TIPS. *J Hepatol* 2011;54:901–907. <https://doi.org/10.1016/j.jhep.2010.08.025>.
- [21] Sauerbruch T, Mengel M, Dollinger M, Zipprich A, Rössle M, Panther E, et al. Prevention of rebleeding from esophageal varices in patients with cirrhosis receiving small-diameter stents versus hemodynamically controlled medical therapy. *Gastroenterology* 2015;149:660–668.e1. <https://doi.org/10.1053/j.gastro.2015.05.011>.
- [22] Holster IL, Tjwa ET, Moelker A, Wils A, Hansen BE, Vermeijden JR, et al. Covered transjugular intrahepatic portosystemic shunt versus endoscopic therapy +  $\beta$ -blocker for prevention of variceal rebleeding. *Hepatology* 2016;63:581–589. <https://doi.org/10.1002/hep.28318>.
- [23] Niekamp A, Kuban JD, Lee SR, Yevich S, Metwalli Z, McCarthy CJ, et al. Transjugular intrahepatic portosystemic shunts reduce variceal bleeding and improve survival in patients with cirrhosis: a population-based analysis. *J Vasc Interv Radiol* 2020;31:1382–1391.e2. <https://doi.org/10.1016/j.jvir.2020.06.005>.
- [24] Azoulay D, Castaing D, Majno P, Saliba F, Ichaï P, Smail A, et al. Salvage transjugular intrahepatic portosystemic shunt for uncontrolled variceal bleeding in patients with decompensated cirrhosis. *J Hepatol* 2001;35:590–597. [https://doi.org/10.1016/s0168-8278\(01\)00185-4](https://doi.org/10.1016/s0168-8278(01)00185-4).
- [25] Vangeli M, Patch D, Burroughs AK. Salvage tips for uncontrolled variceal bleeding. *J Hepatol* 2002;37:703–704. [https://doi.org/10.1016/s0168-8278\(02\)00321-5](https://doi.org/10.1016/s0168-8278(02)00321-5).
- [26] García-Pagán JC, Caca K, Bureau C, Laleman W, Appenrodt B, Luca A, et al. Early use of TIPS in patients with cirrhosis and variceal bleeding. *N Engl J Med* 2010;362:2370–2379. <https://doi.org/10.1056/NEJMoa0910102>.
- [27] Rudler M, Cluzel P, Corvec TL, Benosman H, Rousseau G, Poynard T, et al. Early-TIPS placement prevents rebleeding in high-risk patients with variceal bleeding, without improving survival. *Aliment Pharmacol Ther* 2014;40:1074–1080. <https://doi.org/10.1111/apt.12934>.
- [28] Bucsic T, Schoder M, Goeschl N, Schwabl P, Mandorfer M, Diermayr M, et al. Re-bleeding rates and survival after early transjugular intrahepatic portosystemic shunt (TIPS) in clinical practice. *Dig Liver Dis* 2017;49:1360–1367. <https://doi.org/10.1016/j.dld.2017.08.002>.
- [29] Hernández-Gea V, Procopet B, Giráldez Á, Amitrano L, Villanueva C, Thabut D, et al. Preemptive-TIPS improves outcome in high-risk variceal bleeding: an observational study. *Hepatology* 2019;69:282–293. <https://doi.org/10.1002/hep.30182>.
- [30] Dunne PDJ, Sinha R, Stanley AJ, Lachlan N, Ireland H, Shams A, et al. Randomised clinical trial: standard of care versus early-transjugular intrahepatic porto-systemic shunt (TIPSS) in patients with cirrhosis and oesophageal variceal bleeding. *Aliment Pharmacol Ther* 2020;52:98–106. <https://doi.org/10.1111/apt.15797>.
- [31] Trebicka J, Fernandez J, Papp M, Caraceni P, Laleman W, Gambino C, et al. PREDICT identifies precipitating events associated with the clinical course of acutely decompensated cirrhosis. *J Hepatol* 2021;74:1097–1108. <https://doi.org/10.1016/j.jhep.2020.11.019>.
- [32] Trebicka J, Gu W, Ibáñez-Samaniego L, Hernández-Gea V, Pitarch C, Garcia E, et al. Rebleeding and mortality risk are increased by ACLF but reduced by pre-emptive TIPS. *J Hepatol* 2020;73:1082–1091. <https://doi.org/10.1016/j.jhep.2020.04.024>.
- [33] Luca A, Miraglia R, Caruso S, Milazzo M, Sapere C, Maruzzelli L, et al. Short- and long-term effects of the transjugular intrahepatic portosystemic shunt on portal vein thrombosis in patients with cirrhosis. *Gut* 2011;60:846–852. <https://doi.org/10.1136/gut.2010.228023>.
- [34] Qi X, He C, Guo W, Yin Z, Wang J, Wang Z, et al. Transjugular intrahepatic portosystemic shunt for portal vein thrombosis with variceal bleeding in liver cirrhosis: outcomes and predictors in a prospective cohort study. *Liver Int* 2016;36:667–676. <https://doi.org/10.1111/liv.12929>.
- [35] Lv Y, He C, Wang Z, Guo W, Wang J, Bai W, et al. Association of nonmalignant portal vein thrombosis and outcomes after transjugular intrahepatic portosystemic shunt in patients with cirrhosis. *Radiology* 2017;285:999–1010. <https://doi.org/10.1148/radiol.2017162266>.
- [36] Wang Z, Jiang MS, Zhang HL, Weng NN, Luo XF, Li X, et al. Is post-TIPS anticoagulation therapy necessary in patients with cirrhosis and portal vein thrombosis? a randomized controlled trial. *Radiology* 2016;279:943–951. <https://doi.org/10.1148/radiol.2015150369>.

- [37] Fares N, Robic MA, Péron JM, Muscari F, Otal P, Suc B, et al. Transjugular intrahepatic portosystemic shunt placement before abdominal intervention in cirrhotic patients with portal hypertension: lessons from a pilot study. *Eur J Gastroenterol Hepatol* 2018;30:21–26. <https://doi.org/10.1097/MEG.0000000000000990>.
- [38] Lahat E, Lim C, Bhangui P, Fuentes L, Osseis M, Moussallem T, et al. Transjugular intrahepatic portosystemic shunt as a bridge to non-hepatic surgery in cirrhotic patients with severe portal hypertension: a systematic review. *HPB (Oxford)* 2018;20:101–109. <https://doi.org/10.1016/j.hpb.2017.09.006>.
- [39] Tabchouri N, Barbier L, Menahem B, Perarnau JM, Muscari F, Fares N, et al. Original study: transjugular intrahepatic portosystemic shunt as a bridge to abdominal surgery in cirrhotic patients. *J Gastrointest Surg* 2019;23:2383–2390. <https://doi.org/10.1007/s11605-018-4053-x>.
- [40] Reverter E, Cirera I, Albillos A, Debernardi-Venon W, Abraldes JG, Llop E, et al. The prognostic role of hepatic venous pressure gradient in cirrhotic patients undergoing elective extrahepatic surgery. *J Hepatol* 2019;71:942–950. <https://doi.org/10.1016/j.jhep.2019.07.007>.
- [41] Geeroms B, Laleman W, Laenen A, Heye S, Verslype C, van der Merwe S, et al. Expanded polytetrafluoroethylene-covered stent-grafts for transjugular intrahepatic portosystemic shunts in cirrhotic patients: long-term patency and clinical outcome results. *Eur Radiol* 2017;27:1795–1803. <https://doi.org/10.1007/s00330-016-4570-5>.
- [42] Gaba RC, Khatiani VL, Knuttinen MG, Omene BO, Carrillo TC, Bui JT, et al. Comprehensive review of TIPS technical complications and how to avoid them. *AJR Am J Roentgenol* 2011;196:675–685. <https://doi.org/10.2214/AJR.10.4819>.
- [43] Vozzo CF, Singh T, Bullen J, Sarvepalli S, McCullough A, Kapoor B. Hospital readmission following transjugular intrahepatic portosystemic shunt: a 14-year single-center experience. *Gastroenterol Rep (Oxf)* 2019;8:98–103. <https://doi.org/10.1093/gastro/goz062>.
- [44] Sarwar A, Weinstein JL, Novack V, Chakrala N, Tapper EB, Malik R, et al. Causes and rates of 30-day readmissions after transjugular intrahepatic portosystemic shunts. *AJR Am J Roentgenol* 2020;215:235–241. <https://doi.org/10.2214/AJR.19.1732>.
- [45] Coronado WM, Ju C, Bullen J, Kapoor B. Predictors of occurrence and risk of hepatic encephalopathy after TIPS creation: a 15-year experience. *Cardiovasc Intervent Radiol* 2020;43:1156–1164. <https://doi.org/10.1007/s00270-020-02512-7>.
- [46] Khan A, Maheshwari S, Gupta K, Naseem K, Chowdry M, Singh S. Rate, reasons, predictors, and burden of readmissions after transjugular intrahepatic portosystemic shunt placement. *J Gastroenterol Hepatol* 2021;36:775–781. <https://doi.org/10.1111/jgh.15194>.
- [47] Bureau C, Thabut D, Jezequel C, Archambeaud I, D'Alteroche L, Dharancy S, et al. The use of rifaximin in the prevention of overt hepatic encephalopathy after transjugular intrahepatic portosystemic shunt : a randomized controlled trial. *Ann Intern Med* 2021;174:633–640. <https://doi.org/10.7326/M20-0202>.
- [48] Pereira K, Carrion AF, Salsamendi J, Doshi M, Baker R, Kably I. Endovascular management of refractory hepatic encephalopathy complication of transjugular intrahepatic portosystemic shunt (TIPS): comprehensive review and clinical practice algorithm. *Cardiovasc Intervent Radiol* 2016;39:170–182. <https://doi.org/10.1007/s00270-015-1197-x>.
- [49] Borentain P, Soussan J, Resseguier N, Botta-Fridlund D, Dufour JC, Gérolami R, et al. The presence of spontaneous portosystemic shunts increases the risk of complications after transjugular intrahepatic portosystemic shunt (TIPS) placement. *Diagn Interv Imaging* 2016;97:643–650. <https://doi.org/10.1016/j.diii.2016.02.004>.
- [50] Bettinger D, Sturm L, Pfaff L, Hahn F, Kloeckner R, Volkwein L, et al. Refining prediction of survival after TIPS with the novel Freiburg index of post-TIPS survival. *J Hepatol* 2021;74:1362–1372. <https://doi.org/10.1016/j.jhep.2021.01.023>.
- [51] Praktijnjo M, Clees C, Pigliacelli A, Fischer S, Jansen C, Lehmann J, et al. Sarcopenia is associated with development of acute-on-chronic liver failure in decompensated liver cirrhosis receiving transjugular intrahepatic portosystemic shunt. *Clin Transl Gastroenterol* 2019;10:e00025. <https://doi.org/10.14309/ctg.0000000000000025>.
- [52] Billey C, Billet S, Robic MA, Cognet T, Guillaume M, Vinel JP, et al. A prospective study identifying predictive factors of cardiac decompensation after transjugular intrahepatic portosystemic shunt: the Toulouse algorithm. *Hepatology* 2019;70:1928–1941. <https://doi.org/10.1002/hep.30934>.
- [53] Perarnau JM, Le Gouge A, Nicolas C, d'Alteroche L, Borentain P, Saliba F, et al. Covered vs. uncovered stents for transjugular intrahepatic portosystemic shunt: a randomized controlled trial. *J Hepatol* 2014;60:962–968. <https://doi.org/10.1016/j.jhep.2014.01.015>.
- [54] Saad WE, Lippert A, Saad NE, Caldwell S. Ectopic varices: anatomical classification, hemodynamic classification, and hemodynamic-based management. *Tech Vasc Interv Radiol* 2013;16:158–175. <https://doi.org/10.1053/j.tvir.2013.02.004>.
- [55] Vidal V, Joly L, Perreault P, Bouchard L, Lafortune M, Pomier-Layrargues G. Usefulness of transjugular intrahepatic portosystemic shunt in the management of bleeding ectopic varices in cirrhotic patients. *Cardiovasc Intervent Radiol* 2006;29:216–219. <https://doi.org/10.1007/s00270-004-0346-4>.
- [56] Vangeli M, Patch D, Terreni N, Tibballs J, Watkinson A, Davies N, et al. Bleeding ectopic varices—treatment with transjugular intrahepatic porto-systemic shunt (TIPS) and embolisation. *J Hepatol* 2004;41:560–566. <https://doi.org/10.1016/j.jhep.2004.06.024>.
- [57] Oey RC, de Wit K, Moelker A, Atalik T, van Delden OM, Maleux G, et al. Variable efficacy of TIPSS in the management of ectopic variceal bleeding: a multicentre retrospective study. *Aliment Pharmacol Ther* 2018;48:975–983. <https://doi.org/10.1111/apt.14947>.
- [58] Deipolyi AR, Kalva SP, Oklu R, Walker TG, Wicky S, Ganguli S. Reduction in portal venous pressure by transjugular intrahepatic portosystemic shunt for treatment of hemorrhagic stomal varices. *AJR Am J Roentgenol* 2014;203:668–673. <https://doi.org/10.2214/AJR.13.12211>.
- [59] Bai M, Qi XS, Yang ZP, Wu KC, Fan DM, Han GH. EVS vs. TIPS shunt for gastric variceal bleeding in patients with cirrhosis: a meta-analysis. *World J Gastrointest Pharmacol Ther* 2014;5:97–104. <https://doi.org/10.4292/wjgpt.v5.i2.97>.
- [60] Lv Y, Zuo L, Zhu X, Zhao J, Xue H, Jiang Z, et al. Identifying optimal candidates for early TIPS among patients with cirrhosis and acute variceal bleeding: a multicentre observational study. *Gut* 2019;68:1297–1310. <https://doi.org/10.1136/gutjnl-2018-317057>.
- [61] Nicoară-Farcău O, Han G, Rudler M, Angrisani D, Monescillo A, Torres F, et al. Effects of early placement of transjugular portosystemic shunts in patients with high-risk acute variceal bleeding: a meta-analysis of individual patient data. *Gastroenterology* 2021;160:193–205.e10. <https://doi.org/10.1053/j.gastro.2020.09.026>.
- [62] Thabut D, Pauwels A, Carbonell N, Remy AJ, Nahon P, Causse X, et al. Cirrhotic patients with portal hypertension-related bleeding and an indication for early-TIPS: a large multicentre audit with real-life results. *J Hepatol* 2017;68:73–81. <https://doi.org/10.1016/j.jhep.2017.09.002>.
- [63] Expert Panel on Interventional Radiology, Kim CY, Pinchot JW, Ahmed O, Braun AR, Cash BD, et al. ACR appropriateness criteria® radiologic management of gastric varices. *J Am Coll Radiol* 2020;17:S239–S254. <https://doi.org/10.1016/j.jacr.2020.01.017>.
- [64] Liu J, Yang C, Huang S, Zhou C, Shi Q, Qian K, et al. The combination of balloon-assisted antegrade transvenous obliteration and transjugular intrahepatic portosystemic shunt for the management of cardiofundal varices hemorrhage. *Eur J Gastroenterol Hepatol* 2020;32:656–662. <https://doi.org/10.1097/MEG.0000000000001705>.
- [65] Paleti S, Notalapati V, Fathallah J, Jeepalyam S, Rustagi T. Balloon-occluded retrograde transvenous obliteration (BRTO) versus transjugular intrahepatic portosystemic shunt (TIPS) for treatment of gastric varices because of portal hypertension: a systematic review and meta-analysis. *J Clin Gastroenterol* 2020;54:655–660. <https://doi.org/10.1097/MCG.0000000000001275>.
- [66] Saad WE. Combining transjugular intrahepatic portosystemic shunt with balloon-occluded retrograde transvenous obliteration or augmenting TIPS with variceal embolization for the management of gastric varices: an evolving middle ground? *Semin Intervent Radiol* 2014;31:266–268. <https://doi.org/10.1055/s-0034-1382796>.
- [67] Loffroy R, Favelier S, Pottecher P, Estivalet L, Genson PY, Gehin S, et al. Transjugular intrahepatic portosystemic shunt for acute variceal gastrointestinal bleeding: indications, techniques and outcomes. *Diagn Interv Imaging* 2015;96:745–755. <https://doi.org/10.1016/j.diii.2015.05.005>.
- [68] Yu J, Wang X, Jiang M, Ma H, Zhou Z, Yang L, et al. Comparison of transjugular intrahepatic portosystemic shunt (TIPS) alone and combined with embolisation for the management of cardiofundal varices: a retrospective study. *Eur Radiol* 2019;29:699–706. <https://doi.org/10.1007/s00330-018-5645-2>.
- [69] Chen S, Li X, Wei B, Tong H, Zhang MG, Huang ZY, et al. Recurrent variceal bleeding and shunt patency: prospective randomized controlled trial of transjugular intrahepatic portosystemic shunt alone or combined with coronary vein embolization. *Radiology* 2013;268:900–906. <https://doi.org/10.1148/radiol.13120800>.

- [70] Qi X, Liu L, Bai M, Chen H, Wang J, Yang Z, et al. Transjugular intrahepatic portosystemic shunt in combination with or without variceal embolization for the prevention of variceal rebleeding: a meta-analysis. *J Gastroenterol Hepatol* 2014;29:688–696. <https://doi.org/10.1111/jgh.12391>.
- [71] Wan YM, Li YH, Xu ZY, Wu HM, Wu XN, Xu Y. Comparison of TIPS alone and combined with partial splenic embolization (PSE) for the management of variceal bleeding. *Eur Radiol* 2019;29:5032–5041. <https://doi.org/10.1007/s00330-019-06046-6>.
- [72] Li YH, Wu JF, Wu HM, Wu XN, Xu Y, Wan YM. The effect of transjugular intrahepatic portosystemic shunt plus partial splenic embolization for the treatment of patients with recurrent variceal bleeding. *Acad Radiol* 2020;27:323–331. <https://doi.org/10.1016/j.acra.2019.04.013>.
- [73] Bosch J. Small diameter shunts should lead to safe expansion of the use of TIPS. *J Hepatol* 2021;74:230–234. <https://doi.org/10.1016/j.jhep.2020.09.018>.
- [74] Chung HH, Razavi MK, Sze DY, Frisoli JK, Kee ST, Dake MD, et al. Portosystemic pressure gradient during transjugular intrahepatic portosystemic shunt with Viatorr stent graft: what is the critical low threshold to avoid medically uncontrolled low pressure gradient related complications? *J Gastroenterol Hepatol* 2008;23:95–101. <https://doi.org/10.1111/j.1440-1746.2006.04697.x>.
- [75] Riggio O, Ridola L, Angeloni S, Cerini F, Pasquale C, Attili AF, et al. Clinical efficacy of transjugular intrahepatic portosystemic shunt created with covered stents with different diameters: results of a randomized controlled trial. *J Hepatol* 2010;53:267–272. <https://doi.org/10.1016/j.jhep.2010.02.033>.
- [76] Miraglia R, Maruzzelli L, Tuzzolino F, Petridis I, D'Amico M, Luca A. Transjugular intrahepatic portosystemic shunts in patients with cirrhosis with refractory ascites: comparison of clinical outcomes by using 8- and 10-mm PTFE-covered stents. *Radiology* 2017;284:281–288. <https://doi.org/10.1148/radiol.2017161644>.
- [77] Trebicka J, Bastgen D, Byrtus J, Praktikno M, Terstiegen S, Meyer C, et al. Smaller-diameter covered transjugular intrahepatic portosystemic shunt stents are associated with increased survival. *Clin Gastroenterol Hepatol* 2019;17:2793–2799.e1. <https://doi.org/10.1016/j.cgh.2019.03.042>.
- [78] Luo X, Wang X, Zhu Y, Xi X, Zhao Y, Yang J, et al. Clinical efficacy of transjugular intrahepatic portosystemic shunt created with expanded polytetrafluoroethylene-covered stent-grafts: 8-mm versus 10-mm. *Cardiovasc Intervent Radiol* 2019;42:737–743. <https://doi.org/10.1007/s00270-019-02162-4>.
- [79] Huang Z, Yao Q, Zhu J, He Y, Chen Y, Wu F, et al. Efficacy and safety of transjugular intrahepatic portosystemic shunt (TIPS) created using covered stents of different diameters: a systematic review and meta-analysis. *Diagn Interv Imaging* 2021;102:279–285. <https://doi.org/10.1016/j.diii.2020.11.004>.
- [80] Praktikno M, Abu-Omar J, Chang J, Thomas D, Jansen C, Kupczyk P, et al. Controlled underdilation using novel VIATORR® controlled expansion stents improves survival after transjugular intrahepatic portosystemic shunt implantation. *JHEP Rep* 2021;3:100264. <https://doi.org/10.1016/j.jhepr.2021.100264>.
- [81] Bissonnette J, Garcia-Pagán JC, Albillos A, Turon F, Ferreira C, Tellez L, et al. Role of the transjugular intrahepatic portosystemic shunt in the management of severe complications of portal hypertension in idiopathic noncirrhotic portal hypertension. *Hepatology* 2016;64:224–231. <https://doi.org/10.1002/hep.28547>.
- [82] Luo X, Nie L, Zhou B, Yao D, Ma H, Jiang M, et al. Transjugular intrahepatic portosystemic shunt for the treatment of portal hypertension in noncirrhotic patients with portal cavernoma. *Gastroenterol Res Pract* 2014;2014:659726. <https://doi.org/10.1155/2014/659726>.
- [83] Fanelli F, Angeloni S, Salvatori FM, Marzano C, Boatta E, Merli M, et al. Transjugular intrahepatic portosystemic shunt with expanded-polytetrafluoroethylene-covered stents in non-cirrhotic patients with portal cavernoma. *Dig Liver Dis* 2011;43:78–84. <https://doi.org/10.1016/j.dld.2010.06.001>.
- [84] Qi X, Han G, Yin Z, He C, Wang J, Guo W, et al. Transjugular intrahepatic portosystemic shunt for portal cavernoma with symptomatic portal hypertension in non-cirrhotic patients. *Dig Dis Sci* 2012;57:1072–1082. <https://doi.org/10.1007/s10620-011-1975-5>.
- [85] Knight GM, Clark J, Boike JR, Maddur H, Ganger DR, Talwar A, et al. TIPS for adults without cirrhosis with chronic mesenteric venous thrombosis and EHPVO refractory to standard-of-care therapy. *Hepatology* 2021;74:2735–2744. <https://doi.org/10.1002/hep.31915>.
- [86] Yadav A, Gangwani G, Mishra N, Gupta A. Percutaneous transhepatic approach for recanalization of superior mesenteric and portal vein in a patient with pancreatic neuroendocrine tumor presenting with bleeding duodenal varices: a brief case report. *J Clin Exp Hepatol* 2018;8:318–320. <https://doi.org/10.1016/j.jceh.2018.03.003>.
- [87] Rodrigues SG, Maurer MH, Baumgartner I, De Gottardi A, Berzigotti A. Imaging and minimally invasive endovascular therapy in the management of portal vein thrombosis. *Abdom Radiol (NY)* 2018;43:1931–1946. <https://doi.org/10.1007/s00261-017-1335-9>.
- [88] Marot A, Barbosa JV, Duran R, Deltenre P, Denys A. Percutaneous portal vein recanalization using self-expandable nitinol stents in patients with non-cirrhotic non-tumoral portal vein occlusion. *Diagn Interv Imaging* 2019;100:147–156. <https://doi.org/10.1016/j.diii.2018.07.009>.
- [89] Kim KR, Ko GY, Sung KB, Yoon HK. Percutaneous transhepatic stent placement in the management of portal venous stenosis after curative surgery for pancreatic and biliary neoplasms. *AJR Am J Roentgenol* 2011;196:W446–450. <https://doi.org/10.2214/AJR.10.5274>.
- [90] Valla DC. Recent developments in the field of vascular liver diseases. *Liver Int* 2020;40(Suppl 1):142–148. <https://doi.org/10.1111/liv.14348>.
- [91] Kim KS, Kim JM, Lee JS, Choi GS, Cho JW, Lee SK. Stent insertion and balloon angioplasty for portal vein stenosis after liver transplantation: long-term follow-up results. *Diagn Interv Radiol* 2019;25:231–237. <https://doi.org/10.5152/dir.2019.18155>.
- [92] Sare A, Chandra V, Shanmugasundaram S, Shukla PA, Kumar A. Safety and efficacy of endovascular treatment of portal vein stenosis in liver transplant recipients: a systematic review. *Vasc Endovasc Surg* 2021;55:452–460. <https://doi.org/10.1177/1538574421994417>.
- [93] Luo J, Yan Z, Wang J, Liu Q, Qu X. Endovascular treatment for nonacute symptomatic portal venous thrombosis through intrahepatic portosystemic shunt approach. *J Vasc Interv Radiol* 2011;22:61–69. <https://doi.org/10.1016/j.jvir.2010.07.028>.
- [94] Hall TC, Garcea G, Metcalfe M, Bilku D, Dennison AR. Management of acute non-cirrhotic and non-malignant portal vein thrombosis: a systematic review. *World J Surg* 2011;35:2510–2520. <https://doi.org/10.1007/s00268-011-1198-0>.
- [95] Rössle M, Bettinger D, Trebicka J, Klinger C, Praktikno M, Sturm L, et al. A prospective, multicentre study in acute non-cirrhotic, non-malignant portal vein thrombosis: comparison of medical and interventional treatment. *Aliment Pharmacol Ther* 2020;52:329–339. <https://doi.org/10.1111/apt.15811>.
- [96] Woodrum DA, Bjarnason H, Andrews JC. Portal vein venoplasty and stent placement in the nontransplant population. *J Vasc Interv Radiol* 2009;20:593–599. <https://doi.org/10.1016/j.jvir.2009.02.010>.
- [97] Hasegawa T, Yamakado K, Takaki H, Nakatsuka A, Uraki J, Yamanaka T, et al. Portal venous stent placement for malignant portal venous stenosis or occlusion: who benefits? *Cardiovasc Intervent Radiol* 2015;38:1515–1522. <https://doi.org/10.1007/s00270-015-1123-2>.
- [98] Thornburg B, Desai K, Hickey R, Kulik L, Ganger D, Baker T, et al. Portal vein recanalization and transjugular intrahepatic portosystemic shunt creation for chronic portal vein thrombosis: technical considerations. *Tech Vasc Interv Radiol* 2016;19:52–60. <https://doi.org/10.1053/j.tvir.2016.01.00>.
- [99] Rosenqvist K, Eriksson LG, Rorsman F, Sangfelt P, Nyman R. Endovascular treatment of acute and chronic portal vein thrombosis in patients with cirrhotic and non-cirrhotic liver. *Acta Radiol* 2016;57:572–579. <https://doi.org/10.1177/0284185115595060>.
- [100] Salem R, Vouche M, Baker T, Herrero JL, Caicedo JC, Fryer J, et al. Pretransplant portal vein recanalization-transjugular intrahepatic portosystemic shunt in patients with complete obliterative portal vein thrombosis. *Transplantation* 2015;99:2347–2355. <https://doi.org/10.1097/TP.0000000000000729>.
- [101] Barbier CE, Rorsman F, Eriksson LG, Sangfelt P, Sheikhi R, Vessby J, et al. Placement of a transjugular intrahepatic portosystemic shunt in addition to recanalization of acute and chronic portomesenteric vein occlusions - a retrospective evaluation. *Acta Radiol Open* 2020;9. <https://doi.org/10.1177/2058460120964074>. 2058460120964074.
- [102] Habib A, Desai K, Hickey R, Thornburg B, Vouche M, Vogelzang RL, et al. Portal vein recanalization-transjugularintrahepatic portosystemic shunt using the transsplenic approach to achieve transplant candidacy in patients with chronic portal vein thrombosis. *J Vasc Interv Radiol* 2015;26:499–506. <https://doi.org/10.1016/j.jvir.2014.12.012>.
- [103] Thornburg B, Desai K, Hickey R, Hohlastos E, Kulik L, Ganger D, et al. Pretransplantation portal vein recanalization and transjugular intrahepatic portosystemic shunt creation for chronic portal vein thrombosis:

- final analysis of a 61-patient cohort. *J Vasc Interv Radiol* 2017;28:1714–1721.e2. <https://doi.org/10.1016/j.jvir.2017.08.005>.
- [104] Vauthey JN, Dixon E, Abdalla EK, Helton WS, Pawlik TM, Taouli B, et al. Pretreatment assessment of hepatocellular carcinoma: expert consensus statement. *HPB (Oxford)* 2010;12:289–299. <https://doi.org/10.1111/j.1477-2574.2010.00181.x>.
- [105] Denys A, Prior J, Bize P, Duran R, De Baere T, Halkic N, et al. Portal vein embolization: what do we know? *Cardiovasc Intervent Radiol* 2012;35:999–1008. <https://doi.org/10.1007/s00270-011-0300-1>.
- [106] Downing TM, Khan SN, Zvavanjanja RC, Bhatti Z, Pillai AK, Kee ST. Portal venous interventions: how to recognize, avoid, or get out of trouble in transjugular intrahepatic portosystemic shunt (TIPS), balloon occlusion sclerosis (ie, BRTO), and portal vein embolization (PVE). *Tech Vasc Interv Radiol* 2018;21:267–287. <https://doi.org/10.1053/j.tvir.2018.07.009>.
- [107] van Lienden KP, van den Esschert JW, de Graaf W, Bipat S, Lameris JS, van Gulik TM, et al. Portal vein embolization before liver resection: a systematic review. *Cardiovasc Intervent Radiol* 2013;36:25–34. <https://doi.org/10.1007/s00270-012-0440-y>.
- [108] Ishizawa T, Hasegawa K, Sano K, Imamura H, Kokudo N, Makuuchi M. Selective versus total biliary drainage for obstructive jaundice caused by a hepatobiliary malignancy. *Am J Surg* 2007;193:149–154. <https://doi.org/10.1016/j.amjsurg.2006.07.015>.
- [109] Hameed A, Pang T, Chiou J, Pleass H, Lam V, Hollands M, et al. Percutaneous vs. endoscopic pre-operative biliary drainage in hilar cholangiocarcinoma - a systematic review and meta-analysis. *HPB (Oxford)* 2016;18:400–410. <https://doi.org/10.1016/j.hpb.2016.03.002>.
- [110] Miura S, Kanno A, Fukase K, Tanaka Y, Matsumoto R, Nabeshima T, et al. Preoperative biliary drainage of the hepatic lobe to be resected does not affect liver hypertrophy after percutaneous transhepatic portal vein embolization. *Surg Endosc* 2020;34:667–674. <https://doi.org/10.1007/s00464-019-06813-y>.
- [111] Isfordink CJ, Samim M, Braat MNGJA, Almalki AM, Hagendoorn J, Borel Rinkes IHM, et al. Portal vein ligation versus portal vein embolization for induction of hypertrophy of the future liver remnant: a systematic review and meta-analysis. *Surg Oncol* 2017;26:257–267. <https://doi.org/10.1016/j.suronc.2017.05.001>.
- [112] Schnitzbauer AA, Lang SA, Goessmann H, Nadalin S, Baumgart J, Farkas SA, et al. Right portal vein ligation combined with in situ splitting induces rapid left lateral liver lobe hypertrophy enabling 2-staged extended right hepatic resection in small-for-size settings. *Ann Surg* 2012;255:405–414. <https://doi.org/10.1097/SLA.0b013e31824856f5>.
- [113] Truant S, Scatton O, Dokmak S, Regimbeau JM, Lucidi V, Laurent A, et al. Associating liver partition and portal vein ligation for staged hepatectomy (ALPPS): impact of the inter-stages course on morbi-mortality and implications for management. *Eur J Surg Oncol* 2015;41:674–682. <https://doi.org/10.1016/j.ejso.2015.01.004>.
- [114] Buc S, Schadde E, Schnitzbauer AA, Vogt K, Hernandez-Alejandro R. The many faces of ALPPS: surgical indications and techniques among surgeons collaborating in the international registry. *HPB (Oxford)* 2016;18:442–448. <https://doi.org/10.1016/j.hpb.2016.01.547>.
- [115] Eshmunov D, Raptis DA, Linecker M, Wirsching A, Lesurtel M, Clavien PA. Meta-analysis of associating liver partition with portal vein ligation and portal vein occlusion for two-stage hepatectomy. *Br J Surg* 2016;103:1768–1782. <https://doi.org/10.1002/bjs.10290>.
- [116] Shindoh J, Tzeng CW, Aloia TA, Curley SA, Huang SY, Mahvash A, et al. Safety and efficacy of portal vein embolization before planned major or extended hepatectomy: an institutional experience of 358 patients. *J Gastrointest Surg* 2014;18:45–51. <https://doi.org/10.1007/s11605-013-2369-0>.
- [117] Glantzounis GK, Tokidis E, Basourakos SP, Ntzani EE, Lianos GD, Pentheroudakis G. The role of portal vein embolization in the surgical management of primary hepatobiliary cancers. A systematic review. *Eur J Surg Oncol* 2017;43:32–41. <https://doi.org/10.1016/j.ejso.2016.05.026>.
- [118] Ironside N, Bell R, Bartlett A, McCall J, Powell J, Pandanaboyana S. Systematic review of perioperative and survival outcomes of liver resections with and without preoperative portal vein embolization for colorectal metastases. *HPB (Oxford)* 2017;19:559–566. <https://doi.org/10.1016/j.hpb.2017.03.003>.
- [119] Shindoh J, Tzeng CW, Aloia TA, Curley SA, Zimmiti G, Wei SH, et al. Portal vein embolization improves rate of resection of extensive colorectal liver metastases without worsening survival. *Br J Surg* 2013;100:1777–1783. <https://doi.org/10.1002/bjs.9317>.
- [120] Ogata S, Belghiti J, Farges O, Varma D, Sibert A, Vilgrain V. Sequential arterial and portal vein embolizations before right hepatectomy in patients with cirrhosis and hepatocellular carcinoma. *Br J Surg* 2006;93:1091–1098. <https://doi.org/10.1002/bjs.5341>.
- [121] Yoo H, Kim JH, Ko GY, Kim KW, Gwon DI, Lee SG, et al. Sequential transcatheter arterial chemoembolization and portal vein embolization versus portal vein embolization only before major hepatectomy for patients with hepatocellular carcinoma. *Ann Surg Oncol* 2011;18:1251–1257. <https://doi.org/10.1245/s10434-010-1423-3>.
- [122] Ronot M, Cauchy F, Gregoli B, Breguet R, Allaham W, Paradis V, et al. Sequential transarterial chemoembolization and portal vein embolization before resection is a valid oncological strategy for unilobar hepatocellular carcinoma regardless of the tumor burden. *HPB (Oxford)* 2016;18:684–690. <https://doi.org/10.1016/j.hpb.2016.05.012>.
- [123] Bekki Y, Marti J, Toshima T, Lewis S, Kamath A, Argiriadi P, et al. A comparative study of portal vein embolization versus radiation lobectomy with Yttrium-90 micropheres in preparation for liver resection for initially unresectable hepatocellular carcinoma. *Surgery* 2021;169:1044–1051. <https://doi.org/10.1016/j.surg.2020.12.012>.
- [124] Garlipp B, de Baere T, Damm R, Irmischer R, van Buskirk M, Stübs P, et al. Left-liver hypertrophy after therapeutic right-liver radioembolization is substantial but less than after portal vein embolization. *Hepatology* 2014;59:1864–1873. <https://doi.org/10.1002/hep.26947>.
- [125] Di Stefano DR, de Baere T, Denys A, Hakime A, Gorin G, Gillet M, et al. Preoperative percutaneous portal vein embolization: evaluation of adverse events in 188 patients. *Radiology* 2005;234:625–630. <https://doi.org/10.1148/radiol.2342031996>.
- [126] Yeom YK, Shin JH. Complications of portal vein embolization: evaluation on cross-sectional imaging. *Korean J Radiol* 2015;16:1079–1085. <https://doi.org/10.3348/kjr.2015.16.5.1079>.
- [127] Guiu B, Bize P, Gunther D, Demartines N, Halkic N, Denys A. Portal vein embolization before right hepatectomy: improved results using n-butylcyanoacrylate compared to microparticles plus coils. *Cardiovasc Intervent Radiol* 2013;36:1306–1312. <https://doi.org/10.1007/s00270-013-0565-7>.
- [128] Dhaliwal SK, Annamalai G, Fafoor N, Pugash R, Dey C, David EN. Portal vein embolization: correlation of future liver remnant hypertrophy to type of embolic agent used. *Can Assoc Radiol J* 2018;69:316–321. <https://doi.org/10.1016/j.carj.2018.02.003>.
- [129] Jaber A, Toor SS, Rajan DK, Mironov O, Kachura JR, Cleary SP, et al. Comparison of clinical outcomes following glue versus polyvinyl alcohol portal vein embolization for hypertrophy of the future liver remnant prior to right hepatectomy. *J Vasc Interv Radiol* 2016;27:1897–1905.e1. <https://doi.org/10.1016/j.jvir.2016.05.023>.
- [130] Sugawara S, Arai Y, Sone M, Nara S, Kishi Y, Esaki M, et al. Retrospective comparative study of absolute ethanol with N-Butyl-2-Cyanoacrylate in percutaneous portal vein embolization. *J Vasc Interv Radiol* 2019;30:1215–1222. <https://doi.org/10.1016/j.jvir.2018.12.020>.
- [131] Ali A, Ahle M, Björnsson B, Sandström P. Portal vein embolization with N-butyl cyanoacrylate glue is superior to other materials: a systematic review and meta-analysis. *Eur Radiol* 2021;31:5464–5478. <https://doi.org/10.1007/s00330-020-07685-w>.
- [132] Luz JHM, Veloso Gomes F, Costa NV, Vasco I, Coimbra E, Luz PM, et al. BestFLR trial: liver regeneration at CT before major hepatectomies for liver cancer-A randomized controlled trial comparing portal vein embolization with N-butyl-cyanoacrylate plus iodized oil versus polyvinyl alcohol particles plus coils. *Radiology* 2021;299:715–724. <https://doi.org/10.1148/radiol.2021204055>.
- [133] Malinowski M, Stary V, Lock JF, Schulz A, Jara M, Seehofer D, et al. Factors influencing hypertrophy of the left lateral liver lobe after portal vein embolization. *Langenbecks Arch Surg* 2015;400:237–246. <https://doi.org/10.1007/s00423-014-1266-7>.
- [134] Fischer C, Melstrom LG, Arnaoutakis D, Jarnagin W, Brown K, D'Angelica M, et al. Chemotherapy after portal vein embolization to protect against tumor growth during liver hypertrophy before hepatectomy. *JAMA Surg* 2013;148:1103–1108. <https://doi.org/10.1001/jamasurg.2013.2126>.
- [135] Zorzi D, Chun YS, Madoff DC, Abdalla EK, Vauthey JN. Chemotherapy with bevacizumab does not affect liver regeneration after portal vein embolization in the treatment of colorectal liver metastases. *Ann Surg Oncol* 2008;15:2765–2772. <https://doi.org/10.1245/s10434-008-0035-7>.
- [136] Aussilhou B, Dokmak S, Faivre S, Paradis V, Vilgrain V, Belghiti J. Preoperative liver hypertrophy induced by portal flow occlusion before major hepatic resection for colorectal metastases can be impaired by bevacizumab. *Ann Surg Oncol* 2009;16:1553–1559. <https://doi.org/10.1245/s10434-009-0447-z>.

- [137] Guiu B, Chevallier P, Denys A, Delhom E, Pierredon-Foulongne MA, Rouanet P, et al. Simultaneous trans-hepatic portal and hepatic vein embolization before major hepatectomy: the liver venous deprivation technique. *Eur Radiol* 2016;26:4259–4267. <https://doi.org/10.1007/s00330-016-4291-9>.
- [138] Laurent C, Fernandez B, Marichez A, Adam JP, Papadopoulos P, Lapuyade B, et al. Radiological simultaneous portohepatic vein embolization (RASPE) before major hepatectomy: a better way to optimize liver hypertrophy compared to portal vein embolization. *Ann Surg* 2020;272:199–205. <https://doi.org/10.1097/SLA.0000000000003905>.
- [139] Hocquelet A, Sotiriadis C, Duran R, Guiu B, Yamaguchi T, Halkic N, et al. Preoperative portal vein embolization alone with biliary drainage compared to a combination of simultaneous portal vein, right hepatic vein embolization and biliary drainage in Klatskin tumor. *Cardiovasc Intervent Radiol* 2018;41:1885–1891. <https://doi.org/10.1007/s00270-018-2075-0>.
- [140] Kobayashi K, Yamaguchi T, Denys A, Perron L, Halkic N, Demartines N, et al. Liver venous deprivation compared to portal vein embolization to induce hypertrophy of the future liver remnant before major hepatectomy: a single center experience. *Surgery* 2020;167:917–923. <https://doi.org/10.1016/j.surg.2019.12.006>.
- [141] Le Roy B, Gallon A, Cauchy F, Pereira B, Gagnière J, Lambert C, et al. Combined biembolization induces higher hypertrophy than portal vein embolization before major liver resection. *HPB (Oxford)* 2020;22:298–305. <https://doi.org/10.1016/j.hpb.2019.08.005>.
- [142] Esposito F, Lim C, Lahat E, Shwaartz C, Eshkenazy R, Salloum C, et al. Combined hepatic and portal vein embolization as preparation for major hepatectomy: a systematic review. *HPB (Oxford)* 2019;21:1099–1106. <https://doi.org/10.1016/j.hpb.2019.02.023>.
- [143] Guiu B, Quenet F, Escal L, Bibeau F, Piron L, Rouanet P, et al. Extended liver venous deprivation before major hepatectomy induces marked and very rapid increase in future liver remnant function. *Eur Radiol* 2017;27:3343–3352. <https://doi.org/10.1007/s00330-017-4744-9>.
- [144] Khayat S, Cassese G, Quenet F, Cassinotto C, Assenat E, Navarro F, et al. Oncological outcomes after liver venous deprivation for colorectal liver metastases: a single center experience. *Cancers (Basel)* 2021;13:200. <https://doi.org/10.3390/cancers13020200>.
- [145] Deshayes E, Piron L, Bouvier A, Lapuyade B, Lermite E, Vervueren L, et al. Study protocol of the HYPER-LIV01 trial: a multicenter phase II, prospective and randomized study comparing simultaneous portal and hepatic vein embolization to portal vein embolization for hypertrophy of the future liver remnant before major hepatectomy for colo-rectal liver metastases. *BMC Cancer* 2020;20:574. <https://doi.org/10.1186/s12885-020-07065-z>.
- [146] Piron L, Deshayes E, Cassinotto C, Quenet F, Panaro F, Hermida M, et al. Deportalization, venous congestion, venous deprivation: serial measurements of volumes and functions on morphofunctional <sup>99m</sup>Tc-mebrofenin SPECT-CT. *Diagnostics (Basel)* 2020;11:12. <https://doi.org/10.3390/diagnostics11010012>.
- [147] Guiu B, Quenet F, Panaro F, Piron L, Cassinotto C, Herrero A, et al. Liver venous deprivation versus portal vein embolization before major hepatectomy: future liver remnant volumetric and functional changes. *Hepatobiliary Surg Nutr* 2020;9:564–576. <https://doi.org/10.21037/hbsn.2020.02.06>.
- [148] Kishi Y, Madoff DC, Abdalla EK, Palavecino M, Ribero D, Chun YS, et al. Is embolization of segment 4 portal veins before extended right hepatectomy justified? *Surgery* 2008;144:744–751. <https://doi.org/10.1016/j.surg.2008.05.015>.
- [149] Björnsson B, Hasselgren K, Røsoek B, Larsen PN, Urdzik J, Schultz NA, et al. Segment 4 occlusion in portal vein embolization increase future liver remnant hypertrophy - a Scandinavian cohort study. *Int J Surg* 2020;75:60–65. <https://doi.org/10.1016/j.ijvsu.2020.01.129>.
- [150] Ito J, Komada T, Suzuki K, Matsushima M, Nakatochi M, Kobayashi Y, et al. Evaluation of segment 4 portal vein embolization added to right portal vein for right hepatic trisectionectomy: a retrospective propensity score-matched study. *J Hepatobiliary Pancreat Sci* 2020;27:299–306. <https://doi.org/10.1002/jhbp.723>.
- [151] Hammond CJ, Ali S, Haq H, Luo L, Wyatt JJ, Toogood GJ, et al. Segment 2/3 hypertrophy is greater when right portal vein embolisation is extended to segment 4 in patients with colorectal liver metastases: a retrospective cohort study. *Cardiovasc Intervent Radiol* 2019;42:552–559. <https://doi.org/10.1007/s00270-018-02159-5>.
- [152] Alvarez FA, Castaing D, Figueroa R, Allard MA, Golse N, Pittau G, et al. Natural history of portal vein embolization before liver resection: a 23-year analysis of intention-to-treat results. *Surgery* 2018;163:1257–1263. <https://doi.org/10.1016/j.surg.2017.12.027>.
- [153] Loveday BPT, Jaber A, Moulton CA, Wei AC, Gallinger S, Beecroft R, et al. Effect of portal vein embolization on treatment plan prior to major hepatectomy for hepatocellular carcinoma. *HPB (Oxford)* 2019;21:1072–1078. <https://doi.org/10.1016/j.hpb.2018.12.009>.
- [154] Lim C, Cauchy F, Azoulay D, Farges O, Ronot M, Pocard M. Tumour progression and liver regeneration—insights from animal models. *Nat Rev Gastroenterol Hepatol* 2013;10:452–462. <https://doi.org/10.1038/nrgastro.2013.55>.
- [155] Simoneau E, Aljiffry M, Salman A, Abualhassan N, Cabrera T, Valenti D, et al. Portal vein embolization stimulates tumour growth in patients with colorectal cancer liver metastases. *HPB (Oxford)* 2012;14:461–468. <https://doi.org/10.1111/j.1477-2574.2012.00476.x>.
- [156] Imai K, Yamashita YI, Nakao Y, Uemura N, Kitamura F, Miyata T, et al. Is disease progression a contraindication for the strategy of portal vein embolization followed by hepatectomy for hepatocellular carcinoma? *Surgery* 2019;165:696–702. <https://doi.org/10.1016/j.surg.2018.10.023>.
- [157] Giglio MC, Giakoustidis A, Draz A, Jawad ZAR, Pai M, Habib NA, et al. Oncological outcomes of major liver resection following portal vein embolization: a systematic review and meta-analysis. *Ann Surg Oncol* 2016;23:3709–3717. <https://doi.org/10.1245/s10434-016-5264-6>.
- [158] Pommier R, Ronot M, Cauchy F, Gaujoux S, Fuks D, Faivre S, et al. Colorectal liver metastases growth in the embolized and non-embolized liver after portal vein embolization: influence of initial response to induction chemotherapy. *Ann Surg Oncol* 2014;21:3077–3083. <https://doi.org/10.1245/s10434-014-3700-z>.
- [159] Spelt L, Sparrelid E, Isaksson B, Andersson RG, Stureson C. Tumour growth after portal vein embolization with pre-procedural chemotherapy for colorectal liver metastases. *HPB (Oxford)* 2015;17:529–535. <https://doi.org/10.1111/hpb.12397>.