




Contents lists available at ScienceDirect

Interdisciplinary Neurosurgery: Advanced Techniques and Case Management

journal homepage: www.inat-journal.com

Technical Note & Surgical Technique

The reconstructive role of TachoSil in neurosurgery

Graziano Francesca, MD^{*}, Maugeri Rosario, MD, PhD, Luigi Basile, MD, Carlo Guli', MD, Iacopino D. Gerardo, MD, PhD

Department of Experimental Biomedicine and Clinical Neurosciences Neurosurgical Clinic, AOPU "P. Giaccone" Università degli Studi di Palermo, Italy

ARTICLE INFO

Article history:

Received 14 July 2016

Revised 4 August 2016

Accepted 28 August 2016

ABSTRACT

Hemorrhages, cerebrospinal fluid (CSF) fistula and infections are the most challenging post-operative complications in Neurosurgery [1–5]. Fibrin sealant agents have been developed with the aim to provide efficient hemostasis and safe dural closure [3,6–14]. In this study we report our initial experience using TachoSil® (haemostatic surgical patch; Nycomed, Linz, Austria) in achieving hemostasis and CSF leakage repair during craniocerebral procedures [15–18]. We describe and show the unique features of this fibrin sealant, pioneered with stunning success in many surgical procedures known to be at high risk of peri- and postoperative bleeding (i.e. nephrectomies, pulmonary lobectomies, ballistic injuries, arthroplasties, coronary bypass graftings), but still not widely exploited at its best in the field of Neurosurgery.

© 2016 The Authors. Published by Elsevier B.V. This is an open access article under the CC BY-NC-ND license (<http://creativecommons.org/licenses/by-nc-nd/4.0/>).

1. Introduction

Dural repair remains a source of morbidity during and following neurosurgery operations. Postoperative cerebrospinal fluid (CSF) leakage remains the most serious and life-threatening complication. Persistent CSF leakage is a significant concern for surgeons, as this complication has been associated with increased time of hospitalization, worse neurological outcome, and development of CSF fistula [1–5].

During tumor removal, ventricular cavities opening may occur; in these cases, cerebrospinal fistula may become even more common [3, 6–14]. In particular, in cases of lesions involving the fourth ventricle, the aim of the surgery is to cover the surgical bed and restore the roof of the ventricle avoiding any potential compression. In this study, we analyze our experience of using TachoSil® (haemostatic surgical patch; Nycomed, Linz, Austria) in microneurosurgical procedures [15–18]. In five cases we used TachoSil as dural sealing and as ventricular wall restoring. It demonstrated to assure a safe and durable dural sealing and to reconstruct the regular ventricular anatomy eliminating the risky complication of ventricular occlusion.

2. Material and methods

A study was carried out in the Department of Neurosurgery at the University Hospital of Palermo upon approval of local institutional review board. Beginning on January 1, 2015 we prospectively analyzed 5 surgeries performed by the senior author (DGI), who used TachoSil®.

^{*} Corresponding author at: Department of Experimental Biomedicine and Clinical Neurosciences, Neurosurgical Clinic, AOPU "P. Giaccone" Università degli Studi di Palermo, Italy, 129, Via del Vespro, 90100 Palermo, Italy.

E-mail address: franeurosurgery@libero.it (G. Francesca).

The patient group included four women and one man; the mean age was 53 years old (range 40–67). Indications for surgery included removal of glial tumors in four cases and evacuation of intracranial hemorrhage in one case. The pterional approach was used most commonly to remove the tumors and a suboccipital craniectomy was performed in one patient affected by intracerebellar hemorrhage. During surgery TachoSil® served different purposes including bed covering after tumor resection, dural covering to ensure watertight closure and ventricular wall restoring following ventricles opening in the surgical fields. In 3 cases it was used to cover the frontal horn opening in the surgical field and as dural sealing (Fig. 1). In these cases the yellow side of the sponge was cut in the size of interest and applied with wet bayonet along the surgical bed and above the frontal horn opening (Fig. 2). In one case it was used only as dural sealing and in the remaining fifth case it was used to reconstruct the roof of the fourth ventricle after the evacuation of a massive intracerebellar hemorrhage.

3. Results

Patients received postoperative care according to local neurosurgical department protocol, including a postoperative CT scan after each craniotomy and a brain MRI within 3–4 days post tumor removal. Primary assessment of the wound took place during the hospital stay as well as at discharge or transfer to a rehabilitation unit. The last wound assessment was performed at the Neurosurgical Department outpatient clinic with a mean follow-up time of 6 months (range 3–10 months). None of the patients developed postoperative hematoma after craniotomy or liquor collection. At primary assessment, all patients had had no wound-related problems over the normal course of healing. No case registered any liquor leak from the wound, and none of the patients

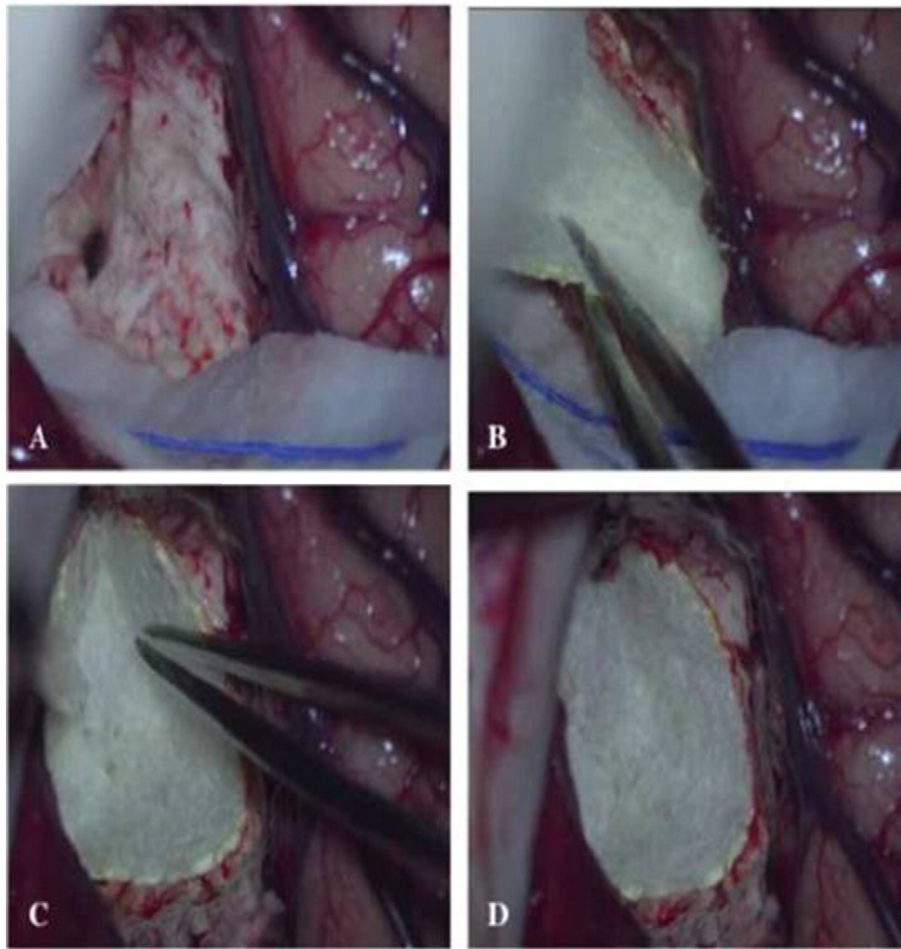


Fig. 1. Intraoperative picture of the ventricular opening following brain tumor removal. The frontal horn opened into the surgical field and was covered with a slice of TachoSil patch.

showed any signs of allergic response related to TachoSil® usage. At the last follow-up, all patients experienced uneventful wound healing.

4. Discussion

TachoSil® (haemostatic surgical patch; Nycomed, Linz, Austria) is a fixed combination of a collagen matrix coated with two coagulation factors such as fibrinogen and thrombin. TachoSil® is indicated in surgery as supportive treatment for improvement of hemostasis, to promote tissue sealing, and for suture support in vascular surgery [16–17].

TachoSil includes a white collagen sponge coated on one side, with human fibrinogen, thrombin and riboflavin giving it a yellowish color. The carrier of the substance is equine collagen, which is free of immunogenic epitopes. The yellow side of the TachoSil® fleece is the active part and should be applied at the site of bleeding. TachoSil® has served as a hemostat in procedures such as lung, kidney, spleen, or liver surgery and, more recently, cardiovascular surgery [13–18]. Moreover, recently it's has been used in neurosurgical procedures as sealant and hemostatic agent [19–24].

In our Neurosurgical Center we use TachoSil® to provide fibrinogen and thrombin locally at the site of the surgical bed and along dural defects. Indeed, upon contact with fluid the clotting factors of TachoSil® dissolve and form a fibrin network, which glues the collagen sponge to the wound surface. Combining the clotting factors in a collagen patch provides a high concentration of clotting factors at the site where it is specifically needed. Despite it's recommended to use it only as a hemostat, in our experience, TachoSil® served as an effective sealant an adhesive. Our procedures showed that closing the dural

defect with TachoSil® is a technically simple, reliable and safe method for patients. Moreover, we specifically documented an important novel technical feature of TachoSil®, such as it's reconstructing effect on the ventricular wall. Indeed, it demonstrated to be able to cover the ventricular wall defect, closing the connection with the surgical cavity and avoiding the risk of ventricular obstruction (Fig. 2).

The sealing features of TachoSil® in occluding the surgical opening of the ventricular system has been documented in literature. Bock et al. reported on a series of nine patients who underwent gross total resection of a glioblastoma with further implantation of a cytostatic drug wafer into the resection cavity [24]. Since usage of wafers is not recommended in surgical opening of the ventricular system, the authors used TachoSil to occlude the connection between the resection cavity and the ventricle. Such a strategy proved to be safe and effective in long-term MRI follow-up, with no registered complications.

In our experience, TachoSil® was well tolerated and no adverse event was documented. Although the risk of severe immunologic reactions to bovine material is low, TachoSil® has gradually replaced all bovine material with material of human origin and has therefore eliminated the associated risks of bovine material.

Drawback of TachoSil® application is its propensity to adhere to the instrument; however, keeping the instrument wet and clean is useful in avoiding this annoying tendency.

Declaration of interest

The authors report no declarations of interest. No funds were received in support of this work.

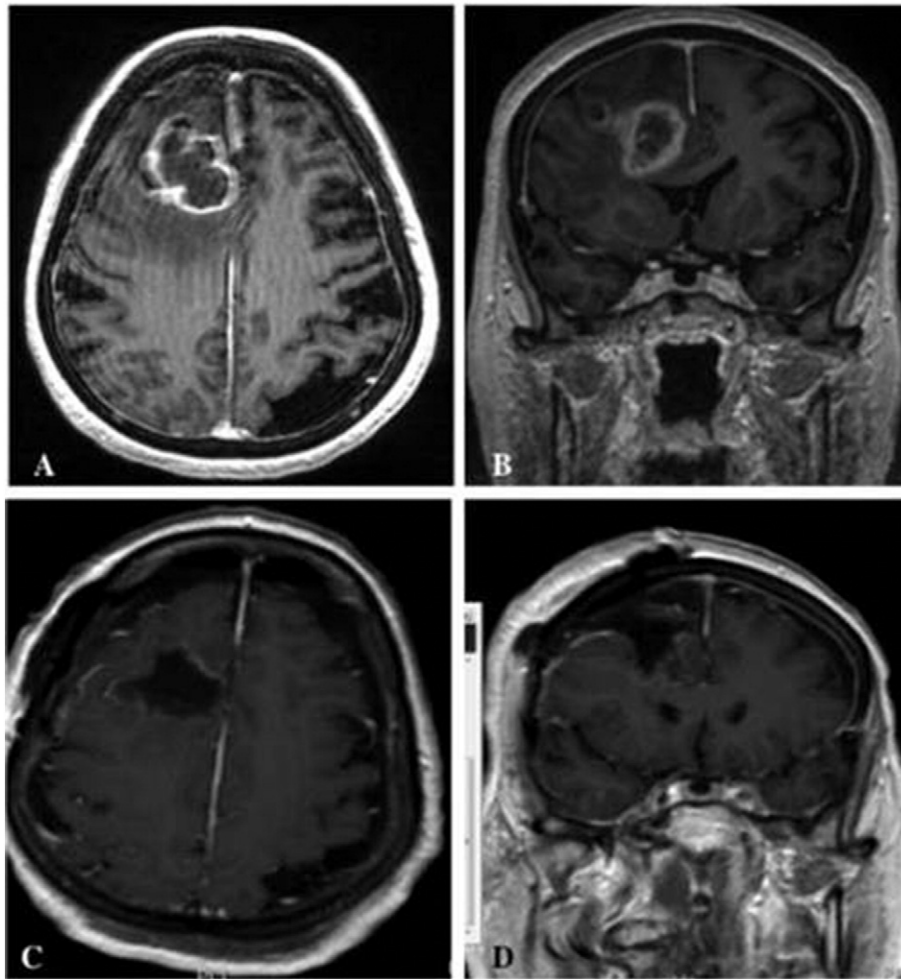


Fig. 2. Pre and post operative brain MRI showing the complete removal of the brain tumor. No liquor or hemorrhagic collection is depicted.

5. Conclusion

Our experience reinforces the thesis that the use of TachoSil in neurosurgery is safe and effective. Its features as hemostat, adhesive and sealant have been widely explored and appreciated. In our study we pointed out on its reconstructive effect of the ventricular wall that avoid communication between ventricles and surgical field without causing any risk of liquor obstruction. Thus it seems very convincing, further studies with larger sample size are warranted to confirm the efficacy of TachoSil® patches for neurosurgical defects repair.

References

- [1] P. Black, Cerebrospinal fluid leaks following spinal or posterior fossa surgery: use of fat grafts for prevention and repair, *Neurosurg. Focus*. 9 (1) (2000), e4.
- [2] Landriel Ibanez FA, Hem S, Ajler P, et al. A new classification of complications in neurosurgery, *World Neurosurg.* 2011; 75(5–6):709–715 10 (discussion 604–711).
- [3] M.G. Ochsner, Fibrin solutions to control hemorrhage in the trauma patient, *J. Long-Term Eff. Med. Implants* 8 (2) (1998) 161–173.
- [4] M.A. Seifman, P.M. Lewis, J.V. Rosenfeld, P.Y. Hwang, Postoperative intracranial haemorrhage: a review, *Neurosurg. Rev.* 34 (4) (Oct 2011) 393–407.
- [5] C.D. Shorter, D.E. Connor Jr., J.D. Thakur, G. Gardner, A. Nanda, B. Guthikonda, Repair of middle fossa cerebrospinal fluid leaks using a novel combination of materials: technical note, *Neurosurg. Focus*. 32 (6) (Jun 2012), E8.
- [6] S. Haas, The use of a surgical patch coated with human coagulation factors in surgical routine: a multicenter postauthorization surveillance, *Clin. Appl. Thromb. Hemost.* 12 (2006) 445–45015.
- [7] A. Kumar, N.F. Maartens, A.H. Kaye, Evaluation of the use of BioGlue in neurosurgical procedures, *J. Clin. Neurosci.* 10 (2003) 661–664.
- [8] M. Ganau, F. Graziano, D.G. Iacopino, Advanced hemostatics in the management of cerebral dural sinus lacerations, *Neurosurgery* 77 (4) (2015) E670–E673.
- [9] A. Giugno, R. Maugeri, S. D'Arpa, M. Visocchi, F. Graziano, D.G. Iacopino, Complex reconstructive surgery following removal of extra-intracranial meningiomas, including the use of autologous fibrin glue and a pedicled muscle flap (2014), *Interdisciplinary Neurosurgery: Advanced Techniques and Case Management* 1 (4) (2015) 84–87.
- [10] F. Graziano, F. Certo, L. Basile, R. Maugeri, G. Grasso, F. Meccio, M. Ganau, D.G. Iacopino, Autologous fibrin sealant (Vivostat®) in the neurosurgical practice: part I: intracranial surgical procedure, *Surg. Neurol. Int.* 12 (6) (2015) 77.
- [11] R. Maugeri, L. Basile, A. Giugno, F. Graziano, D.G. Iacopino, Impasse in the management of recurrent basal cell carcinoma of the skull with sagittal sinus erosion, *Interdiscip. Neurosurg.* 2 ((3), 80) (2015) 160–163.
- [12] F. Graziano, R. Maugeri, L. Basile, F. Meccio, D. Iacopino, Autologous fibrin sealant (Vivostat®) in the neurosurgical practice: part II: vertebro-spinal procedures source of the document surgical, *Neurol. Int.* (2016) S77–S82.
- [13] V. Pilone, R. Di Micco, A. Monda, E. Villamina, P. Forestieri, Use of TachoSil® in bariatric surgery: preliminary experience in control of bleeding after sleeve gastrectomy, *Minerva Chir.* 67 (2012) 241–248.
- [14] M. Pocar, D. Passolunghi, A. Bregasi, F. Donatelli, TachoSil for postinfarction ventricular free wall rupture, *Interact. Cardiovasc. Thorac. Surg.* 14 (2012) 866–867.
- [15] K.A. Simo, E.M. Hanna, D.K. Imagawa, D.A. Iannitti, Hemostatic agents in hepatobiliary and pancreas surgery: a review of the literature and critical evaluation of a novel carrier-bound fibrin sealant (TachoSil), *ISRN Surg.* 729086 (2012).
- [16] A. Toro, M. Mannino, G. Reale, I. Di Carlo, TachoSil use in abdominal surgery: a review, *J. Blood Med.* 2 (2011) 31–36.
- [17] F. Maisano, H.K. Kjaergard, R. Bauernschmitt, A. Pavie, G. Rabago, M. Laskar, J.P. Marstein, V. Falk, TachoSil surgical patch versus conventional haemostatic fleece material for control of bleeding in cardiovascular surgery: a randomised controlled trial, *Eur. J. Cardiothorac. Surg.* 36 (2009) 708–714.
- [18] D. Berdajs, M. Burki, A. Michelis, L.K. von Segesser, Seal properties of TachoSil: in vitro hemodynamic measurements, *Interact. Cardiovasc. Thorac. Surg.* 10 (2010) 910–913.
- [19] J. Kivelev, F. Göhre, M. Niemelä, J. Hernesniemi, Experiences with TachoSil® in microneurosurgery, *Acta Neurochir.* 157 (8) (2015) 1353–1357.
- [20] G. Hutter, S. von Felten, M.H. Sailer, M. Schulz, L. Mariani, Risk factors for postoperative CSF leakage after elective craniotomy and the efficacy of fleece-bound tissue sealing against dural suturing alone: a randomized controlled trial, *J. Neurosurg.* 121 (3) (2014 Sep) 735–744, <http://dx.doi.org/10.3171/2014.6.JNS.131917> (Epub 2014 Jul 18).

- [21] S. Olivieri, G. Peri, G. Tiezzi, E. Mileo, A. Giorgio, G. Oliveri, From surgery to neurosurgery: our experience on the efficacy of fleece-bound sealing (TachoSil®) for dural repair, *G Chir.* 35 (7–8) (2014 Jul-Aug) 195–198.
- [22] G. Grasso, C. Alafaci, Letter: tissue-glue-coated collagen sponge (TachoSil) for minor cerebral dural venous sinus laceration: what is the evidence? *Neurosurgery* 77 (4) (2015 Oct) E669–E670, <http://dx.doi.org/10.1227/NEU.0000000000000893>.
- [23] N. Montano, F. Papacci, E. Fernandez, The use of TachoSil® associated to fibrin glue as dural sealant in spinal intradural tumors surgery, *J. Neurosurg. Sci.* 10 (2015 Jul).
- [24] H.C. Bock, J. Cohnen, N. Keric, S.R. Kantelhardt, A. Giese, Occlusion of surgical opening of the ventricular system with fibrinogen-coated collagen fleece: a case collection study, *Acta Neurochir.* 153 (2011) 533–539 (Wien).