



Contents lists available at ScienceDirect

## International Journal of Surgery Case Reports

journal homepage: [www.casereports.com](http://www.casereports.com)

# Systemic chemotherapy and pressurized intraperitoneal aerosol chemotherapy (PIPAC): A case report of a multimodal treatment for peritoneal metastases of pancreatic origin

Stefano Rotolo<sup>a</sup>, Federica Ferracci<sup>b,\*</sup>, Francesco Santullo<sup>b</sup>, Claudio Lodoli<sup>b</sup>, Frediano Inzani<sup>c</sup>, Carlo Abatini<sup>b</sup>, Fabio Pacelli<sup>b</sup>, Andrea Di Giorgio<sup>b</sup>

<sup>a</sup> Department of Surgical, Oncological and Oral Sciences, University of Palermo, Palermo, Italy

<sup>b</sup> Surgical Unit of Peritoneum and Retroperitoneum, Fondazione Policlinico Universitario A. Gemelli IRCCS, Rome, Italy

<sup>c</sup> Institute of Pathology, Fondazione Policlinico Universitario A. Gemelli IRCCS, Rome, Italy

## ARTICLE INFO

### Article history:

Received 9 June 2020

Received in revised form 13 October 2020

Accepted 13 October 2020

Available online 22 October 2020

### Keywords:

Pressurized intraperitoneal aerosol

chemotherapy (PIPAC)

Peritoneal metastases

Pancreatic ductal adenocarcinoma

Carcinomatosis

## ABSTRACT

**INTRODUCTION:** Pancreatic ductal adenocarcinoma (PDAC) with peritoneal metastases (PM) has a dismal prognosis and palliative systemic chemotherapy, which represents the standard treatment option, has significant pharmacokinetics limitations and low efficacy. Pressurized intraperitoneal aerosol chemotherapy (PIPAC) is a new method of drug delivery that is expected to maximize exposure of peritoneal nodules to antituberculous agents. A combination of systemic chemotherapy and PIPAC may be valuable.

**PRESENTATION OF CASE:** A 55 years old male affected by PDAC with synchronous PM underwent a multimodal treatment comprising systemic chemotherapy and PIPAC without any procedural-related adverse events. Tumor genomic profiling evaluation from peritoneal biopsies addressed further tailored systemic chemotherapy.

**DISCUSSION:** The presented case illustrates the possibility of adding PIPAC to systemic chemotherapy with a fair tolerance profile and good quality of life while allowing monitoring of therapy-response and tailoring of the antituberculous treatment.

© 2020 Published by Elsevier Ltd on behalf of IJS Publishing Group Ltd. This is an open access article under the CC BY-NC-ND license (<http://creativecommons.org/licenses/by-nc-nd/4.0/>).

## 1. Introduction

Pancreatic ductal adenocarcinoma (PDAC) is an aggressive neoplasm carrying a high metastatic potential and a 5-year survival rate of 5–7% [1].

Surgery represents the only curative alternative but just 15% of patients undergo primary tumor resection which is often associated with severe complications requiring long-term recovery [2]. Indeed, at the time of diagnosis, the vast majority of cases already developed a locally advanced disease, distant or peritoneal metastases (PM) [3]. Furthermore, the recurrence rate is nearly 80% within the first two years after surgery, and about half of these patients show peritoneal relapse [4,5]. While peritoneal disease constitutes a substantial burden for PDAC patients, systemic chemotherapy represents the only option available in such cases, leading to a median survival of 6–11 months [6–9].

The efficacy of intravenous chemotherapy may be impaired by scarce vascularization and reduced blood supply of peritoneal nodules [10]. Thus, the idea of intraperitoneal chemotherapy has a strong rationale [11]. The need to improve pharmacokinetics limitation of systemic chemotherapy prompted research efforts to develop new treatment alternatives.

Pressurized intraperitoneal aerosol chemotherapy (PIPAC) emerged in the last few years as a novel method of drug administration with encouraging results in the treatment of PM of several origins [12]. Based on the aerosolization of drugs during laparoscopy, PIPAC optimizes penetration of chemotherapy agents into peritoneal tumor implants with favorable pharmacokinetics and biodistribution profiles [13].

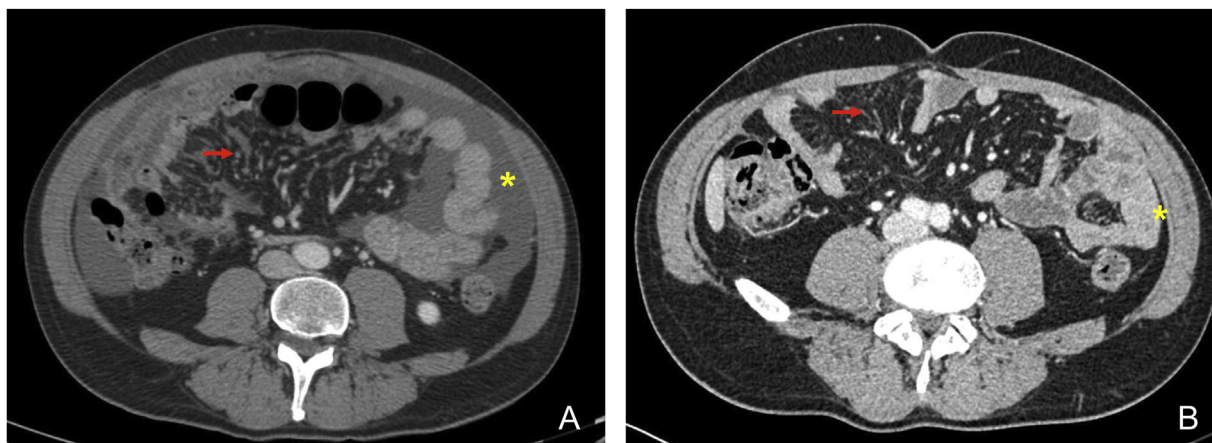
Previous experiences on PIPAC for peritoneal diffusion from PDAC reported a relevant antitumoral activity with reassuring safety and toxicity profiles with the use of the combination of cisplatin and doxorubicin (PIPAC-CD) or oxaliplatin [8,14,15].

Here we describe our first application of PIPAC-CD and systemic chemotherapy for PM of pancreatic origin, in a referral center for peritoneal surface disease.

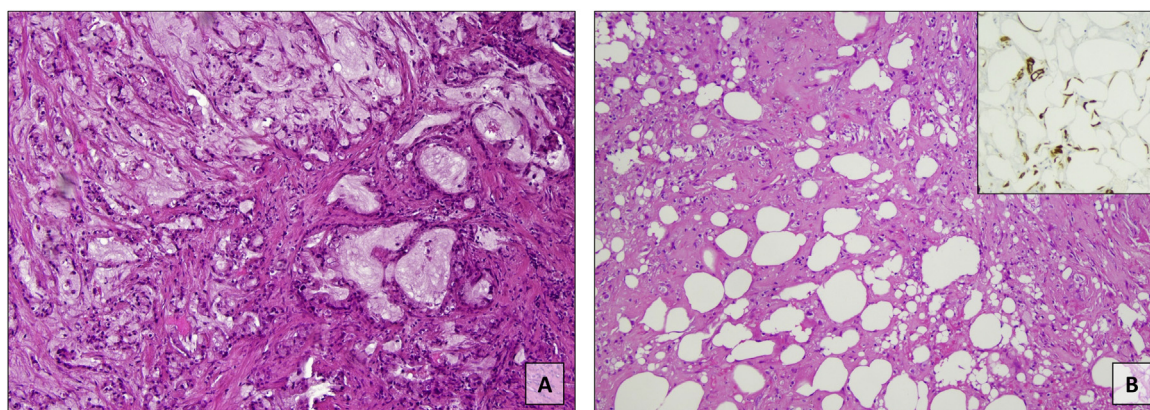
This case was prepared and reported in line with the SCARE criteria [16].

\* Corresponding author at: Surgical Unit of Peritoneum and Retroperitoneum, Fondazione Policlinico Universitario A. Gemelli IRCCS, Largo A. Gemelli, 8, 00168, Rome, Italy.

E-mail address: [federica.ferracci01@icatt.it](mailto:federica.ferracci01@icatt.it) (F. Ferracci).



**Fig. 1.** Abdomen CT scan before (A) and after (B) systemic chemotherapy with FOLFIRINOX. Red arrow: thickened mesenteric peritoneal surface (A) markedly reduced after treatment (B). Yellow asterisk: high volume ascites (A) disappeared after treatment (B).



**Fig. 2.** Histology of peritoneal biopsy infiltrated by pancreatic adenocarcinoma without significant histological regressive changes to chemotherapy (A). Peritoneal biopsy after PIPAC procedure showing marked regressive changes with fibrosis and rare scattered individual tumor cells (B) positive at immunostaining for BerEP4 (inset) (A and B: H&E, B inset: immunoperoxidase).

**2. Case presentation**

A 55-year-old man without co-morbidities was admitted to the hospital in March 2017 with a left hemithorax stabbing pain. An abdominal CT scan showed ascites and multiple peritoneal nodules and inhomogeneity of the pancreas isthmus associated with slight dilation of the main pancreatic duct.

The histological examination from CT-guided biopsy of peritoneal nodule showed metastasis of adenocarcinoma of pancreatic origin. CEA was 1.7 ng/mL (n.v. < 5), Ca 19.9 was 4553.6 IU/mL (n.v. < 37).

Given the extent of disease, we carried out a combination of systemic chemotherapy with fluorouracil, leucovorin, irinotecan, and oxaliplatin (FOLFIRINOX) of which 13 cycles were completed until an adverse reaction to oxaliplatin.

The abdomen CT scans performed at the end of the first-line chemotherapy showed a partial response, both on primary tumor and peritoneum (Fig. 1).

In February 2018, encouraged by the good response, the multidisciplinary tumor board (MDT) proposed to integrate systemic FOLFIRI (folinic acid, fluorouracil, and irinotecan) with PIPAC (UIN: researchregistry6039).

At admission before surgery, the patient had a good general condition (Eastern Cooperative Oncology Group performance status grade 0). Laboratory tests were within normal limits.

The PIPAC procedure was first performed in February 2018, according to the standard technique [17]. After laparoscopy and evaluation of PM extent according to the Sugarbaker Peritoneal Cancer Index (PCI), any ascitic fluid is drained and at least four peritoneal biopsies are taken for chemotherapy-response assessment. Connecting a nebulizer (Capnopen-MIP, Reger Medizintechnik, Rottweil, Germany) to a high-pressure injector (Injektron 82 M, MedTron, Saarbruecken), a pressurized aerosol containing antitubercular drugs is administered inside the peritoneal cavity.

The procedure is monitored by the laparoscopic camera hold in place by a self-retaining retractor and the injection is remote-controlled to avoid occupational exposure. After maintaining the capnoperitoneum for 30 min at 37 °C, the aerosol is evacuated via a closed aerosol waste system. The trocars are removed, and no abdominal drain tube is applied. The fascia and skin are closed with absorbable sutures.

Chemotherapy agents for PIPAC administration were chosen based on previous drug exposure, adverse reaction, and response to systemic chemotherapy. We decided for the combination of cisplatin 7.5 mg/m<sup>2</sup> in 150 mL NaCl solution and doxorubicin 1.5 mg/m<sup>2</sup> in 50 mL NaCl.

At the first PIPAC, the Peritoneal Cancer Index (PCI), calculated according to Sugarbaker's criteria [18] revealed a score of 22. The baseline pathological response on peritoneal biopsies according to the Peritoneal Regression Grading Score (PRGS) [19] was 2. There

were no postoperative adverse events and the patient was discharged on the second postoperative day.

The patient repeated 3 more PIPAC-CD cycles every 6–8 weeks: April 2018 (PCI 22, PRGS 1), June 2018 (PCI 22, PRGS 1), and August 2018 (PCI 29, PRGS 2) (Fig. 2).

All the cycles were very well tolerated, and no postoperative complications were noted. FOLFIRI was continued between PIPAC administrations with 2 weeks interval before and one week after each PIPAC cycle.

Global Health Score/QoL of the EORTC quality of life questionnaire (QLQ-C30) before PIPAC was 92, it maintained stable after 2 PIPAC cycles and slightly decreased to 83 after the fourth PIPAC.

The abdomen CT scan performed in September 2018 showed a progression of peritoneal disease.

Comprehensive genomic profiling of peritoneal tumor samples documented the negativity of Ribonucleotide Reductase Catalytic Subunit M1 (RRM1) on immunochemistry. On this base, a new line of systemic chemotherapy with gemcitabine was started 18 months after diagnosis.

In July 2019 the patient developed initial symptoms of intestinal sub-occlusion and the new CT scan showed further progression of the disease. Symptomatic and supportive care was therefore initiated.

The patient died in December 2019, 33 months after the diagnosis.

### 3. Discussion

Peritoneal dissemination from PDAC confers a dismal prognosis as available treatment relies on systemic chemotherapy that roughly reaches 1-year survival and it is affected by severe side effects [6,7].

We report our first case of multimodal treatment for PM of pancreatic origin, illustrating the possibility to safely administer PIPAC and systemic chemotherapy with a good tolerance profile.

Considering the good response to FOLFIRINOX on primary tumor and PM, switched to FOLFIRI because of an adverse reaction to oxaliplatin, the MDT proposed to combine systemic administration with PIPAC-CD.

We experienced no intraoperative and postoperative complications and toxicity was not a concern, as we did not observe any renal, hepatic, or bone marrow impairment. After each PIPAC, the patient was discharged within the second postoperative day.

Importantly, during treatment, the patient experienced an optimal quality of life, with a slight decrease in the Global Health Score/QoL score of QLQ-C30 after the fourth cycle. The combination of intravenous and locoregional chemotherapy seems feasible, as most of the systemic chemotherapy regimens fit well with a PIPAC administration every 6–8 weeks. In the present case, we experienced no delay in the resumption of systemic FOLFIRI after PIPAC and vice versa. Furthermore, the patient tolerated well the whole treatment schedule, not only managing daily activities but also being able to undertake working duties as well as flying between Europe and North America.

The possibility to repeat this non-complicated, minimally invasive procedure allowed therapy-response monitoring on subsequent biopsies. PRGS reduction after the first two PIPAC cycles demonstrated a pathological response on peritoneal metastases after the addition of locoregional chemotherapy, attesting the anti-tumoral efficacy of PIPAC. Also, when dealing with PM, a pathological assessment is a very attractive feature considering that radiological imaging poorly performs on measurable peritoneal nodules volume reduction and PCI evaluation it is not reliable on fibrotic nodules. Remarkably, peritoneal biopsies offer the opportunity to perform a molecular characterization of the disease, which

may provide evidence of further effective therapeutic options. In this case, the absence of Ribonucleotide Reductase Catalytic Subunit M1 (RRM1) in survivor cell lines led to a tailored shift to gemcitabine systemic chemotherapy [20].

Of course, this is only a single case and several factors contributed to the outcomes observed, however, the overall survival of 33 months is promising for this metastatic neoplasm and encourages further research on the described multimodal approach for peritoneal dissemination of pancreatic origin. Furthermore, the repeated response assessment and molecular characterization on subsequent biopsies may shed new insights on the natural history of pancreatic cancer, paving the way for personalized medicine.

This article is part of a supplement entitled Case reports from Italian young surgeons, published with support from the Department of Surgical, Oncological and Oral Sciences – University of Palermo.

### Funding

No funding sources to report.

### Ethical approval

Ethical approval was not required for this case report presentation.

### Consent

Written informed consent was obtained from the patient for publication of this case report and accompanying images. A copy of the written consent is available for review by the Editor-in-Chief of this journal on request.

### Author's contribution

Andrea Di Giorgio, Fabio Pacelli: Study design.

Francesco Santullo, Claudio Lodoli, Frediano Inzani: Data collection.

Federica Ferracci, Stefano Rotolo: Writing the papers.

### Registration of research studies

N/A.

### Guarantor

Andrea Di Giorgio.

### Provenance and peer review

Not commissioned, externally peer-reviewed.

### Declaration of Competing Interest

The authors report no declarations of interest.

### Acknowledgement

This article is part of a supplement entitled Case reports from Italian young surgeons, published with support from the Department of Surgical, Oncological and Oral Sciences – University of Palermo.



## References

- [1] M. Ducreux, A.S. Cuhna, C. Caramella, A. Hollebecque, P. Burtin, D. Goéré, T. Seufferlein, K. Haustermans, J.L. Van Laethem, T. Conroy, D. Arnold, Cancer of the pancreas: ESMO Clinical Practice Guidelines for diagnosis, treatment and follow-up, *Ann. Oncol.* 26 (2015) v56–v68, <http://dx.doi.org/10.1093/annonc/mdv295>.
- [2] D. Gui, G. Pepe, C. Callari, R. Persiani, A. Di Giorgio, S. Magalini, Vacuum-assisted wound care (vac<sup>®</sup>) for enteric fistula closure: how we do it, *World J. Surg.* 38 (2014) 3280–3283, <http://dx.doi.org/10.1007/s00268-014-2739-0>.
- [3] J.P. Sleeman, PIPAC puts pressure on peritoneal metastases from pancreatic cancer, *Clin. Exp. Metastasis* 34 (2017) 291–293, <http://dx.doi.org/10.1007/s10585-017-9851-0>.
- [4] T.A. Sohn, C.J. Yeo, J.L. Cameron, L. Koniari, S. Kaushal, R.A. Abrams, P.K. Sauter, J. Coleman, R.H. Hruban, K.D. Lillemoe, Resected adenocarcinoma of the pancreas - 616 patients: results, outcomes, and prognostic indicators, *J. Gastrointest. Surg.* 4 (2000) 567–579, [http://dx.doi.org/10.1016/S1091-255X\(00\)80105-5](http://dx.doi.org/10.1016/S1091-255X(00)80105-5).
- [5] T. Yamamoto, S. Yagi, H. Kinoshita, Y. Sakamoto, K. Okada, K. Uryuhara, T. Morimoto, S. Kaihara, R. Hosotani, Long-term survival after resection of pancreatic cancer: a single-center retrospective analysis, *World J. Gastroenterol.* 21 (2015) 262–268, <http://dx.doi.org/10.3748/wjg.v21.i1.262>.
- [6] T. Conroy, F. Desseigne, M. Ychou, O. Bouché, R. Guimbaud, Y. Bécouarn, A. Adenis, J.L. Raoul, S. Gourgou-Bourgade, C. De La Fouchardière, J. Bennouna, J.B. Bachet, F. Khemissa-Akouz, D. Péré-Vergé, C. Delbaldo, E. Assenat, B. Chauffert, P. Michel, C. Montoto-Grillot, M. Ducreux, FOLFIRINOX versus gemcitabine for metastatic pancreatic cancer, *N. Engl. J. Med.* 364 (2011) 1817–1825, <http://dx.doi.org/10.1056/NEJMoa1011923>.
- [7] J. Taberner, E.G. Chiorean, J.R. Infante, S.R. Hingorani, V. Ganju, C. Weekes, W. Scheithauer, R.K. Ramanathan, D. Goldstein, D.N. Penenberg, A. Romano, S. Ferrara, D.D. Von Hoff, Prognostic factors of survival in a randomized phase III trial (MPACT) of weekly nab- paclitaxel plus gemcitabine versus gemcitabine alone in patients with metastatic pancreatic cancer, *Oncologist* 20 (2015) 143–150, <http://dx.doi.org/10.1634/theoncologist.2014-0394>.
- [8] P. Horvath, S. Beckert, F. Struller, A. Königsrainer, M.A. Reymond, Pressurized intraperitoneal aerosol chemotherapy (PIPAC) for peritoneal metastases of pancreas and biliary tract cancer, *Clin. Exp. Metastasis* 35 (2018) 635–640, <http://dx.doi.org/10.1007/s10585-018-9925-7>.
- [9] S. Gourgou-Bourgade, C. Bascoul-Molle, F. Desseigne, M. Ychou, O. Bouché, R. Guimbaud, Y. Bécouarn, A. Adenis, J.L. Raoul, V. Boige, J. Béville, T. Conroy, Impact of FOLFIRINOX compared with gemcitabine on quality of life in patients with metastatic pancreatic cancer: results from the PRODIGE 4/ACCORD 11 randomized trial, *J. Clin. Oncol.* 31 (2013) 23–29, <http://dx.doi.org/10.1200/JCO.2012.44.4869>.
- [10] Z. Lu, J. Wang, M.G. Wientjes, J.L.S. Au, Intraperitoneal therapy for peritoneal cancer, *Future Oncol.* 6 (2010) 1625–1641, <http://dx.doi.org/10.2217/fon.10.100>.
- [11] N. Takahara, H. Isayama, Y. Nakai, H. Ishigami, S. Sato, S. Mizuno, H. Kogure, S. Matsubara, N. Yamamoto, H. Yamaguchi, M. Tada, J. Kitayama, T. Watanabe, K. Koike, Intravenous and intraperitoneal paclitaxel with S-1 for treatment of refractory pancreatic cancer with malignant ascites, *Invest. New Drugs* 34 (2016) 636–642, <http://dx.doi.org/10.1007/s10637-016-0369-0>.
- [12] A. Di Giorgio, C. Abatini, M. Attalla El Halabieh, E. Vita, G. Vizzielli, V. Gallotta, F. Pacelli, S. Rotolo, From palliation to cure: PIPAC for peritoneal malignancies, *Minerva Med.* 110 (2019) 385–398, <http://dx.doi.org/10.23736/S0026-4806-19-06081-6>.
- [13] T.A. Falkenstein, T.O. Götze, M. Ouaiissi, C.B. Tempfer, U. Giger-Pabst, C. Demtröder, First clinical data of pressurized intraperitoneal aerosol chemotherapy (PIPAC) as salvage therapy for peritoneal metastatic biliary tract cancer, *Anticancer Res.* 38 (2018) 373–378, <http://dx.doi.org/10.21873/anticancerres.12232>.
- [14] M. Graversen, S. Detlefsen, J.K. Bjerregaard, P. Pfeiffer, M.B. Mortensen, Peritoneal metastasis from pancreatic cancer treated with pressurized intraperitoneal aerosol chemotherapy (PIPAC), *Clin. Exp. Metastasis* 34 (2017) 309–314, <http://dx.doi.org/10.1007/s10585-017-9849-7>.
- [15] A. Di Giorgio, O. Sgarbura, S. Rotolo, C.A. Schena, C. Bagalà, F. Inzani, A. Russo, V. Chiantera, F. Pacelli, Pressurized intraperitoneal aerosol chemotherapy with cisplatin and doxorubicin or oxaliplatin for peritoneal metastasis from pancreatic adenocarcinoma and cholangiocarcinoma, *Ther. Adv. Med. Oncol.* (January) (2020), <http://dx.doi.org/10.1177/1758835920940887>.
- [16] R.A. Agha, M.R. Borrelli, R. Farwana, K. Koshy, A.J. Fowler, D.P. Orgill, H. Zhu, A. Alsawadi, A. Noureldin, A. Rao, A. Enam, A. Thoma, M. Bashashati, B. Vasudevan, A. Beamish, B. Challacombe, R.L. De Wilde, D. Machado-Aranda, D. Laskin, D. Muzumdar, A. D'cruz, T. Manning, D. Healy, D. Pagano, P. Goel, P. Ranganathan, P.S. Pai, S. Raja, M.H. Ather, H. kadiožlu, I. Nixon, I. Mukherjee, J. Gómez Rivas, K. Raveendran, L. Derbyshire, M. Valmasoni, M. Chalkoo, N. Reason, O. Muensterer, P. Bradley, C. Roberto, R. Affi, D. Rosin, R. Klappenbach, R. Wynn, S. Giordano, S. Basu, S. Surani, P. Suman, M. Thorat, V. Kasi, The SCARE 2018 statement: updating consensus Surgical CAse REport (SCARE) guidelines, *Int. J. Surg.* 60 (2018) 132–136, <http://dx.doi.org/10.1016/j.ijsu.2018.10.028>.
- [17] A. Di Giorgio, C.A. Schena, M. Attalla El Halabieh, C. Abatini, E. Vita, A. Strippoli, F. Inzani, E. Rodolfo, F. Pacelli, Systemic chemotherapy and pressurized intraperitoneal aerosol chemotherapy (PIPAC): a bidirectional approach for gastric cancer peritoneal metastasis, *Surg. Oncol.* 34 (2020) 270–275, <http://dx.doi.org/10.1016/j.suronc.2020.05.006>.
- [18] P.H. Sugarbaker, Cytoreductive surgery using peritonectomy and visceral resections for peritoneal surface malignancy, *Transl. Gastrointest. Cancer* 2 (2013) 54–74, <http://dx.doi.org/10.3978/j.issn.2224-4778.2013.01.02>.
- [19] W. Solass, C. Sempoux, S. Detlefsen, N.J. Carr, F. Bibeau, Peritoneal sampling and histological assessment of therapeutic response in peritoneal metastasis: proposal of the Peritoneal Regression Grading Score (PRGS), *Pleura Peritoneum* 1 (2016) 99–107, <http://dx.doi.org/10.1515/pp-2016-0011>.
- [20] W. Gong, X. Zhang, J. Wu, L. Chen, L. Li, J. Sun, Y. Lv, X. Wei, Y. Du, H. Jin, J. Dong, RRM1 expression and clinical outcome of gemcitabine-containing chemotherapy for advanced non-small-cell lung cancer: a meta-analysis, *Lung Cancer* 75 (2012) 374–380, <http://dx.doi.org/10.1016/j.lungcan.2011.08.003>.

## Open Access

This article is published Open Access at [sciencedirect.com](https://www.sciencedirect.com). It is distributed under the [IJSCR Supplemental terms and conditions](#), which permits unrestricted non commercial use, distribution, and reproduction in any medium, provided the original authors and source are credited.