






Original Article

Comparison of Electrocochleography and Video Head Impulse Test findings in Vestibular Migraine and Ménière Disease: A Preliminary Study

Francesco Martines , Francesco Dispenza , Calogero Montalbano, Roberta Priola, Angelo Torrente, Rosario La Gumina, Filippo Brighina , Francesco Galletti , Pietro Salvago 

Department of Biomedicine, Neuroscience and Advanced Diagnostics (BiND), University of Palermo, Palermo, Italy (FM, RP, AT, RLG, FB, PS)
U.O.C. Otorinolaringoiatria, Policlinico "P. Giaccone" University Hospital, Palermo, Italy (FD, CM)
Department of Human Pathology of Adults and Children "G. Barresi", University of Messina, Messina, Italy (FG)

ORCID iDs of the authors: F.M. 0000-0002-8616-4481; F.D. 0000-0002-5844-9762; F.B. 0000-0001-5875-3126; F.G. 0000-0003-3073-9247; P.S. 0000-0001-8570-3212.

Cite this article as: Martines F, Dispenza F, Montalbano C, Priola R, Torrente A, La Gumina R, et al. Comparison of Electrocochleography and Video Head Impulse Test findings in Vestibular Migraine and Ménière Disease: A Preliminary Study. J Int Adv Otol 2020; 16(2): 183-9.

OBJECTIVES: To evaluate electrophysiological findings among patients with vestibular migraine (VM) and to compare them with those of patients suffering from definite Ménière disease (MD) without migraine.

MATERIALS and METHODS: Twenty-one consecutive patients suffering from VM were enrolled; all subjects were selected according to the criteria proposed by the Bäràny Society for Neuro-otology. Each patient underwent a careful otological and neurotological examination. After completing a questionnaire regarding migraine and vertigo complaints, they were assessed by audiometric testing, video head impulse test (vHIT), and electrocochleography (EcochG). Data were compared with those of 21 patients who fulfilled the criteria for definite MD.

RESULTS: 52.38% of the patients with VM suffered from at least two episodes of migraine per week, with 42.85% of the subjects complaining of migraines lasting ≥ 24 hours. 57.14% of the patients reported at least four episodes of vertigo per month, whereas 61.9% suffered from symptoms of chronic unsteadiness. No significant difference ($p=0.76$) resulted from the comparison of vHIT gain between patients with VM and MD. Eleven out of 21 patients (52.38%) with definite MD presented at least one ear with SP/AP >0.4 , differently from patients with VM who exhibited SP/AP values suggestive of endolymphatic hydrops (EH) in only three cases (14.28%).

CONCLUSION: The present study found a higher proportion of abnormal EcochG in MD than in VM ($p=0.02$) without any significant difference in the vHIT gain. On the basis of our findings, the identification of EH in some patients with VM cannot be definitely related to the same pathway that triggers MD symptoms. Future research may help in better understanding whether abnormal EcochG findings can predict the occurrence of MD among patients with VM.

KEYWORDS: Vestibular migraine, EcochG, Ménière disease, endolymphatic hydrops

INTRODUCTION

Aural and vestibular symptoms are frequent complaints of people who suffer from migraines. It has been estimated that around 30-50% of migraineurs may experience vertigo and/or dizziness at a certain point of their life but, of these, only 9% are identified as being affected by vestibular migraine (VM) ^[1-3]. The diagnosis of VM is challenging because it depends on a clinically based symptom criteria reported by patients rather than vestibular function tests. In particular, after excluding other vestibular disorders, the diagnostic criteria included in the Appendix of the International Classification of Headache Disorders (ICHD)-3 beta version must be fulfilled in order for a case of definite VM to be recognized ^[4, 5].

The pathophysiology of VM remains unclear and seems to involve different neural pathways including the vestibular nuclei, trigeminal nerve, and thalamus and cortical regions. Specifically, a parallel activation of vestibular and nociceptive pathways has

Corresponding Address: Pietro Salvago E-mail: pietrosalvago@libero.it

Submitted: 02.04.2020 • **Accepted:** 03.25.2020

Available online at www.advancedotology.org



Content of this journal is licensed under a
Creative Commons Attribution-NonCommercial
4.0 International License.

been suggested by many authors as a possible key to explaining the relationship between migraine symptoms and vestibular complaints [6, 7]. Obermann et al. [8] observed a gray matter volume reduction in cerebral areas, including the superior, inferior, and middle temporal gyrus; the mid cingulate; and the insula, among 17 patients with VM. Teggi et al. [9] hypothesized a dismodulation of vestibular and nociceptive processing in thalamo-cortical regions after fMRI assessment of two VM subjects who showed an activation of brain areas related to the integration of visual and vestibular cues during visual stimulation. A study conducted by Shin et al. [10] supported a role for the activation of the vestibulo-thalamo-cortical pathway during the ictal period as a possible explanation for VM symptoms. In addition, motion-sickness susceptibility might be a consequence of the sensitization of thalamic pathways, and the degree of activation of the thalamus itself may be a possible indicator of the frequency of VM attacks [11, 12].

Peripherally, an involvement of the inner ear in VM pathophysiology has been claimed by Koo and Balaban [13]: examining a migraine murine model, they noted a protein extravasation in the inner ear comparable to the one determined by the trigeminovascular reflex and causing meningeal inflammation. This process may be traceable to the innervation of cochlear vessels, mediated by the trigeminal nerve, and/or to its synaptic projections to the cochlear nucleus and the superior olivary complex [14, 15].

From a clinical point of view, VM often shares common features with Ménière disease (MD), and it can be quite challenging to discriminate between these pathologies, particularly in their earlier stages. Patients with VM may complain of aural symptoms, while patients with MD may report a history of migraine in 20-30% of cases [16]. Furthermore, it is possible that a subject may fulfil diagnostic criteria for both VM and MD, experiencing the so-called “overlap syndrome” [17].

Previous studies have attempted to find a vestibular function test that could identify a gold standard for differentiating VM, MD, and non-vestibular migraine [18-22]; in particular, the calculation of the SP/AP ratio through electrocochleography (EcochG) has often been reported as an objective index of endolymphatic hydrops (EH) in MD [23], even though it is limited by low sensitivity and its reliability is strictly dependent on the kind of EcochG technique used, type of stimulus given, and stage of MD. In contrast, scarce data are available relative to the use of EcochG among patients with VM. For example, Vitkovic et al. [24] studied 523 patients who were categorized into four groups (definite migrainous vertigo, probable migrainous vertigo, vestibular disorder coexisting with migraine, and non-migraine-related dizziness with migraine) and

they did not find any difference in EcochG test results between the groups. Lotfi et al. [25], did not observe relevant EcochG differences between patients with VM and healthy subjects in a case series of 20 patients. Yollu et al. [22], instead, evidenced higher SP/AP ratio averages among patients with VM with respect to migraineurs without complaints of vertigo.

The main purpose of this study was to evaluate electrophysiological findings among patients with VM and to compare EcochG results with those of a group of patients suffering from definite MD without migraine.

MATERIALS AND METHODS

Study Sample

The study was conducted between November 2018 and April 2019 by enrolling 21 consecutive patients, 20 females and 1 male, suffering from definite VM (mean age = 43.61±12.31 years).

Exclusion criteria were the following: aged younger than 18, history of acute unilateral vestibulopathy, definite MD, benign paroxysmal positional vertigo, trauma, ear infections, perilymphatic fistula, MRI-documented retrocochlear disease (e.g. schwannoma), exposure to ototoxic drugs, barotrauma, and middle and/or inner ear malformation. We also did not include subjects affected by ophthalmologic and neurodegenerative disorders, diabetes mellitus, hypertension, and with a history of ischemic heart disease.

Patients affected by definite VM were selected according to the criteria proposed by the Bàràny Society for Neuro-otology and included in the Appendix of the new ICDH-3 beta version of headache classification [5].

After ethical committee approval (approval number 27/06), written informed consent was obtained from each participant at the beginning of the study. All tests were performed in a symptom-free interval.

Each patient underwent a careful otological examination with micro-otoscopy to rule out external/middle ear disease that could alter the results of the tests performed. A bedside examination, including spontaneous nystagmus, smooth pursuit, saccade, head shaking test, and Romberg Test, was performed. In addition, a detailed neurological examination, including cranial nerve and cerebellar functions, manual muscle testing for power, and somatosensory assessments, was also performed.

Participants were assisted in completing a questionnaire by qualified medical personnel. Data collection regarded the age of migraine onset, number of vertigo episodes, number of migraine episodes, migraine duration, chronic unsteadiness, tinnitus, fullness, food intolerance, anxiety, phonophobia, photophobia, and a family history of headache and migraine.

Pure tone audiometry was performed with an Amplaid 309 audiometer in a soundproof audiometric chamber. Air conduction was measured using on-ear headphones for 125-8,000 Hz; bone conduction was measured using a calibrated bone transducer for 250-4,000 Hz. Patients subsequently underwent video head impulse test (vHIT) and EcochG.

MAIN POINTS

- No significant difference from the comparison of vHIT gain between patients with VM and MD.
- A higher proportion of abnormal EcochG in MD than in VM.
- The identification of EH in some patients with VM cannot be definitely related to the same pathway that triggers MD symptoms.

Data were compared with those of 21 patients (mean age = 43.28 ± 7.3 years), 9 females and 12 males, who fulfilled the criteria for definite MD [26] and who had a negative history of migraine. Each patient with MD was recruited in the same period of the study and assessed in the symptom-free interval.

vHIT

We used the Eye-See-Cam system (Interacoustics, Middelfart, Denmark) to record vHIT. Patients were seated 1.5 m in front of a target and were asked to continue watching it as their head was passively rotated by the examiner. The head was subjected to passive high-acceleration, low-amplitude rotations in the planes of the horizontal semicircular canals.

Patients' eye movements were evaluated using video-oculography, while their head movements were recorded using inertial sensors. At least 15 valid head impulses were recorded for each horizontal semicircular canal. The vestibulo-ocular reflex (VOR) gains during the vHIT (eye velocity/head velocity) were automatically measured using a software that computed the slope of the regression between head and eye velocity. Abnormal functioning of the canal was taken into consideration in case of gain asymmetry >5% and

mean gain in vHIT <0.8 for the lateral canals with detection of catch-up (corrective) saccades [27].

EcochG

A Socrates system (Hedera Biomedics, Padova, Italy) was used to record EcochG potentials.

EcochG was performed using an extratympanic external ear canal electrode (Lilly TM-Wick Electrode, Intelligent Hearing Systems, Miami, Florida, USA). Click Stimuli at 130 dB nHL, with alternating polarity, were sent to the ear using insert headphones, with a stimulation of 5.4/s, for a period long enough to receive at least 2,000 responses. Graphs representing the output were evaluated to calculate the SP, AP, and SP/AP amplitude ratio values for both ears. The ground electrode was placed on the forehead, whereas the negative was placed on the contralateral mastoid. An SP/AP ratio of greater than 0.4 was considered abnormally elevated [28].

Statistical Analysis

Group data were expressed as percentages and quantitative variables as mean ± standard deviation. Statistical comparisons between two or more groups were made using χ^2 test, Fisher's exact test, and/

Table 1. Demographic and clinical characteristics of patients with VM

N	Age	Gender	Age of migraine onset	Episodes of migraine	Migraine duration	Episodes of vertigo	Chronic unsteadiness	Tinnitus	Fullness	Phonophobia	Photophobia	Family history of migraine
1	48	f	40	3/week	2 hours	2/month	+	+	-	+	+	-
2	48	f	18	1/week	72 hours	10/month	-	+	+	-	+	-
3	51	f	45	4/week	72 hours	10/ month	+	+	+	+	+	-
4	39	f	19	3/month	2 hours	4/month	+	+	+	+	+	+
5	64	m	17	3/month	48 hours	4/month	-	-	-	+	+	-
6	26	f	15	3/month	24 hours	2/month	+	+	-	+	+	+
7	49	f	45	3/week	24 hours	1/month	+	+	+	+	+	-
8	57	f	29	4/week	24 hours	10/ month	+	+	+	+	+	+
9	30	f	25	4/week	24 hours	4/week	+	-	+	+	+	+
10	30	f	20	2/ week	6 hours	2/week	+	+	-	+	+	+
11	18	f	15	1/week	2 hours	10/ month	-	+	-	+	+	-
12	37	f	36	3/week	3 hours	2/month	-	+	+	+	+	-
13	37	f	35	5/week	2 hours	3/ week	-	+	+	+	+	-
14	64	f	14	3/week	72 hours	2/ month	+	+	-	+	+	-
15	59	f	18	2/ week	48 hours	3/ week	+	-	+	+	+	+
16	40	f	25	1/week	3 hours	2/month	+	-	+	-	+	+
17	38	f	21	2/ week	2 hours	6/month	-	+	+	+	+	+
18	50	f	20	4/month	72 hours	4/week	-	-	-	-	-	-
19	51	f	33	2/month	48 hours	1/month	-	-	-	+	+	+
20	35	f	15	2/month	4 hours	2/month	+	+	-	+	+	-
21	45	f	23	3/month	2 hours	2/month	+	+	-	-	-	-

F: female; m: male; VM: vestibular migraine.

or Student's paired t-test. The Statistica Software (Version 8.0 for Windows, Palermo, Italy) was adopted.

RESULTS

Table 1 shows the demographic and clinical characteristics of the patients with VM. Twenty out of 21 patients were female, with a mean age of migraine symptom onset of 25.14±10.03 years, and 57.14% of them developed migraines younger than 25 years. 52.38% of the patients suffered from at least two migraine episodes per week, with 42.85% of the subjects complaining of migraines lasting ≥24 hours. Concerning the frequency of vertigo, 57.14% of the patients reported at least four episodes of vertigo per month, whereas 61.9% suffered from symptoms of chronic unsteadiness.

Fifteen (71.42%) individuals out of the total sample were affected by tinnitus, with 52.38% reporting fullness in at least one ear. The majority of patients suffered from phonophobia (80.95%) and photophobia (90.47%). A family history of migraine (42.85%) was frequently reported.

As shown in Figure 1, no cases of moderate to profound hearing loss were detected. A slight hearing loss, limited to the 4 kHz frequency, was detected in only six patients in the left ear and four individuals

Table 2. Demographic and clinical characteristics of patients with MD

N	Age	Gender	Age of Vertigo onset	Left Hearing (*)	Right Hearing (*)	MD Side
1	38	m	36	Normal	Mild	Right
2	42	m	39	Normal	Severe	Right
3	50	m	48	Medium	Normal	Left
4	35	m	33	Normal	Severe	Right
5	60	m	51	Normal	Medium	Right
6	47	f	45	Normal	Medium	Right
7	42	m	41	Mild	Normal	Left
8	51	f	43	Normal	Medium	Right
9	36	m	33	Medium	Normal	Left
10	40	m	30	Severe	Normal	Left
11	42	f	38	Normal	Mild	Right
12	46	m	39	Mild	Normal	Left
13	52	m	45	Normal	Mild	Right
14	39	f	28	Normal	Severe	Right
15	29	f	23	Mild	Normal	Left
16	35	f	30	Normal	Mild	Right
17	46	f	35	Normal	Medium	Right
18	51	f	30	Severe	Normal	Left
19	40	f	37	Mild	Normal	Left
20	39	m	28	Medium	Normal	Left
21	49	m	34	Normal	Medium	Right

F: female; m: male; MD: Ménière disease. (*) The degree of hearing loss was calculated as an average of three frequencies (0.5, 1, and 2 kHz).

in the right ear. No significant difference was found between ears for each frequency tested (p>0.05).

Patients with VM showed vHIT gain mean values of 0.95±0.09 for the left and of 0.93±0.06 for the right ear, respectively, without significant difference (p=0.15).

Table 2 depicts the demographic and clinical characteristics of the patients with MD included in the study. All subjects suffered from unilateral MD and the 23.8% were affected by a severe sensorineural hearing loss (SNHL); the right ear was affected in 12 out of 21 patients with MD (57.14%). Video head impulse test gain mean values of patients suffering from MD were 0.90±0.08 for the left and 0.95±0.16 for the right ear, respectively, without significant difference (p=0.13). Only one patient with MD exhibited a pathological gain on the affected side. No significant difference (p=0.76) resulted from the comparison of vHIT gain between patients with VM and MD (Figure 2).

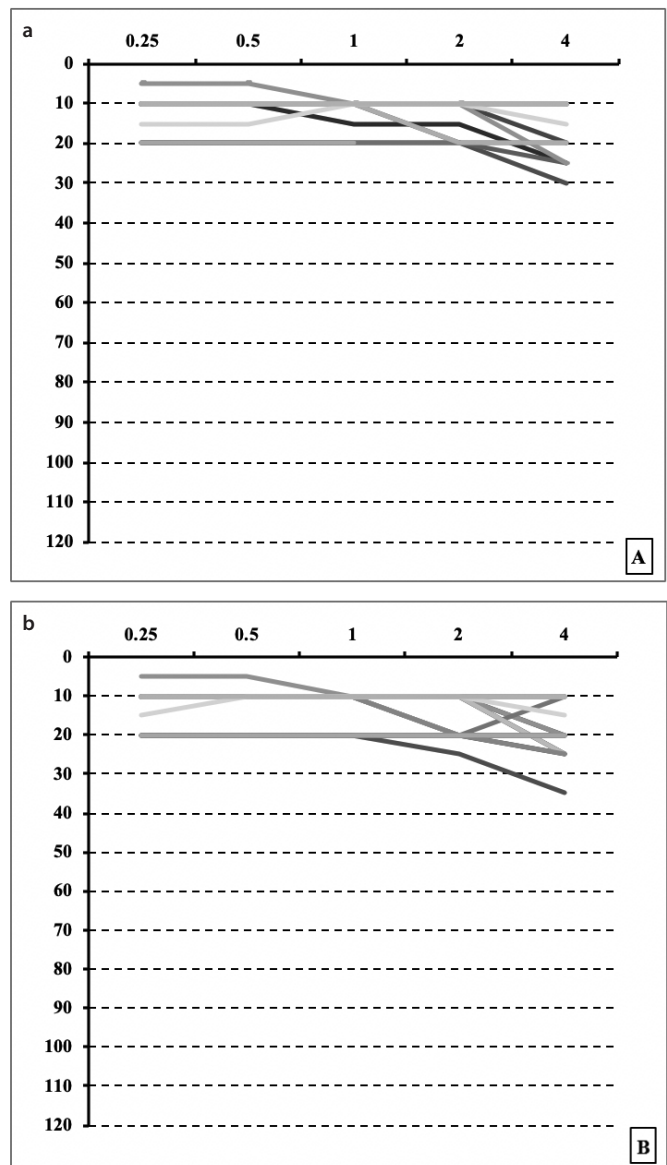


Figure 1. a, b. Pure tone audiometry of the left (a) and the right (b) ear of VM patients.

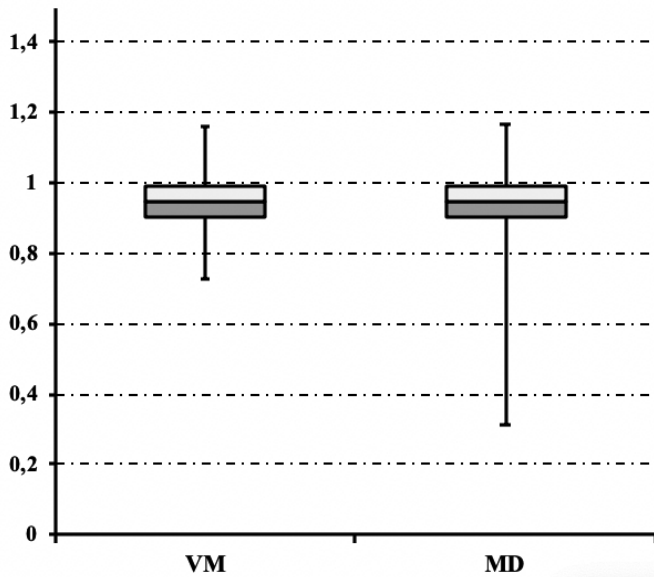


Figure 2. Box plot: vHIT gain of VM and MD patients.

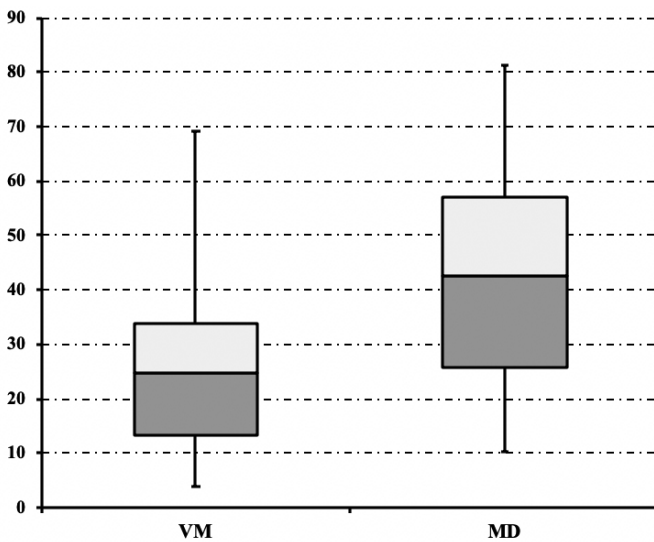


Figure 3. Box plot: SP/AP ratio of VM and MD patients.

In terms of EcochG data, Figure 3 shows the comparison of SP/AP values between patients with VM and MD. Both groups did not differ statistically in terms of mean age ($p=0.91$). The mean SP/AP value was 26.53 ± 13.75 and 43.08 ± 20.99 in the VM and in the MD groups, respectively ($p=0.004$). Eleven out of 21 patients (52.38%) with MD presented at least one ear with SP/AP >0.4 , differently from patients with VM who exhibited SP/AP values suggestive of EH ($p=0.02$) in only three cases (14.28%).

DISCUSSION

The diagnostic evaluation of patients with VM is often challenging because its criteria still relies on clinical findings taken from an accurate anamnesis; vestibular testing may help the physician to rule out the presence of any associated vestibular hypofunction that might justify some of the patient's complaints, but it does not really contribute to discriminating between VM and MD.

First of all, the patients with VM enrolled in our study did not show any relevant abnormalities in the vHIT examination, with the excep-

tion of one patient (4.76%) who had a gain value of 0.73 for the left and 0.76 for the right ear, close to the inferior limit of normal range. According to the literature data, vHIT is more frequently pathological in patients with MD than in those with VM, and when studies are limited to the latter group, only a small proportion show abnormal gain values. For example, when Blodow et al.^[29] compared vHIT data on 30 subjects suffering from MD and 23 individuals with VM, they observed a significantly reduced gain in the first group, with only 9% of the patients with VM showing an abnormal gain. It is important to underline that in contrast to patients with MD with abnormal gain, who presented a wide range of reduced gain (between 0.1 and 0.79), VM subjects with reduced gain presented values contained within a narrower interval (between 0.7 and 0.79), close to the inferior limit of normal gain. The prevalence of abnormal findings in the vHIT is quite similar to the one reported by Kang et al.^[20] (11%), but very far from the one reported by ElSherif et al.^[30] (26%); however, when considering only the absolute VOR gain, the percentage reported by the latter authors was reduced to 8%.

Traditionally, an altered EcochG has been associated with EH, a common histopathological feature of MD. For this reason, it is not surprising to find only scarce data about EcochG recordings in VM. From the comparison of EcochG values between patients suffering from MD and VM, we found a higher prevalence of abnormal SP/AP ratios in the first group ($p=0.02$). Our results agree with Martin-Sanz et al.^[31], who found in a study comparing audiological and vestibular features of patients with MD and VM a significantly higher proportion of abnormal EcochG in the former group; we should specify that they also included patients with probable VM and adopted a higher (>0.5) cut-off for SP/AP. Lofti et al.^[25], compared the EcochGs of 10 patients with VM and 10 normal subjects, and they did not find a significant difference in mean SP/AP ratio ($p>0.05$); however, two cases of SP/AP >0.42 were found among vestibular migraineurs. In contrast, Yollu et al.^[22], in a more recent study, found a higher percentage (71.4%) of SP/AP >0.4 among subjects suffering from VM, with a significant difference from a group of migraineurs without vertigo complaints. It should be underlined that, even though these authors declared that they excluded patients with any sort of medical history that could be remotely related to MD, they reported low-frequency SNHL in 28.6% of cases among VM subjects; this audiometric pattern is often associated with MD and, for this reason, an overlap of MD and VM may justify the higher proportion of pathological SP/AP found.

Could these findings be interpreted as indirect signs of similar pathological pathways involving both MD and VM? Even though it can be claimed that the detection of EH may be a casual finding, as seen sometimes in normal patients, and that subjects suffering from VM with abnormal EcochG may develop MD over time, the possibility of a common type of inner ear damage in patients with MD and VM has been previously suspected. In particular, Zuniga et al.^[20], from the comparison of vestibular evoked myogenic potentials (VEMP) amplitude, were not able to differentiate MD and VM on most of the VEMP test battery, suggesting they might be related in both cases to saccular hydrops. Furthermore, other authors have hypothesized that EH could be the consequence of consecutive end-organ damage, independently from its triggers^[32]. Gürkov et al.^[33], in a study conducted using a locally enhanced inner ear MRI technique on 19 patients with VM, found morphologic evidence of cochlear and ves-

tibular EH in four patients, of which three also received a diagnosis of definite MD; interestingly, in the sample reported, 10 subjects exhibited abnormal EcochG values and, of these, two did not report any hearing loss in audiometric testing. Kirsh et al. [34], reported a case of a 61-year-old woman suffering from VM attacks without hearing loss who was found to have increased endolymphatic space volume in a gadolinium-enhanced MRI of the inner ear. Other authors have instead theorized that MD might be considered a variant of VM, and that the symptoms are a consequence of a migraine etiology and not of an intrinsic inner ear disorder; according to their hypothesis, the hearing loss experienced by patients with MD may be a consequence of recurrent vasospasms in the inner ear circulation and its anastomotic patterns [35].

This study presents the following limitations: to begin with, all patients were assessed in a symptom free interval; this may account for the lower prevalence of abnormal vestibular testing results compared to other authors. Secondly, the study sample is relatively small; however, differently from other authors, we only selected patients with definite VM without overlapping with definite MD. Third, we do not have a follow-up on the patients with VM, so we cannot conclude that subjects with pathological SP/AP will not develop MD in the future, nor that patients with normal SP/AP will not show pathological EcochG over time.

CONCLUSION

In conclusion the present study found a higher proportion of abnormal EcochG in MD with respect to VM ($p=0.02$) without any significant difference in the vHIT gain. On the basis of our findings, the question of the underlying common pathophysiological mechanism that might explain the detection of EH in some patients suffering from definite VM cannot be conclusively answered. Furthermore, future longitudinal studies may help in better understanding whether abnormal EcochG findings can predict the occurrence of MD among VM patients.

Ethics Committee Approval: Ethics committee approval was received for this study from the Medical Ethics Committee of AOUP (27/06).

Informed Consent: Informed consent was obtained from the patients who participated in this study.

Peer-review: Externally peer-reviewed.

Author Contributions: Concept – F.M., P.S.; Design - F.M., F.D.; Supervision - P.S., F.M.; Resource - F.B., R.L.G.; Materials - A.T., R.P.; Data Collection and/or Processing - A.T., R.P., C.M.; Analysis and/or Interpretation -F.G., C.M.; Literature Search - R.P., R.L.G.; Writing - F.M., P.S.; Critical Reviews - F.D., C.M., P.S.

Conflict of Interest: The authors have no conflict of interest to declare.

Financial Disclosure: The authors declared that this study has received no financial support.

REFERENCES

1. Neuhauser H, Leopold M, von Brevern M, Arnold G, Lempert T. The interrelations of migraine, vertigo, and migrainous vertigo. *Neurology* 2001; 56: 436-41. [\[Crossref\]](#)
2. Vuković V, Plavec D, Galinović I, Lovrenčić-Huzjan A, Budisić M, Demarin V. Prevalence of vertigo, dizziness, and migrainous vertigo in patients with migraine. *Headache* 2007; 47: 1427-35. [\[Crossref\]](#)
3. Lampl C, Rapoport A, Levin M, Bräutigam E. Migraine and episodic Vertigo: a cohort survey study of their relationship. *J Headache Pain* 2019; 20: 33. [\[Crossref\]](#)
4. Lempert T, Olesen J, Furman J, Waterston J, Seemungal B, Carey J, et al. Vestibular migraine: diagnostic criteria. *J Vestib Res* 2012; 22: 167-72. [\[Crossref\]](#)
5. International Headache Society Classification Subcommittee. The international classification of headache disorders. 3rd edition (beta version). *Cephalalgia* 2013; 33: 629-808. [\[Crossref\]](#)
6. Balaban CD. Migraine, vertigo and migrainous vertigo: links between vestibular and pain mechanisms. *J Vestib Res* 2011; 21: 315-21. [\[Crossref\]](#)
7. Furman JM, Balaban CD. Vestibular migraine. *Ann NY Acad Sci* 2015; 1343: 90-6. [\[Crossref\]](#)
8. Obermann M, Wurthmann S, Steinberg BS, Theysohn N, Diener HC, Naegel S. Central vestibular system modulation in vestibular migraine. *Cephalalgia* 2014; 34: 1053-61. [\[Crossref\]](#)
9. Teggi R, Colombo B, Rocca MA, Bondi S, Messina R, Comi G, et al. A review of recent literature on functional MRI and personal experience in two cases of definite vestibular migraine. *Neurol Sci* 2016; 37: 1399-402. [\[Crossref\]](#)
10. Shin JH, Kim YK, Kim HJ, Kim JS. Altered brain metabolism in vestibular migraine: comparison of interictal and ictal findings. *Cephalalgia* 2014; 34: 58-67. [\[Crossref\]](#)
11. Sharon JD, Hullar TE. Motion sensitivity and caloric responsiveness in vestibular migraine and Meniere's disease. *Laryngoscope* 2014; 124: 969-73. [\[Crossref\]](#)
12. Espinosa-Sanchez JM, Lopez-Escamez JA. New insights into pathophysiology of vestibular migraine. *Frontiers in Neurology* 2015; 6: 12. [\[Crossref\]](#)
13. Koo JW, Balaban CD. Serotonin-induced plasma extravasation in the murine inner ear: possible mechanism of migraine-associated inner ear dysfunction. *Cephalalgia* 2006; 26:1310-9. [\[Crossref\]](#)
14. Vass Z, Steyger PS, Hordichok AJ, Trune DR, Jancsó G, Nuttall AL. Capsaicin stimulation of the cochlea and electric stimulation of the trigeminal ganglion mediate vascular permeability in cochlear and vertebro-basilar arteries: a potential cause of inner ear dysfunction in headache. *Neuroscience* 2001; 103: 189-201. [\[Crossref\]](#)
15. Shore SE, Vass Z, Wys NL, Altschuler RA. Trigeminal ganglion innervates the auditory brainstem. *Journal of Comparative Neurology* 2000; 419: 271-85. [\[Crossref\]](#)
16. Frejo L, Martin-Sanz E, Teggi R, Trinidad G, Soto-Varela A, Santos-Perez S, et al. Extended phenotype and clinical subgroups in unilateral Meniere disease: A cross-sectional study with cluster analysis. *Clin Otolaryngol* 2017; 42: 1172-80. [\[Crossref\]](#)
17. Murofushi T, Tsubota M, Kitao K, Yoshimura E. Simultaneous Presentation of Definite Vestibular Migraine and Definite Ménière's Disease: Overlapping Syndrome of Two Diseases. *Front Neurol* 2018; 9: 749. [\[Crossref\]](#)
18. Baier B, Stieber N, Dieterich M. Vestibular-evoked myogenic potentials in vestibular migraine. *J Neurol* 2009; 256: 1447-54. [\[Crossref\]](#)
19. Zuniga MG, Janky KL, Schubert MC, Carey JP. Can Vestibular-Evoked Myogenic Potentials Help Differentiate Ménière Disease from Vestibular Migraine? *Otolaryngol Head Neck Surg* 2012; 146: 788-96. [\[Crossref\]](#)
20. Kang WS, Lee SH, Yang CJ, Ahn JH, Chung JW, Park HJ. Vestibular Function Tests for Vestibular Migraine: Clinical Implication of Video Head Impulse and Caloric Tests. *Front Neurol* 2016; 7: 166. [\[Crossref\]](#)
21. Kirkim G, Mutlu B, Olgun Y, Tanrıverdzade T, Keskinöglü P, Güneri EA, et al. Comparison of Audiological Findings in Patients with Vestibular Migraine and Migraine. *Turk Arch Otorhinolaryngol* 2017; 55: 158-61. [\[Crossref\]](#)
22. Yollu U, Uluduz DU, Yilmaz M, Yener HM, Akil F, Kuzu B, et al. Vestibular migraine screening in a migraine-diagnosed patient population, and assessment of vestibulocochlear function. *Clin Otolaryngol* 2017; 42: 225-33. [\[Crossref\]](#)
23. Gibson WP. The Clinical Uses of Electrocochleography. *Front Neurosci* 2017; 11: 274. [\[Crossref\]](#)

24. Vitkovic J, Paine M, Rance G. Neuro-otological findings in patients with migraine- and nonmigraine-related dizziness. *Audiol Neurootol* 2008; 13: 113-22. [\[Crossref\]](#)
25. Lotfi Y, Mardani N, Rezazade N, Saedi Khamene E, Bakhshi E. Vestibular function in patients with vestibular migraine. *Aud Vest Res* 2016; 25: 166-74.
26. Lopez-Escamez JA, Carey J, Chung WH, Goebel JA, Magnusson M, Mandalà M, et al. Diagnostic criteria for Ménière's disease. *J Vestib Res* 2015; 25: 1-7. [\[Crossref\]](#)
27. Guinand N, Van de Berg R, Cavuscens S, Ranieri M, Schneider E, Lucieer F, et al. The Video Head Impulse Test to Assess the Efficacy of Vestibular Implants in Humans. *Front Neurol* 2017; 8: 600. [\[Crossref\]](#)
28. Kim HH, Kumar A, Battista RA, Wiet RJ. Electrocochleography in patients with Meniere's disease. *Am J Otolaryngol* 2005; 26: 128-31. [\[Crossref\]](#)
29. Blödow A, Heinze M, Bloching MB, von Brevern M, Radtke A, Lempert T. Caloric stimulation and video-head impulse testing in Ménière's disease and vestibular migraine. *Acta Otolaryngol* 2014; 134: 1239-44. [\[Crossref\]](#)
30. ElSherif M, Reda MI, Saadallah H, Mourad M. Video head impulse test (vHIT) in migraine dizziness. *J Otol* 2018; 13: 65-7. [\[Crossref\]](#)
31. Martin-Sanz E, Vargas Salamanca E, Marqués Cabrero A, Esteban J, Muerte I, Sanz-Fernández R. Value of clinical data and vestibular testing in a population of 101 patients with recurrent vestibulopathy. *Clin Otolaryngol* 2014; 39: 311-5. [\[Crossref\]](#)
32. Straube A, Rauch SD. Vertigo and migraine: a more than two-fold connection. *Cephalalgia* 2010; 30: 774-6. [\[Crossref\]](#)
33. Gürkov R, Kantner C, Strupp M, Flatz W, Krause E, Ertl-Wagner B. Endolymphatic hydrops in patients with vestibular migraine and auditory symptoms. *Eur Arch Otorhinolaryngol* 2014; 271: 2661-7. [\[Crossref\]](#)
34. Kirsch V, Becker-Bense S, Berman A, Kierig E, Ertl-Wagner B, Dieterich M. Transient endolymphatic hydrops after an attack of vestibular migraine: a longitudinal single case study. *J Neurol* 2018; 265(Suppl 1): 51-3. [\[Crossref\]](#)
35. Ghavami Y, Mahboubi H, Yau AY, Maducdoc M, Djalilian HR. Migraine features in patients with Meniere's disease. *Laryngoscope* 2016; 126: 163-8. [\[Crossref\]](#)