

# Reverse remodeling and arrhythmic burden reduction in a patient with an implantable cardioverter defibrillator treated with sacubitril/valsartan: Case report

Egle Corrado | Antonino Saladino | Giusy Morgante | Antonino Mignano |  
Cinzia Nugara | Giuseppina Novo | Giuseppe Coppola

UTIC – Cardiologia, Policlinico  
Universitario Paolo Giaccone, Palermo,  
Italy

## Correspondence

Antonino Saladino, UTIC – Cardiologia,  
Policlinico Universitario Paolo Giaccone,  
Via del Vespro 129, contrada Montagna  
91028 Partanna (TP), Italy.  
Email: antoninosaladino88@gmail.com

## Funding information

Novartis Pharma

## Abstract

Sacubitril/valsartan has been shown to reduce cardiovascular mortality and hospitalizations in patients with HFrEF when compared to enalapril. There are also some evidences of its potential antiarrhythmic effects. We present a report where we found a relation between reverse ventricular remodeling and arrhythmic reduction in a patient treated with sacubitril/valsartan.

## KEYWORDS

ARNI, arrhythmic burden, heart failure, remodeling

## 1 | INTRODUCTION

Heart failure (HF) is the common final pathway of many acute and chronic cardiac disorders that significantly worsen the left ventricular function.

The 2016 European Society of Cardiology<sup>1</sup> guidelines state a IB class of recommendation for sacubitril/valsartan in patients with heart failure with reduced ejection fraction (HFrEF) after the publication of PARADIGM-HF, that demonstrated the superiority of sacubitril/valsartan, compared to enalapril, in reducing the risk of death and hospitalization for heart failure.<sup>2,3</sup>

Sacubitril/valsartan is the association of the neprilysin inhibitor sacubitril and the angiotensin–receptor-blocker valsartan.

Neprilysin is a neural endopeptidase that degrades several endogenous vasoactive peptides such as natriuretic peptides, bradykinin, and adrenomedullin. This inhibition increases hormone serum levels, antagonizing sodium retention, vasoconstriction, and remodeling.<sup>4</sup>

Although the physiological mechanisms of action of sacubitril/valsartan are well known, its effects on left ventricular remodeling and left ventricular ejection fraction (LVEF) have not been well studied.<sup>4</sup>

Cardiac remodeling can be defined as the result of different molecular, cellular, and histological myocardial changes that lead to fibrosis, modifications of heart size and function. Several studies have demonstrated that, in many patients with HFrEF, remodeling can be reversed when the cardiac insult is removed or, much more frequently, with pharmacological therapy.<sup>4</sup> Other studies have demonstrated that angiotensin converting enzyme (ACE)-inhibitors, angiotensin receptor blockers, beta-blockers, and mineralocorticoid receptor antagonists are effective in reverse remodeling and in improving LVEF.<sup>4</sup>

When patients have symptoms of sustained ventricular tachycardia, cardiac arrest, or when LVEF is lower than 30%, an implantable cardiac defibrillator (ICD) is mandatory in primary prevention both for ischemic or nonischemic cardiomyopathy.<sup>5</sup>

In patients with left bundle branch block (LBBB) and consequent ventricular dyssynchrony, cardiac resynchronization

therapy (CRT) can successfully induce reverse remodeling, primarily in responding patients.<sup>6,7</sup>

The most common left ventricular function echocardiographic evaluations, including left ventricular end diastolic volume, left ventricular end systolic volume, left ventricular dimension and LVEF, were critically reviewed to be unclear in elucidating data on clinical outcomes and were not validated as useful follow up methods to analyze the effect of sacubitril/valsartan; the same is true for the left ventricular systo-diastolic deformations analyzed with strain imaging, that in other clinical scenarios was demonstrated to have good clinical performance.<sup>9</sup>

Strain is defined as the fractional change in length of a myocardial segment relative to its baseline length and is expressed as percentage. Strain rate is the temporal derivative of strain, and it provides information on the speed at which the deformation occurs.<sup>9</sup> Strains commonly used in clinical contests are oriented along with the coordinate system of the left ventricle; they analyze radial thickening and thinning and circumferential and longitudinal shortening and lengthening.<sup>9</sup>

One of the most commonly used parameters is longitudinal strain. Global longitudinal strain (GLS) reflects the deformation along the entire left ventricle.

Sacubitril/valsartan was also found to be useful in arrhythmic burden reduction.<sup>10</sup>

We report a case of a male patient with HFrEF and ICD carrier treated successfully with sacubitril/valsartan. In this clinical case report, we showed that sacubitril/valsartan, beyond optimal medical therapy, played a role in left ventricular reverse remodeling and in arrhythmic burden reduction.

## 2 | CASE REPORT

A 61-year-old man with a medical history of heart failure with midrange ejection fraction (last exhibited 40%) secondary to previous myocarditis of the lateral wall and with an ICD was admitted in February 2018 to our outpatient clinic for worsening of his clinical conditions.

He had a clinical history of myocarditis in 2008, confirmed by cardiac MRI and followed by several episodes of sustained symptomatic ventricular tachycardia that lead to the ICD implantation. Ejection fraction was 40% at that time and remained stable during follow up.

He received optimal pharmacological therapy with enalapril 20 mg BID, carvedilol 25 mg BID, spironolactone 25 mg QID, and furosemide 100 mg. The choice of carvedilol was due to the concomitant hypertension because of its bigger valodilator effects.

At the time of admission, the patient was in NYHA class III, with bendopnea and shortness of breath, blood pressure 115/70 mm Hg, and NT-proBNP 2500 pg/dL.

Hematological exams showed normal hemocrome, K and Na; creatinine level 1.6 mg/dL (eGFR 47.42 mL/min/1.73 m<sup>2</sup>).

The electrocardiogram showed sinus tachycardia and left bundle branch block (LBBB).

We performed a complete echocardiography with strain imaging that showed a worse ejection fraction (30%), moderate (2+/4+) mitral regurgitation, and global longitudinal strain-8% (Table 1). Then, we decided to start therapy with sacubitril/valsartan 49/51 mg BID stopping enalapril, before eventual upgrading to CRT.

Before starting sacubitril/valsartan, we analyzed the arrhythmic burden by performing an ICD test, looking for sustained and nonsustained ventricular tachycardia and ventricular extrasystolic activity per hour.

Our patient, in the year before our examination, had an average of six episodes per month of nonsustained ventricular tachycardia (the longest lasted 12 seconds), one episode of sustained ventricular tachycardia effectively treated by anti-tachy-pacing, one episode of sustained atrial tachycardia, and a 220/h average of ventricular extrasystoles.

After 2 months of therapy, the patient had improvement of his clinical condition and functional capacity and was in class NYHA II; clinical examination showed no signs of peripheral or pulmonary congestion and unchanged ECG. Blood pressure was 125/80 mm Hg so we decided to titrate sacubitril/valsartan to 97/103 mg BID.

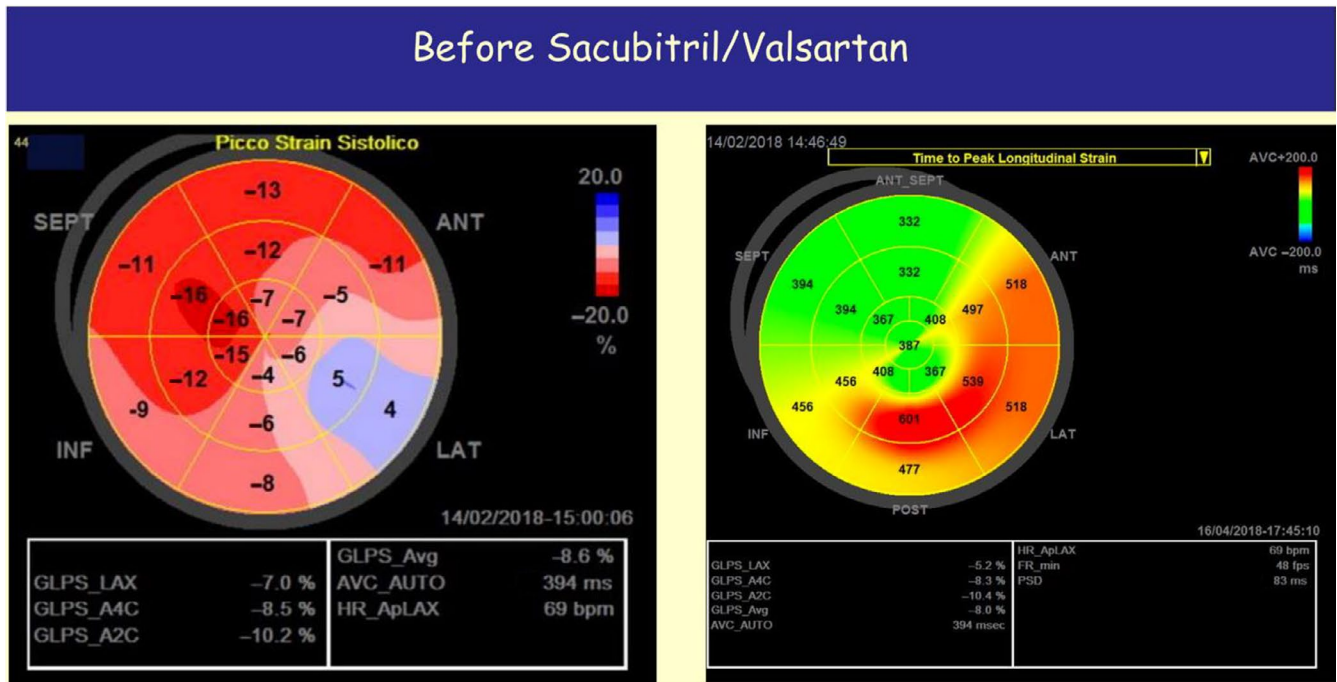
The furosemide dosage was reduced from 100-50 mg/die.

Hematological examination showed reduced creatinine levels (1.4 mg/dL, eGFR 55 mL/min/1.73 m<sup>2</sup>); NT-proBNP was 500 pg/dL.

We performed a complete echocardiographic evaluation that showed an increased ejection

**TABLE 1** Echocardiographic data before sacubitril/valsartan and after 2 mo of therapy

	Before sacubitril/valsartan	After 2 mo of therapy
LVEDV (mL)	130	134
LVESV (mL)	85	76
EF (Ejection fraction, %)	35	43
LA area (cm <sup>2</sup> )	22	22
LA volume (mL)	116	114
GLS (%)	-8.6	-13.8
LA strain (%)	3.6	8.6
RV strain (%)	-9.4	-14.8
E/e'	15	6
sPAP (mm Hg)	43	30
Mitral regurgitation	++/4+	+/4+



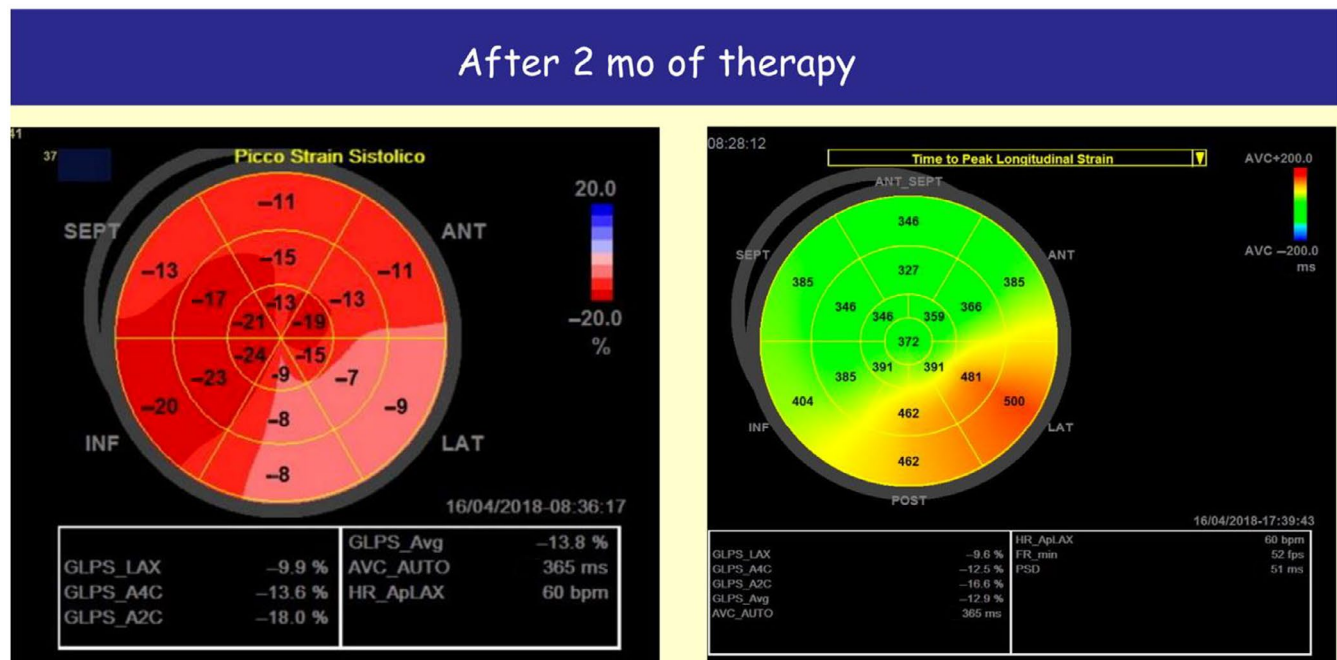
**FIGURE 1** Echocardiographic strain analysis before sacubitri/valsartan

fraction (LVEF 43%), reduction of mitral regurgitation (1+/4+), improvement of systolic, and diastolic indices with a reduction of dyssynchrony and GLS of  $-13,85$  (Table 1).

The examination of his arrhythmic burden showed just three episodes of nonsustained ventricular tachycardia in the

2 months of therapy, no sustained ventricular tachycardia, no supraventricular tachycardia, and a significant reduction in ventricular extrasystoles (220/h-50/h).

We confirmed no modification of beta-blockers dosage, because our patient already had the maximum tolerated dose of carvedilol.



**FIGURE 2** Echocardiographic strain analysis after 2 mo of therapy with sacubitri/valsartan

### 3 | DISCUSSION

In patients with HFrEF LVEF have been shown to be predictive of cardiovascular death, heart failure hospitalization, and all-cause mortality. In our patient with chronic HFrEF due to previous myocarditis, with worsening of clinical condition and who had received optimal medical therapy we started sacubitril/valsartan and stopped enalapril.

After 2 months, we observed improvement in symptoms and functional capacity; he moved from NYHA class III to NYHA class II. At the echocardiographic examination LVEF increased from 30% to 43%, global longitudinal strain moved from  $-8\%$  to  $-13.85\%$  (Figure 1, Figure 2) and mitral regurgitation decreases from moderate to mild. We also observed a modification of the arrhythmic burden that consisted of reduction of nonsustained ventricular tachycardia, absence of sustained ventricular tachycardia, no supraventricular tachycardia, and a significant reduction in hourly ventricular extrasystoles from 220/h to 50/h in the 2 months of therapy.

To our knowledge left ventricular function echocardiographic evaluations, such as LVEF and the systo-diastolic deformation with strain imaging are not validated as useful and clear for the follow up of patients who have received sacubitril/valsartan.

The improvement in clinical condition, LVEF, chambers volumes, global longitudinal strain, and the arrhythmic burden reduction we observed can explain why sacubitril/valsartan was shown to be superior to enalapril in reducing mortality and HF hospitalizations in patients with HFrEF. The inhibition of neprilysin may lead to a reduction in pulmonary pressure, myocardial after load, and mitral regurgitation, with improvement of NYHA functional class. Less clear is how sacubitril/valsartan reduces the arrhythmic burden; it is probably due to a complex interaction among the increased ejection fraction, the reduced sympathetic tone, and reverse remodeling.

Giving the long-term favorable findings of sacubitril/valsartan and our experience with this patient, we suggest that larger clinical trials are needed to assess the efficacy of echocardiographic evaluation in patients who start therapy with sacubitril/valsartan and for the evaluation of the potential indirect antiarrhythmic effects. Another important topic will be to understand how sacubitril/valsartan could improve reverse remodeling in CRT nonresponder patients and if it will be a valid alternative solution in patients waiting for CRT implantation or upgrading.

#### CONFLICT OF INTEREST

None declared.

#### AUTHORS' CONTRIBUTIONS

First EC, second AS, and last GC: author contributed in equal measure, coordinating the drafting of the article and writing

the discussion and references. Third GM: contributed in introduction and references; fourth AM: contributed writing case report and conclusion. Fifth CN: contributed performing the echocardiography. Sixth GN: contributed on strain analysis.

#### ORCID

Antonino Saladino  <https://orcid.org/0000-0001-9535-5039>

Giuseppe Coppola  <https://orcid.org/0000-0003-3080-407X>

#### REFERENCES

1. Ponikowski P, Voors AA, Anker SD, et al. 2016 ESC guidelines for the diagnosis and treatment of acute and chronic heart failure. *Eur Heart J*. 2016;37:2129-2130.
2. Solomon SD, Claggett B, Desai AS, et al. Influence of ejection fraction on outcomes and efficacy of sacubitril/valsartan (LCZ696) in heart failure with reduced ejection fraction. *Circ Heart Fail*. 2016;9:e00274.
3. McMurray JJ, Packer M, Desai AS, et al. Angiotensin-neprilysin inhibition versus enalapril in heart failure. *N Engl J Med*. 2014;371(11):993-1004.
4. Iborra-Egea O, Gálvez-Montón C, Roura S, et al. Mechanisms of action of sacubitril/valsartan on cardiac remodeling: a systems biology approach. *NPJ Syst Biol Appl*. 2017;3:12.
5. Coppola G, Guttilla D, Corrado E, et al. ICD implantation in non-compaction of the left ventricular myocardium: a case report. *Pacing Clin Electrophysiol*. 2009;32:1092-1095.
6. Coppola G, Ciaramitaro G, Stabile G, et al. Magnitude of QRS duration reduction after biventricular pacing identifies responders to cardiac resynchronization therapy. *Int J Cardiol*. 2016;221:450-455.
7. Carità P, Corrado E, Pontone G, et al. Non-responders to cardiac resynchronization therapy: insights from multimodality imaging and electrocardiography. A brief review. *Int J Cardiol*. 2016;225:402-407.
8. Merlo M, Caiffa T, Gobbo M, Adamo L, Sinagra G. Reverse remodeling in dilated cardiomyopathy: insights and future perspectives. *Int J Cardiol Heart Vasc*. 2018;18:52-57.
9. Mirea O, Duchenne J, Voigt JU. Recent advances in echocardiography: strain and strain rate imaging. *F1000Res*. 2016;5:787-96.
10. De Diego C, Gonzalez-Torres L, Núñez JM, et al. Effects of angiotensin-neprilysin inhibition compared to angiotensin inhibition on ventricular arrhythmias in reduced ejection fraction patients under continuous remote monitoring of implantable defibrillator devices. *Heart Rhythm*. 2018;15:395-402.

**How to cite this article:** Corrado E, Saladino A, Morgante G, et al. Reverse remodeling and arrhythmic burden reduction in a patient with an implantable cardioverter defibrillator treated with sacubitril/valsartan: Case report. *Clin Case Rep*. 2020;8:1349–1352. <https://doi.org/10.1002/ccr3.2655>