

Extended Abstract

# Use of Optical Coherence Tomography in Patients with Desquamative Gingivitis: A Case Series <sup>†</sup>

Vera Panzarella <sup>1,2,\*</sup>, Alessia Bartolone <sup>2</sup>, Domenico Ciavarella <sup>3</sup>, Andrea Santarelli <sup>4</sup>, Olga Di Fede <sup>2</sup>, Rodolfo Mauceri <sup>1</sup> and Giuseppina Campisi <sup>1,2</sup>

<sup>1</sup> Unit of Oral Medicine, A.O.U.P. "Paolo Giaccone", 90127 Palermo, Italy; rodolfo.mauceri@unipa.it (R.M.); giuseppina.campisi@unipa.it (G.C.)

<sup>2</sup> Department of Surgical, Oncological and Oral Sciences (Di.Chir.On.S.), University of Palermo, 90127 Palermo, Italy; alessia.bartolone@community.unipa.it (A.B.); olga.difede@unipa.it (O.D.F.)

<sup>3</sup> Department of Clinical and Experimental Medicine, University of Foggia, 71122 Foggia, Italy; domenico.ciavarella@unifg.it

<sup>4</sup> Department of Clinical Specialistic and Dental Sciences, Marche Polytechnic University, 60121 Ancona, Italy; andrea.santarelli@staff.univpm.it

\* Correspondence: panzarella@odonto.unipa.it

<sup>†</sup> Presented at the XV National and III International Congress of the Italian Society of Oral Pathology and Medicine (SIPMO), Bari, Italy, 17–19 October 2019.

Published: 12 December 2019

## 1. Introduction

Desquamative gingivitis (DG) is a descriptive term indicating the presence of erythematous, erosive, desquamative and vesiculo-bullous lesions in the free/attached gingiva, usually expression of several chronic systemic conditions [1].

Optical Coherence Tomography (OCT) is a new biomedical technique based on the interaction of the infrared radiation (900–1500 nm) to the human tissues, allowing the visualization at high resolution of the micro-structural morphology. OCT is proposed in dermatology, ophthalmology and recently in oral medicine [2]. It could be recommended for managing the patients with chronic disease, such as DG.

The aim of this paper is to report a case series of three patients affected by clinical DG valued by OCT before diagnostic biopsy in order to assess the morphology of the lesions and to guide the oral medicine specialist to hypothetical differential diagnosis.

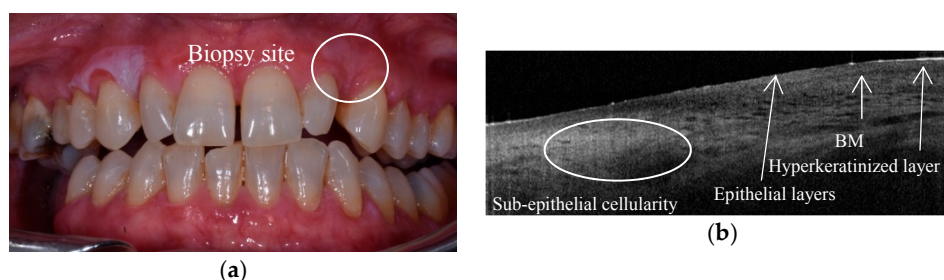
## 2. Case Series

Three female patients (mean age  $74 \pm 9.2$  years), with clinical DG, were consecutively recruited at unit of Oral Medicine, and after informed consent, underwent to in vivo OCT examination. In details, we used VivoSight® OCT (Michelson Diagnosis) which is equipped with a flexible fiber optic probe. However, the probe, because it is used for dermatological purposes, is not of the optimal size for the oral cavity. In this way OCT allows to obtain a scan section with width of 6mm and focal depth of 2 mm.

After photo record, OCT examination was performed on each patient in order to identify the most suggestive DG site for the incisional punch biopsy, successively performed by a punch 6 mm diameter (the same size area of OCT scans).

**Case 1–2:** For both patients, DGs were characterized by erythematous, desquamative, hyperkeratotic lesions. In both cases Nikolsky's sign was negative (Figure 1a).

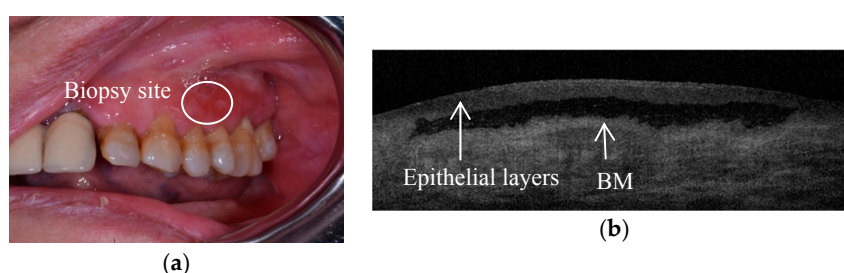
OCT scans showed: hyperkeratinization, unhomogeneity and decrease of the epithelial layers and increased sub-epithelial cellularity under basement-membrane (BM) (Figure 1b).



**Figure 1. (Case 1)** (a) Atrophic-erosive, desquamative and hyperkeratotic DG, (biopsy site underlined); (b) OCT scan of the same site of punch biopsy, with morphological details.

**Case 3:** DG showed erythematous, desquamative, hyperkeratotic areas, associated with a positive Nikolsky’s sign (Figure 2a).

OCT scan showed a compact epithelial layer entirely separated from the BM by interposed fluid that appears dark, and potentially suggestive of a sub-epithelial blister (Figure 2b) [3].



**Figure 2. (Case 3)** (a) Atrophic-erosive, hyperkeratotic and vesicular DG, (biopsy site underlined); (b) OCT scan shows evident detachment of the epithelium from BM zone.

Histological reports of **Case 1** and **2** were Oral Lichen Planus; whereas **Case 3** was Mucous Membrane Pemphigoid (MMP).

### 3. Conclusions

We presented three patients with similar clinical-features of DGs, that showed a morphological diversity by OCT investigation.

In details, in **case 1–2** were present an alteration of epithelial layers with a greater sub-epithelial cellularity, reported in OCT scans could be evocative of a chronic inflammatory infiltrate, usually histologically described in OLP.

In **case 3** it was a clear evidence of a sub-epithelial blister that could early guider the clinician to a diagnosis sub-epithelial vesicular-bullous pathologies (I.E MMP).

The results of our study, although reported to a small simple size, prompt a potential use of OCT in clinical management of DG. In particular, for preliminary assessment of the lesions, in order to suggest a more specific sites for histological investigation.

**Conflicts of Interest:** The authors declare no conflict of interest.

### References

1. Lo Russo, L.; Fierro, G.; Guiglia, R.; Compilato, D.; Testa, N.F.; Lo Muzio, L.; Campisi, G. Epidemiology of desquamative gingivitis: Evaluation of 125 patients and review of the literature. *Int. J. Dermatol.* **2009**, *48*, 1049–1052. doi:10.1111/j.1365-4632.2009.04142.x.
2. Huang, D.; Swanson, E.A.; Lin, C.P.; Schuman, J.S.; Stinson, W.G.; Chang, W.; Hee, M.R.; Flotte, T.; Gregory, K.; Puliafito, C.A.; et al. Optical coherence tomography. *Science* **1991**, *254*, 1178–1181.

3. Capocasale, G.; Panzarella, V.; Rodolico, V.; Di Fede, O.; Campisi, G. In vivo optical coherence tomography imaging in a case of mucous membrane pemphigoid and a negative Nikolsky's sign. *J. Dermatol.* **2018**, *45*, 603–605. doi:10.1111/1346-8138.14267.



© 2019 by the authors. Licensee MDPI, Basel, Switzerland. This article is an open access article distributed under the terms and conditions of the Creative Commons Attribution (CC BY) license (<http://creativecommons.org/licenses/by/4.0/>).