

CASE REPORT

Sudden death in water: Diagnostic challenges



Elvira Ventura Spagnolo ^{a,*}, Cristina Mondello ^b, Luigi Cardia ^c, Stefania Zerbo ^a, Giulio Cardia ^b

^a Department of Biotechnology and Legal Medicine, University of Palermo, Via del Vespro, 129, 90127, Italy

^b Department of Biomedical Science and of Morphological and Functional Images, University of Messina, Via Consolare Valeria, Gazzi, Messina 98125, Italy

^c Department of Neurosciences, University of Messina, Via Consolare Valeria, Gazzi 98125, Italy

Received 3 May 2015; revised 25 June 2015; accepted 20 July 2015

Available online 12 September 2015

KEYWORDS

Sudden death;
Breath-held diving;
Arrhythmia;
Hypoxia

Abstract: The authors report a case of sudden death in a breath-holding diver and highlight the forensic diagnostic difficulties in opining the cause of sudden death in water. The autopsy showed increased thickness of the left ventricular wall with a distinct pattern of concentric hypertrophy, evident particularly in the subaortic interventricular septum. Histological examination revealed diffuse interstitial fibrosis and associated findings of multifocal myocyte disarray especially evident in the subaortic interventricular septum. The analysis and discussion of this case made it possible to attribute sudden death to a lethal arrhythmia following myocyte disarray and hypoxia caused by breath-holding, the triggering factor of apnea. This case demonstrates the importance of a thorough forensic investigation, particularly in histological terms, in subjects found dead in water, in order to ascertain the real cause of death, which may not be always ascribable to drowning.

© 2015 The International Association of Law and Forensic Sciences (IALFS). Production and hosting by Elsevier B.V. All rights reserved.

1. Introduction

The scientific community has long debated on the need to distinguish between subjects dying of asphyctic syndrome from drowning and subjects found dead in water. In 1999 Modell

et al. deemed it appropriate to apply to the latter the notion of “drowning without aspiration”.¹

These implications are even more important in cases where forensic investigations provide evidence that the presence of pre-existing pathological conditions may have contributed to and/or caused death in water.

This issue is further complicated by the inherent difficulty of ascertaining that sudden death in water had occurred at such an early stage that no drowning fluid could enter the airways and generally the gastrointestinal tract. In addition, other than in deaths caused by the inhibitory nervous mechanism or asphyctic syndrome from laryngospasm, the main mechanisms underlying sudden death in water do not necessarily involve

* Corresponding author.

E-mail addresses: elvira.ventura@unipa.it (E. Ventura Spagnolo), mondello@unime.it (C. Mondello), luigicardial@gmail.com (L. Cardia), stefania.zerbo@unipa.it (S. Zerbo), gcardia@unime.it (G. Cardia).

Peer review under responsibility of The International Association of Law and Forensic Sciences (IALFS).

<http://dx.doi.org/10.1016/j.ejfs.2015.07.003>

2090-536X © 2015 The International Association of Law and Forensic Sciences (IALFS). Production and hosting by Elsevier B.V. All rights reserved.

such a sudden arrest of cardiac function and breathing as to allow concomitant drowning to be ruled out.²

These considerations are extremely relevant given the growing number of diving incidents that require medical assessment, as competitive and/or non-competitive breath-held diving activities have become increasingly popular.

The authors report a case of sudden death in a breath-holding diver hunting underwater.

2. Case report

A 44-year-old man died during breath-held diving while hunting under water. His body was found on the seabed about 6 h after plunging. The police authority then requested a post-mortem examination.

The external examination of the body, weighing 77 kg and measuring 174 cm in length, revealed conjunctival hyperaemia and moderate leakage of reddish fluid from the nostrils. There was no evidence of traumatic injuries on the body.

The internal examination showed in particular that the heart weighed 400 g and had a significant concentric left ventricle hypertrophy particularly in the subaortic interventricular septum (asymmetrical form with significant Van Noorden index), bilateral atrial enlargement and a mild prolapse of the posterior mitral leaflet. The lungs showed some subpleural petechiae and bronchial leakage of pinkish foam.

Samples of tissues and fluids were collected for further histological and toxicological testing.

Toxicology tests were performed on the heart, blood, urine and bile. All specimens tested negative for alcohol, illegal and psychotropic drugs.

Histological tests reported hyperventilated alveoli often converging into emphysematous spaces. Seventy-five percent of these spaces were optically empty (Fig. 1), while the other 25% contained scarce red-blood cells (Fig. 2). The examination of the heart revealed multifocal myocyte disarray affecting 35% of the left ventricular sections studied associated with diffuse interstitial fibrosis mainly in the subaortic interventricular septum (Fig. 3). It also showed significant myocyte hypertrophy and a multifocal wave-like pattern (Fig. 4). The examination of the other organs reported no pathological signs.

3. Discussion

The analysis of this case and in particular of the macroscopic and histological cardiac findings demonstrated evidence of previously undiagnosed hypertrophic cardiomyopathy.

This disease is a common cause of sudden death in young adults. It can occur during both routine daily tasks and even mild physical activities.^{3,4} Genetic studies demonstrated that it is associated with dominant autosomal mutations of some genes, including MYH7, MYBPC3 and TNNT2. However, these mutations were reported in slightly less than 50% of clinically affected subjects.⁴

In this disease, the most typical anatomopathological findings are an asymmetrical increase in the thickness of the ventricular walls (particularly in the septum) with a potential shrinkage of the cavity, a common endocardial fibrosis of the mitral leaflet, atrial enlargement and mitral valve thickening. The most common histological findings are an uneven pattern of enlarged and irregular myocardial fibres (“disarray”),

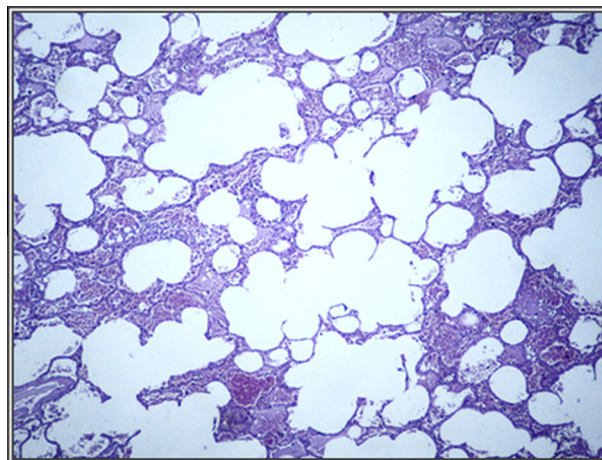


Figure 1 Hyperventilated alveoli converging into optically empty emphysematous spaces (EE 25).

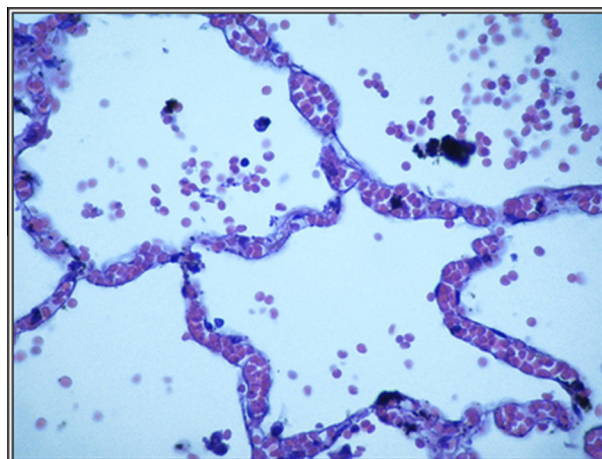


Figure 2 Alveoli sprayed with red blood cells (EE 40).

increased interstitial matrix and fibrotic hyperplasia of intramural arterioles.⁵⁻⁷

Hemodynamic and electrophysiological studies demonstrated that the clinical symptoms of hypertrophic cardiac disease are attributable to mechanisms associated with structural abnormalities of the ventricular cavity and abnormal ejection due to a defective release of myocytes. This mechanism can be promoted by anterior systolic motion of the mitral valve with subsequent congestive cardiac failure.⁸ In other cases, abnormal electrocardiographic findings can be attributed to ischemic events due to the increased myocardial mass. However this finding apparently contradicts the absence of any evidence of myocardial infarction or extensive replacement fibrosis even in severe hypertrophic cardiomyopathy.^{4,9}

Sudden death in hypertrophic cardiomyopathy is a frequent occurrence. It is generally caused by cardiac arrhythmias associated with re-entry mechanisms or excitable foci or a reduced ventricular cavity or small vessel disease.⁵

Although lethal mechanisms underlying arrhythmias associated with sudden death are well understood, the same cannot be said for the cause and timing of the initial triggering event.

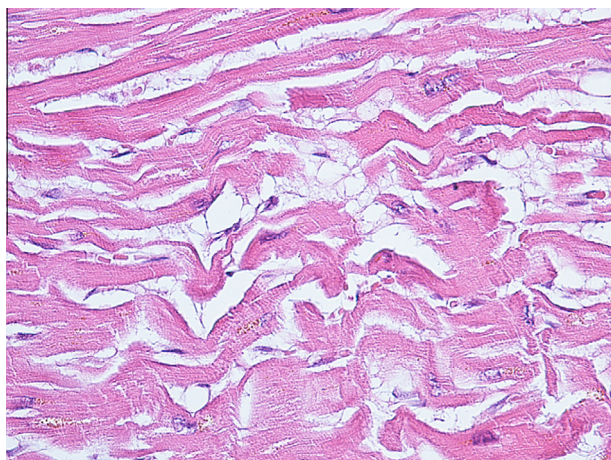


Figure 3 Diffuse interstitial fibrosis and multifocal myocyte disarray especially in the subaortic interventricular septum (EE 25).

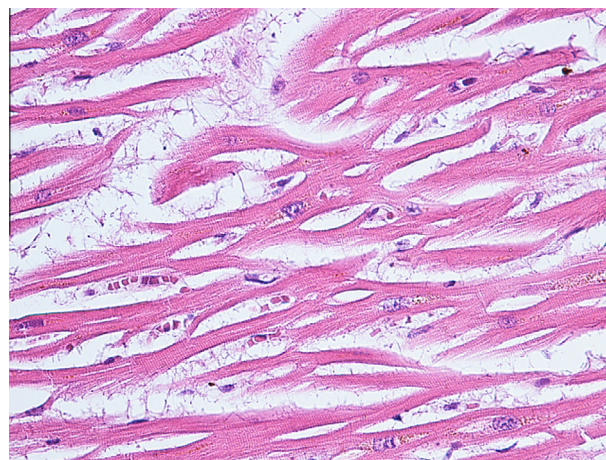


Figure 4 Marked hypertrophy of myocytes and a multifocal wave-like pattern (EE 25).

In fact it is still unclear why some subjects die of sudden death, while others with the same anatomical abnormalities survive. It is believed that there are several factors at play, such as the severity of the macroscopic and histological abnormality or the conditions that increase myocyte metabolic stress (triggering factors).

In this case, the authors maintain that the most relevant triggering factor is breath-holding underwater. Under such a condition the human body undergoes physiological adjustments with redistribution of the blood flow (greater intrathoracic blood volume with increased cardiac and cerebral perfusion), bradycardia and a decline in the cardiac output due to increased peripheral resistance.^{10–12}

This sports activity involves many risks, such as barotrauma, which is a common cause of morbidity and mortality. Another risk worth considering, particularly in this case report, is certainly the onset of arrhythmias, such as extreme bradycardia (even under 10 beats per minute), atrial fibrillation, supraventricular and ventricular extrasystoles (occasionally combined), ventricular tachycardia, right branch bundle block and atrioventricular blockade.

In 1997, Ferrigno et al. examined a number of breath-held dives in a hyperbaric pool and confirmed a faster onset of bradycardia in cold water.¹³ In 2009 Hansel et al. observed a clear-cut correlation between the onset of arrhythmias (recorded in 77% of cases) and the oxygen saturation drop.¹⁴

Arrhythmias are caused by progressive hypoxia and therefore alterations in the hydroelectrolytic balance cause changes in action potential and mitochondrial hypo-anoxia accompanied by the production of reactive oxygen species.

The risk of lethal events during breath-held diving can also be attributable to glossopharyngeal breathing that increases the air inflow in the lungs and may therefore cause hemodynamic fluctuations in both systemic and pulmonary circulation. The increased intrathoracic pressure impedes the return of blood to the right heart. This activity is associated with a significant drop of mean arterial pressure, an increase in heart rate (up to 103 beats per minute) and a decline of differential pressure associated with the drop in the cardiac output.^{15,16} These mechanisms are at

the basis of reduction in the systemic blood pressure and, tissue hypoxia causing syncope or potentially lethal arrhythmias.

In the light of these considerations and the characteristics of this case, it is believed that in the pathogenesis of sudden death the anatomical abnormality (myocyte disarray) acted as the locus *minoris resistentiae* to hypoxia following breath-held diving. In this case breath-holding was the triggering factor which contributed with the cardiac disease to the onset of an arrhythmia that was probably lethal.

4. Conclusions

The analysis and discussion of this case made it possible to attribute sudden death to a lethal arrhythmia following myocyte disarray and hypoxia caused by breath-holding. This was therefore the triggering factor leading to the manifestation of the previously undiagnosed lethal cardiac disease.

This case demonstrates the importance of a thorough forensic investigation, particularly in histological terms, in subjects found dead in water, in order to ascertain the real cause of death, which may not be always ascribable to drowning. Each case should therefore be examined in all its anatomopathological aspects.

Prior to performing breath-held diving it is certainly advisable to undergo appropriate health checkups so as to confirm the eligibility of the subjects who intend to undertake these activities. Campaigns aimed at increasing awareness of the importance of prevention should be promoted along these lines.

Funding

None

Conflict of interest

None declared

Ethical approval

Necessary ethical approval was obtained from the institute Ethics Committee

References

1. Modell JH, Bellefleur M, Davis JH. Drowning without aspiration: is this an appropriate diagnosis? *J Forensic Sci* 1999;**44**(6):1119–23.
2. Dell'Erba A, Santini M. Rapporti tra morte nell'acqua ed annegamento. *Zacchia* 1962;**57**–67.
3. Teare D. Asymmetrical hypertrophy of the heart in young adults; **1957**.
4. Maron BJ, Maron MS. Hypertrophic cardiomyopathy. *Lancet* 2013;**381**(4):242–55.
5. Fineschi V., Baroldi G. Cuore e morte improvvisa in patologia forense. *Cedam*; **2004**.
6. Davies MJ, Pomerance A, Teare RD. Pathological feature of hypertrophic obstructive cardiomyopathy. *J Clin Pathol* 1974;**27**(7):529–35.
7. Davies MJ, McKenna WJ. Hypertrophic cardiomyopathy – pathology and pathogenesis. *Hystopathology* 1995;**26**(6):493–500.
8. Wigle ED, Henderson M, Rakowski H, et al. Muscular (hypertrophic) subaortic stenosis (hypertrophic obstructive cardiomyopathy): the evidence for true obstruction to left ventricular outflow. *Postgrad Med J* 1986;**62**:531–6.
9. Maron BJ, Fananapazir L. Sudden cardiac death in hypertrophic cardiomyopathy. *Circulation* 1992;**85**(1 Suppl.):157–63.
10. Linèr MH. Cardiovascular and pulmonary responses to breath-hold diving in humans. *Acta Physiol Scand Suppl* 1994;**620**:1–32.
11. Ferretti G, Costa M. Diversity in and adaption to breath-old diving in humans. *Comp Biochem Physiol Part A* 2003;**136**:205–13.
12. Lindholm P, Lundgren CEG. The physiology and pathophysiology of human breath-hold diving. *J Appl Physiol* 2009;**106**:284–92.
13. Ferrigno M, Ferretti G, Lundgren CEG, et al. Cardiovascular changes during deep breath-hold dives in a pressure chamber. *J Appl Physiol* 1997;**83**:1282–90.
14. Hansel J, Solleder I, Gfroerer W, Muth CM, Paulat K, Simon P, et al. Hypoxia and cardiac arrhythmias in breath-hold divers during voluntary immersed breath-holds. *Eur J Appl Physiol* 2009;**105**(5):673–8.
15. Novalija J, Lindholm P, Loring SH, Diaz E, Fox JA, Ferrigno M. Cardiovascular effects of Glossopharyngeal insufflation and exufflation. *Undersea Hyperb Med* 2007;**34**(6):415–23.
16. Eichinger M, Waltersbacher S, Scholz T, Tetziaff K, Muth CM, Puderbach M, et al. Lung hyperinflation: foe or friend? *Eur Respir* 2008;**32**(4):1113–6.