

## Case Report

# Presurgical evaluation of hemifacial spasm and spasmodic torticollis caused by a neurovascular conflict from AICA with 3T MRI integrated by 3D drive and 3D TOF image fusion: A case report and review of the literature

Concetta Alafaci, Francesca Granata<sup>1</sup>, Mariano Cutugno, Giovanni Grasso<sup>2</sup>, Francesco M. Salpietro<sup>3</sup>, Francesco Tomasello

Departments of Neurosurgery, <sup>1</sup>Neuroradiology, <sup>3</sup>Neurosurgery, Papardo-Piemonte Hospital, University of Messina, Messina, Italy,

<sup>2</sup>Department of Neurosurgery, University of Palermo, Palermo, Italy

E-mail: \*Concetta Alafaci - [calafaci@unime.it](mailto:calafaci@unime.it); Francesca Granata - [effgranata@alice.it](mailto:effgranata@alice.it); Cutugno Mariano - [cutugnomariano@libero.it](mailto:cutugnomariano@libero.it); Giovanni Grasso - [ggrasso@unipa.it](mailto:ggrasso@unipa.it); Francesco M. Salpietro - [fsalp@unime.it](mailto:fsalp@unime.it); Francesco Tomasello - [ftomasel@unime.it](mailto:ftomasel@unime.it)

\*Corresponding author

Received: 24 January 14 Accepted: 17 April 14 Published: 16 July 14

**This article may be cited as:**

Alafaci C, Granata F, Cutugno M, Grasso G, Salpietro FM, Tomasello F. Presurgical evaluation of hemifacial spasm and spasmodic torticollis caused by a neurovascular conflict from AICA with 3T MRI integrated by 3D drive and 3D TOF image fusion: A case report and review of the literature. *Surg Neurol Int* 2014;5:108.

Available FREE in open access from: <http://www.surgicalneurologyint.com/text.asp?2014/5/1/108/136887>

Copyright: © 2014 Alafaci C. This is an open-access article distributed under the terms of the Creative Commons Attribution License, which permits unrestricted use, distribution, and reproduction in any medium, provided the original author and source are credited.

## Abstract

**Background:** Hemifacial spasm (HS) and spasmodic torticollis (ST) are well-known disorders that are caused by a neurovascular conflict. HS is characterized by irregular, involuntary muscle contractions on one side of the face due to spasms of orbicularis oris and orbicularis oculi muscles, and is usually caused by vascular compression of the VII cranial nerve. ST is an extremely painful chronic movement disorder causing the neck to involuntarily turn to the side, upward and/or downward. HS is usually idiopathic but it is rarely caused by a neurovascular conflict with the XI cranial nerve.

**Case Description:** We present a case of a 36-year-old woman with a 2-year history of left hemifacial spasm and spasmodic torticollis. Pre-surgical magnetic resonance imaging MRI examination was performed with 3T MRI integrated by 3D drive and 3D TOF image fusion. Surgery was performed through a left suboccipital retrosigmoid craniectomy. The intraoperative findings documented a transfixing artery penetrating the facial nerve and a dominant left anteroinferior cerebellar artery (AICA) in contact with the anterior surface of the pons and lower cranial nerves. Microvascular decompression (MVD) was performed. Postoperative course showed the regression of her symptoms.

**Conclusions:** Transfixing arteries are rarely reported as a cause of neurovascular conflicts. The authors review the literature concerning multiple neurovascular conflicts.

**Key Words:** Hemifacial spasm, microvascular decompression, neurovascular conflict, spasmodic torticollis, transfixing artery

**Access this article online****Website:**

[www.surgicalneurologyint.com](http://www.surgicalneurologyint.com)

**DOI:**

10.4103/2152-7806.136887

**Quick Response Code:**

## INTRODUCTION

Neurovascular conflict syndrome is due to an abnormal contact between cranial nerves and arterial or venous

vessels, causing an active cranial nerve dysfunction.<sup>[9,11]</sup> Trigeminal neuralgia (TN), hemifacial spasm (HS), and spasmodic torticollis (ST) are related to V, VII and XI cranial nerve involvement.<sup>[2,9,14,20]</sup> For trigeminal nerve the

most common offending vessel is the superior cerebellar artery (SCA). The facial nerve is usually offended by the anteroinferior cerebellar artery (AICA) and the XI cranial nerve by the posteroinferior cerebellar artery (PICA).<sup>[2]</sup>

Generally, the abnormal contact between nerve and offending vessel can take the form of a “cross compression” or “sandwich compression” which is the entrapment of the nerve between two vascular structures. The possible alterations in the nerve course are stretching, bending, grooving, or delamination of the fibers due to a transfixing artery.

HS is characterized by irregular, involuntary muscle contractions on one side of the face due to spasms of orbicularis oris and orbicularis oculi muscles, and is usually caused by a vascular compression of the VII cranial nerve. ST is a painful chronic movement disorder causing the neck to involuntarily turn to the side, upward and/or downward. HS is usually idiopathic but in a few number of cases, it can be due to a neurovascular conflict with the XI cranial nerve.

Magnetic resonance imaging MRI examination clearly visualizes the complex neurovascular anatomy within the cisternal spaces. Virtual MRI techniques are currently used to presurgically simulate microvascular decompression (MVD), giving a clear depiction of the contact between cranial nerves and offending vessels with an optimal correlation with intraoperative patterns.<sup>[4,10,11,30]</sup>

We describe an interesting case of a rare association of HS, ST and hemiparesis caused by two different neurovascular conflicts by the same vessel (AICA). We also focus on pre-surgical 3T MRI examination, integrated by bidimensional image fusion.

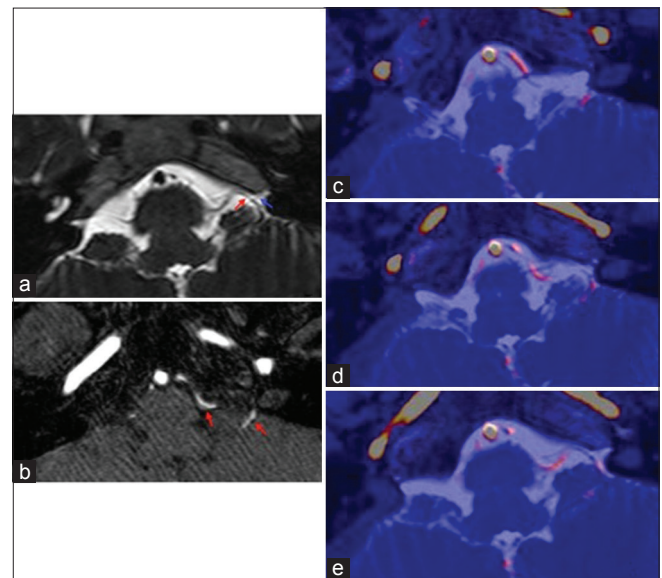
## CASE REPORT

A 36-year-old female with a 2-year history of left HS and ST was admitted to our department in October 2012. The spasm was initially confined to the superior orbicularis oculi muscle, but gradually affected the entire left side of the face. Spasm was presenting with a frequency of 5-10 episodes per day and was painful causing severe limitations in the normal daily life. She had been treated with botulinum toxin two times before admission but the effect was temporary. Preoperative neurological examination documented a mild left hemiparesis, involuntary contractions of perioral and periorbital muscles of the left face and torticollis caused by intermittent tonic spasm of the left neck muscles. We also examined the blink reflex with registration from orbicularis muscle of the left eye and square muscle of the left chin (depressor labii inferioris). We performed stimulation of the left supraorbital nerve and chin nerve, but no R1 response after stimulation of both nerves was recorded. Electrophysiological findings

conclusively proved the absence of ephaptic transmission at the level of the left VII cranial nerve.

Presurgical MRI examination was performed using a 3T superconductive scanner. MRI basal examination showed a dominant left AICA in contact with ipsilateral IX, X and XI cranial nerves. Bidimensional image fusion was subsequently performed and another anomalous contact between a small AICA distal branch and the left facial nerve was demonstrated. MRI data were transferred to an independent workstation in order to obtain a “3D fusion.” To visualize the neurovascular conflict between AICA and lower cranial nerves [Figure 1], the nervous structures were displayed in blue color and the arterial vessels in red. To visualize the neurovascular conflict between AICA distal branch and facial nerve [Figure 2], the nervous structures and distal arteries were displayed in red color and the main arterial vessels in yellow.

MVD was performed via a suboccipital retrosigmoid approach. The intraoperative findings showed a small distal branch of the left AICA transfixing the facial nerve in the intracisternal tract and a left dominant AICA marking the pons and, caudally, the lower cranial nerves, mainly the XI. After gentle retraction of the V cranial nerve, the VII nerve was dissected parallel to the axis at the site of arterial transfixing point to facilitate splitting up of the artery from the nerve. Microvascular decompression was performed with small pieces of autologous muscle at the point in which the transfixing artery penetrated the nerve, and between AICA, lower



**Figure 1: Anteroinferior cerebellar artery (AICA) – IX, X and XI c.n. at the intracisternal tract. (a) Axial 3D T2 drive image (b) axial 3D TOF image, and (c-e) 3D T2 axial bidimensional image fusion. (a) AICA (blue arrow) impacts IX, X and XI cranial nerve at the intracisternal tract (red arrow) (b) Only the tortuous AICA is visible (red arrows) (c and d) Simultaneous display of artery (red color) and nerves (blue color). (e) Contact between AICA (red color) and XI cranial nerve (blue color)**

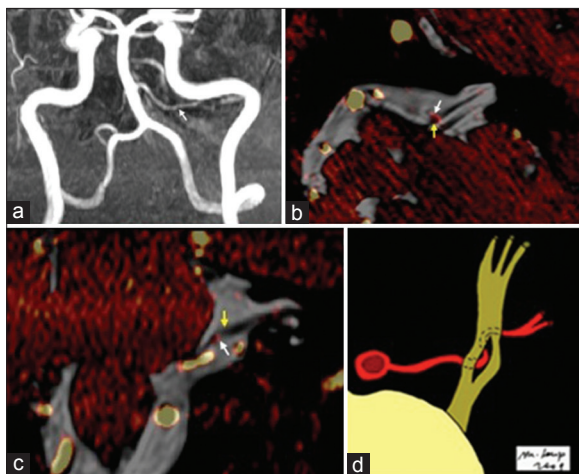
cranial nerve and brain stem, allowing the shifting of the vessel from the above-mentioned structures [Figure 3]. No intraoperative complications were observed. The postoperative course was uneventful with no signs of cranial nerves deficits. The HS and ST gradually improved 2 days after surgery. There was also a mild improvement of the left hemiparesis. At 4 months of follow-up the patient had completely recovered.

## DISCUSSION

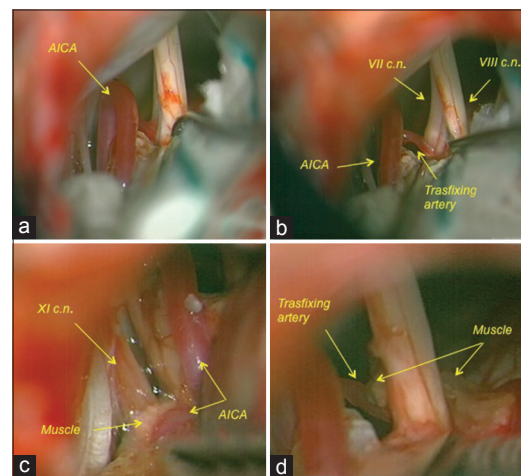
HS is caused by pulsatile vascular compression upon the facial nerve root exit zone. This 23 mm area, considered synonymous with the Obersteiner-Redlich zone, is a transition zone (TZ) between central and peripheral axonal myelination situated at the nerves detachment from the pons. More proximally the facial nerve is exposed on the pontine surface and emerges from the pontomedullary sulcus. Neurovascular compression is one of the main causes of HS, and the most common offending vessels are the AICA, the PICA, the vertebral artery or a large vein.<sup>[3,29]</sup> After MVD for HS, regardless of preoperative symptoms, lasting relief is observed in a high proportion of patients.<sup>[22,23]</sup> Spasmodic torticollis caused by a neurovascular conflict has also been reported in the literature.<sup>[1,7,13,16,17,26]</sup> In 1995, Jho and Jannetta reported successful surgical results using MVD in 20 patients affected by spasmodic torticollis and concluded that MVD for ST is a mini-invasive procedure with high probability of cure or significant improvement.<sup>[15]</sup> A recent paper by Shtange *et al.* described the surgical results in 40 patients with

spastic torticollis showing that unilateral microvascular decompression of the accessory nerve proved to be effective in homolateral type of torticollis.<sup>[24]</sup> Again, Nagata *et al.* showed two cases of spasmodic torticollis who underwent surgery according to their pathogenetic mechanisms.<sup>[18]</sup> Additionally, they reviewed pertinent literature and found 16 cases of ST who took advantage from microvascular decompression.

Complex neurovascular conflicts are rare disorders and very few cases have been reported in the literature.<sup>[5,6,15,19,21]</sup> Transfixing artery, as a cause of a neurovascular conflict, has been rarely reported in the literature and only for trigeminal and facial nerves. In 1991, Tashiro *et al.* reported three patients with TN caused by an offending artery transfixing the V cranial nerve.<sup>[27]</sup> In two cases, the authors performed a partial rhizotomy perpendicular to the axis of the nerve at the site of arterial transfixion. However, these two patients developed postoperative sensory facial deficits. In the third case, rhizotomy was performed longitudinal to the axis of the nerve, without causing any postoperative deficits.<sup>[27]</sup> In 1999, Furuse *et al.* reported a single case of transfixing artery penetrating the V nerve and causing TN. Surgery was performed through a classical retrosigmoid approach: the nerve was dissected parallel to the axis to facilitate transposition of the SCA. In addition to anchoring the distal portion of the SCA to the tentorium, a prosthesis was interposed between the proximal portion and the pons to ensure decompression.<sup>[8]</sup> Both studies described partial rhizotomy longitudinal to the axis of the nerve as the procedure of choice in the presence of a transfixing artery. In 1999, McLaughlin *et al.* presented a large series of 4400 patients



**Figure 2: AICA distal branch – VII cranial nerve (c.n.) conflict.** (a) Magnetic resonance angiogram (MRA) with maximum intensity projection (MIP), (b) 3D T2 axial bidimensional image fusion, and (c) 3D T2 coronal bidimensional image fusion. (a) Moderate scoliosis of the basilar trunk with a long cisternal route of a “dominant” left AICA (arrow) (b) AICA distal branch (white arrow) and VII c.n. at the intracisternal tract (yellow arrow) (c) The VII c.n. (yellow arrow) is slightly raised by the offending vessel (white arrow). (d) Schematic representation of the compression modality in case of “transfixing artery”



**Figure 3: Intraoperative findings** (a) A left dominant AICA turns in the cerebello-pontine cistern, conflicting with the lower cranial nerves (c.n.) and the anterior surface of the pons. A small branch of AICA penetrates the VII c.n., under the V c.n. (b) The V c.n. is gently pushed on a side to better evaluate the artery transfixing the VII c.n. (c) A small piece of autologous muscle is interposed between the proximal AICA, the XI c.n. and pons. (d) MVD for VII c.n.: A small piece of muscle is interposed around the transfixing artery in the area where the nerve is penetrated. No rhizotomy is performed



treated with MVD but no case of transfixing artery was reported.<sup>[17]</sup> In 2002, Sindou *et al.* published a study on the anatomical observation during surgery in 579 patients operated for TN.<sup>[25]</sup> A simple contact with the nerve was documented in 17.6%, a distortion in 49.2%, and a marked indentation in 33.2%, but no case of transfixing artery was observed. Only two reports of neurovascular conflict with the VII cranial nerve by a transfixing artery have so far been reported.<sup>[12,16]</sup> In 2007, Liu *et al.* presented their series of 25 patients operated for HS. Only one case presented with AICA transfixing the facial nerve. The authors performed a retromastoid craniectomy with facial nerve root scraping with partial rhizotomy.<sup>[16]</sup> In 2009, Grigorian *et al.* presented a series of 35 patients treated for HS and described only one case of AICA transfixing the facial nerve. No microvascular decompression was performed in this case because the penetration of the artery into the nerve did not allow a safe manipulation of the nerve itself.<sup>[11]</sup> In 2000, Alafaci *et al.* presented a case of ST caused by a conflict between AICA and the XI cranial nerve at its root entry zone.<sup>[1]</sup> The patient was a 72-year-old man with a 2-year history of spasmodic tilting of the neck to the right side caused by arrhythmic paroxysmal contractions of the right trapezius and sternocleidomastoideus muscle. MVD was successful in relieving the symptoms. The patient described in the present paper is the first case to be reported in the literature so far of an association between HS, ST and hemiparesis caused by two different neurovascular conflicts by the same vessel (AICA). A branch of the artery was transfixing the facial nerve, while a dominant vessel was compressing the lower cranial nerves and pons. Left upper and lower limb weakness was likely caused by compression of the left portion of the pons. The blood vessels that are running nearby the cranial nerves and brainstem can be elongated; curves and loops of the vessels may develop mostly due to the degenerative alterations of aging and these vessels can compress the surrounding neural elements. In our case, MRI and the intraoperative findings showed the left AICA transfixing the facial nerve in the intracisternal tract and a left dominant AICA impressing the surface of the pons, probably involving ipsilateral undecussated corticospinal fibers.<sup>[28]</sup>

MVD was performed in order to resolve all conflicts. MVD, in our opinion, prevents nerve's injury related to other procedures, such as rhizotomy that usually carries postoperative facial sensory impairment. The patient was studied with presurgical 3TMRI, integrated by bidimensional image fusion. We previously used this technique, with presurgical 1.5 T MRI, in a group of 32 patients who underwent MVD. This gave a clear picture of the contact between cranial nerves and the offending vessel. In our opinion, however, the small artery transfixing the VII cranial nerve would not have been detected in 1.5 T MRI examination.

## CONCLUSIONS

Simple microvascular decompression represents an excellent modality of treatment in cases of transfixing artery and, compared to other treatment modalities such as partial rhizotomy, it carries less risk of facial nerve injuries. MVD can also be used in order to resolve multiple neurovascular conflicts in the same patients. Presurgical 3T MRI with 3D fusion images provides an excellent picture of multiple neurovascular conflicts which well correlate with intraoperative findings.

## REFERENCES

- Alafaci C, Salpietro FM, Montemagno G, Grasso G, Tomasello F. Spasmodic torticollis due to neurovascular compression of the spinal accessory nerve by the anteroinferior cerebellar artery: Case report. *Neurosurgery* 2000;47:768-71.
- Borucki L, Szyfter W, Wróbel M, Sosnowski P. Neurovascular Conflicts. *Otolaryngol Pol* 2006;60:809-15.
- Campos-Benitez M, Kaufmann AM. Neurovascular compression findings in hemifacial spasm. *J Neurosurg* 2008;109:416-20.
- Chiaramente R, Bonfiglio M, D'Amore A, Chiaramente I. Developmental venous anomaly responsible for hemifacial spasm. *Neuroradiol J* 2013;26:201-7.
- De Ridder D, Ryu H, De Mulder G, Van de Heyning P, Verlooy J, Møller A. Frequency specific hearing improvement in microvascular decompression of the cochlear nerve. *Acta Neurochir (Wien)* 2005;147:495-501.
- Fioretti A, Peri G, Eibenstein A. Suppression of tinnitus in a patient with unilateral sudden hearing loss: A case report. *Case Rep Otolaryngol* 2012;2012:210707.
- Freckmann N, Hagenah R, Herrmann HD, Muller D. Treatment of neurogenic torticollis by microvascular lysis of the accessory nerve roots: Indication, technique, and first results. *Acta Neurochir (Wien)* 1981;59:167-75.
- Furuse M, Kuroda Y, Kobata H, Nagasawa S, Ohta T. Trigeminal neuralgia with the offending artery transfixing the trigeminal nerve: A case report. *No Shinkei Geka* 1999;27:22.
- Gardner WJ. Concerning the mechanism of trigeminal neuralgia and hemifacial spasm. *J Neurosurg* 1962;19:947-58.
- Granata F, Vinci SL, Longo M, Bernava G, Caffo M, Cutugno M, *et al.* Advanced virtual magnetic resonance imaging (MRI) techniques in neurovascular conflict: Bidimensional image fusion and virtual cisternography. *Radiol Med* 2013;118:1045-54.
- Grigorian luA, Sitnikov AR. Neurovascular interactions in hemifacial spasm. *Zh Vopr Neurokhir Im N N Burdenko* 2009;4:13-7.
- Kim HR, Rhee DJ, Kong DS, Park K. Prognostic factors of hemifacial spasm after microvascular decompression. *J Korean Neurosurg Soc* 2009;45:336-40.
- Kobata H, Kondo A, Kinuta Y, Iwasaki K, Nishioka T, Hasegawa K. Hemifacial spasm in childhood and adolescence. *Neurosurgery* 1995;36:710-4.
- Jia Y, Wenhua W, Quanbin Z. A single microvascular decompression surgery cures a patient with trigeminal neuralgia, hemifacial spasm, tinnitus, hypertension, and paroxysmal supraventricular tachycardia caused by the compression of a vertebral artery. *Neurol India* 2013;61:73-5.
- Jho HD, Jannetta PJ. Microvascular decompression for spasmodic torticollis. *Acta Neurochir* 1995;134:21-6.
- Liu B, Zhu X, Lu Q, Qin Y, Yuan H, He N, *et al.* Facial nerve root combing scraping for hemifacial spasm. *Lin Chung Er Bi Yan Hou Tou Jing Wai Ke Za Zhi* 2007;21:24-6.
- McLaughlin MR, Jannetta PJ, Clyde BL, Subach BR, Comey CH, Resnick DK. Microvascular decompression of cranial nerves: Lessons learned after 4400 operations. *J Neurosurg* 1999;90:1-8.
- Nagata K, Matsui T, Joshita H, Shigeno T, Asano T. Surgical treatment of spasmodic torticollis: Effectiveness of microvascular decompression. *No To Shinkei* 1989;41:97-102.
- Nakamura T, Osawa M, Uchiyama S, Iwata M. Arterial hypertension in

- patients with left primary hemifacial spasm is associated with neurovascular compression of the left rostral ventrolateral medulla. *Eur Neurol* 2007;57:150-5.
20. Naraghi R, Tanrikulu L, Troesch-Weber R, Bischoff B, Hecht M, Buchfelder M, et al. Classification of neurovascular compression in typical hemifacial spasm: Three dimensional visualization of the facial and the vestibulocochlear nerves. *J Neurosurg* 2007;107:1154-63.
  21. Perlmutter DH, Petraglia AL, Barbano R, Schwalb JM. Microvascular decompression in patient with atypical features of hemifacial spasm secondary to compression by a tortuous vertebrobasilar system: Case report. *Neurosurgery* 2010;66:E1212.
  22. Samii M, Günther T, Iaconetta G, Muehling M, Vorkapic P, Samii A. Microvascular decompression to treat hemifacial spasm: Long-term results for a consecutive series of 143 patients. *Neurosurgery* 2002;50:712-8.
  23. Sandel T, Eide PK. Long-term results of microvascular decompression for trigeminal neuralgia and hemifacial spasms according to preoperative symptomatology. *Acta Neurochir (Wien)* 2013;155:1681-92.
  24. Shtange LA, Ogleznev KlA, Grigorian luA, Roshchina NA. The results of microvascular decompression of the accessory nerve in patients with spastic torticollis. *Zh Vopr Neurokhir Im N N Burdenko* 1998;1:17-9.
  25. Sindou M, Howeidy T, Acevedo G. Anatomical observations during microvascular decompression for idiopathic trigeminal neuralgia (with correlations between topography of pain and site of the neurovascular conflict). Prospective study in a series of 579 patients. *Acta Neurochir (Wien)* 2002;144:1-12.
  26. Sun K, Lu Y, Hu G, Luo C, Hou L, Chen J, et al. Microvascular decompression of the accessory nerve for treatment of spasmodic torticollis: Early results in 12 cases. *Acta Neurochir (Wien)* 2009;151:1251-7.
  27. Tashiro H, Kondo A, Aoyama I, Nin K, Shimotake K, Nishioka, et al. Trigeminal neuralgia caused by compression from arteries transfixing the nerve. Report of three cases. *J Neurosurg* 1991;75:783-6.
  28. Zaorsky NG, Luo JJ. A case of classic Raymond syndrome. *Case Rep Neurol Med* 2012;2012:583123.
  29. Zhang QB, Wang WH, Chen XZ, Yin J. Hemifacial spasm developing after the adhesion of the facial nerve and vertebral artery. *CNS Neutosci Ther* 2013;19:539-40.
  30. Zhong J, Li ST, Zhu J, Guan HX, Zhou QM, Jiao W, et al. A clinical analysis on microvascular decompression surgery in a series of 3000 cases. *Clin Neurol Neurosurg* 2012;114:846-51.