

## Peculiar and Unusual Drowning in Waste Oil from Motor Vehicles: Case Report

Elvira Ventura Spagnolo<sup>1\*</sup>, Cristina Mondello<sup>2</sup>, Luigi Cardia<sup>3</sup> and Giulio Cardia<sup>2</sup>

<sup>1</sup>Department for Health Promotion and Mother-Child Care, University of Palermo, Palermo, Italy

<sup>2</sup>Department of Biomedical Science and of Morphological and Functional Images, University of Messina, Messina ME, Italy

<sup>3</sup>Department of Neurosciences, University of Messina, Messina ME, Italy

\*Corresponding author: Elvira Ventura Spagnolo, Legal Medicine Section, Department for Health Promotion and Mother-Child Care University of Palermo, Via del Vespro 129, Plaermo, Sicily 90127, Italy; Tel: 00393496465532; E-mail: [elvira.ventura@unipa.it](mailto:elvira.ventura@unipa.it)

Received date: September 05, 2016; Accepted date: September 27, 2016; Published date: September 30, 2016

Copyright: © 2016 Ventura-Spagnolo et al. This is an open access article distributed under the terms of the Creative Commons Attribution License, which permits unrestricted use, distribution, and reproduction in any medium, provided the original author and source are credited.

### Abstract

Drowning is one of the most frequent causes of accidental or suicidal death, and more rarely it is associated with a homicide. Cases of drowning in water or in the sea are common. The authors report an unusual and peculiar case of drowning, that of a woman who accidentally fell inside a collection tank of waste oil of motor vehicles.

**Keywords:** Drowning; Asphyxia; Accidental death; Waste motor oil

### Introduction

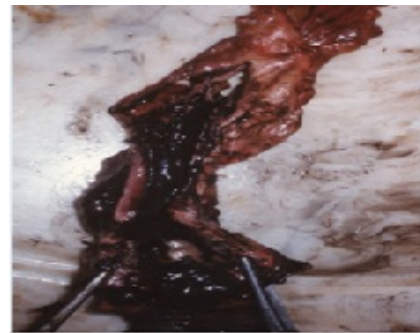In Italy 800 drowning cases per year have been appraised, 45% of which are fatal [1]. Generally, drowning means a form of mechanical asphyxia subsequent to the occlusion of the respiratory tract by a fluid. Usually water represents the most common means by which drowning and asphyxia occurs, in these cases the body can be found totally or partially submerged.

If we consider alternative fluids to the water, it is more common that their penetration in the respiratory tract is subsequent to inhalation, which is followed by lung pathologies more than by a real asphyctic syndrome [2-8]. Other fluid that in rare occurrences have been mentioned in the literature as a means of drowning asphyxia are represented by wax, paraffin, beer, bitumen, and gas oil [9-14]. Therefore, due to its uniqueness, the authors present a case of drowning in waste oil from motor vehicles.

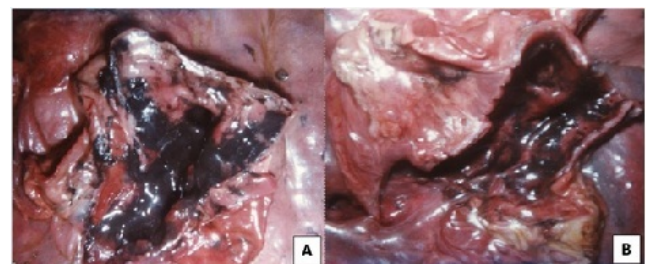
### Case Report

The case concerns a 64-year-old woman, who had been missing for six days, and then was found dead in a collection tank for motor oil waste. The judiciary ordered the implementation of the autopsy aimed at clarifying the cause of death and if it was due to a homicide, a suicide or an accident.

The external examination showed an advanced stage of decomposition of the body, at evident gas stage. The facial traits were altered due to the swelling of integuments caused by putrefaction gases. The putrefaction epidermolysis was widespread. On the head and trunk there was some stratified blackish oily fluid. No traumatic lesion was detected. The body dissection showed the presence of the blackish oily fluid inside the mouth, in the upper digestive tract to the stomach and in the respiratory tree (Figure 1). In particular the lungs were solids and heavy, even if they were found expanded and emphysematous; the dissection revealed the presence of the blackish fluid inside the main bronchi and into their intraparenchymal ramifications which in some cases were completely obstructed (Figure 2).



**Figure 1:** Blackish oily fluid on the mucosa of the esophago and trachea.



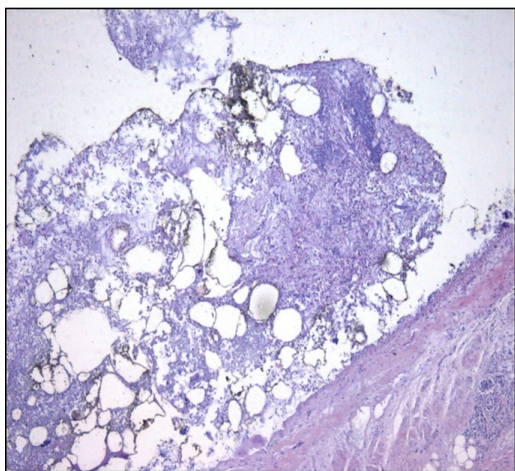
**Figure 2:** (A) Blackish fluid in pulmonary hilum and (B) completely obstructed intraparenchymal ramifications.

The histological examination showed some structural changes on the laryngeal and tracheal wall, in which the mucosa was found completely without epithelium and its tunic was covered by a blackish amorphous granular substance.

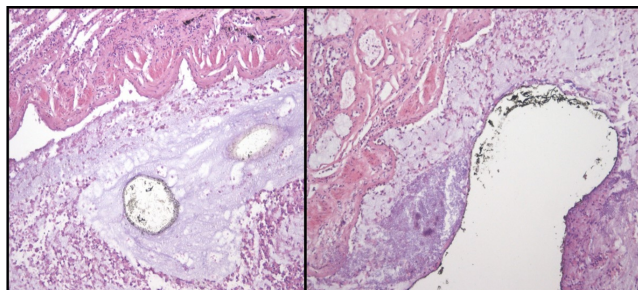
In the lung sections there were some areas of emphysema, visibly empty and alternated with other areas covered by the blackish matter (Figure 3). The lumen of many bronchus ramifications showed blackish

substance on the mucosa (Figure 4) while others were totally obstructed.

Another noteworthy aspect was given by the evidence that came out by the kidneys examination that showed a widespread fibrosis, several cystic formations, a marked thickening of capillary loops, glomerulus transformed into connective and tubular epithelium reduced to an amorphous granular substance without nuclei.



**Figure 3:** Emphysema areas with blackish substance on the alveolar mucosa (EE 1.5X).



**Figure 4:** Blackish granular substance stratified on the bronchus mucosa (EE 10X and 20X).

## Discussion

The results of the autopsy and of the histological examination enabled us to ascribe the death due to acute asphyxia caused by drowning in mineral oil waste used for motor vehicles contained in a collecting well. The drowning fluid, in fact, has been found up to the smallest ramifications of the respiratory tree and it has been partially swallowed. This coincides with what usually happens during drowning in water and confirms that the woman at that moment was alive.

The causes that brought about the drowning could be attributed to an accidental event, since there are no forensic elements allowing us to formulate the hypothesis of suicide or homicide.

In fact, the external examination of the body did not show any sign of traumatism referable to the possible intervention of other subjects; and the woman, according to what the relatives said, had never manifested suicidal thoughts nor suffered from psychiatric pathologies.

Furthermore, considering the severe grade of nephrosclerosis with cystic transformation of the kidney parenchyma and the severe nephrotic component that appeared during the histological examination, we have considered as a reliable hypothesis to be evidence of kidney failure at uremic stage with possible clinical signs such as the state of mental confusion. This could have facilitated the fall of the woman in the well and the subsequent drowning. This hypothesis has been supported by her relatives' statements who said that the woman, in that period, was submitted to dialysis three times a week.

The analysed case represents the unique of drowning in waste motor oil and the authors reported it to document the macroscopic and microscopic characteristic evidences.

## References

1. Istituto Superiore di Sanità (2011) Drownings in Italy: Epidemiology and strategies prevention.
2. Guerin CK, Owen RA, Keys TF (1983) Aspiration of barnyardmanure. *Minn Med* 66: 359-360.
3. Hussain IR, Edenborough FP, Wilson RSE, Stableforth DE (1996) Severe lipoid pneumonia following attempted suicide by mineral oil immersion. *Thorax* 51: 652-653.
4. Indumathi CK, Vikram KS, Paul P, Lewin S (2012) Severe lipoid pneumonia following aspiration of machine oil: successful treatment with steroids. *Indian J Chest Dis Allied Sci* 54: 197-199.
5. Yu MC, Lin JL, Wu CT, Hsia SH, Lee F (2007) Multiple organ failure following lamp oil aspiration. *Clin Toxicol (Phila)* 45: 304-306.
6. Khan AJ, Akhtar RP, Faruqi ZS (2006) Turpentine oil inhalation leading to lung necrosis and empyema in a toddler. *Pediatr Emerg Care* 22: 355-357.
7. Annobil SH, Tahir ME, Kameswaran M, Morad N (1997) Olive oil aspiration pneumonia (lipoid) in children. *Trop Med Int Health* 2: 383-388.
8. Rodriguez MA, Martinez MC, Martinez-Ruiz D, Paz Giménez M, Menéndez M, et al. (1991) Death following crude oil aspiration. *J Forensic Sci* 36: 1240-1245.
9. Capovilla M, Durigon M, de la Grandmaison GL (2007) An original cause of drowning in an industrial environment. *Am J Forensic Med Pathol* 28: 91-93.
10. Mullan TM, Vey EL (2011) Unique drowning in an atypical medium: paraffinwax in the setting of a motor vehicle crash-case report and literature survey. *Forensic Sci Med Pathol* 7: 198-208.
11. James WR (1966) A case of drowning in a vat of beer and two other short case reports. *Med Sci Law* 6: 164-165.
12. Singh B (1982) A case report of 'drowning' in a bitumen tank. *Med Sci Law* 22: 51-52.
13. Apic R, Gaspavec Z, Weber KI (1976) Drowning in gasoline. *Forensic Sci Int* 7: 181.
14. Talwar V, Sood N, Verma PK (2009) Drowning in concentrated syrup. *Indian Pediatr.* 46: 352-353.