

## Non-Occlusive Mesenteric Ischemia (NOMI) in Parkinson's disease: case report

G. SALAMONE, C. RASPANTI, L. LICARI, N. FALCO,  
G. ROTOLO, G. AUGELLO, G. MELFA, G. GULOTTA

**SUMMARY: Non-Occlusive Mesenteric Ischemia (NOMI) in Parkinson's disease: case report.**

G. SALAMONE, C. RASPANTI, L. LICARI, N. FALCO, G. ROTOLO, G. AUGELLO, G. MELFA, G. GULOTTA

*Non-occlusive mesenteric ischemia (NOMI) is a severe pathological condition characterized by signs and symptoms of bowel obstruction, intestinal necrosis resulting from acute and/or chronic inadequate blood perfusion, in the absence of an organic vascular obstruction detectable by imaging techniques.*

*A 64 years old man case with a history of Parkinson's disease in high-functioning levodopa treatment is presented. Clinical and radiological signs of intestinal obstruction were observed. He underwent sur-*

*gical operation with total colectomy and terminal ileostomy for generalized secondary peritonitis due to perforation of sigmoid colon. Ischemic pancolitis was first suspected. In third post-operative day a contrast-enhanced CT scan was performed in the evidence of fever and sub-occlusive symptoms. It was found absence of reliable evidence of vascular changes; superior mesenteric artery and vein patency is maintained. A NOMI was then diagnosed.*

*NOMI represents about 0.04% of mesenteric artery diseases. It is correlated with a poor prognosis with a mortality estimated of 70-90%. Parkinson's disease, considering neurodegenerative alterations that characterize it, can be considered as a predisposing factor. The combined treatment with high doses of levodopa and vasodilators, such as PGE (Prostaglandin E), can contribute to an improvement in prognosis.*

**KEY WORDS:** Non-occlusive mesenteric ischemia (NOMI) - Bowel obstruction - Intestinal necrosis - Vasodilators - Parkinson's disease - Total colectomy.

### Introduction

Non-occlusive mesenteric ischemia (NOMI) is a severe pathological condition characterized by intestinal necrosis resulting from acute and/or chronic inadequate blood perfusion of mesenteric arteries or veins, in the absence of an organic obstruction detectable by imaging techniques. It represents an abdominal emergency accounting for approximately 2% of gastrointestinal illnesses (1-6), and 20-30% of all cases of acute mesenteric ischemia. Generally it affects patients over 50 years of age suffering of myocardial infarction, congestive heart failure, aortic insufficiency and renal or hepatic diseases (7, 8). The phenomenon of ischemia-reperfusion injury is responsible for multi-organ insufficiency sometimes ag-

gravated by secondary peritonitis due to intestinal perforation.

NOMI is about five times less common than acute bowel infarction caused by vascular occlusion of the superior or inferior mesenteric artery (9-15). Main site of NOMI is the right-sided colon (1). Hypoperfusion of peripheral mesenteric arteries can be caused by different mechanisms. Pharmacological interactions, in patients suffering of chronic diseases requiring a variety of drugs, are co-factors of mesenteric vasoconstriction (2).

Atherosclerosis of mesenteric vessels is a common condition in patients with NOMI even though vascular occlusion is not the real cause of bowel infarction (9).

Risk factors include low cardiac output state, sepsis, use of vasospastic drugs, digitalis, haemodialysis, major heart or abdominal surgery, and any critical illnesses; it is frequently associated with pancreatitis due to proximity of superior mesenteric artery and celiac plexus to the pancreas. Early symptoms are frequently absent so that acute abdominal pain may be the only presenting symptom of mesenteric ischemia (16).

Physical signs, such as abdominal distension, abdo-

Unit of General and Emergency Surgery, "Policlinico P. Giaccone",  
University of Palermo, Palermo, Italy

Corresponding Author: Cristina Raspanti, e-mail: cristinaraspanti@yahoo.it

© Copyright 2017, CIC Edizioni Internazionali, Roma

minimal tenderness and muscular defense, hypotension, fever, decreased bowel sounds, nausea, sickness, diarrhea, and anorexia, are observed with decreasing frequency (10). Early diagnosis of NOMI remains a challenge as the symptoms are often non-specific. If acute mesenteric ischemia is suspected, the diagnostic gold standard method is CT scan with intravascular contrast enhancement due to the possibility of detecting alterations of the colonic wall (20). Unlike chronic mesenteric ischemia, the treatment of acute mesenteric ischemia remains largely surgical. This is due to the emergent need for revascularization combined with an assessment of bowel transit (21). An alternative approach might consist in injecting the patients with autologous endothelial progenitor cells, to accelerate tissue revascularization and prevent a surgical approach (22, 23). Surgical intervention could be required if the ischemic damage progresses. In the intermediate phase the bowel wall of both small and large bowel appears thinned due to inefficacy to collateral circulation. All loops are dilated, only gas filled and the transition from spastic ileus to hypotonic ileus is detected. The mesentery appears pale and there is also lack of enhancement of the intestinal wall (27, 28).

If the blood pressure is restored, the bowel is re-perfused and the findings depend on the severity of the ischemic damage. The oedema of the wall causes low attenuation of enhanced CT and the typical "target sign". Patients who need urgent surgery for acute right-sided colonic ischemia without feasible vascular intervention have a very high short and long-term mortality risk probably due to their multiple and severe underlying diseases (29, 30).

## Case report

Man, 64 years old, a history of Parkinson's disease in high-functioning levodopa treatment. We found clinical signs of intestinal obstruction (abdominal pain, nausea, vomiting, fever, decreased excretion of urine) (38); CT scan without contrast was performed in "suspected bowel obstruction". The CT was performed before the surgical operation. The examination showed: presence of loop package with conglomerate aspect [medium-distal ileum] in the left iliac fossa, associated with severe bowel distension upstream with showy fluid levels and severe gastrectasia (11) (Figures 1, 2, 3); 'Pneumatosis Intestinalis' (PI) is a radiologic sign which is represented by the presence of gas in the bowel wall, and could indicate mesenteric ischemia (22, 33, 34).

Surgery was performed as a consequence of the diagnosis of mesenteric ischemia; at the opening of the peritoneum abundant corpusculated ascites was found, the loops of the small intestine were dilated (from Treitz to the ileocecal valve); necrotic phenomena of the colon and rectum were also found. We decided to perform sigmoidectomy resecting the large bowel segment by means of a double charge of GIA-75 and terminal colostomy.

When we opened the stoma, the mucosa looked totally necrotic; so we decided to make an intraoperative colonoscopy that, despite the absence of patient's bowel preparation, showed necrosis of entire colonic mucosa. So we decided to make a total colectomy and packaging terminal ileostomy on the left side (31, 32, 39).

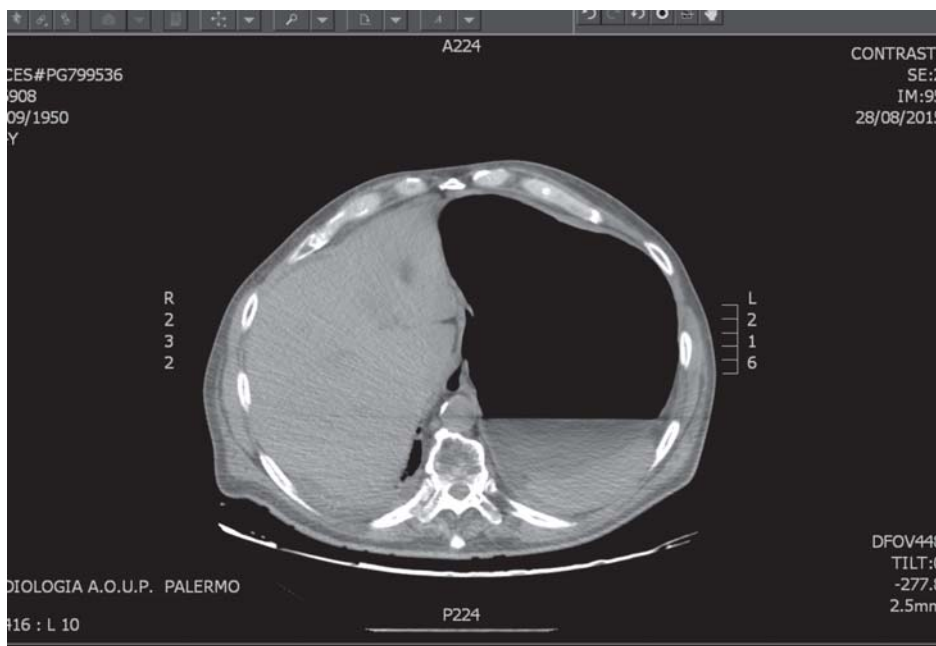


Figure 1 - Bowel obstruction.

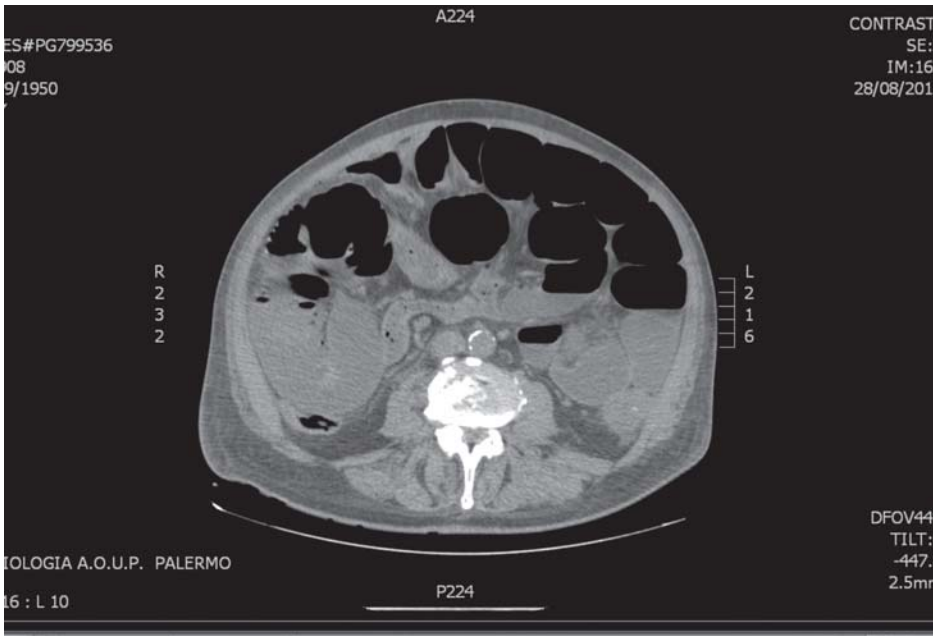

Figure 2 - Bowel obstruction.

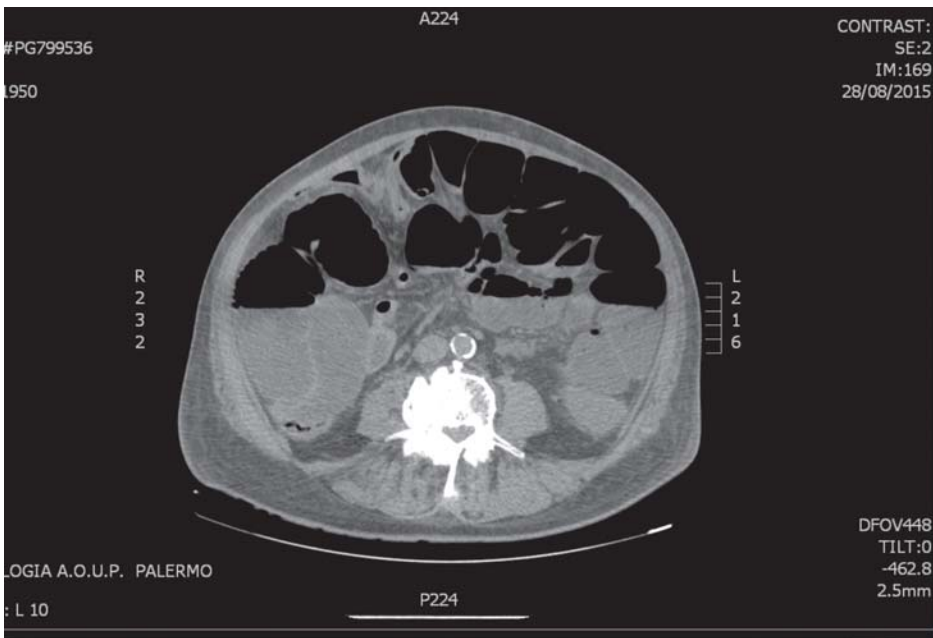


Figure 3 - Bowel obstruction.

In third post-operative day: onset of fever, important abdominal distension, decreased excretion of urine; the contrast-enhanced CT scan showed severe gastrectasia with overdistension predominantly gaseous of the small intestine with multiple air-fluid levels in the absence of reliable evidence of vascular changes; superior mesenteric artery and vein patency. A NOMI was then diagnosed. Thus we decided on beginning drug treatment that combined PGE, vasodilators with the aim of reducing the va-

sospasm and restore circulation, and levodopa at high dosages.

In tenth post-operative day we saw: the feverish framework resolution, ostomy pervious to gas and feces, urine output, resolution of pain symptoms in the abdomen, but permanence of gastrectasia; therapy with prostaglandins was continued until the administration of antibiotics was suspended. So the patient was discharged.

## Discussion

Parkinson's disease is characterized by degeneration of *substantia nigra* cells that secrete dopamine, frequently associated with gastrointestinal symptoms, mostly represented by constipation and defecatory dysfunctions. Central nigrostriatal dopaminergic denervation is associated with an impaired excitatory neurotransmission characterized by a loss of myenteric neuronal Choline Acetyl Transferase (ChAT) positivity and decrease in acetylcholine release, resulting in a dysregulated smooth muscle motor activity, which likely contributes to the concomitant decrease in colonic transit rate (18-20).

Follow-up of NOMI provided: control of hemoglobin prior to ten days, then each month, then every six months unless complications. Abdominal computed tomographic (CT) angiography, without oral contrast, is useful as a screening examination for patients with acute abdominal pain and suspicion for acute mesenteric ischemia. CT angiography has high degree of accuracy for diagnosing acute mesenteric ischemia, and it is useful in excluding other causes of acute abdominal pain, and other etiologies of acute mesenteric ischemia. For patients with risk factors, and clinical features that suggest non occlusive mesenteric ischemia rather than another etiology for acute mesenteric ischemia, we suggest selective arteriography of the mesenteric circulation over other vascular imaging modalities (37). Digital subtraction arteriography has the advantage of offering a therapeutic option for these patients. Initial management of non occlusive mesenteric ischemia includes aggressive hemodynamic monitoring and support, correction of metabolic acidosis, initiation of broad spectrum antibiotics, and placement of a nasogastric tube for gastric decompression (24-26, 35, 36).

The peculiarity of this case report is the finding of an acute abdomen closely related to a neurodegenerative disease, which in the literature did not reveal any kind of correlation. Also we suspect that our patient had a NOMI born only in the third post-operative day. In urgent cases, the clinical picture was that of a suspected intestinal perforation of probable ischemic bowel.

In fact, when NOMI is clinically suspected, immediate selective angiography is the gold standard technique to verify the diagnosis (7). If NOMI is confirmed, current treatment recommendations include a conservative approach using local infusion of vasodilator agents (e.g. papaverine, tolazolin, prostaglandin E1) angiographically placed via catheter in the superior or inferior mesenteric arteries (7, 9, 11, 14).

In early non occlusive mesenteric ischemia without mucosal necrosis surgical therapy is not recommended; persistent prolonged vasoconstriction plays an important role in the development and maintenance of NOMI

ischemia complicating mesenteric re-vascularization and requiring surgery.

Although cardiovascular failure is a clear indication for inotropic and vasopressor therapy, vasopressors have been repeatedly shown to be involved in the pathogenesis of NOMI (6).

The exact mechanism leading to the persistence of vasospasm is unknown, but it responds to intra-arterial vasodilator infusion.

In literature, therefore, even during "mesenteric reperfusion syndrome", vasopressor drugs are considered to be relatively contraindicated. Simultaneous local infusion of the strong vasodilator prostaglandin E1 into the superior mesenteric artery might have buffered any potential vasoconstrictive effect of arginine vasopressin [AVP] or norepinephrine on the mesenteric vascular system. On the other hand, low dosages of AVP have been shown to induce mesenteric vasodilation, which could contribute to restitution of intestinal perfusion in our patient. Colloid fluid resuscitation and low phenylephrine dosages (0.48 µg/kg body weight bw/min) are often required to stabilize cardiovascular function. In order to treat gastrointestinal bleeding, AVP has been used at dosages that were 5–20 times higher than those administered in advanced vasodilatory shock. Thus, many authors have cautioned against the use of AVP, possible cause of fear of gastrointestinal hypoperfusion and subsequent ischemia (1, 2).

Moreover, in patients with mesenteric ischemia, including NOMI, AVP is considered strictly contraindicated because of a potential exacerbation of mesenteric ischemia.

Mituyoshi et al. reported that continuous intravenous PGE1 administration resolved the spasm and narrowing of the superior mesenteric artery in NOMI patients; the combination of local prostaglandin E1 with systemic AVP/norepinephrine infusion induced mesenteric vasodilation and allowed arterial lactate levels to normalize and liver enzymes to improve significantly (17).

## Conclusions

The NOMI represents about 0.04% of the forms of mesenteric artery disease found. It is correlated with a poor prognosis with a year mortality rate estimated of 70-90%. The coexistence of Parkinson's disease, for neurodegenerative alteration by which it is characterized, can be considered a predisposing factor. The treatment of acute mesenteric ischemia remains largely surgical; subsequently the combined treatment with high doses of levodopa and vasodilators, such as PGE, can contribute to an improvement of prognosis.



## References

1. Stöckmann H, Roblick UJ, Kluge N, Kunze U, Schimmelpenninck H, Kujath P, Müller G, Bruch H-P. Diagnostik und Therapie der nichtokklusiven mesenterialen Ischämie [NOMI]. *Zentralbl Chir.* 2000;125:144-151.
2. Mazzei MA, Mazzei FG, Marrelli D, Imbriaco G, Guerrini S, Vindigni C, Civitelli S, Roviello F, Grassi R, Volterrani L. Computed tomographic evaluation of mesentery: diagnostic value in acute mesenteric ischemia. *J Comput Assist Tomogr.* 2012;36(1): 1-7.
3. Cocorullo G, Mirabella A, Falco N, Fontana T, Tutino R, Licari L, Salamone G, Scerrino G, Gulotta G. An investigation of bedside laparoscopy in the ICU for cases of non-occlusive mesenteric ischemia. *World J Emerg Surg.* 2017 Jan 18;12:4. doi: 10.1186/s13017-017-0118-5. eCollection 2017.
4. Hirner A, Häring R, Hofmeister M. Acute Mesenteric vascular occlusions. *Chirurg.* 1987; 58(9):577-84.
5. Woodhams R, Nishimaki H, Fujii K, Kakita S, Hayakawa K. Usefulness of multidetector-row CT [MDCT] for the diagnosis of non-occlusive mesenteric ischemia [NOMI]: assessment of morphology and diameter of the superior mesenteric artery [SMA] on multi-planar reconstructed [MPR] images. *European journal of radiology.* 2010;76[1]:96-102.
6. Masolino A, Scerrino G, Gullo R, Genova C, Melfa GI, Raspanti C, Fontana T, Falco N, Porrello C, Gulotta G. Large retroperitoneal abscess extended to the inferior right limb secondary to a perforated ileal Crohn's disease: the importance of the multidisciplinary approach. *G Chir* 2016;37(1): 37-41.
7. Acosta S, Ogren M, Sternby NH, Bergqvist D, Björck MJ. Fatal nonocclusive mesenteric ischaemia: population-based incidence and risk factors. *Intern Med.* 2006;259:305-13.
8. Trompeter M, Brazda T, Remy CT, Vestring T, Reimer P. Non-occlusive mesenteric ischemia: etiology, diagnosis, and interventional therapy. *Eur Radiol.* 2002;12:1179-87.
9. Fingerhut A, Uranus S, Ettorre GM, Felli E, Colasanti M, Scerrino G, Melfa GI, Raspanti C, Gulotta G, Meyer A, Oberhofer M, Schmoeckel M, Weltert LP, Vignolini G, Salvi M, Masieri L, Vittori G, Siena G, Minervini A, Serni S, Carini M. European Initial Hands-On Experience with HEMOPATCH, a Novel Sealing Hemostatic Patch: Application in General, Gastrointestinal, Biliopancreatic, Cardiac, and Urologic Surgery. *Surg Technol Int.* 2014;25:29-35.
10. Howard TJ, Plaskon LA, Wiebke EA, Wilcox MG, Madura JA. Nonocclusive mesenteric ischemia remains a diagnostic dilemma. *Am J Surg.* 1996;171:405-8.
11. Amato G, Romano G, Salamone G, Agrusa A, Saladino VA, Silvestri F, Bussani R. Damage to the vascular structures in inguinal hernia specimens. *Hernia.* 2012 Feb;16[1]:63-7. doi: 10.1007/s10029-011-0847-4. Epub 2011 Jul 8.
12. Kniemeyer HW. Mesenterialinfarkt: wann braucht man den Gefäßchirurgen? *Zentralbl Chir.* 1998;123:1411-1417.
13. Bruch H-P, Habscheid W, Schindler G, Schiedeck THK. Nichtocclusive ischämische Enteropathie. Diagnose, Differentialdiagnose und Therapie. *Langenbecks Arch Chir.* 1990;(Suppl 2):317-321.
14. Bruch H-P, Broll R, Wünsch P, Schindler G. Zum Problem der nicht-okklusiven ischämischen Enteropathie [NOD]: Diagnose, Therapie und Prognose. *Chirurg.* 1989;60:419-425.
15. Hirner A, Häring R, Hofmeister M. Akute Mesenterialgefäßverschlüsse. *Chirurg.* 1987;58:577-584.
16. Cocorullo G, Tutino R, Falco N, Licari L, Orlando G, Fontana T, Raspanti C, Salamone G, Scerrino G, Gallo G, Trompetto M, Gulotta G. The non-surgical management for hemorrhoidal disease. A systematic review. *G Chir.* 2017 Jan-Feb;38(1):5-14.
17. Yukaya T, Saeki H, Taketani K, Ando K, Ida S, Kimura Y, Oki E, Yasuda M, Morita M, Shirabe K, Maehara Y. Clinical outcomes and prognostic factors after surgery for non-occlusive mesenteric ischemia: a multicenter study. *J Gastrointest Surg.* 2014 Sep;18(9):1642-7.
18. Fornai M, Pellegrini C, Antonioli L, Segnani C, Ippolito C, Barocelli E, Ballabeni V, Vegezzi G, Al Harraq Z, Blandini F, Levandis G, Cerri S, Blandizzi C, Bernardini N, Colucci R. Enteric Dysfunctions in Experimental Parkinson's Disease: Alterations of Excitatory Cholinergic Neurotransmission Regulating Colonic Motility in Rats. *J Pharmacol Exp Ther.* 2016 Feb;356[2]:233-43.
19. Bonventre S, Inviati A, Di Paola V, Morreale P, Di Giovanni S, Di Carlo P, Schifano D, Frazzetta G, Gulotta G, Scerrino G. Evaluating the efficacy of current treatments for reducing postoperative ileus: a randomized clinical trial in a single center. *Minerva Chir.* 2014 Feb;69(1):47-55.
20. Tanaka A, Ito Y, Sugiura Y, Sezaki R. Non-occlusive mesenteric ischemia in a hemodialysis patient. *Intern Med.* 2011;50(5):523.
21. Reginelli A, Iacobellis F, Berritto D, Gagliardi G, Di Grezia G, Rossi M, Fonio P, Grassi R. Mesenteric ischemia: the importance of differential diagnosis for the surgeon. From 26th National Congress of the Italian Society of Geriatric Surgery, Naples, Italy. 19-22 June 2013.
22. Dhoble A, Patel K, Khasnis A. Non-occlusive mesenteric ischemia leading to 'pneumatosis intestinalis': a series of unfortunate hemodynamic events. *Cases J.* 2008;1[1]:60.
23. Käser SA, Müller TC, Guggemos A, Nitsche U, Späth C, Maurer CA, Janssen KP, Kleeff J, Friess H, Wilhelm D, Bader FG. Outcome after surgery for acute right-sided colonic ischemia without feasible vascular intervention: a single center experience of 58 patients over 6 years. *BMC Surg.* 2015;15:31.
24. Sachs SM, Morton JH, Schwartz SI. Acute mesenteric ischemia. *Surgery.* 1982;92(4):646-53.
25. Mamode N, Pickford I, Leiber P. Failure to improve outcome in acute mesenteric ischaemia: seven-year review. *Eur J Surg.* 1999;165[3]:203-8.
26. Loffroy R, Steinmetz E, Guiu B, Molin V, Kretz B, Gagnaire A, et al. Role for endovascular therapy in chronic mesenteric ischemia. *Can J Gastroenterol.* 2009;23(5):365-73.
27. Bonventre S, Inviati A, Di Paola V, Morreale P, Di Giovanni S, Di Carlo P, Schifano D, Frazzetta G, Gulotta G, Scerrino G. Evaluating the efficacy of current treatments for reducing postoperative ileus: a randomized clinical trial in a single center. *Minerva Chir.* 2014;69(1): 47-55.
28. Salamone G, Licari L, Agrusa A, Romano G, Cocorullo G, Falco N, Tutino R, Gulotta G. Usefulness of ileostomy defunctioning stoma after anterior resection of rectum on prevention of anastomotic leakage A retrospective analysis. *Ann Ital Chir.* 2016;87:155-60.
29. Paladino NC, Inviati A, Di Paola V, Busuito G, Amodio E, Bonventre S, Scerrino G. Predictive factors of mortality in patients with acute mesenteric ischemia. A retrospective study. *Ann Ital*

- Chir. 2014 May-Jun;85(3):265-70.
30. Salamone G, Atzeni J, Agrusa A, Gulotta G. A rare case of abdominal cocoon. *Ann Ital Chir.* 2013;84(ePub). pii: S2239253X13021531.
  31. Cocorullo G, Falco N, Tutino R, Fontana T, Scerrino G, Salamone G, Licari L, Gulotta G. Open versus laparoscopic approach in the treatment of abdominal emergencies in elderly population. *G Chir.* 2016 May-Jun;37(3):108-112.
  32. Cappello M, Randazzo C, Peralta S, Cocorullo G. Subcutaneous emphysema, pneumomediastinum and pneumoperitoneum after diagnostic colonoscopy for ulcerative colitis: a rare but possible complication in patients with multiple risk factors. *Int J Colorectal Dis.* 2011 Mar;26(3):393-4.
  33. Sartelli M, Abu-Zidan FM, Catena F, Griffiths EA, Di Saverio S, Coimbra R, Ordoñez CA, Leppaniemi A, Fraga GP, Cocolini F, Agresta F, Abbas A, Abdel Kader S, Agboola J, Amhed A, Ajibade A, Akkucuk S, Alharthi B, Anyfantakis D, Augustin G, Baiocchi G, Bala M, Baraket O, Bayrak S, Bellanova G, Beltrán MA, Bini R, Boal M, Borodach AV, Bouliaris K, Branger F, Brunelli D, Catani M, Che Jusoh A, Chichom-Mefire A, Cocorullo G, Colak E, Costa D, Costa S, Cui Y, Curca GL, Curry T, Das K, Delibegovic S, Demetrashvili Z, Di Carlo I, Drozdova N, El Zalabany T, Enani MA, Faro M, Gachabayov M, Giménez Maurer T, Gkiokas G, Gomes CA, Gonsaga RA, Guercioni G, Guner A, Gupta S, Gutierrez S, Hutan M, Ioannidis O, Isik A, Izawa Y, Jain SA, Jokubauskas M, Karamarkovic A, Kauhanen S, Kaushik R, Kenig J, Khokha V, Kim JI, Kong V, Koshy R, Krasniqi A, Kshirsagar A, Kuliesius Z, Lasithiotakis K, Leão P, Lee JG, Leon M, Lizarazu Pérez A, Lohsiriwat V, López-Tomassetti Fernandez E, Lostoridis E, Mn R, Major P, Marinis A, Marrelli D, Martinez-Perez A, Marwah S, McFarlane M, Melo RB, Mesina C, Michalopoulos N, Moldovanu R, Mouaqit O, Munyika A, Negoï I, Nikolopoulos I, Nita GE, Olaoye I, Omari A, Ossa PR, Ozkan Z, Padmakumar R, Pata F, Pereira Junior GA, Pereira J, Pintar T, Pougouras K, Prabhu V, Rausei S, Rems M, Rios-Cruz D, Sakakushev B, Sánchez de Molina ML, Seretis C, Shelat V, Simões RL, Sinibaldi G, Skrovina M, Smirnov D, Spyropoulos C, Tepp J, Tezcaner T, Tolonen M, Torba M, Ulrych J, Uzunoglu MY, van Dellen D, van Ramshorst GH, Vasquez G, Venara A, Vereczkei A, Vettoretto N, Vlad N, Yadav SK, Yilmaz TU, Yuan KC, Zachariah SK, Zida M, Zilinskas J, Ansaloni L. Global validation of the WSES Sepsis Severity Score for patients with complicated intra-abdominal infections: a prospective multicentre study [WISS Study]. *World J Emerg Surg.* 2015 Dec 16;10:61.
  34. Agresta F, Campanile FC, Podda M, Cillara N, Pernazza G, Giaccaglia V, Ciccioritti L, Ioia G, Mandalà S, La Barbera C, Birindelli A, Sartelli M, Di Saverio S; Joined Italian Surgical Societies Working Group. Current status of laparoscopy for acute abdomen in Italy: a critical appraisal of 2012 clinical guidelines from two consecutive nationwide surveys with analysis of 271,323 cases over 5 years. *Surg Endosc.* 2017;31(4): 1785-1795.
  35. Agrusa A, Romano G, Cucinella G, Cocorullo G, Bonventre S, Salamone G, Di Buono G, De Vita G, Frazzetta G, Chianetta D, Sorce V, Bellanca G, Gulotta G. Laparoscopic, three-port and SILS cholecystectomy: a retrospective study. *G Chir.* 2013 Sep-Oct;34(9-10):249-53.
  36. Cocorullo G, Tutino R, Falco N, Salamone G, Gulotta G. Threeport colectomy: reduced port laparoscopy for general surgeons. A single center experience. *Ann Ital Chir.* 2016;87:350-355.
  37. Agresta F, Ansaloni L, Baiocchi GL, Bergamini C, Campanile FC, Carlucci M, Cocorullo G, Corradi A, Franzato B, Lupo M, Mandalà V, Mirabella A, Pernazza G, Piccoli M, Staudacher C, Vettoretto N, Zago M, Lettieri E, Levati A, Pietrini D, Scaglione M, De Masi S, De Placido G, Francucci M, Rasi M, Fingerhut A, Uranüs S, Garattini S. Laparoscopic approach to acute abdomen from the Consensus Development Conference of the Società Italiana di Chirurgia Endoscopica e nuove tecnologie (SICE), Associazione Chirurghi Ospedalieri Italiani (ACOI), Società Italiana di Chirurgia (SIC), Società Italiana di Chirurgia d'Urgenza e del Trauma (SICUT), Società Italiana di Chirurgia nell'Ospedalità Privata (SICOP), and the European Association for Endoscopic Surgery (EAES). *Surg Endosc.* 2012;26(8): 2134-64.
  38. Di Carlo P, Di Vita G, Guadagnino G, Cocorullo G, D'Arpa F, Salamone G, Salvatore B, Gulotta G, Cabibi D. Surgical pathology and the diagnosis of invasive visceral yeast infection: two case reports and literature review. *World J Emerg Surg.* 2013 Sep 26;8(1):38. doi: 10.1186/1749-7922-8-38.
  39. Salamone G, Licari L, Agrusa A, Romano G, Cocorullo G, Falco N, Tutino R, Gulotta G. Usefulness of ileostomy defunctioning stoma after anterior resection of rectum on prevention of anastomotic leakage: A retrospective analysis. *Ann Ital Chir.* 2016;87:155-60.