

Is it really useful the Harmonic scalpel in axillary dissection for locally advanced breast cancer? A case series

G. MILITELLO, P. DE MARCO, N. FALCO, K. KABHULI, A. MASCOLINO,
L. LICARI, R. TUTINO, G. COCORULLO, G. GULOTTA

SUMMARY: Is it really useful the Harmonic scalpel in axillary dissection for locally advanced breast cancer? A case series.

G. MILITELLO, P. DE MARCO, N. FALCO, K. KABHULI, A. MASCOLINO,
L. LICARI, R. TUTINO, G. COCORULLO, G. GULOTTA

Background. *The seroma is one of the most common complications in the axillary lymph nodal dissection (different surgical approaches have been tried to reduce the seroma incidence). In our study we evaluate the outcome of patients using or not the ultrasonic scalpel (Harmonic scalpel) according to a standardized surgical technique.*

Patients and Methods. *From January 2011 to December 2015 120 patients underwent axillary dissection for breast cancer. Patients were divided in two groups: patients belonging to the first group underwent Harmonic scalpel dissection and patients belonging to the second group underwent classical dissection. Each group consisted of 60*

patients. Quadrantectomy (QUAD) was performed in 54 patients, 66 women underwent mastectomy. In all patients axillary dissection included the I, II and III level. We compared two groups in terms of: time of surgery, hematoma, drainage volume, days of sealing drainage, seroma formation, number of post-seroma aspirations, upper limb lymphedema, wound infections, post-operative pain.

Results. *Statistically significant results were obtained in terms of the total volume of the breast and axillary drainage in the two techniques. There were no significant differences in the two samples in terms of operative time incidence of seroma, post-operative hematoma, wound infection, and lymphedema of the upper limb.*

Conclusion. *The small number of cases did not allow us to reach definitive conclusions. The use of Harmonic scalpel seems to show smaller incidence of seroma and reduction of the amount of both breast and axillary drainages. Further studies are needed to define the real advantage in terms of cost benefit of using these devices in the axillary surgery.*

KEY WORDS: Harmonic scalpel - Axillary dissection - Breast Cancer - Volume drainage.

Introduction

Today we tend to make less axillary lymph node dissections due the introduction of sentinel lymph node biopsy, but it remains the gold standard in cases of locally advanced breast cancer (1, 5). The main complications observed after axillary lymph node dissection can be classified in immediate (bleeding and seroma) and late (pain, decreased function, upper limb lymphedema) (2). The incidence of these complications is very variable in the different case studies; to minimize the impact of technical issues on these complications different aids was proposed (physiotherapy, external compression and use of pharmacological aids such as hemostatic biological adhesives) (3-7). The mono or bipolar electrocautery te-

chniques are the most commonly used in breast surgery, safe and effective with regard to haemostasis, but probably increasing the onset of seromas because the thermal effect on the tissues and the incomplete obliteration of lymphatic ducts (5-8). We report our experience on the axillary dissection using 'Harmonic scalpel' and compare it to classical dissection focusing our attention on the onset of seromas.

Patients and Methods

Patients

From January 2011 to December 2015 a total of 120 patient underwent axillary dissection for breast cancer. Patients were divided in two groups: the ones underwent Harmonic scalpel dissection and the others underwent classical dissection. The choice of the technique was defined on the base of the availability of harmonic scalpel device. Each group consisted of 60 patients undergoing axillary lymph node dissection. We excluded from our case series the patients who underwent previous ipsilateral

Department of Surgical, Oncological and Oral Sciences,
University of Palermo, General Surgery and Emergency Operative Unit,
"Policlinico Universitario P. Giaccone", Palermo, Italy

Corresponding author: Nicolò Falco, e-mail: nicola.falco87@libero.it

© Copyright 2016, CIC Edizioni Internazionali, Roma

breast surgery for malignancy, patients taking on anti-coagulants (aspirin, warfarin), patients with bleeding diathesis which had just been noted at the time of surgery. The quadrantectomy (QUAD) was performed in 54 patients, 66 women underwent mastectomy. In all patients axillary dissection included the I, II and III level. All procedures were performed by the same surgeon, in accordance with a standardized surgical technique, at the end of each intervention were inserted a drain on the chest wall and one in the axilla. We compared two groups in terms of: time of surgery, hematoma, drainage volume, days of sealing drainage, seroma formation, number of post-seroma aspirations, upper limb lymphedema, wound infections, post-operative pain.

Methods

The Harmonic scalpel (Ethicon, Somerville, NJ) is a system that allows cutting and hemostasis with maximum safety, precision and control without the application of electrical energy to the patient because it uses mechanical energy at a frequency of 55.5 kHz. The system uses three components: an acoustic transducer or piezoelectric that converts electrical energy from the generator into mechanical energy, an acoustic support that provides mechanical amplification to the longitudinal movement, the blade of the tool whose movement that gives ultrasonic energy to the tissue with which is placed in contact. The rationale of the harmonic scalpel is to practice a traumatic surgical dissection and hemostatic effect, which are not cruel to the tissues through direct application of ultrasound. The harmonic scalpel can be done: cavitation fusion protein, coagulation and cutting, these effects can be applied on the fabric alone or in synergistic combination (9, 10).

Surgical technique

In all operations we have recorded the surgical time. In the harmonic group both the breast and the axilla time were performed exclusively with a harmonic scalpel after skin incision with a classic scalpel according to a standardized surgical technique. The patient's arm was

extended and positioned at right angles to the trunk. In all cases the axillary dissection followed breast surgery. The external margin of the major pectoral muscle was exposed and all the lymphatic vessels, veins and arterial branches were obliterated with the harmonic scalpel. Avascular plane has been identified between the serratus anterior muscle and the Charles Bell's nerve, which needs to be isolated and preserved. A cleavage plane was created along the bottom edge of the axillary vein and all blood and lymphatic vessels were obliterated with the harmonic scalpel. The thoraco-dorsal pedicle was left intact. There was no need of ligatures. A precise and accurate control of hemostasis was performed before the introduction of drainage in the armpit and on the chest wall (11).

Postoperative data

Every day volumes of the drainages were recorded; they were removed when the drainage volume was found to be less than 30 mL in 24 hours. The postoperative pain was measured by visual analogue scale (VAS). Any collection that is clinically eco-graph relevant was drawn and recorded, and there were no cases of wound infections required antibiotic treatment. The histology of tumor and the number of metastatic lymph nodes removed have been recorded.

Statistics

The analysis was carried out taking into account the two samples treated with the different surgical techniques. After an initial exploratory analysis, descriptive tests were carried out to test the hypothesis that the two samples come from the same population. The variables considered can be divided into continuous variables (e.g. age, lymph nodes removed, lymph node metastasis, total axillary drainage, total drainage breast, axillary operative time, incidence of seroma) and categorical variables (e.g., tumor stage, quadrantectomy and mastectomy). Table 1 shows the characteristics of the samples that were subjected to the two treatments. Note how the samples reported a different age. This is just the result of chance because we have adopted the "single blind ran-

TABLE 1 - PATIENTS UNDERWENT BREAST SURGERY AND AXILLARY DISSECTION BOTH WITH HARMONIC SCALPEL AND TRADITIONAL TREATMENT.

	HARMONIC SCALPEL	CLASSICAL TECHNIQUE	P value
NUMBER OF PATIENTS	60	60	
AGE*	56 (44-75) yrs	59,5 (47-85) yrs	NS
TUMOR STAGE	T1 10; T2 18; T3 2	T1 9; T2 15; T3 6	
REMOVED LYMPH NODES*	13 (6-16), n	12 (3-29), n	NS
METASTATIC LYMPH NODES*	3,5 (0-16), n	3 (0-25), n	NS
QUADRANTECTOMY	30, n	24, n	
MASTECTOMY	30, n	36, n	

*Median (range); NS= not significant

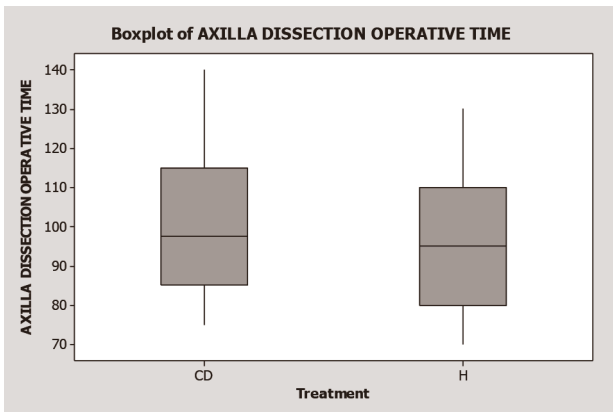


Fig. 1 - Boxplot of "Axilla dissection operative time": Not significant differences between the two samples.

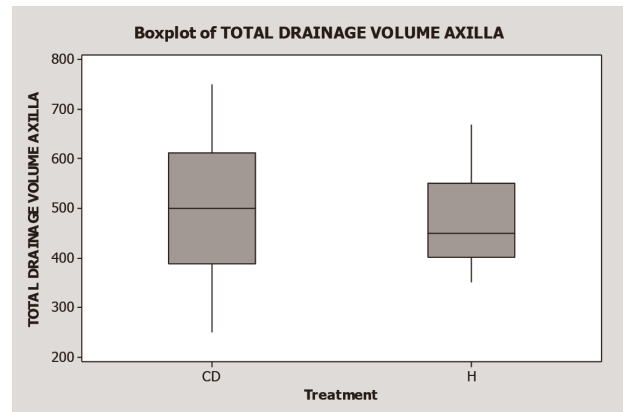


Fig. 3 - This boxplot shows the "Total drainage volume axilla" between the two samples. There is a significant difference. These samples are from different populations.

domized controlled trial". After analysis of the characteristics the results of different treatments were described graphically. In this regard were used the box and whiskers plot (better known as boxplot). The boxplot is a very useful tool for describing a sample using measures of dispersion and position. Its representation consists of a rectangle divided into two parts by the median, the ends of which consist in the first and third quartile (respectively 25% and 75%). The segments outgoing represent the remaining data which are dispersed up to the given minimum value of one side and up to the given maximum value of the other. Throughout the analysis was used the software Minitab. This is a very advanced tool that allows to perform various statistical tests. The exploratory analysis was performed for the variables "Axilla dissection operative time", "Total drainage volume chest wall" and "Total drainage volume axilla" (Figures 1, 2, 3). For both there seems to be a significant difference between the two samples. This leads us to think that the samples come from two different populations. We reserve to validate this thesis only with the use of statistical tests. Given the

limited sample size and the unknown distributional form of the samples we decided to perform a non-parametric test to compare the two samples. The test used is the test of Mann-Whitney. This is one of the most powerful non-parametric tests to demonstrate whether two independent groups belong to the same population. Test results confirm what was said in the previous descriptive analysis. Thanks to the Mann-Whitney test it is possible to tell which variables are really significant.

Results

Between January 2011 and December 2015, 120 patients underwent axillary dissection for breast cancer: 60 underwent traditional technique, while 60 using the Harmonic scalpel. The two series of patients were comparable for age, tumor stage, number of lymph nodes removed, number of metastatic lymph nodes, and the number of mastectomy and quadrantectomy (Table 1). In all patients was performed up to the axillary level III. There were no statistically significant differences as regards the operative time between the two groups, while no statistically significant differences were observed between the two groups with regard to the drainage volume of the chest wall and the axilla (Table 2). The incidence of seroma was 8/60 in the group of patients who underwent classical technique; in the group of patients operated with harmonic incidence was 4/60. The number of

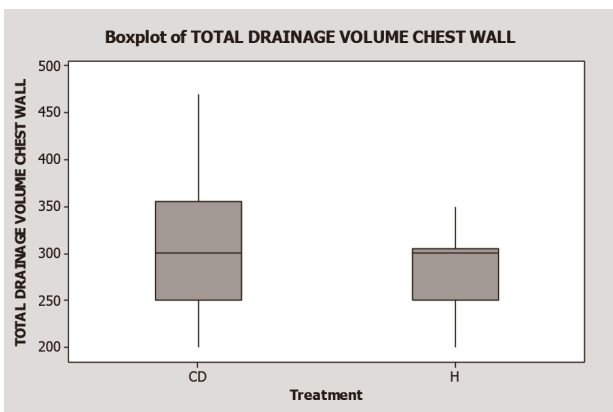


Fig. 2 - "Total drainage volume chest wall" between the samples. There is a significant difference. These samples are from different populations.

TABLE 2 - CLINICAL PARAMETERS EVALUATED WITH THE MANN-WHITNEY TEST.

	Mann-Whitney test
Axilla dissection operative time	P value= 0,2401
Total drainage volume chest wall	P value= 0,0402
Total drainage volume axilla	P value= 0,046

TABLE 3 - OUTCOMES AFTER SURGERY WITH HARMONIC SCALPEL OR TRADITIONAL TREATMENT.

	CLASSICAL TECHNIQUE	HARMONIC SCALPEL
OPERATIVE TIME*	100,66 min	95 min
VOLUME DRAINAGE CHEST WALL*	322 ml	289 ml
VOLUME DRAINAGE AXILLA*	508,3 ml	470,5 ml
NUMBER OF DAY DRAINAGE AXILLA*	7,96 days	7,1 days
NUMBER OF DAY DRAINAGE CHEST WALL*	5,03	4,23
NUMBER OF SEROMA	6/30	2/30
NUMBER OF ASPIRATION FOR SEROMA AFTER DRAINAGE*	3,5	2,5
NUMBER OF WOUND INFECTION	0	0
NUMBER OF HEMATOMA	0	0
POST OPERATIVE PAIN (VAS)*	4,5	3,1
UPPER -LIMB LYMPHEDEMA	0	0

*Mean

seroma aspirations was the same in both groups. The post-operative pain controlled with the use of analgesics was reported an average of 4.5 in the group of patients operated with classic technique and 3.1 in the group of patients operated with harmonic. The mobility of the shoulder was taken quickly in both groups. Finally, no cases of wound infection, hematoma, and lymphedema of the upper limb were observed (Table 3).

Conclusions

Lymph-node sentinel biopsy is the gold standard in the study of axillary nodal status and this has led to a re-

duction in the number of axillary lymphadenectomy. Nevertheless lymphadenectomy is sometimes necessary in cases of locally advanced disease. The most frequent complication is the onset of seromas. To reduce the incidence of this complication various techniques have been implemented including the use of the harmonic scalpel. Aim of our study is to evaluate the efficacy of the harmonic in the axillary dissection in regard to the incidence of seroma. The use of Harmonic would appear to reduce the incidence of seroma not significantly and the total volume of drainage significantly, despite higher costs compared to the classical technique. Therefore further studies seem, in our opinion, necessary to establish the real benefit of using these devices.

References

1. Omair M, Al-Azawi D, Mann GB. Sentinel node biopsy in breast cancer revisited. *Surgeon*. 2014 Feb 15. pii: S1479-666X(14)00005-5. doi: 10.1016/j.surge.2013.12.007.
2. Ferreira BP, Pimentel MD, Santos LC, di Flora W, Gobbi H. Morbidity after sentinel node biopsy and axillary dissection in breast cancer. *Rev Assoc Med Bras*. 2008 Nov-Dec;54(6):517-21.
3. Docimo G, et al. A Gelatin-Thrombin Matrix Topical Hemostatic Agent (Floseal) in Combination With Harmonic Scalpel Is Effective in Patients Undergoing Total Thyroidectomy: A Prospective, Multicenter, Single-Blind, Randomized Controlled Trial. *Surg Innov*. 2016 Feb;23(1):23-9. doi: 10.1177/1553350615596638. Epub 2015 Aug 3.
4. Fingerhut A. European Initial Hands-On Experience with HEMOPATCH, a Novel Sealing Hemostatic Patch: Application in General, Gastrointestinal, Biliopancreatic, Cardiac, and Urologic Surgery. *Surg Technol Int*. 2014 Nov;25:29-35.
5. Porter KA, O'Connor S, Rimm E, Lopez M. Electrocautery as a factor in seroma formation following mastectomy *Am J Surg*. 1998 Jul;176(1):8-11.
6. Segura-Castillo JL, Estrada-Rivera O, et al. Reduction of lymphatic drainage posterior to modified radical mastectomy with the application of fibrin glue. *Cir Cir*. 2005 Sep-Oct;73(5):345-50.
7. Berger A, Tempfer C, Hartmann B. Sealing of postoperative axillary leakage after axillary lymphadenectomy using a fibrin glue coated collagen patch: a prospective randomised study. *Breast Cancer Res Treat*. 2001 May;67(1):9-14.
8. Douay N, Akerman G, Clément D, Malartic C, Morel O, Barranger E. Seroma after axillary lymph node dissection in breast cancer. *Gynecol Obstet Fertil*. 2008 Feb;36(2):130-5.
9. Selwyn Selvendran, Rajkumar Cheluvappa, Vinh Khiêm Truong, Simon Yarrow, Tony C. Pang, Davendra Segara, Patsy Soon. Efficacy of harmonic focus scalpel in seroma prevention after axillary clearance. *Int J Surg* 2016;30:116-120.
10. Jinbo Huang, Yinghua Yu, Changyuan Wei, Qinghong Qin, Qinguo Mo, Weiping Yang. Harmonic Scalpel versus Electrocautery Dissection in Modified Radical Mastectomy for Breast Cancer: A Meta-Analysis. *PLoS One*. 2015 Nov 6;10(11):e0142271. doi: 10.1371/journal.pone.0142271. eCollection 2015.
11. Chung AP, Sacchini V. Nipple-sparing mastectomy: where are we now? *Surg Oncol*. 2008 Dec;17(4):261-6. doi: 10.1016/j.suronc.2008.03.004. Epub 2008 May 5. Erratum in: *Surg Oncol*. 2010 Jun;19(2):114.