

SOMATOTOPIC ORGANIZATION OF THE CRANIAL NERVE NUCLEI INVOLVED IN EYE MOVEMENTS: III, IV, VI.

Alessio Lipari¹, Luana Lipari¹, Marcello Romano², Raffaella Morreale Bubella¹, Elvira Farina¹

1. Department of Experimental Biomedicine and Clinical Neurosciences, University of Palermo, Italy.

2. The “Cervello-Villa Sofia” Hospital, Palermo, Italy.

ARTICLE INFO

Article history:

Received 12 September 2016

Revised 25 November 2016

Accepted 02 January 2017

Keywords:

Cranial nerve, eye movement,
oculomotor

ABSTRACT

The oculomotor nucleus is divided into: 1. somatic medial column innervating the superior rectus muscle and somatic lateral column, further subdivided into a lateral column innervating the inferior rectus, inferior oblique and medial rectus muscles; 2. central nucleus innervating the levator palpebrae superioris muscle; 3. visceral nucleus innervating the pupillary sphincter muscle, consisting of the following two groups of neurons: cholinergic, preganglionic neurons supplying the ciliary ganglion, termed the Edinger-Westphal preganglionic (EWpg) neuron population, and the centrally projecting, peptidergic neurons, termed the Edinger-Westphal centrally projecting (EWcp) population. A detailed understanding of the position of both nuclei and their subgroups supplying the individual muscles is an essential prerequisite for eye movement assessment, offering a simple clinical method for diagnosing eventual dysfunctions of eye movement generation pathways.

© EuroMediterranean Biomedical Journal 2017

1. Introduction

The twelve pairs of cranial nerves originate from the surface of the brain. Each nerve is known by a name and a Roman numeral. The latter are assigned according to the rostral-caudal position of the nerves on the brain. Cranial nerves differ from spinal nerves for their specialized functions: indeed, some cranial nerves have motor functions only, while others provide only sensory innervation, and some have both sensory and motor functions. The I nerve, or olfactory nerve, originates from the chemoreceptors in the nasal olfactory epithelium and terminates in the olfactory bulb. The II nerve, or optic nerve, originates from the ganglionic neurons of the retina and terminates in the lateral geniculate body. The III-XII nerves emerge from the brainstem; the sensory nerve (VIII) and the sensory component of mixed-function nerves (V, VII, IX, X) have their secondary neuron nuclei in the brainstem, while the proprioceptive fibers of the trigeminal nerve (V), motor nerves (III, IV, VI, XI, XII) and motor fibers of mixed nerves (V, VII, IX, X) have their primary neuron nuclei in the brainstem. The III-XII nerves are visible on the inferior (ventral) surface of the brainstem, while the VI nerve, or abducent nerve, emerges from the posterior (dorsal) midbrain. All these nerves innervate various structures of the head and neck, with only the vagus nerve innervating some thoracic-abdominal viscera.

In this paper, we describe the somatotopic organization of the cranial nuclei involved in eye movement: Oculomotor nuclear complex (III), Trochlear nucleus (IV), and Abducens nucleus (VI).

2. The oculomotor nuclear complex

Oculomotor nuclear complex (cranial nerve III) occupies the V-shaped space between the two medial longitudinal fasciculi, ventral to the central grey matter, and has a somatotopic organization. The oculomotor nuclear complex consists of paired columns: 1) somatic cell columns; 2) a separate midline dorsal cell group, called caudal central nucleus; 3) midline and dorsal visceral nuclei (Figure 1 and 2).

1) The somatic cell columns are further subdivided into: lateral (A) and medial (B) nuclei:

1A) The lateral somatic cell columns composed of larger motor type neurons innervate the extraocular muscles. The fibers arising from these cell columns are uncrossed, ipsilaterally.

- A1) The dorsal cell column innervates the inferior rectus muscle;
- A2) The intermediate cell column innervates the inferior oblique muscle;
- A3) The ventral column innervates the medial rectus muscle.

* Corresponding author: Alessio Lipari, alessio.lipari@tiscali.it

DOI: 10.3269/1970-5492.2017.12.2

All rights reserved. ISSN: 2279-7165 - Available on-line at www.embj.org

The subnucleus (A3) of the medial rectus muscle is further subdivided into three distinct components: 1. a more conspicuous ventral subgroup located in the cranial two-thirds of the subnucleus; 2. a dorsal subgroup occupying the cranial two-thirds of the subnucleus, comprising of smaller motoneurons innervating the narrow orbital component of the medial rectus muscle; 3. a dorsolateral subgroup occupying the caudal two-thirds of the subnucleus.

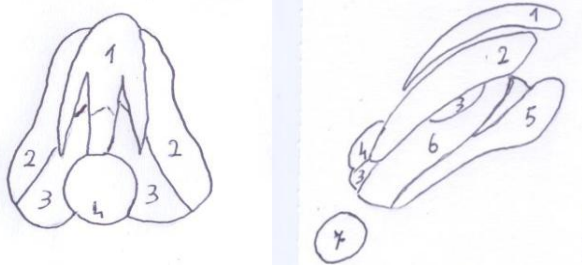


Figure 1 - Oculomotor complex. A Dorsal view (left); B right lateral view (right): 1 Visceral nucleus 2. Dorsal-lateral nucleus innervating the inferior rectus muscle. 3. Dorsal-medial nucleus innervating the superior rectus muscle. 4. Central nucleus innervating the levator palpebrae superioris muscle. 5. Ventral-lateral nucleus innervating the medial rectus muscle. 6. Ventral-medial nucleus innervating the inferior oblique muscle. 7 Trochlear nucleus. (Warwick, 53 a)

1B) The medial somatic cell columns (a cell column medial to both the dorsal and intermediate cell columns) provide crossed fibers that innervate the contralateral superior rectus muscle.

2) The caudal central nucleus is a midline somatic cell group found only in the caudal third of the complex. It gives rise to crossed and uncrossed fibers that innervate the levator palpebrae superioris muscle. This nucleus is adjacent to the medial and superior subnuclei.

3) The visceral nuclei of the oculomotor nuclear complex consist of two distinct neuron groups which are rostrally connected, and are often collectively referred to as the Edinger-Westphal nucleus.

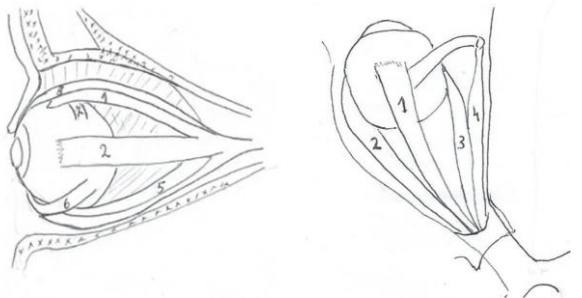


Figure 2 - Map of the extraocular muscles. A. Lateral view (left). B. Superior view (right). 1. Superior rectus muscle. 2. Lateral rectus muscle. 3. Medial rectus muscle. 4. Trochlear muscle. 5. Inferior rectus muscle. 6. Inferior oblique muscle. 7 Superior oblique muscle.

These groups are located dorsally to the main nucleus (Fig. 1A, B).

Recent comparative studies of the Edinger-Westfall (EW) nucleus (3, 4), comparing the location of cholinergic and urocortin-positive neurons, demonstrated that it consists of two separate, adjacent populations of cholinergic and urocortin-positive neurons. Within the cytoarchitecturally defined EW nucleus in rat, ferret and human, almost exclusively urocortin-positive neurons were found, whereas in monkey, only cholinergic preganglionic neurons were found. In humans, the preganglionic neurons presumably form an inconspicuous group of choline acetyltransferase-positive neurons located dorsally to the urocortin-positive EW. (Figure 3)

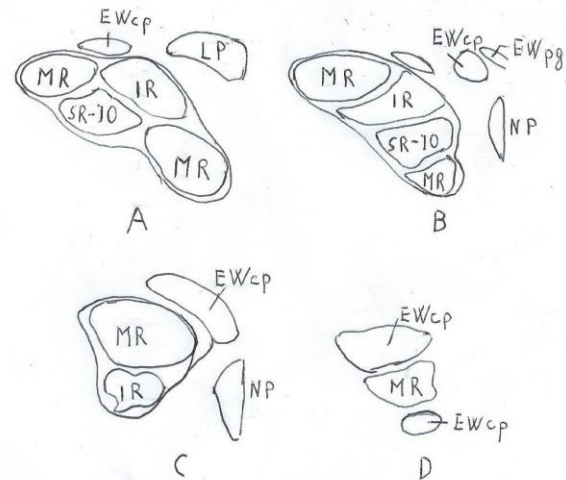


Figure 3 - Map of motoneurons for extraocular muscles in human, shown at four levels from caudal to rostral planes (A-D). MR. Medial rectus muscle. IR. Inferior rectus muscle. SR/IO. Superior rectus/inferior oblique muscles. NP. Nucleus of Perlia muscle. LP Levator palpebrae muscle. IR. Inferior rectus muscle. EWcp. Edinger-Westphal nucleus. EWpg. preganglionic population Edinger-Westphal nucleus. EWcp. Centrally projecting peptidergic neurons the Edinger-Westphal centrally projecting (EWcp) population.

The terminology of EW nucleus components is based on their connectivity: 1) cholinergic, preganglionic neurons supplying the ciliary ganglion are termed the Edinger-Westphal preganglionic (EWpg) population; 2) the centrally projecting, peptidergic neurons are termed the Edinger-Westphal centrally projecting (EWcp) population (5).

In the human oculomotor nucleus (nIII), seven subgroups have been defined: central caudal nucleus (CCN), dorsolateral (DL), dorsomedial (DM), central (CEN), and ventral (VEN) groups, the nucleus of Perlia (NP) and the non-preganglionic centrally projecting Edinger-Westphal nucleus (EWcp) (6). (Fig.3) da Che Ngwa E., 2014)

The DL, VEN, NP, and EWcp subgroups are characterized by a strong supply of GAD-positive (glutamate decarboxylase) terminals, in contrast to DM, CEN and nIV;

the terminals and fibers of CCN, CEN and NP are CR-positive (calretinin).

In the monkey oculomotor nucleus, based on location and histochemistry of the motoneuron subgroups (Figure 3):

- CEN (Central) includes the superior rectus and inferior oblique motoneurons,
- DL includes the B-group of the medialis rectus motoneurons,
- VEN includes the A-group of the medialis rectus motoneurons,
- DM includes the inferior rectus motoneurons.

The centrally projecting neurons of the Edinger–Westphal nucleus (EWcp) appear as a single lateral group of neurons at the caudal level, dorsally to nIII (A), bordered by a medial group rostrally (B), eventually emerging into a single dorsal group (C). Another ventral extension of the EWcp emerges at the rostral level (D). The preganglionic neurons in the EWcp do not form a compact nucleus (B).

An evident correlation between monkey and human is seen for calretinin (CR) input, which occurs only in the motoneurons of eye muscles participating in upgaze: superior rectus, inferior oblique, and levator palpebrae muscles. The CCN contains the motoneurons for the levator palpebrae muscle, while the motoneurons for the superior oblique muscle are located in the nIV. Furthermore, it has been hypothesized that NP may contain upgaze motoneurons.

A strong GABAergic input to human MR motoneurons has also been discovered, which is not seen in monkey and may indicate a functional oculomotor specialization.

3. The trochlear nucleus

The trochlear nucleus (7,8) is a column of somatic cells within the grey matter in the caudal and dorsal part of the mesencephalon, just below the aqueduct, to the side of the nucleus of CN III which is situated slightly higher in the mesencephalon. At the level of the inferior colliculus, the CN IV is clearly outlined as a round nucleus embedded in the fibers of the medial longitudinal fasciculus (6). The trochlear nucleus is the origin of the trochlear nerve.

The trochlear nerve, IV cranial nerve, is an exclusively somatic motor nerve, has the longest intracranial course and is also the thinnest; it is the only nerve that arises from the dorsal surface of the brainstem and decussates in the superior medullary velum. After leaving the dorsal surface of the brainstem, it runs anterolaterally around the lateral surface of the brainstem and then passes anteriorly just beneath the free edge of the tentorium. It then enters the cavernous sinus passes through the superior orbital fissure and terminates in the superior oblique muscle in the orbit. The trochlear nerve innervates the superior oblique muscle whose actions include intorsion and depression (in the adducted position).

4. The abducens nucleus

The abducens nucleus (8) is located in the pons on the lateral part of the medial eminence, beneath the fourth ventricle. Axons from the facial nerve loop around the abducens nucleus, creating a slight bulge (the facial colliculus) that is visible on the dorsal surface of the bottom of the fourth ventricle. The nucleus contains primary neurons for innervations of the ipsilateral lateral rectus muscle and interneurons for the innervations of the ventral nucleus of contralateral oculomotor nerve.

The abducens nerve, VI cranial nerve, is exclusively a motor nerve; it emerges from the medial abducens nucleus, passes ventrally through the pontine tegmentum, and laterally to the corticospinal tract, emerging from the brainstem at caudal border of the pons. The abducens nerve passes through Dorello's foramen in the lateral wall of the cavernous sinus, where it runs with the oculomotor, trochlear and ophthalmic nerves. The nerve perforates the dura mater, turning, at an acute angle, along the superior border of the pyramid of the temporal bone, and passing through the superior orbital fissure within the lower portion of the tendinous circle laterally to the nasociliary nerve, between the two branches of the oculomotor nerve, running along the medial surface of the lateral rectus muscle.

The extraocular muscle fibers of vertebrates (9) can be classified into two categories: singly innervated fibers (SIFs) and multiply innervated fibers (MIFs). In monkeys, the motoneurons of SIFs lie within the oculomotor, trochlear, and abducens nucleus, whereas the motoneurons of MIFs appear in separate subgroups in the periphery of the classical nuclei borders. Past studies provide evidence that SIF and MIF motoneurons, which can be correlated with twitch motoneurons and presumed non-twitch motoneurons, differ in their histochemical properties. In rat (10), the overall identification of multiply-innervated muscle fiber and singly-innervated muscle fiber motoneurons within the oculomotor nucleus, trochlear nucleus, and abducens nucleus revealed that rat extraocular muscles are innervated by two sets of motoneurons that differ in their molecular, morphological, and anatomical properties, and that the smaller multiply-innervated muscle fiber motoneurons tend to lie separate from the larger diameter singly-innervated muscle fiber motoneurons.

5. Conclusion

A correct eye position is vital for the best visual acuity that is available only in the fovea of the retina, and binocular perception (of an object as a single object) requires the received image to be located in the corresponding positions on both retinas. Eye movements are either conjugate movements where both eyes move in same direction, or vergence movements where the eye moves toward the midline or away from the midline. The vergence movements occur when looking at an object near the eye or when switching the gaze from a nearby object to an object farther away.

Eye coordination requires connections between the cranial nerve nuclei controlling eye movements. Eye position control occurs through activation of the medial longitudinal fasciculus, reflex and cerebral center; the superior colliculus coordinates reflexive orienting movements of the eye and head via medial longitudinal fasciculus and tectospinal tract (11).

A detailed knowledge of the position not only of the nuclei, but also of their subgroups supplying the single muscles is an essential prerequisite for eye movement assessment, offering a simple clinical method for diagnosing eventual disturbances in eye movement generation pathways, including extra- and intraocular muscles.

References

1. Carpenter MB: Human Neuroanatomy seventh edition. The Williams & Wilkins Company. Baltimore 1976.
2. Gray: Gray's Anatomy: The Anatomical Basic Basis of Clinical Practice edited by Standring Susan. 2008.
3. Horn AK, Eberhorn A, Härtig W, Ardeleanu P, Messoudi A, Büttner-Ennever JA: Periocolomotor cell groups in monkey and man defined by their histochemical and functional properties: reappraisal of the Edinger-Westphal nucleus. *J Comp Neurol.* 2008; 507:1317-35. doi: 10.1002/cne.21598.
4. Horn AK, Schulze C, Radtke-Schuller S: The Edinger-Westphal nucleus represents different functional cell groups in different species. *Ann N Y Acad Sci.* 2009; 1164:45-50. doi: 10.1111/j.1749-6632.2009.03856.x.
5. Kozicz T, Bittencourt JC, May PJ, Reiner A, Gamlin PD, Palkovits M, Horn AK, Toledo CA, Ryabinin AE: The Edinger-Westphal nucleus: a historical, structural, and functional perspective on a dichotomous terminology. *J Comp Neurol.* 2011 Jun 1;519(8):1413-34. doi: 10.1002/cne.22580.
6. Che Ngwa E, Zeeh C, Messoudi A, Büttner-Ennever JA, Horn AK: Delineation of motoneuron subgroups supplying individual eye muscles in the human oculomotor nucleus. *Front Neuroanat.* 2014 Feb 12;8:2. doi: 10.3389/fnana.2014.00002. eCollection 2014.
7. Joo W, Rhoton AL Jr: Microsurgical anatomy of the trochlear nerve. *Clin Anat.* 2015 Oct; 28(7):857-64. doi: 10.1002/ca.22602. Epub 2015 Aug 28.)
8. Koskas P, Héran F: Towards understanding ocular motility: III, IV and VI. *Diagn Interv Imaging.* 2013 Oct;94(10):1017-31. doi: 10.1016/j.diii.2013.08.008. Epub 2013 Sep 28.
9. Eberhorn AC, Ardeleanu P, Büttner-Ennever JA, Horn AK: Histochemical differences between motoneurons supplying multiply and singly innervated extraocular muscle fibers. *J Comp Neurol.* 2005 Oct 31;491(4):352-665
10. Eberhorn AC, Büttner-Ennever JA, Horn AK: Identification of motoneurons supplying multiply or singly-innervated extraocular muscle fibers in the rat. *Neuroscience.* 2006 Feb;137(3):891-903. Epub 2005 Dec 5.
11. Alessio L, Marcello R, Luana L, Elvira F. The somatotopy of the spinal cord: A comprehensive description. *EuroMediterranean Biomedical Journal* 2016, 11(06): 40-51.