

## **ANATOMICAL DISSECTION AND ANALYSIS OF THE STRUCTURES OF THE UPPER LIMB**

Andrea Etrusco <sup>1\*</sup>, Leonardo Salvaggio <sup>1\*</sup>, Giulia Arrigo <sup>1</sup>, Simone Cataldi <sup>1</sup>, Claudio Farina <sup>1</sup>, Irene Gattuso <sup>1</sup>, Mauro La Bruna <sup>1</sup>, Mirco Pistone <sup>1</sup>, Sarah Tinaglia <sup>1</sup>, Fabio Torregrassa <sup>1</sup>, Francesco Carini <sup>1,2</sup>, Giovanni Tomasello <sup>2,4</sup>, Cristoforo Pomara <sup>3</sup>

\* These authors contributed equally to the present work.

1. School of Medicine and Surgery, University of Palermo, Palermo, Italy.

2. Department of Experimental Biomedicine and Clinical Neuroscience, University of Palermo, Palermo, Italy.

3. Department of Anatomy, School of Medicine, University of Malta, Msida, Malta.

4. Euro Mediterranean Institute of Science and Techonolgy – IEMEST Palermo

### **ARTICLE INFO**

Article history:

Received 02 April 2016

Revised 25 October 2016

Accepted 17 January 2017

Keywords:

Dissection course, young medical doctor training, upper limb

### **ABSTRACT**

In 2015, a whole body dissection course was proposed by the University of Palermo (UoP), Palermo, Italy, thanks to the cooperation with the University of Malta (UoM), Msida, Malta. The purpose of this study was to show the difference between the study of anatomy on books and on corpses. The article focuses its attention on the dissection method of the upper limb. The study was performed on two corpses, a male and a female, by using a basic surgeon kit. Blunt dissection method was used for fasciae, innards and to isolate vascular-nervous structures from the fat; we used scalpel for cutis, sub cutis, muscles and tendons. We compared the anatomy figured by books and cadaver's anatomy. We separated muscles, fasciae, veins, arteries and nerves of the upper limb from the shoulder to the hand. The upper limb dissection shows the difference between how a real body appears and how books represent it.

© EuroMediterranean Biomedical Journal 2017

## **1. Introduction**

An important aspect of the training of young medical doctors is represented by the international experience performed during the course of study [1]. The knowledge of the anatomical structure of our body is necessary for those who are going to become a doctor. These notions are often acquired using ineffective study aids: the pictures in the books show a two-dimensional and partial view of the human body [2-5]. Instead, we could acquire a tri-dimensional and holistic view, substantial information in the medicine course of study, by using the anatomic dissection of cadaver. Nevertheless, the dissection is barely diffused in the Italian University. The University of Palermo (UoP), Italy, has a framework cooperation agreement with the University of Malta (UoM), School of Medicine, by which a group of students from the UoP that already passes

brilliantly the exam of Human Anatomy, performed, under a voluntary base, a month-long course of human dissection at the Department of Anatomy of the UoM. In this article we focus on the upper limb region dissection whit its principal musculoskeletal and vascular-nervous structures, providing a comparison between the photos of the dissection and the didactic pictures of an anatomic atlas.

## **2. Material and methods**

In July-August 2015, for a period of four weeks, we worked at the dissection hall of the Department of Anatomy of the University of Malta, School of Medicine, on two corpses, 1 male and 1 female. The corpses were embalmed with a solution composed by 99% of phenoxyethanol and

\* Corresponding author: Giovanni Tomasello, giovanni.tomasello@unipa.it

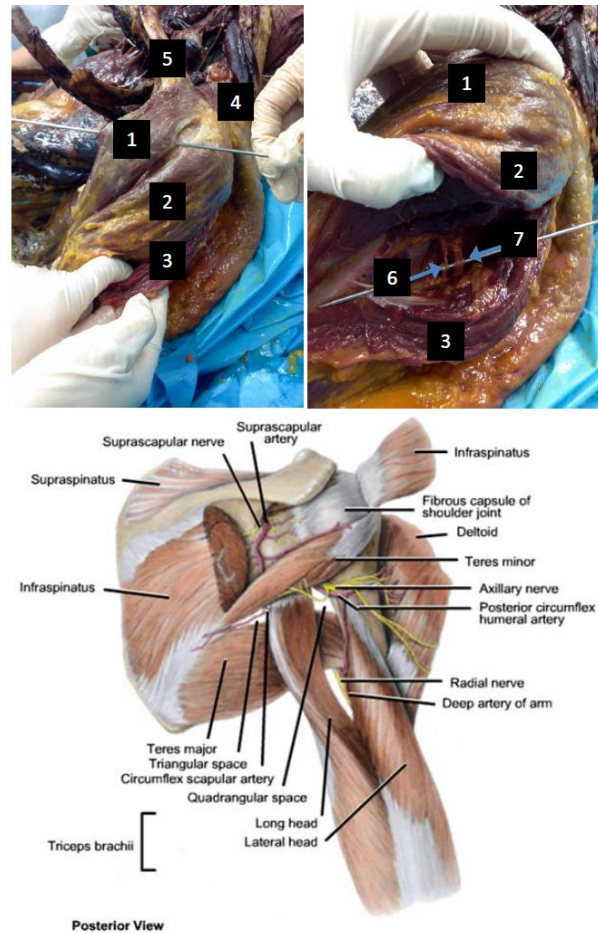
DOI: 10.3269/1970-5492.2017.12.3

All rights reserved. ISSN: 2279-7165 - Available on-line at www.embj.org

1% of formalin, and they were maintained at a temperature between 2-4°C. The process of the embalming starts from the incision of the femoral artery and femoral vein, situated in the triangle of the Scarpa. Salt water was pumped in the femoral artery using a catheter and the blood was going out from another catheter, inserted in the femoral vein. As soon as the salt water comes out instead of blood, we stopped to pump salt water and started pumping the solution of phenoxyethanol and formalin for twenty minutes. The artery and the vein were closed and the skin sutured. Nevertheless, the central nervous system (CNS) can not be embalmed with this method. To do the dissection, a basic surgery kit, which included a scalpel handle n. 4 for blades 20-24, a scalpel handle n.3 for blades 10-15, anatomy forceps, surgery forceps, a scissors straight blunt/sharp, a scissors curved blunt/blunt, a Klemmer's forceps, a Kocher's forceps and a Gluck pulling forceps for ribs, were used. Blunt dissection method was used for fasciae, innards and to isolate vascular-nervous structures from the fat; we used scalpel for cutis, subcutis, muscles and tendons. Before the dissection, we first usually study the structures of the different regions on the book and then on the specimen prepared by professor Pomara. Thanks to this method, we were able to make a comparative exam between the anatomy figured by the books and the corpses' anatomy with all of its variation [4].

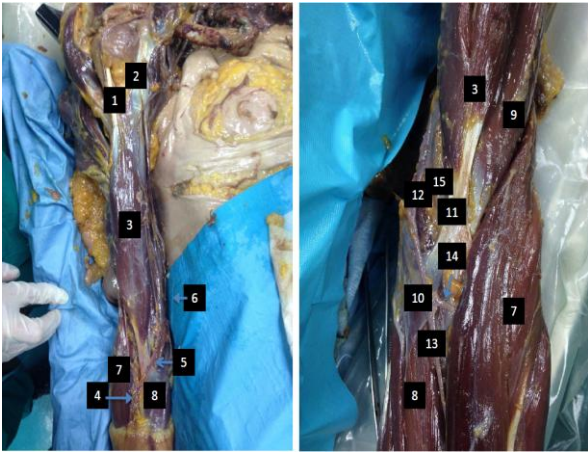
### 3. Results and Discussion

The upper limb is composed by shoulder, arm, forearm and hand. The shoulder girdle is made by the shoulder's skeleton (clavicle and scapula) and it links the appendicular part of the limb to the trunk through the sternoclavicular joint. The deltoid muscle, which gives roundness to the shoulder, is made up by three fibres: clavicular part, acromial part and scapular part, which end with a sturdy tendon on the humeral deltoid's tuberosity [2-3]. In order to obtain the result shown in Figure 1, a chalice incision was made from the acromion to the coracoid process of the scapula, which continued at right angle across the later face of the arm [4]. We removed the cutis and the sub cutis highlighting the deltoid's fascia, and after then it was cut the fibres of the deltoid muscle came up. We continued with the conservative dissection of the muscular fibres, showing and cutting the connective tissue between the adjacent fibres. Engraving along the connective tissue, we arrived on the bone surface to completely separate the muscle from it, preserving the tendon insertions. The clavicular part was reflected to show the axillary nerve (C5-C6) - branch of the posterior cord of brachial plexus - which innervates the deltoid muscle and the teres minor muscle, and collects the cutaneous sensibility of this region; and the posterior circumflex humeral artery - branch of the axillary artery - which vascularises the shoulder's stump [2]. The humerus is connected to the scapula by the shoulder's joint and it is the only bone of the arm. The humeral capitulum and trochlea are respectively joint with radius and ulna (which compose the forearm skeleton) in the elbow joint. The flexor muscles of the arm are situated in the ventral loggia, composed by biceps brachii muscle and brachial muscle. The arm's extensor muscles are in the posterior loggia and they are triceps brachii muscle and anconeus. Although the coracobrachial muscle is included among the muscles of the anterior loggia, from a functional point of view it is part of the shoulder's muscles, because it bends, adduces and internal rotates the arm [2-3].



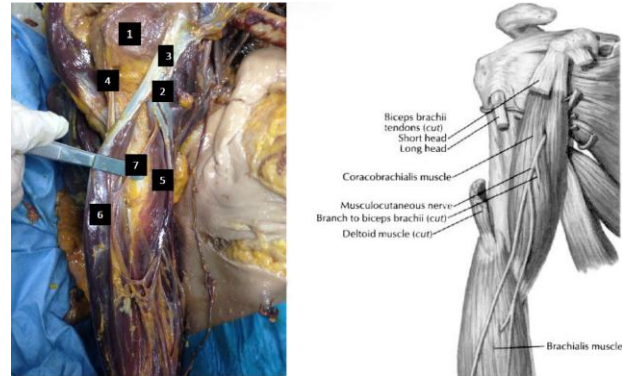
**Figure 1 - The fibres of deltoid muscle was separated from each other, and the posterior deltoid reflected to show the axillary nerve and the posterior circumflex humeral artery. 1: Clavicular part of deltoid muscle. 2: Acromial part of deltoid muscle. 3: Scapular part of deltoid muscle. 4: Acromion. 5: Clavicle. 6: Posterior circumflex humeral artery. 7: Axillary nerve.**

Widening the strips of the incision of the lateral surface of the arm, we continued to remove the cutis and undercutis to reveal the brachial fascia, which is linked with the fasciae of the deltoid and of the pectoral. After removing the bicipital fascia (Figure 2), we continued isolating the biceps brachii muscle, its tendons continue in the muscular fibres that even if they are strictly juxtaposed, they can be separated within 7 cm or more by the elbow joint [4]. After that, we were able to separate the biceps brachii muscle from the below coracobrachialis muscle give particular attention to the neurovascular structures. The short head of biceps brachii muscle arises with the tendon of the coracobrachialis muscle from the coracoid process. The long head arises from the shoulder joint capsule with a long tendon, which emerges behind the transverse humeral ligament and continues along the intertubercular sulcus.



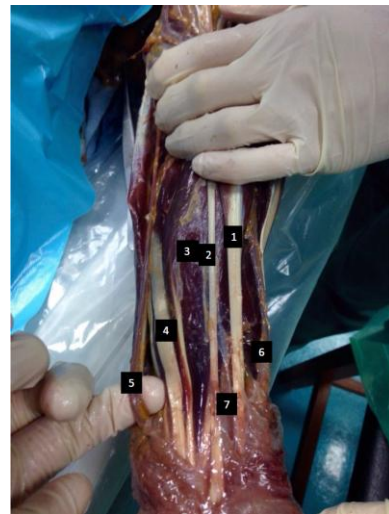
**Figure 2 - Left: Dissection of cutaneous veins of the cubital region cover by brachial and antibrachial fasciae, and dissection of the arm muscles of the superior layer. Right: Superficial layer (anterior aspect) of the cubital region. The antibrachial fascia was removed and the focus of dissection was the arteries of the cubital region. 1: Tendon of long head of biceps brachii muscle. 2: Tendon of short head of biceps brachii muscle. 3: Biceps brachii muscle. 4: Cephalic vein. 5: Median cubital vein. 6: Basilic vein. 7: Brachioradialis muscle. 8: Pronator teres muscle. 9: Brachial muscle. 10: Bicipital Aponeurosis. 11: Tendon of biceps brachii muscle. 12: Brachial artery. 13: Ulnar artery. 14: Radial artery. 15: Median nerve.**

Arrived at the elbow, the two heads of the muscle come out in a flat tendon that ends on the radial tuberosity. The tendon with his medial expansion - bicipital aponeurosis - creates the roof the cubital region and then it continues with the antibrachial fascia [2]. Removing the epidermis from the derma, we can see the venous structures, which were cleaned from surrounding tissue, is possibly examined: the cephalic and the basilica vein are easily recognizable, they take origins respectively from the thumb and little finger, and that in the cubital region are linked by the median cubital vein. Separating the vein's structures, it is possible to analyze the median nerve, the brachial artery and the two branch of this: radial and ulnar arteries. Reconsidering the muscles of the arm, under the biceps brachii muscle, we can find the coracobrachialis muscle which is strictly distally adherent to the bone surface and not separable. Proximally, after separating the proximal fiber from the humerus, we can easily study the musculocutaneous nerve (C5-C7), that proximally pierce the third of the cocarcobrachial muscle that continues ventrally under the biceps brachii muscle (Figure 3). The musculocutaneous nerve gives mobility to the biceps brachii muscle, the brachial muscle and the coracobrachialis muscle. It collects sensibility of the lateral surface of the forearm and of the elbow joint capsule [2-3].



**Figure 3 - The biceps brachii muscle was separated from the coracobrachialis muscle and reflected to show the musculocutaneous nerve, that pierces the coracobrachialis in the proximal third. 1: Head of humerus. 2: Tendon of choracobrachialis muscle. 3: Tendon of short head of biceps brachii muscle. 4: Tendon of long head of biceps brachii muscle. 5: Choracobrachialis muscle. 6: Biceps brachii muscle (reflected). 7: Musculocutaneous nerve.**

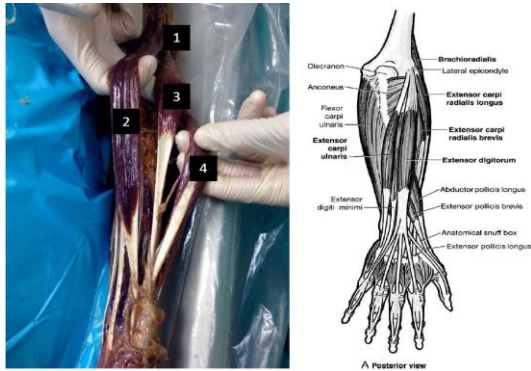
We continued the previous incision (Figure 4), in the first place we stopped under the elbow's joint, until the wrist. Removing the cutis and sub cutis, we find the antibrachial fascia. Under the antibrachial fascia, we can emphasize the several muscles of the forearm. We need to cut the light connective between the muscles to separate them, so that we can immediately recognize the division into layer of the three muscular lodges (anterior, posterior and lateral) [4]. Muscles of the anterior loggia are flexor, and they are divided into four layer strictly overlapping. The deepest layer is strongly adherent to the bone surface.



**Figure 4 - The antibrachial fascia was removed and the structures were put in evidence. 1: Tendon of flexor carpi radialis muscle. 2: Tendon of palmaris longus muscle. 3: Flexor digitorum superficialis muscle. 4: Flexor carpi ulnaris muscle. 5: Ulnar artery. 6: Radial Artery. 7: Median nerve.**



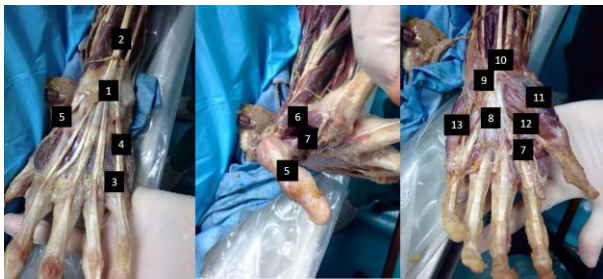
The muscles of the posterior loggia are extensor and they are divided into two layers easily separable thanks to a massive presence of connective. The muscles of the lateral loggia (Figure 5) are three and they are disposed into a single layer, only the extensor carpi radialis longus muscle and the extensor carpi radialis brevis muscle reach the hand. The third one, the brachioradialis muscle takes insertion on the ulnar styloid process.



**Figure 5 - The muscles was separated from each other. 1: Lateral epicondyle of humerus. 2: Brachioradialis muscle. 3: Extensor carpi radialis longus muscle. 4: Extensor carpi radialis brevis muscle.**

The arm's bones joint with the carpal's bones in the radiocarpal joint, making possible the hand's movements (pronation and supination).

In order to get the result of the sixth picture (Figure 6), we made a "Y" incision on the palmar surface of the hand, with the arms of the Y, laying respectively on the thumb and on the little finger [4]. After removing cutis and sub cutis, it is possible to see the musculotendineous structure. The dissection of the hand is completed by removing the cited tissues also from the dorsal surface of the hand, taking care to divide the different tendon.



**Figure 6 - Left: Dorsal aspect: it is possible to see the spread of tendons of extensor digitorum muscle. Middle: Medial aspect: the adductor pollicis muscle was separated from the first dorsal interosseous muscle. Right: Palmar aspect. 1: Extensor retinaculum. 2: Tendon of extensor digitorum muscle. 3: Intertendinous connections. 4: Tendon of extensor digiti minimi muscle. 5: Tendon of extensor pollicis longus muscle. 6: First dorsal interosseous muscle. 7: Adductor pollicis muscle. 8: Palmar aponeurosis. 9: Flexor retinaculum. 10: Tendon of palmaris longus muscle. 11: Abductor pollicis brevis muscle. 12: Flexor pollicis brevis muscle. 13: Abductor digiti minimi muscle.**

## 4. Conclusions

The upper limb dissection shows the difference between how a real body appears and how books represent it. The atlases of anatomy represent muscles separated from each other and from the other structures (bones, fasciae), but that is just a simplistic and theoretical view.

Thanks to this experience, we can strongly affirm that the study of anatomy begins with explanation of the teacher, continues with the study on the books and ends with the corpses dissection. We hope that human dissection becomes a common method of study in all Universities because the knowledge of Human Anatomy is essential for all medical doctors.

Moreover, considering the future competition between medical professionals working in different European contexts, we strongly suggest to the Italian Government to implement funds for medical dissection in the Universities in order to provide a better education in our medical schools for Italian young doctors.

## 5. Acknowledgements

AE, LS, GA, SC, CF, IG, MLB, MP, ST and FT were the students from the UoP that performed the course at Malta. CP was the supervisor of these students at the UoM. GT was the supervisor of these students in writing this report. We thank Prof. Francesco Cappello from the UoP for giving to the students the opportunity to perform this stage at the UoM.

## References

1. Costantino C, Maringhini G, Albegiani V, Monte C, Lo Cascio N, Mazzucco W. Perceived need for an international elective experience among Italian medical residents. *Euromediterranean Biomedical Journal* 2013, 8 (3):10-15
2. *Anatomia del Gray – Le basi anatomiche della pratica clinica – Elsevier*
3. *Prometheus – Atlante di anatomia umana – Edises*
4. Pomara, Karch, Fineschi: *Forensic autopsy – A handbook and atlas – CRC Press Color atlas of anatomy – Williams&Wilkins*
5. Carpenter MB: *Human Neuroanatomy seventh edition. The Williams & Wilkins Company. Baltimore 1976.*