

Transanal endoscopic video-assisted (TEVA) resection of early rectal lesions using a SILS port

A single center experience



Ann. Ital. Chir., 2016 87: 36-40
Published online 30 November 2015
pii: S0003469X16024520
www.annitalchir.com

Calogero Cipolla, Giuseppina Ferro, Giuseppa Graceffa, Lorenzo Morini, Giuseppina Guercio, Salvatore Vieni, Gianni Pantuso

Department of Oncology, Division of General and Oncological Surgery, University of Palermo, AUO Policlinico "Paolo Giaccone", Palermo, Italy

Transanal endoscopic video-assisted (TEVA) resection of early rectal lesions using a SILS port. A single center experience.

AIM: Transanal Endoscopic Video Assisted (TEVA) excision using a Single Incision Laparoscopic Surgery SILSTM-Port represents a safe and complete technique to remove benign lesions of the rectum not treatable by endoscopy and malignant rectal lesions at early stage. It is a valid alternative to transanal endoscopic microsurgery (TEM), to conventional transanal surgery and to transabdominal resection.

METHODS: In our operating Unit we performed a resection of 8 voluminous adenoma in the rectal ampulla with SILSTM-Port.

RESULTS: The mean age of the patients was of 51.1 years, the mean BMI was 23. There were not intra or post-operative complications nor conversions to conventional transanal excision or major resective surgery. The postoperative course was normal. The average time of hospitalization was 3 days.

CONCLUSIONS: TEVA is easier to perform than TEM and does not require a long training and specific and expensive material as the TEM does. TEVA might go to replace completely TEM.

KEY WORDS: Rectal tumours, SILS, TEVA

Introduction

Transanal Endoscopic Video Assisted (TEVA) excision using Single Incision Laparoscopic Surgery (SILS) port represents a complete, safe and technically undemand-

ing procedure to locally remove adenomas and cancerous rectal lesions at an early stage ¹ TEVA imposes itself as a viable alternative to demolitive intervention such as anterior resection of the rectum or the abdominoperineal amputation, with limited hospital stay, morbidity and mortality ² and to less invasive intervention, such as endoscopic submucosal dissection (ESD) – which are difficult to achieve especially when the lesion is large and at a short distance from the anal verge – and transanal endoscopic microsurgery (TEM). The latter, designed by Buess in 1980 ³ requires a specific equipment, with high cost, and a high learning curve. To date we had 8 cases of voluminous adenoma resection in the rectal ampulla using SILS port and below we present our experience.

Pervenuto in Redazione Luglio 2015. Accettato per la pubblicazione Ottobre 2015

Correspondence to: Calogero Cipolla, MD, University of Palermo, AUO Policlinico "Paolo Giaccone", Department of Oncology, Division of General and Oncological Surgery, Via del Vespro 129, 90127 Palermo, Italy (e-mail: calogero Cipolla@virgilio.it)

Materials and Methods

Between November 2011 and June 2014, in our operating unit TEVA with SILS™-Port (® Covidien, Mansfield MA, USA) was performed for 8 patients. In all cases, the preoperative diagnostic work up included a colonoscopy, multiple biopsies of the lesions for histological diagnosis, an endorectal ultrasonography (EUS) of the rectal wall and a computed tomography (CT) of the thorax and the abdomen with a contrast medium. The procedure has been performed by the same surgical team under general anesthesia. The day before the surgery all patients underwent an adequate bowel wash out, a thromboembolic prophylaxis administering low molecular weight heparin 2 hours prior to surgery and antibiotic prophylaxis using 2 g cephalosporin at the induction of general anesthesia. All patients were placed in lithotomy position, except in one patient which presented a massive lesion of the posterior rectal wall measuring 10 cm in the maximum diameter. In this patient the jackknife position was preferred in order to avoid blood collections that would have hindered optimal view. No digital rectal dilatation was needed. We placed the monoport SILS in the anal canal, securing it to the perineal skin with a 2/0 non absorbable suture, and we created the working chamber by constant insufflation of CO₂ at a pressure of 12-14 mmHg with insertion of the device into the orifices of three 5 mm surgery trocars. To achieve the view, a 5 mm optic 30° has been

used. The complete resection of the lesions was performed by using radio frequency current, bipolar current and laparoscopic grasper (Fig. 1).

Results

Of the 8 patients, 5 were females and 3 males, their mean age was 51.1 years (ranging from 33 to 65); mean BMI was 23 (range: 20-30 kg/m²). In 5 cases the histopathological preoperative diagnosis was of villous adenoma with high-grade dysplasia, whereas in 3 cases of tubular adenoma with low-grade dysplasia. EUS of the rectal wall showed in all cases no infiltration of the muscular layer or enlarged lymph nodes (Table I).

The mean operative time was 70 minutes (range: 50-90 minutes). In all cases the resection of polypoid growths was radical, with macroscopically free lateral margin of at least 5 mm and deep margin extended into the mesorectal fat in the posterior lesions (Fig. 2). The maximum diameter of the lesions ranged between 3 and 10 cm. The average distance of the lower margin of the lesion from the anal verge was 6 cm (range: 4-11 cm). In 5 patients the lesion was located in the posterior rectal wall, whereas in the other 3 cases on the anterior wall. There were not problems related to the presence of smoke into the rectal ampulla due to the intermittent use of a "luer lock", placed on one of the canulas of the device. Full-thickness excision of the lesions

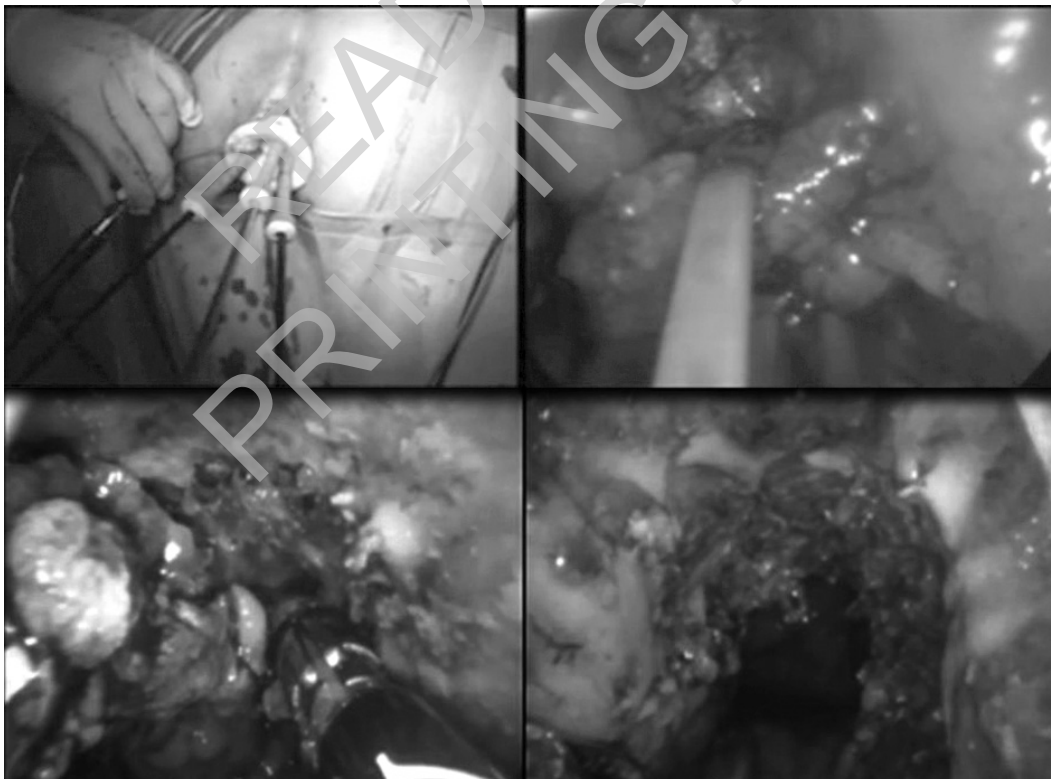


Fig. 1: Polypoid lesion of the posterior rectal wall removed in jackknife position.

TABLE I - Demographics and clinical characteristics of the patients.

Patient	A	B	C	D	E	F	G	H
Age	53	61	33	46	65	60	40	51
Sex	F	M	F	F	F	M	F	M
BMI	24	23	21	30	22	26	20	21
Patient's position	jackknife	lithotomy	lithotomy	lithotomy	lithotomy	lithotomy	lithotomy	lithotomy
Histological results at preoperative biopsy	V.A.	V.A.	T.A.	T.A.	V.A.	V.A.	V.A.	T.A.
	H.G.D.	H.G.D.	L.G.D.	L.G.D.	H.G.D.	H.G.D.	H.G.D.	L.G.D.
Endorectal Ultrasonography	N.F.M.	N.F.M.	N.F.M.	N.F.M.	N.F.M.	N.F.M.	N.F.M.	N.F.M.
Abdominal Computed Tomography	N.F.M.	N.F.M.	N.F.M.	N.F.M.	N.F.M.	N.F.M.	N.F.M.	N.F.M.

BMI: body mass index; V.A.: Villous Adenoma; T.A.: Tubular Adenoma; H.G.D.: High Grade Dysplasia; L.G.D.: Low Grade Dysplasia; N.F.M.: negative for malignancy

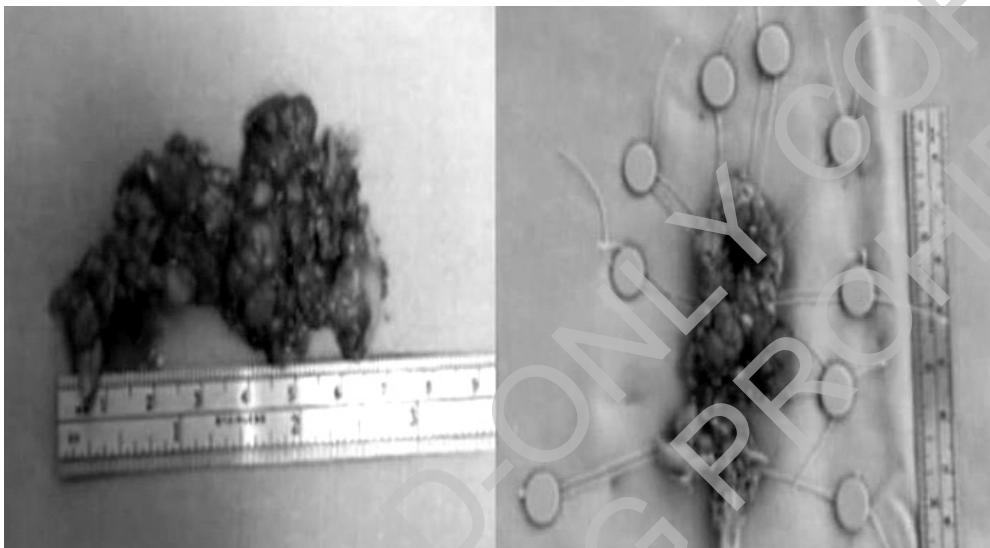


Fig. 2: Surgical specimen of the lesion.

was achieved and the closure of the wall defect after resection was not needed. There were neither intra or postoperative complications (such as spread of CO₂ in other districts or bleeding), nor conversion to conventional transanal excision or major resective surgery. The postoperative period showed no thermal increases and painful manifestations. The bowel canalization and re-feeding occurred on average in the second postoperative day; the average postoperative hospital stay was of 3 days (range 3 to 5 days). Notably, the final histological examination confirmed the histological diagnosis of the pre-operative biopsies. There were no cases of fecal incontinence or anorectal dysfunction. The average follow-up was 19.7 months (ranging from 9 to 36 months) and in none of the cases local recurrence was highlighted. In one of the 8 patients (E), during the examination carried out one month after the surgery, a small non suspicious tissue proliferation was detected in the surgical scar. The lesion was radically removed and the histopathological diagnosis was of granulomatous scar tissue. No further lesions were found in this patient at the successive controls (Table II).

Discussion

The local treatment of benign not endoscopically treatable rectal lesions or malignant lesions at an early stage (T1N0) has been an object of study for a less invasive approach for long time. Transanal excision is a viable alternative for local resection of these lesions but limited to lesions occurring within 5-8 cm from the anal verge⁴, because lesions in the middle or upper portion of the rectum are not easily accessible. Buess overcame the limits of TAE³ with the introduction of TEM, thus allowing the resections of rectal lesions not accessible by the transanal approach, thanks to a specific instrumentation and better visibility in the surgical field. TEM used in selected patients as the elderly can give important results in terms of reduction of surgical trauma, preservation of anatomical integrity and resolution of symptoms also offering a good quality of life⁵⁻⁶. However, contrarily to what happens with laparoscopy, the instruments are placed in parallel planes, and this makes difficult the exposure of the operative field and requires a long and frustrating training. In fact, although

TABLE II - Results of the eight TEVA

Patient	A	B	C	D	E	F	G	H
Operative time	90 min	77 min	75 min	80 min	60 min	50 min	70 min	60 min
Maximum diameter of the lesions	10 cm	6 cm	3 cm	4 cm	6 cm	5 cm	3 cm	5 cm
Distance from anal verge	4 cm	4 cm	6 cm	7 cm	11cm	5 cm	8 cm	4 cm
Complications	no	no	no	no	no	no	no	no
Postoperative hospital stay	5 days	4 days	3 days	4 days	3 days	3 days	4 days	3 days
Fecal incontinence	no	no	no	no	no	no	no	no
Ano-rectal dysfunction	no	no	no	no	no	no	no	no
Post-operative histological results	V.A. H.G.D.	V.A. H.G.D.	T.A. L.G.D.	T.A. L.G.D.	V.A. H.G.D.	V.A. H.G.D.	V.A. H.G.D.	T.A. L.G.D.
Follow-up	no local recurrence	no local recurrence	no local recurrence	no local recurrence	no local recurrence	no local recurrence	no local recurrence	no local recurrence

V.A.: Villous Adenoma; T.A.: Tubular Adenoma; H.G.D.: High Grade Dysplasia; L.G.D.: Low Grade Dysplasia; G.S.T.: Granulomatous Scar Tissue.

this procedure has been employed for more than twenty years, it has not been easily widespread in the field of colon rectal surgery, because of the high cost of the equipment, the long training required and the limited indications, which means that TEM became a technique performed at only a few specialized centers ⁷.

As it can be seen in the literature, TEVA represents an efficient alternative. It was introduced for the first time by Atallath in 2009 ⁶, by employing a device called SILS™-Port (© Covidien, Mansfield MA, USA), that is designed to be used in a wide variety of laparoscopic procedures. TEVA is a new surgical method that applies the principles of TEM and the use of single port. It is also called Transanal Minimally Invasive Surgery (TAMIS) ⁸ or Transanal Single Port Microsurgery (TSPM) ⁹.

TEVA takes advantage of the fact that it is a surgical procedure of easy application in any surgical center equipped good laparoscopic instrumentation. With our initial experience we want not only to highlight its real benefits but also to draw attention to some technical details that might help to realize this procedure. Despite the lithotomy position is the most used ¹⁰ for transanal minimally invasive surgical approach, in one case we preferred to place the patient in jackknife position, as the lesion was about 10 cm in the maximum diameter and localized in the posterior rectal wall. Thus, being the lesion on the upper level compared to that of the surgeon, its excision was easily performed, both for a superior counter traction applied by the surgeon with the tools, and for a vision that could be more clear from possible bleeding collected at the bottom and not on the top work. Therefore, for the same principle, in general the position of the patient should be lithotomy, prone or lateral in relation to the implant base of the neoplasm.

The best benefits of TEVA compared to TEM are mainly due to the instruments used to access in the anal canal. The SILS port, being constituted by a thermo-

plastic elastomer, is flexible and perfectly adaptable inside the anal canal. This represents a great advantage over the instrumentation needed for TEM, which involves the use of a rigid sigmoidoscope of 40mm/30mm, which entails the need to perform an anal dilatation. The SILS™-Port, with its 30mm diameter, allows a safe and atraumatic transanal access, that does not require the execution of this maneuver, thus avoiding the possibility of a sphincter dysfunction in the short or long term, represented by the reduction of the anal sphincter tone ¹¹. TEVA is still a technique at its initial stage but the number of cases treated and the long term follow-up provide excellent perspectives for a replacement of TEM in the coming years.

Conclusions

From our personal, albeit preliminary, experience and the studies mentioned in the literature we can deduce that TEVA offers a viable alternative to TEM, conventional transanal surgery and transabdominal resection and provides a relatively inexpensive platform with excellent exposure and adaptability for local transanal excision for middle and upper rectal lesions. Experienced laparoscopic surgeons will be able to perform the procedure with minimal training by applying principles of both transanal surgery and single port laparoscopy. The approach allows the benefits of traditional local transanal resection, avoiding technical limitations and excessive cost of TEM ¹². This procedure is addressed to local and safe excision of benign and malignant lesions of the rectum at an early stage (T1, N0), with the maintenance of oncological principles and the reduction of the obstacles that limited the wide implementation of TEM, still keeping its benefits. However, one of the limitations of TEVA is the short current follow-up available on patients treated, to

prove the effectiveness of the procedure especially relatively to the rate of complications, recurrence and overall survival.

Riassunto

L'escissione chirurgica endoscopica transanale video-assistita (TEVA) mediante SILS™-Port (Single Incision Laparoscopic Surgery) si è affermata come una tecnica valida per la rimozione completa di lesioni benigne del retto non trattabili endoscopicamente e per le neoplasie maligne del retto in fase precoce. La TEVA rappresenta una valida alternativa alla escissione microchirurgica transanale (TEM), alla chirurgia transanale convenzionale ed alla resezione transaddominale.

Nella nostra Unità Operativa sono state effettuate con successo 8 resezioni di voluminosi adenomi del retto impiegando la tecnica TEVA con il SILS™-Port.

L'età media dei pazienti è stata di 51,1 anni, il BMI medio è stato di 23. Non sono state registrate complicanze post-operatorie né conversioni verso interventi resettivi maggiori per via trans-addominale. Il decorso post-operatorio dei pazienti è stato regolare. Il tempo medio di ospedalizzazione è stato di 3 giorni.

I risultati della nostra esperienza, sia pure poco numerosa, in ci consentono di valutare la tecnica TEVA con SILS™-Port più semplice da realizzare rispetto alla TEM. La metodica infatti non richiede lunghi periodi di apprendimento né l'impiego di materiale costoso come quello impiegato nella TEM.

References

1. Ragupathi M, Haas EM: *Transanal Endoscopic Video-Assisted Excision: Application of Single-Port Access*. JSLS, 2011; 15:53-8.
2. Dias AR, Nahas CS, Marques CF, Nahas SC, Cecconello I: *Transanal endoscopic microsurgery: Indications, results and controversies*. Tech Coloproctol, 2009; 13:105-11.
3. Buess G, Kipfmüller K, Hack D, Grüssner R, Heintz A, Junginger T: *Technique of transanal endoscopic microsurgery*. Surg Endosc, 1988; 2:71-5.
4. Moore JS, Cataldo PA, Osler T, Hyman NH: *Transanal endoscopic microsurgery is more effective than traditional transanal excision for rectal masses*. Dis Colon Rectum, 2008; 51:1026-30.
5. Quarto G, Siverio L, Benassai G, Bucci L, Desiato V, Perrotta S, Benassai G, Massa S: *TEM in the treatment of recurrent rectal cancer in elderly*. Ann Ital Chir, 2014; 85:101-05.
6. D'Ambrosio G, Balla A, Mattei F, Quaresima F, De Laurentis F, Paganini AM: *Quality of life after Endoluminal Loco-Regional Resection (ELRR) by Transanal Endoscopic Microsurgery (TEM)*. Ann Ital Chir 2015; 86: 56-60.
7. McCloud JM, Waymont N, Pahwa N, Varghese P, Richards C, Jameson JS, Scott AN: *Factors predicting early recurrence after transanal endoscopic microsurgery excision for rectal adenoma*. Colorectal Dis, 2006; 8:581-85.
8. Atallah S, Albert M, Larach S: *Transanal minimally invasive surgery: Aiant leap forward*. Surg Endosc, 2010; 24:2200-205.
9. Lorenz C, Nimmesgern T, Back M, Langwieler TE: *Transanal single port microsurgery (TSPM) as a modified technique of transanal endoscopic microsurgery (TEM)*. Surg Innov, 2019; 17:160-63.
10. Azimuddin K, Riether RD, Stasik JJ, Rosen L, Khubchandani IT, Reed JF 3rd: *Transanal endoscopic microsurgery for excision of rectal lesions: Technique and initial results*. Surg Laparosc Endosc Percutan Tech, 2000; 10:372-78.
11. Kennedy ML, Lubowski DZ, King DW: *Transanal endoscopic microsurgery excision: Is anorectal function compromised?* Dis Colon Rectum, 2002; 45:601-04.
12. Middleton PF, Sutherland LM, Maddern GJ: *Transanal endoscopic microsurgery: A systematic review*. Dis Colon Rectum, 2005; 48:270-84.