

## Abdominal Desmoid Tumors: A Case Report Anatomical Aspect

<sup>1</sup>F. Carini, <sup>2</sup>G. Cocorullo, <sup>1</sup>C. Lo Piccolo and <sup>1</sup>V. Valenza

<sup>1</sup>Department of Experimental Medicine, <sup>2</sup>Department of General and Urgent Surgery,  
University of Palermo, Sicilia, Italy

**Abstract:** Desmoid tumors are rare neoplasms of the soft tissues which develop from fibrous tissues and are histologically characterized by fibroblastic proliferation. They tend to recur at the local site of a previous condition and they do not metastasize. The general clinical presentations manage to simulate the malignant neoplasia from the same histological group. The authors have may have these tumors in the local area on the abdominal wall which can be treated by a large surgical cut in order to avoid recurrence.

**Key words:** Dermoid tumor, abdominal wall, soft tissue, anatomical aspect, fibroblastic

### INTRODUCTION

Desmoid tumors are fibromatosis tumors which originally comes from the structure of the fibrous tissue. The term, “desmoid”, was coined by Muller in 1838 for the formation of the texture of the tendon. Actually, in 1832, MacFarlane had already described two cases of fibromatoses tumors in the abdominal wall. Desmoid tumors are histologically characterized by a fibroblastic proliferation without a wrapping membrane and, even if they are not metastasized, they do not cause intrusive damage. This is why it may sometimes be particularly difficult to remove them. This is a rare condition which is quite frequent in the abdominal wall, although they can be found in other places like the mesentery, a muscle which supports the shoulder blade as well as the trapezius, the chest, muscles and other lower limbs (Church *et al.*, 2008; Cohen *et al.*, 2008).

They are highly aggressive and they invade adjacent tissues and organs. They may grow slowly and they do not invade lymph nodes nor do they metastasize. They do tend to recur after surgery and they rarely turn into fibrosarcoma (Collins *et al.*, 2008).

### MATERIALS AND METHODS

Recently, the case of desmoid tumors in the abdominal wall has been analyzed and since there is still very little information on this subject, we have decided to take the opportunity in showing and examining the medical cases, pathological and treatment.

One medical case is of A.R., aged 30 and married with negative family history. She had two caesarean sections. The following is her family case history: the patient noticed a lump in the gastric area where there was a scar thanks to the caesarean section. This lump was not visible but taken into consideration palpatory and its size was about 10×7 cm. No symptoms were diagnosed. In the following weeks, the lump increased to 12×10 cm and was therefore visible. Symptoms did not occur at first but then there was an increase of urine and serious pain.

Results of the test: generally good skin conditions and pink mucous as well as normal blood chemicals and ecg.

General objective of the exam: Check up. The umbilical xiphoid line was flat pubic, the umbilical scar and skin were normal and introflexed. The scar from surgery can be seen above the pubic area thanks to the caesarean section. At first, it looked like it had recovered, but then it increased by 2 cm, therefore being 10×8 cm.

The lump looked fibrous and hard, the skin surface was smooth and it contracted the muscles in the abdominal wall as it was a bit painful when it is pressed. The abdomen was manageable for all of the rest of the site.

The beating was normal except near the lump where the skin appeared thicker.

The abdominal screening was done in the lower and central abdominal area and there was a homogeneous solid, wavy repetition of sound of about 10×8. The sound was also surrounded by a thick hyperecogen. This new formation presumes continuous formations with the

abdominal wall. As far as the diagnosis of the new formations in the abdominal wall is concerned, surgery will be held and it will consist of surgery of fibrous tissues in the abdominal wall. An incision under the navel, which round lump of 10×8 of solid fiber is situated under the skin will be done. The lump is an integral part of the fibrous tissue and all of the other layers of the fibrous tissues as well as the peritoneum which is underneath will be surgically removed. The incision will not harm the tissue so that there will be a closure in the layers of the wall. Pathological findings include the piece that was surgically removed which was 10×8 with a smooth surface and a solid fiber. Next to the mass, there were areas adhering and medial parts of the rectal muscles; the above mentioned cut has a homogenous, fibrous, whitish structure which does not contain wrapping membrane as well as solid fiber. There are areas and medial portions of the muscles of the rectum adhering near the mass. Such a cut of the mass shows a homogenous, fibrous, whitish structure without a wrapping membrane. The histological exam included proliferation having a wider abnormal shape at the end of the fibroblastic dispersed elements.

#### RESULTS AND DISCUSSION

Desmoid tumors are so rare, that there is not much literature on the matter (Cavenago *et al.*, 2002; Barbella and Fox, 1996; Schmidt *et al.*, 1991). They are quite common in the abdominal area even though they can also be found in other parts. They are more common among women before menopause and the reason for this is that perhaps the patients' hormones need to adjust, having found levels of gonatropine hormone in various desmoid tumors. This theory confirms the fact that there has been a regression of the new formations after menopause. Another solution is to surgically cut the abdominal wall.

Desmoid tumors are hard and whitish which seep into the adjacent structures. Histologically (Fig. 1) it is characterized by infiltrations and substitutions of the fatty and muscular tissues on behalf of the fibrous tissues of various cells (Welsh *et al.*, 1996). Near the new formations, the cells of the striated muscle appear normal whereas the central area tend to lose the striated part. In fact, they look protoplasmatic polynucleate and as if they were giant cells.

The symptoms of desmoid tumors are not clear and most of the patients discover the lump by chance or when they become bigger. They rarely cause great pain or the feeling of urinating when compressed against the bladder. The situation becomes more complicated when the sarcomatosis degenerates and recurrence occurs.

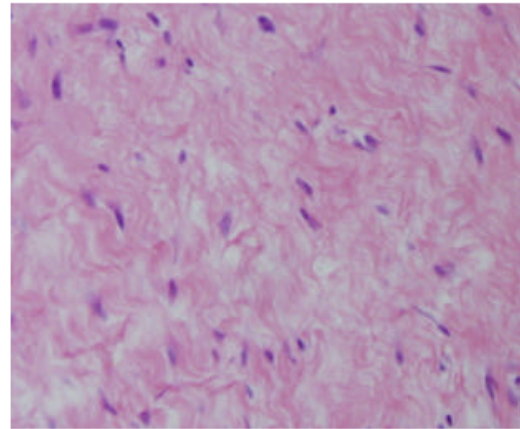


Fig. 1: Photomicrograph demonstrantig spindle cell proliferation withing atypia 100X

#### CONCLUSION

The diagnosis of these new formations is histological. The prognosis of the desmoids tumors of the abdominal wall is positive because they have never undergone metastasis, even though they can be intrusive. In order to avoid recurrence in the local site, surgery of the neoplasia is feasible. The operation is done by placing a net due to the great removal of the abdominal muscle and the possibility of getting postoperative incisional hernia.

Although, some options might include surgery along with radiation treatment, the most effective medical option is total surgical removal. In case of recurrence or excessive removal of the abdominal wall, the doctor must choose the best and effective therapy in order to control the pathology in which is usually aggressive in the local site.

#### REFERENCES

- Barbella, R. and I.M. Fox, 1996. Recurring desmoid tumor of the foot: A case study. *Foot Ankle Int.*, 17: 221-225.
- Cavenago, C., G. Bianchi, M. Marchese and B. Piatti, 2002. Extra abdominal desmoid tumor: A case report localized in the lower limb. *G.I.O.T.*, 28: 176-80.
- Church, J., C. Lynch, P. Neary, L. Laguardia and E. Elayi, 2008. A Desmoid Tumor-Staging System Separates Patients with Intra-Abdominal, Familial Adenomatous Polyposis-Associated Desmoid Disease by Behavior and Prognosis. *Dis. Colon Rectum.*, 6: 39-44.

- Cohen, S., D. Ad-El, O. Benjaminov and H. Gutman, 2008. Post-traumatic soft tissue tumors: Case report and review of the literature a propos a post-traumatic paraspinal desmoid tumor. *World J. Surg. Oncol.*, 29 (6): 28.
- Collins, D., E. Myers, D. Kavanagh, G. Lennon and E. McDermott, 2008. Mesenteric desmoid tumor causing ureteric obstruction. *Int. J. Urol.*, 15 (3): 261-262.
- Schmidt, D., 1991. Infantile desmoids type fibromatosis. Morphological features correlate with biological behaviour. *J. Pathol.*, 164: 315-319.
- Welsh, R.A., 1996. Intracytoplasmic collagen formation in desmoids fibromatosis. *Am. J. Pathol.*, 49: 515-535.