

p53 and Ki-67 expression in renal cell carcinomas of pregnant women and their correlation with prognosis: a pilot study

G. POMARA*, G. SALINITRI*, G. NESI†, E. MAIO†, A. MINERVINI‡, A.M. GAMMAZZA§, F. FRANCESCA*, F. CAPPELLO§ & C. SELLI*

*Department of Surgery, Urology Unit, S. Chiara Hospital, Pisa, Italy; Departments of †Pathology and ‡Urology, University of Florence, Florence, Italy; and §Department of Experimental Medicine, University of Palermo, Palermo, Italy

Abstract. Pomara G, Salinitri G, Nesi G, Maio E, Minervini A, Gammazza AM, Francesca F, Cappello F, Selli C. p53 and Ki-67 expression in renal cell carcinomas of pregnant women and their correlation with prognosis: a pilot study. *Int J Gynecol Cancer* 2007.

In the present study, we reported two cases of renal cell carcinoma (RCC) diagnosed in pregnant women (Pt) that were submitted to radical nephrectomy, in both cases within the fourth month. The patients, after 13 and 3 years, respectively, did not show evidence of recurrent disease. We performed an immunohistochemical study on RCC specimens in comparison to seven age-matched controls (Cl). The panel of antibodies included Ki-67, p53, bcl-2, ER, PgR, PCNA, and IGF-1. We describe a difference in the expression of p53 and Ki-67. Specifically, p53 was highly expressed in RCC of both Pt but scarcely present or absent in Cl; by contrast, Ki-67 was hardly expressed or negative in RCC of both Pt, being commonly positive in Cl. These results may correlate with a good outcome of the disease in Pt. Although the limited number of cases did not permit any statistical evaluation, we postulate that these differences have not to be underestimated since they may disclose a correlation between pregnancy and biological behavior of tumoral disease. Further study may (dis)prove this hypothesis.

KEYWORDS: IGF-1, Ki-67, pregnancy, p53 protein, renal cell carcinoma.

Pregnancy and renal cell carcinoma (RCC) share the fact that they are tolerated by an intact immune system⁽¹⁻³⁾. Moreover, there are evidences in the literature suggesting that the number of births could influence the risk of RCC compared with nulliparous women, the risk being nearly two times higher among pluri-parous women⁽⁴⁾.

RCC is a rare tumor in fertile women, and its diagnosis during pregnancy is even rarer, with 35 reported cases in a literature review of 1986⁽¹⁾ and about 20 added during the following 20 years⁽⁵⁻¹¹⁾.

In the present work, we examined retrospectively two female patients with asymptomatic low-stage renal tumors discovered at routine ultrasound exami-

nation during pregnancy, comparing them to a series of age-matched controls.

Materials and methods

We examined histologic specimens from both a 25- and a 32-year-old female patient who were found to have left-sided renal tumors (Pregnant tumors, Pt) during routine ultrasound examination of their abdomens for pregnancy. They both underwent nephrectomies at the fourth month of pregnancy through a flank approach, and they completed their pregnancies at term. The tumors measured 2.5 and 3 cm in maximum diameter, respectively, and the staging for both cases was pT1 (following the 2002 guidelines of International Union Against Cancer). Further examinations disclosed no evidence of metastatic disease. These patients have been followed for 13 and 3 years, respectively, and there has been no evidence of relapse.

Address correspondence and reprint requests to: Giorgio Pomara, MD, PhD, Department of Surgery, Urology Unit, S. Chiara Hospital, Via Roma 67, 56126 Pisa, Italy. Email: g.pomara@libero.it

The first and second authors contributed equally to the article.

doi:10.1111/j.1525-1438.2007.00962.x

As controls, we selected seven fertile female patients aged between 25 and 35 years presenting pT1 G1–2 N0 M0 RCCs (controls, CI) treated with radical nephrectomy during a 20-year period. All the CI were incidentally discovered and were asymptomatic RCC, confined within the renal capsule, with no evidence of local recurrence during the scheduled follow-up evaluation.

The specimens were obtained by surgical resection in all cases and fixed in 10% buffered formalin before being embedded in paraffin. Hematoxylin and eosin-stained sections from each specimen were reviewed by three pathologists (G.N., E.M., and F.C.) to confirm the histologic diagnosis. Sections of 4 µm for each lesion were obtained for immunohistochemical analyses. All sections were deparaffinized in Bio-Clear (Bio-Optica, Milan, Italy), hydrated with graded ethanol concentration, and rinsed in distilled water. To block endogenous peroxidase activity, slides were treated with 3.0% hydrogen peroxide in distilled water for 20 min. The sections were incubated with the following antibodies for 1 h at room temperature: anti-bcl-2 protein (clone 124, DakoCytomation, Glostrup A/S, Denmark; dilution: 1:40); anti-Ki-67 antigen (clone MIB-1, DakoCytomation; dilution: 1:80); anti-p53 protein (clone D07, DakoCytomation; dilution: 1:40); anti-ER (clone 6F11, Ventana Medical Systems, Tucson, AZ; dilution: 1:100); anti-PgR (clone 16, Ventana Medical Systems; dilution: 1:100); anti-PCNA (clone PC10, DakoCytomation; dilution: 1:100); and anti-IGF-1 (clone BM23, Cymbus Biotechnology, Hampshire, UK; dilution: 1:100).

All sections designated for heat-induced epitope retrieval were placed in a 10 mM/L citrate buffer, pH 6.0, heated in a microwave oven for histology (Microwave MicroMed T/T Mega, Milestone, Bergamo, Italy) for 35 min, followed by cooling for 20 min at room temperature. Staining was achieved using a biotin-conjugated anti-mouse and anti-rabbit secondary antibody (UltraVision, Fremont, CA), and subsequently, the streptavidin–peroxidase (UltraVision) was applied to all sections. The bound antibodies were visualized using 3,3' diaminobenzidine (BioGenex, San Ramon, CA) as the chromogen. Nuclei were slightly counterstained with Mayer's hematoxylin. Negative control was performed by substituting the primary antibody with a nonimmune serum at the same concentration. For positive control, a follicular lymphoma section was used for bcl-2 protein and Ki-67 antigen. For p53, we used a section of squamous cell laryngeal carcinoma with nuclear reactivity; for ER and PgR, human breast tumor sections known to be positive for these steroid hormone receptors; and for IGF-1, human kidney

tissue. Overall tissue expression was scored as follows: 0, no staining; 1+, 1–10% staining; 2+, 11–50% staining; and 3+, 51–100% staining. Immunohistochemical results were evaluated in a blinded manner without knowledge of the clinical data.

Results

In both Pt cases, histopathologic regressive aspects were documented, consisting of fibrosis, lymphocytic infiltration, cystic aspect, and hemorrhagic necrosis (Fig. 1A).

A strong expression of p53 protein was detected in both Pt (Fig. 1B), whereas it was present in only one of the seven CI and with a light immunoreactivity (Table 1). By contrast, occasional Ki-67-positive cells were observed in only one of the Pt (Fig. 1C), while Ki-67 positivity was higher in all but one CI.

Concerning the other markers, no consistent differences of expression of studied markers were found (Table 1). In particular, ER and PgR were present in one Pt and in three of seven CI, bcl-2 in one Pt and four of seven CI, and IGF-I in both Pt and five of seven CI (Fig. 2A, B).

Discussion

To our knowledge, there is no evidence in the literature to suggest that pregnancy influences the clinical course of RCC, although it has been reported that pregnancy and cancer are biologic conditions in which antigenic tissue is tolerated by immune system^(1,12). In particular, a condition of immunosuppression, characterized by decreased cellular immunity, circulating serologic blocking factors and hormones with immunosuppressive effects, allows maternal tolerance of the fetus.

The number of births could influence the rise of RCC compared with nulliparous women, the risk being nearly two times higher among pluriparous women⁽⁴⁾. The regressive features of renal carcinomas consist of extensive fibrosis with marked lymphocyte; moreover, plasma cell infiltrate is frequent and could be ascribed to the high levels of hormones (specifically progesterone) during pregnancy. Abdominal sonography performed during the first trimester allows the diagnosis of low-stage tumors in asymptomatic patients.

We presently investigated if there were biological differences between Pt and CI by immunohistochemistry.

The Ki-67 nuclear antigen is expressed at all phases of the cell cycle in a proliferating cell and represents an excellent marker of cell proliferation in histologic specimens; the p53 tumor suppressor gene has been proved to participate in cellular DNA damage, resulting in

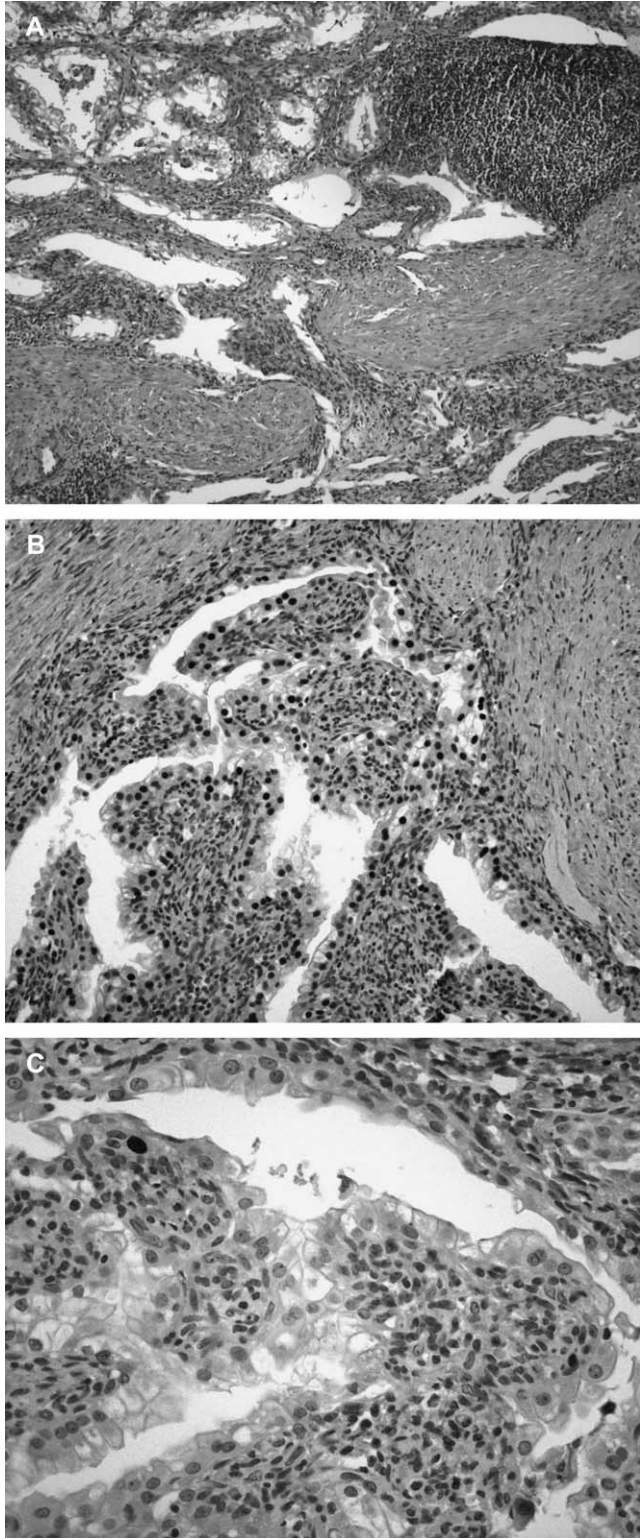


Figure 1. A) Pt display extensive fibrosis and marked lymphocytic infiltration (Hematoxylin–eosin, original magnification $\times 100$). B) Nuclear immunopositivity for p53 oncoprotein in a case of Pt (diaminobenzidene, original magnification $\times 200$). C) Occasional nuclear Ki-67 immunopositivity in Pt (diaminobenzidene, original magnification $\times 400$).

Table 1. Comparison of immunohistochemical results between the two cases of renal cell tumors diagnosed in pregnant women and the seven age-matched controls (CI)

	Pregnant women		CI						
	A	B	1	2	3	4	5	6	7
PCNA	+	+	+	+	+	+	+	+	+
Ki-67	\pm	-	++	++	++	+	++	+	-
ER	+	-	-	+	++	-	-	+	-
PgR	+	-	-	-	++	-	+	+	-
p53	+++	+++	+	-	-	-	-	-	-
Bcl-2	++	-	+	+	+	++	-	-	-
IGF-1	+++	+++	++	-	-	++	++	++	++

either growth arrest or apoptosis. Wild-type (wt) p53 has a short half-life, and it is commonly negative at immunohistochemistry; by contrast, when mutated, p53 accumulates and becomes immunohistochemically

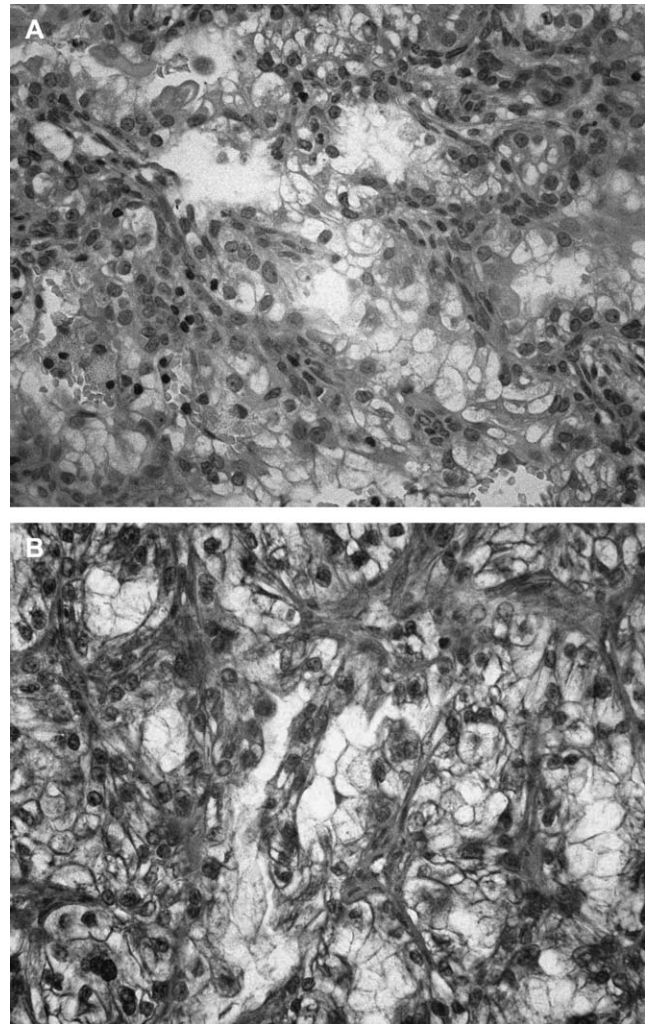


Figure 2. A) Bcl-2 negative staining of tumor cells. Interstitial lymphocytes are positive (LSAB, original magnification $\times 250$). B) High IGF-1 expression in renal carcinoma (LSAB, original magnification $\times 250$).

detectable⁽¹³⁾. Mutated p53 loses its ability to induce apoptosis⁽¹⁴⁾. Recent reports show that p53 mutation is not frequently present in renal carcinoma⁽¹⁵⁾.

We consider of interest the results of immunohistochemistry for p53 and Ki-67. In particular, Pt seem to show higher immunoreactivity for p53 than Cl; by contrast, Ki-67 was scarce or absent in Pt and positive in all Cl except one.

Although intuitively, these discrepancies may be due to an earlier diagnosis and consequently an earlier stage of disease of Pt, we cannot exclude that immunosuppression of pregnancy stimulates growth of mutated p53 cells, while normal immune system could select clones of wt p53 tumoral cells. This hypothesis is supported by recent studies that indicate a proimmunity role of mutated p53 during carcinogenesis^(16,17). In addition, an *in vivo* study showed that p53 may represent a target for CD8+ T cells in a proportion of individuals with cutaneous squamous cell carcinomas⁽¹⁶⁾.

The correlation between increased proliferative index and higher apoptotic index^(18–20) may explain why clones of wt p53 have a higher proliferative index. In addition, simultaneous overexpression of p53 and Ki-67 was reported in early stages of tumorigenesis⁽²¹⁾, while p53-negative and Ki-67-positive tumoral immunophenotypes were already associated significantly with an unfavorable outcome⁽²²⁾.

Finally, concerning the discrepancies between Ki-67 and PCNA immunopositivity, we know that the former antigen is expressed in all cycling cells, whereas the latter reveals only the S-phase fraction; differences between Ki-67 and PCNA scores were already described in breast cancer⁽²³⁾, transitional cell carcinoma⁽²⁴⁾, laryngeal epithelial lesions⁽²⁵⁾, endometrial adenocarcinoma⁽²⁶⁾, and oral leukoplakia⁽²⁷⁾, being commonly accepted that Ki-67 seems to be more consistent for use in therapeutic clinical trials.

In conclusion, this work may be considered a pilot study, and further analyses on wider series could (dis)prove the hypothesis that pregnancy could be related to a better outcome of patients with tumors.

References

- Walker JL, Knight EL. Renal cell carcinoma in pregnancy. *Cancer* 1986;17:2343–7.
- Gleicher N, Deppe G, Cohen CJ. Common aspects immunologic tolerance in pregnancy and malignancy. *Obstet Gynecol* 1979;54:335–42.
- Barber HR. Malignant disease in pregnancy. *J Perinat Med* 2001;29:97–111.
- Lambe M, Lindblad P, Wu J, Remier R, Hsieh C. Pregnancy and risk of renal cell cancer: a population-based study in Sweden. *Br J Cancer* 2002;86:1425–9.
- Selli C, Bartolozzi C, Amorosi A, Carini M. Incidental finding of renal cell carcinoma with histological regressive aspects in a pregnant woman. *Eur Urol* 1988;15:287–9.
- Usta IM, Chammas M, Khalil AM. Renal cell carcinoma with hypercalcemia complicating a pregnancy: case report and review of the literature. *Eur J Gynaecol Oncol* 1998;19:584–7.
- Lesourd B, Siquier J, Haillot O, Lanson Y. Nephrectomy for cancer in pregnant women. Apropos of a case. *J Urol (Paris)* 1997;103:59–61.
- Dakir M, Aboutaieb R, Dahami Z, Ghazli M, Benjelloun S. Kidney cancer and pregnancy. *Prog Urol* 2001;11:1269–73.
- Gladman MA, MacDonald D, Webster JJ, Cook T, Williams G. Renal cell carcinoma in pregnancy. *J R Soc Med* 2002;95:199–201.
- Smith DP, Goldman SM, Beggs DS, Lanigan PJ. Renal cell carcinoma in pregnancy: report of three cases and review of the literature. *Obstet Gynecol* 1994;83:818–20.
- Ceglowska A, Michalski A. Renal cell carcinoma during pregnancy. *Ginekol Pol* 2004;75:145–9.
- Mancuso A, Macri A, Palmara V, Scuderi G, Grosso M, Famulari C. Chromophobe renal cell carcinoma in pregnancy: case report and review of the literature. *Acta Obstet Gynecol Scand* 2001;80:967–71.
- Cappello F, Palma A, Martorana A *et al.* Biological aggressiveness evaluation in prostate carcinomas: immunohistochemical analysis of PCNA and p53 in a series of Gleason 6 (3 + 3) adenocarcinomas. *Eur J Histochem* 2003;47:129–32.
- Cappello F, Bellafiore M, Palma A, Bucchieri F. Defective apoptosis and tumorigenesis: role of p53 mutation and Fas/FasL system dysregulation. *Eur J Histochem* 2002;46:199–208.
- Gurova KV, Hill JE, Razorenova OV, Chumakov PM, Gudkov AV. p53 pathway in renal cell carcinoma is repressed by a dominant mechanism. *Cancer Res* 2004;64:1951–8.
- Black AP, Bailey A, Jones L, Turner RJ, Hollowood K, Ogg GS. p53-specific CD8+ T-cell responses in individuals with cutaneous squamous cell carcinoma. *Br J Dermatol* 2005;153:987–91.
- Espenschied J, Lamont J, Longmate J *et al.* CTLA-4 blockade enhances the therapeutic effect of an attenuated poxvirus vaccine targeting p53 in an established murine tumor model. *J Immunol* 2003;170:3401–7.
- Sarela AL, Verbeke CS, Ramsdale J, Davies CL, Markham AF, Guillou PJ. Expression of survivin, a novel inhibitor of apoptosis and cell cycle regulatory protein, in pancreatic adenocarcinoma. *Br J Cancer* 2002;86:886–92.
- Beardsmore DM, Verbeke CS, Davies CL, Guillou PJ, Clark GW. Apoptotic and proliferative indexes in esophageal cancer: predictors of response to neoadjuvant therapy. *J Gastrointest Surg* 2003;7:77–86.
- Rodel F, Hoffmann J, Grabenbauer GG *et al.* High survivin expression is associated with reduced apoptosis in rectal cancer and may predict disease-free survival after preoperative radiochemotherapy and surgical resection. *Strahlenther Onkol* 2002;178:426–35.
- Kyokane K, Ito M, Sato Y, Ina K, Ando T, Kusugami K. Expression of Bcl-2 and p53 correlates with the morphology of gastric neoplasia. *J Pathol* 1998;184:382–9.
- Rosati G, Chiacchio R, Reggiardo G, De Sanctis D, Manzione L. Thymidylate synthase expression, p53, bcl-2, Ki-67 and p27 in colorectal cancer: relationships with tumor recurrence and survival. *Tumour Biol* 2004;25:258–63.
- Pelosi G, Bresaola E, Rodella S *et al.* Expression of proliferating cell nuclear antigen, Ki-67 antigen, estrogen receptor protein, and tumor suppressor p53 gene in cytologic samples of breast cancer: an immunohistochemical study with clinical, pathobiological, and histologic correlations. *Diagn Cytopathol* 1994;11:131–40.
- Serio G. PCNA/cyclin expression in transitional cell carcinomas of the human bladder: its correlation with Ki-67 and epidermal growth factor receptor immunostainings. *Pathologica* 1994;86:161–6.
- Krecicki T, Jelen M, Zalesska-Krecicka M, Rak J, Szkudlarek T, Jelen-Krzyszewska J. Epidermal growth factor receptor (EGFR), proliferating cell nuclear antigen (PCNA) and Ki-67 antigen in laryngeal epithelial lesions. *Oral Oncol* 1999;35:180–6.
- Gurer IE, Simsek T, Erdogan G *et al.* The utilization of immunohistochemical prognostic factor in endometrial adenocarcinoma: is it cost effective? *Eur J Gynaecol Oncol* 2000;21:197–9.
- Liu SC, Klein-Szanto AJ. Markers of proliferation in normal and leukoplakic oral epithelia. *Oral Oncol* 2000;36:145–51.

Accepted for publication February 8, 2007