



# Minimally invasive mitral valve surgery: state-of-the-art and our experience

Giuseppe Speziale<sup>1\*</sup>, Khalil Fattouch<sup>2</sup>, Vito Romano<sup>3</sup>, Mauro Del Giglio<sup>4</sup>, Alberto Albertini<sup>5</sup>, Chiara Comoglio<sup>2</sup>, Renato Gregorini<sup>6</sup>, Roberto Coppola<sup>7</sup>, Roberta Spirito<sup>8</sup>, Georges Popoff<sup>9</sup>, and Giuseppe Nasso<sup>1</sup>

<sup>1</sup>Department of Cardiovascular Surgery, Anthea Hospital, GVM Care & Research, Via C. Rosalba, 35/37, Bari, BA 70124, Italy

<sup>2</sup>Department of Cardiovascular Surgery, Maria Pia Hospital, GVM Care & Research, Torino, Italy

<sup>3</sup>Department of Cardiovascular Surgery, Villa Torri Hospital, GVM Care & Research, Bologna, Italy

<sup>4</sup>Department of Cardiothoracic and Vascular Surgery, Maria Cecilia Hospital, GVM Care & Research, Cotignola, Italy

<sup>5</sup>Thoracic and Cardiovascular Department, Salus Hospital, GVM Care & Research, Reggio Emilia, Italy

<sup>6</sup>Department of Cardiovascular Surgery, Città di Lecce Hospital, GVM Care & Research, Lecce, Italy

<sup>7</sup>Department of Cardiovascular Surgery, ICLAS, GVM Care & Research, Rapallo, Italy

<sup>8</sup>Clinical Research Unit, E.S. Health Science Foundation, Bari, Italy

<sup>9</sup>Department of Cardiovascular Surgery, Maria Beatrice Hospital, GVM Care & Research, Firenze, Italy

## KEYWORDS

Mitral;  
Mitral repair;  
Minimally invasive cardiac surgery;  
Minimally invasive mitral valve repair

The minimally invasive approach is becoming the standard-of-care for surgery of the mitral valve. As any less invasive strategy, it entails an increased surgical complexity. Standard-of-care mitral repair using the totally videoscopic approach is indeed reproducible; however, few specific data on patients with complex mitral valve disease are available in the published literature. The purpose of the present paper is to provide an overview of the current state-of-the-art in minimally invasive cardiac surgery, and a summary of recent evidence on the topic, with particular regard to the surgical techniques and comparisons with conventional surgery. The experience of the GVM Care and Research network in the field is also briefly reported.

## Introduction

Since the first video-assisted mitral valve repair through a minithoracotomy carried out in 1996<sup>1</sup> and the first minimally invasive mitral valve replacement in the same year, an increasing enthusiasm has accompanied the development of minimally invasive mitral valve surgery.<sup>1,2</sup> The development of minimally invasive approaches in the cardiac surgical domain is indeed characterized by entirely specific challenges, i.e. the need to achieve both optimal myocardial protection and reliable extracorporeal perfusion.<sup>3</sup>

Standardization of the procedures has been the key to success for conventional cardiac surgery.

## Four-step classification of minimally invasive mitral valve surgery

Using an effective analogy with mountaineering, the development of minimally invasive mitral valve surgery and the progression from less to more challenging surgical strategies has been compared with the ascent of Mt Everest. From 'base camp' (lower technical complexity), the surgeon has moved towards more complex settings and surgical installations: the advance has been progressive involving, along the way, the mastering of less complex

\* Corresponding author. Tel + 39 080 5644111, Fax: +39 080 5644678, Email: gspeziale@gvmnet.it

strategies ('comfort zones') through experience and acclimatization.

**Step 1: Direct vision.** This represents the earliest minimally invasive approaches to the mitral valve. These early approaches were essentially based on the modification of previous conventional incisions; the very first clinical results reported low surgical mortality and morbidity, and extracorporeal circulation and aortic clamping times comparable with those observed in conventional surgery. This context made possible the development of intra-aortic balloon occluders, which would be employed in the more advanced levels.

**Step 2: Video-assisted techniques.** The development of the port-access system has been a milestone in this progression. This strategy enabled a further significant reduction in the size of skin incisions. A part of the procedure is performed under a direct vision, and another part is performed under video-assistance. The set-up of the system includes peripheral cannulation, percutaneous transthoracic clamp, and percutaneous retrograde cardioplegia catheter.

**Step 3: Video-directed and robot-assisted techniques.** This step (as well as the fourth) is less extensively used in the practice worldwide. Concerning level 3, a voice-activated robot camera is employed to avoid possible communication errors if the camera is manoeuvred by an assistant. Falk *et al.*<sup>4</sup> published a case series suggesting the feasibility of this approach.

**Step 4: Telemanipulation and robotic surgery.** The very initial experiences in this field occurred in 1998 using the da Vinci Surgical System.<sup>5</sup> In this setting, the surgeon interfaces with the patient using a distant console and controls micro-wrist instruments operating inside the patient's body, in small spaces. Only thoracic ports are needed as an access to the patient's chest, besides a very small minithoracotomy, the sole scope of which is to insert the prosthetic material (mitral prosthetic annuli or prosthetic valves) inside the patient.

### Minimally invasive mitral repair: decision-making issues

Although the criteria for patient selection, the surgical techniques, and the philosophies may differ among surgical groups around the world, the overall clinical results from the published literature are very encouraging and allow an overview of the current state-of-the-art in minimally invasive mitral operations, after almost 20 years of experience with these procedures. Generally speaking, mitral repair itself can be considered as a 'minimally invasive' procedure compared with mitral replacement with either a bioprosthesis or a mechanical valve. A minithoracotomy as a surgical approach to the mitral valve actually facilitates exposure of the mitral valve itself in experienced hands compared with full median sternotomy, since the surgeon's line of vision and work is directly towards the plane of the valve.<sup>6</sup> In median sternotomy, exposure and 'working direction' are less anatomical. This effect is particularly evident for the anterior mitral leaflet, due to its

upward position. Advancement of the camera just inside the left ventricular cavity allows greatest precision in the placement of artificial chordae and in the performance of complex procedures such as papillary muscle repositioning.<sup>7</sup> A better exposure translates into better surgical results, optimal stability of the repair and, therefore, optimal long-term clinical results. This is corroborated by published evidence showing a lesser likelihood of residual mitral regurgitation with the minimally invasive approach than with median sternotomy, and a greater likelihood of successful repair for anterior leaflet disease if, similarly, the minimally invasive approach is employed.<sup>8</sup> It should therefore be considered that, at the end of the learning curve, the minimally invasive approach facilitates the exposure of the mitral valve (*Figures 1–3*).

When it comes to the adoption of a given specific minimally invasive mitral valve surgery protocol, we believe that in choosing one should aim at the optimal standardization and reproducibility in compliance with local conditions. Major problems associated with the development of a minimally invasive mitral valve surgery programme are the technical complexity, the long learning curve, and the hospital costs. Procedures should be planned to be as simple and straightforward as possible. Robotic surgery (although it may offer advantages in terms of skin length incision) undoubtedly entails a growing level of complexity and significant costs due to the nature itself of the high technology equipment and consumables. We draw attention to the importance of performing cost-effective procedures in the current period characterized by a progressive diminishment of state and private funds for healthcare. In this context, future reimbursement policies from both state and private insurance institutions may privilege the procedures that guarantee the best ratio of social costs to measurable indexes of health and to patient reported outcomes (PROs) measuring patient satisfaction. Parameters such as the quality-adjusted life years are increasingly used in this domain, and we believe that studies based on the assessment of such parameters should become part of the long-term armamentarium to evaluate the outcome of patients who undergo mitral valve operations.

Minimally invasive mitral valve surgery is essentially team-based work. Cardiac surgeons need to collaborate with anaesthesiologists, dedicated cardiologists, and intensivists within a heart team. The correct establishment of surgical indications and the adequate planning of the procedures rely on the skills of echocardiographers, who represent a key figure of the minimally invasive surgery programme of an institution. Transoesophageal echocardiography not only allows to precisely determine the mechanism underlying the valve dysfunction, but also assists in the percutaneous cannulation and in the de-airing manoeuvres, and confirms the effectiveness of repair after weaning from cardiopulmonary bypass.

In our opinion, there are a few contraindications to minimally invasive mitral valve surgery performed through a right minithoracotomy. They include: previous surgery within the right pleural space (which may determine severe intrapleural adhesions), non-elective priority (surgeons on duty may not have sufficient expertise or may not have access during night hours to the complete

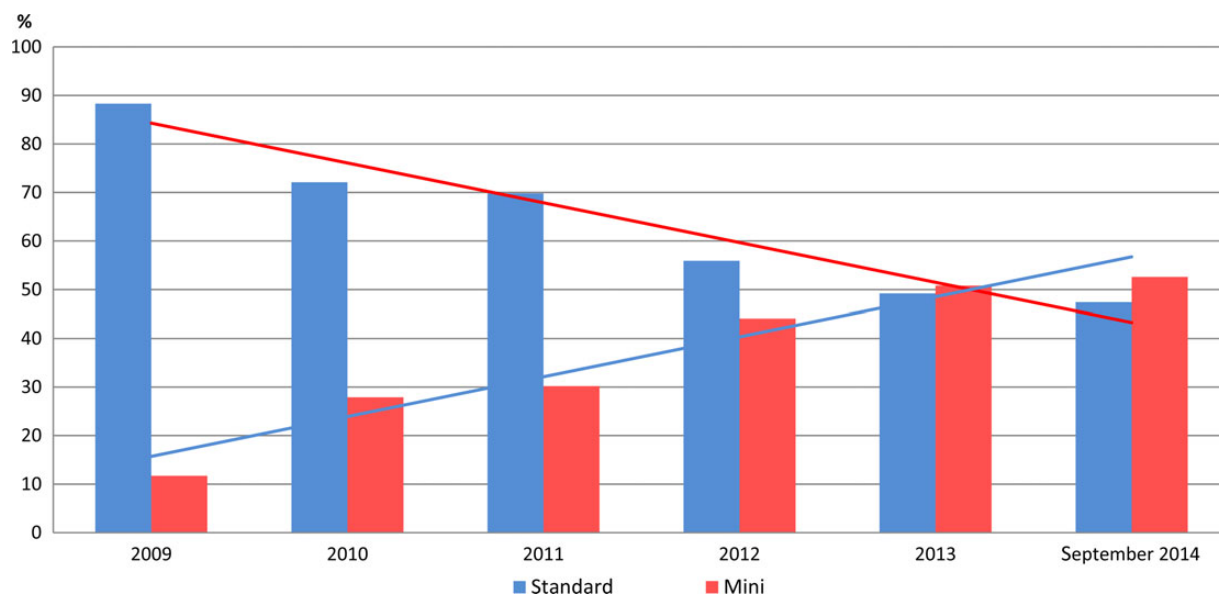


Figure 1 GVM experience in mitral valve repair standard vs. minimally invasive approach.

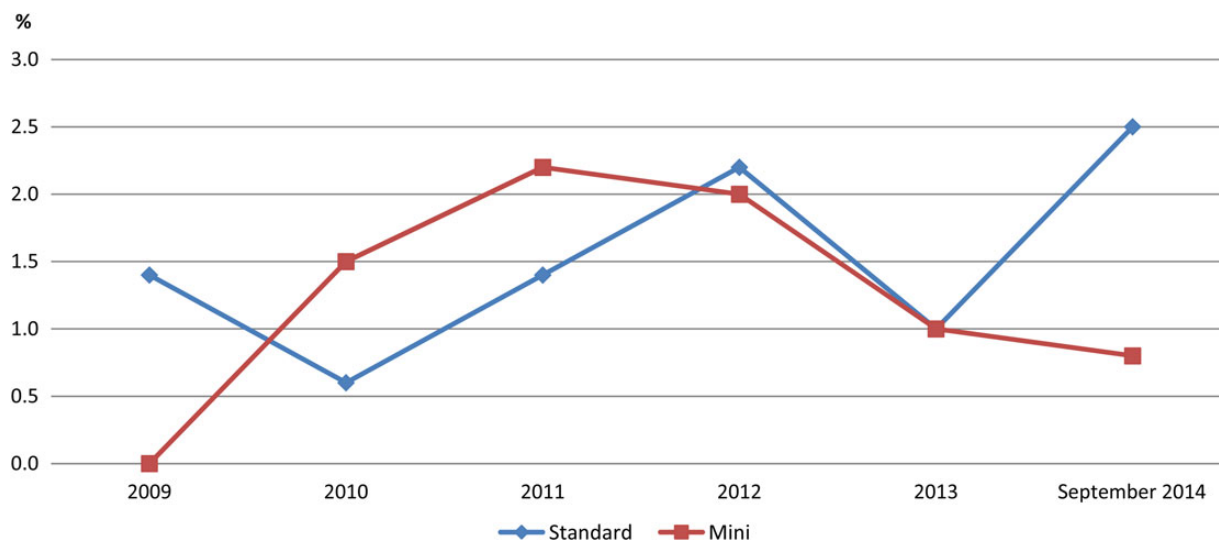


Figure 2 GVM 1-month mortality in mitral valve repair.

minimally invasive material required), incapacity to tolerate right lung exclusion and, as a relative contraindication, severe obesity or chest wall deformities. Such cases should be evaluated individually.

### Why minimally invasive mitral valve surgery?

Any reflection on the advantages, evolution, drawbacks, and limits of minimally invasive mitral valve surgery must be based on a straightforward analysis of the literature in peer-reviewed journals, as the expression of the collective experience of the surgical community. The literature should be systematically analysed in order to clarify one by one all issues associated with this complex clinical reality. Concerning operative mortality, the conclusion from examining the major case series is that we cannot

detect any significant difference between minimally invasive and conventional procedures. A matched analysis found no difference in in-hospital mortality between mini-thoracotomy and sternotomy operated patients (3.7 vs. 3.4%),<sup>9</sup> despite the considerably longer cardiopulmonary bypass times in the minimally invasive surgery group. This result is confirmed in several major series.<sup>10</sup> Interesting investigations have examined through transcranial Doppler the presence of microemboli within the cerebral circulation after conventional external cross-clamping through a sternotomy incision vs. in patients who were treated with an endoaortic balloon occluder: no significant intergroup difference could be detected.<sup>11</sup> There is debate over the question whether minimally invasive mitral valve surgery could actually decrease the blood loss and transfusion requirements compared with conventional surgery. Full

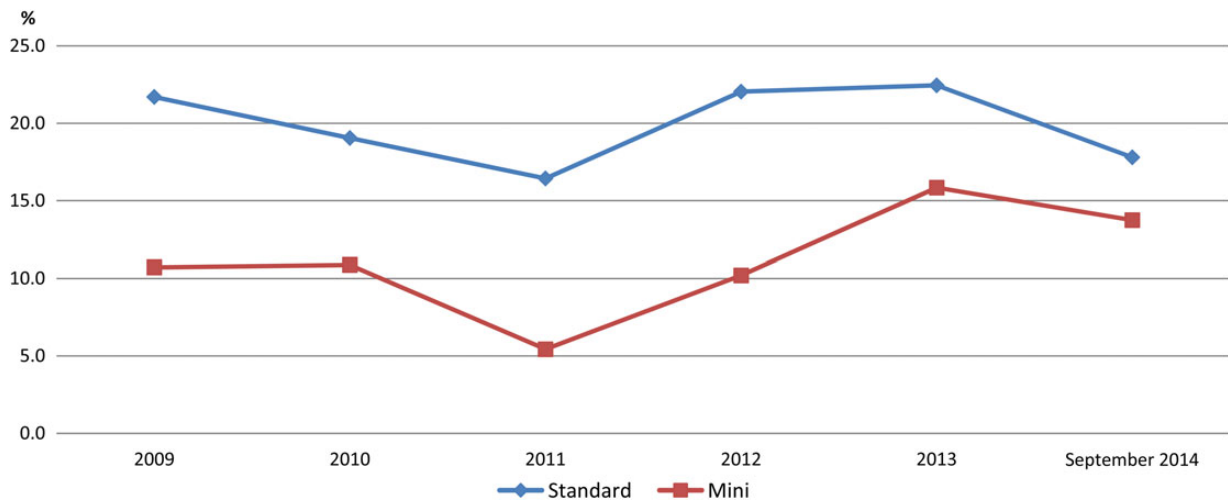


Figure 3 Number of postoperative complications.

median sternotomy entails a larger tissue disruption, whereas a minimally invasive access minimizes the exposure of the interior aspect of the chest wall and the potential sources of bleeding. In fact, several comparative studies have indicated reduced early blood loss after minimally invasive strategy, despite longer cardiopulmonary bypass times. A lower rate of surgical site infections has also been documented, with an inherent reduction of major complications, which carry increased associated mortality, such as sternal infection and mediastinitis. Most studies also underline a significant reduction in postoperative pain with a minimally invasive approach, as well as lesser requirement of analgesic medications and a facilitated recovery of pulmonary function<sup>12</sup> expected through the preserving of the patient's ventilator mechanics made possible due to the sternal integrity. Interestingly, patients who received a reoperation through a minimally invasive approach after previous primary surgery through full sternotomy tend to report that their recovery was easier and faster after minimally invasive surgery.

The elderly represent a particular patient subgroup often characterized by multiple comorbidities and a variable degree of frailty. It has been asked whether the minimally invasive approach may diminish the operative risk among elderly patients affected by severe mitral valve disease. Findings have been reported in the elderly showing a lower mortality rate, and shorter hospital and intensive care unit stays with the minimally invasive approach when compared with median sternotomy.<sup>13</sup> However, the seemingly obvious notion that faster recovery translates into cost-savings and shorter hospitalization is not backed up by a consistent body of evidence in the literature. Differences in local protocols of postoperative hospitalization length may be responsible for a bias in this respect.

The minimally invasive strategy may prove particularly useful in the context of cardiac reoperations: the minithoracotomy access to the mitral valve avoids the sternal re-entry and intrapericardial dissection, with the associated risks of injury and bleeding. Patients with patent coronary grafts are particularly vulnerable in this respect.

## Our experience

Between January 2009 and September 2014, 2267 patients with mitral valve regurgitation have undergone surgical procedures in our hospitals (GVM Care and Research). Mitral valve repair for degenerative diseases was performed in 1758 patients. Among them, 665 patients underwent valve repair using a minimally invasive approach. The rate of using this approach has increased steadily since 2009, to now represent ~50% of cases operated in 2013–14. Currently, more than 12 surgeons are involved in mitral valve repair within eight different centres. The in-hospital mortality rate for the overall period 2009–14 was 1.4%. The mean in-hospital stay was 10.5 days for minimally invasive surgery vs. 11.1 days for standard full sternotomy. The incidence rate of revision for postoperative bleeding was 0.14% for minimally invasive access vs. 0.21% for standard full sternotomy. The rate of successful mitral valve repair was >77% in all centres, while it was higher than 95% in the three centres with >100 cases/year. Within the hospitals with highest valve repair volume (>50 cases/year), we observed a mortality rate of <1%. Overall, our data suggest that the minimally invasive approach can be introduced into routine surgical practice without compromising the repair results, while improving the postoperative outcomes.

## Conclusions

In conclusion, minimally invasive strategies corresponding to level 2 (see four-step classification above) represent in our experience a very good compromise between reproducibility of the procedure and achievement of major advantages associated with the minimal incisions. Moreover, experienced surgeons and high-volume hospitals also contribute to further ameliorate the outcomes and minimize the mortality rate.

**Conflict of interest:** none declared.

## References

1. Carpentier A, Loulmet D, Aupècle B, Kieffer JP, Tournay D, Guibourt P, Fiemeyer A, Méléard D, Richomme P, Cardon C. Computer assisted open heart surgery. First case operated on with success. *CR Acad Sci III* 1998;**321**:437–442.
2. Carpentier A, Loulmet D, Aupeple B, Berrebi A, Relland J. Computer-assisted cardiac surgery. *Lancet* 1999;**353**:379–380.
3. Cosgrove DM, Sabik JF, Navia JL. Minimally invasive valve operations. *Ann Thorac Surg* 1998;**65**:1535–1538.
4. Falk V, Walther T, Autschbach R, Diegeler A, Battellini R, Mohr FW. Robot-assisted minimally invasive mitral valve operation. *J Thorac Cardiovasc Surg* 1998;**115**:470–471.
5. Mohr FW, Falk V, Diegeler A, Walther T, Gummert JF, Bucerius J, Jacobs S, Autschbach R. Computer-enhanced 'robotic' cardiac surgery: experience in 148 patients. *J Thorac Cardiovasc Surg* 2001;**121**:842–853.
6. Chitwood WR, Nifong LW, Elbeery JE *et al.* Robotic mitral valve repair: trapezoidal resection and prosthetic annuloplasty with the da Vinci surgical system. *J Thorac Cardiovasc Surg* 2000;**120**:1171–1172.
7. Nifong LW, Rodriguez E, Chitwood WR. 540 consecutive robotic mitral valve repairs including concomitant atrial fibrillation cryoablation. *Ann Thorac Surg* 2012;**94**:38–42.
8. Suri R, Schaff HV, Dearani JA, Sundt TM III, Daly RC, Mullany CJ, Maurice Enriquez-Sarano M, Orszulak TA. Survival advantage and improved durability of mitral repair for leaflet prolapse subsets in the current era. *Ann Thorac Surg* 2006;**82**:819–826.
9. Grossi EA, Galloway AC, Ribakove GH, Zakow PK, Derivaux CC, Baumann FG, Dennis Schwesinger D, Colvin SB. Impact of minimally invasive valvular heart surgery: a case-control study. *Ann Thorac Surg* 2001;**71**:807–810.
10. Ryan WH, Dewey TM, Mack MJ, Herbert MA, Prince SL. Mitral valve surgery using the classical 'heartport' technique. *J Heart Valve Dis* 2005;**14**:709–714.
11. Schneider F, Onnasch JF, Falk V, Walther T, Autschbach R, Mohr FW. Cerebral microemboli during minimally invasive and conventional mitral valve operations. *Ann Thorac Surg* 2000;**70**:1094–1097.
12. Goldstone AB, Joseph Woo Y. Minimally invasive surgical treatment of valvular heart disease. *Semin Thorac Cardiovasc Surg* 2014;**26**:36–43.
13. Vassileva M, Boley T, Markwell T, Hazelrigg S. Meta-analysis and long-term survival following repair versus replacement for ischemic mitral regurgitation. *Eur J Cardiothorac Surg* 2011;**39**:295–303.