

## Uvulopalatopharyngoplasty with tonsillectomy in the treatment of severe OSAS

S. Gallina\*, F. Dispenza\*\*, G. Kulamarva\*\*\*, A. Ballacchino\*\*\*\* and Riccardo Speciale\*\*\*\*\*

\*Dipartimento Neuroscienze Cliniche, U.O. Otorinolaringoiatria, Università degli Studi di Palermo, Italia; \*\*Dipartimento Discipline Chirurgiche e Oncologiche, U.O. Otorinolaringoiatria, Università degli Studi di Palermo, Italia; \*\*\*ENT Clinic Kasaragod, India; \*\*\*\*Dipartimento Neuroscienze Cliniche, U.O. Otorinolaringoiatria, Università degli Studi di Palermo, Italia

**Key-words.** Snoring; obstructive sleep apnea; tonsillectomy, uvulopalatopharyngoplasty; surgery

**Abstract.** *Uvulopalatopharyngoplasty with tonsillectomy in the treatment of severe OSAS. Objective:* To establish the efficacy of uvulopalatopharyngoplasty with tonsillectomy for treating selected patients with severe obstructive sleep apnea syndrome.

*Methodology:* Retrospective study of patients who underwent clinical/instrumental evaluation and surgical treatment.

*Setting:* University ENT division with a tertiary snoring referral center.

*Participants:* Twenty-two patients with normal body mass index affected by severe obstructive sleep apnea syndrome.

*Main outcome measures:* Pre- and post-operative cardiopulmonary monitoring during sleep, daytime sleepiness evaluation, post-treatment complication recording.

*Results:* Complete response to therapy was obtained in 78% of patients. Four patients had relief of symptoms but retained apnea/hypopnea index scores greater than 5.

*Conclusions:* Uvulopalatopharyngoplasty associated with tonsillectomy can be employed safely to treat patients with normal body mass index who suffer from severe obstructive sleep apnea.

### Introduction

The prevalence of habitual snoring in adult males and females is about 24% and 14%, respectively.<sup>1</sup> Among these, obstructive sleep apnea syndrome (OSAS) affects 4% of men and 2% of women. The pathophysiology of this condition is thought to be excessive narrowing of pharyngeal airway that also collapses during inspiration, resulting in increased negative intrathoracic pressure, which in turn exacerbates the condition. When complete obstruction occurs, the drastic reduction in airflow to the lungs arouses the patient from sleep.

Symptoms of OSAS are generally vague. Neurocognitive symptoms such as memory and learning deficits may be present, and patients can exhibit daytime fatigue due to loss of sleep or

hypoxia itself. In these patients, cardiovascular diseases, such as hypertension and stroke, are related to sleep apnea secondary to increased intrathoracic pressure.<sup>2</sup>

As initial therapy, life-style modifications, such as avoiding alcohol and drugs and weight reduction, are encouraged. When medical treatment is indicated, continuous positive airway pressure (CPAP) therapy during sleep or the use of jaw/tongue advancement devices may be effective. If these prove unsuccessful, surgical options are available. The choice of surgical procedure depends on the site and degree of obstruction. Uvulopalatopharyngoplasty (UPPP) is one of the most common surgical interventions used to treat OSAS. Originally proposed by Ikematsu,<sup>3</sup> it was popularized in 1980 by Fujita *et al.*<sup>4</sup>

The aim of the present work was to establish the efficacy of UPPP with tonsillectomy in the treatment of selected patients with severe OSAS.

### Materials and methods

We retrospectively reviewed the charts of all patients with OSAS who were treated surgically in our department between January 2000 and December 2005. A detailed history of all patients was recorded. All patients underwent a complete head and neck examination, static and dynamic endoscopic evaluation of the upper aerodigestive tract, Muller maneuver evaluation, body mass index (BMI) calculation, and cardiopulmonary monitoring (CPM) during sleep. The parameters evaluated during CPM were 1) apnea/hypopnea index (AHI),

Table 1  
Tonsillar Hypertrophy, Friedman's grading

Grade	Clinical Features
0	Previous tonsillectomy
1	Tonsils inside the tonsillar fossa hidden behind the anterior palatal pillar
2	Tonsils partially outside the tonsillar fossa occupying 25% of the oropharynx
3	Tonsils occupying 50% of the oropharyngeal space
4	Tonsils occupying more than 75% of the oropharynx, almost meeting in the midline

Table 2  
Grading of oropharyngeal (retropalatal) obstruction on Muller's maneuver

Grade	Endoscopic Features
1	Minimal movement of pharyngeal wall with space reduction between 0-49%
2	Pharyngeal wall movement with space reduction between 50-74%
3	Pharyngeal wall movement with space reduction between 75-99%
4	Complete occlusion of pharyngeal lumen

calculated as the summation of total events per hour; 2) oxygen desaturation index (ODI); and 3) saturation value reached during sleep. Apnea was considered as cessation of breathing for at least 10 seconds and hypopnea was defined as reduction of breathing effort with 4% desaturation. We evaluated the daytime sleepiness in all patients based on the Epworth's sleepiness scale questionnaire.

Patients were selected for the study based on the following parameters: 1) OSAS grade severe (AHI > 30) on CPM; 2) Palate position grade I-II according to Friedman's classification<sup>5</sup>; 3) Palatal tonsillar hypertrophy grade 2-4 in accordance with Friedman's grading<sup>6</sup> (Table 1); 4) Oropharyngeal (retropalatal) collapse grade 3 (50-75% of space reduction) to grade 4 (collapse >75%) on Muller's maneuver (Table 2); 5) BMI <28. Patients who did not meet the above criteria were excluded from the study. Patients receiving CPAP therapy were excluded from the study.

Twenty-two patients were included in the study. All 22 patients had been treated surgically with UPPP plus tonsillectomy under general anaesthesia. CPM during sleep was repeated three months after the surgical intervention. Post-operative apnea/hypopnea index and ODI scores below 5 indicated a complete response to therapy. An improvement in AHI exceeding 50% and an AHI less than 20 was considered successful treatment.<sup>7,8</sup> Post-operative complications and chronic adverse effects (hemorrhage, palatal insufficiency, rhinolalia, and disgeusia) were recorded.

Our institutional review board approved the study protocol. Informed consent was obtained from all patients.

*Surgical technique*

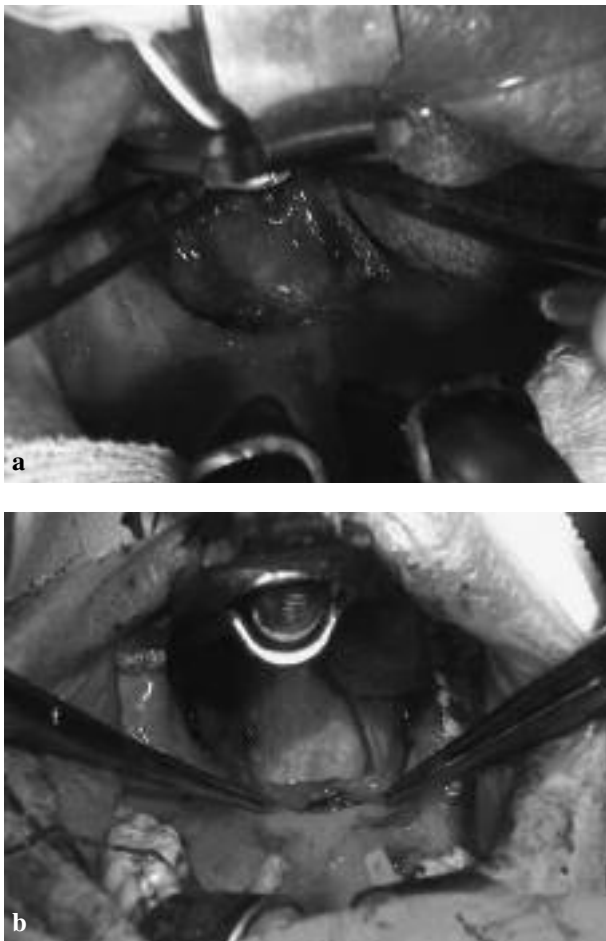
Tonsillectomies were performed using the cold dissection method. The oropharyngeal aspect of the soft palate mucosa was incised 25-mm distal to the posterior end

of the hard palate. The mucosa was then dissected off the underlying muscle up to the free edge of the soft palate and then removed, leaving a myo-mucosal flap of the soft palate mucosa on the nasopharyngeal side (Figure 1). The free soft palate mucosal edge of the nasopharyngeal side was then sutured to the original incision line on the palatal side (Figure 2). This process increases the velopharyngeal inlet.

**Results**

Sixteen males and six females affected by OSAS were included in the study. The mean age of the patients was 47 years (range 24-58). The median pre-operative and post-operative scores are shown in Table 3. Mean follow up was 31 months (range 20-38; Figure 3). According to Friedman's staging system,<sup>5</sup> 18 patients were stage I and four were stage II. All of the patients classified as stage II presented with tonsil size grade 2 and palate position 1-2.

Complete response to therapy was obtained in 17 patients (78%). Four patients had relief of symptoms but retained AHI and ODI scores greater than 5 (Table 3). Thus, treatment was successful in 21 of 22 patients (96%). One patient (4%) was classified as not deriving any benefit from treatment because their post-operative AHI score was 21. All patients were discharged on the second post-operative day. Subjective pain and swallowing discomfort disappeared in all patients by the eighth post-operative day (median 6; range 6-8). Return to normal diet was used as an index of swallowing improvement. No patients complained of velopharyngeal insufficiency.



*Figure 1*

Dissection of the mucosa off the underlying muscle up to the free edge of the soft palate, creating a myo-mucosal flap of the soft palate mucosa on the nasopharyngeal side.

Three patients experienced persistent dry mouth for a mean of 13 months. Two patients had a slight subjective taste disturbance, which recovered spontaneously six months after surgery.

### Discussion

In the last decade, attention to persistent snoring, particularly when associated with apnea syndrome, has increased tremendously. OSAS is a relatively common disorder that affects about 4% of adults.<sup>1</sup> It is often ignored by the patients, which can result in seri-

ous complications and even endanger the patient's life. Quality of life in such patients is generally poor as compared to that of the general population, because of daytime somnolence and its associated consequences, such as increased risk of accidents while driving and at work. Male sex is known to be a major risk factor for rhonchopathy, this is well explained by the higher prevalence of OSAS in men.<sup>9</sup>

Until 1990, the procedures used to diagnose OSAS were inadequate for establishing the precise site of obstruction. Therefore,



*Figure 2*

Suturing the palatal flap using an absorbable suture

patient selection for surgery was not accurate, which affected the eventual outcome of surgery.

Currently, there are various therapeutic options for managing OSAS. The first approach is to encourage the patient to reduce their body weight, improve their sleep hygiene, and avoid alcohol and sedative consumption just before sleep. Medical treatments consist of CPAP devices and oral appliances that advance the mandible to allow the airway to remain patent. Patients show a low compliance with CPAP use and often discontinue or interrupt the treatment for various reasons.

Surgery is generally considered a second-line option. Several techniques have been described in literature, based on the grade of OSAS. Surgery can be performed on either an inpatient or an outpatient basis, depending on the severity of sleep apnea and the surgical procedure chosen.

Historically, lack of understanding of the pathophysiology of OSAS contributed to the erroneous application of some surgical techniques, such as removing

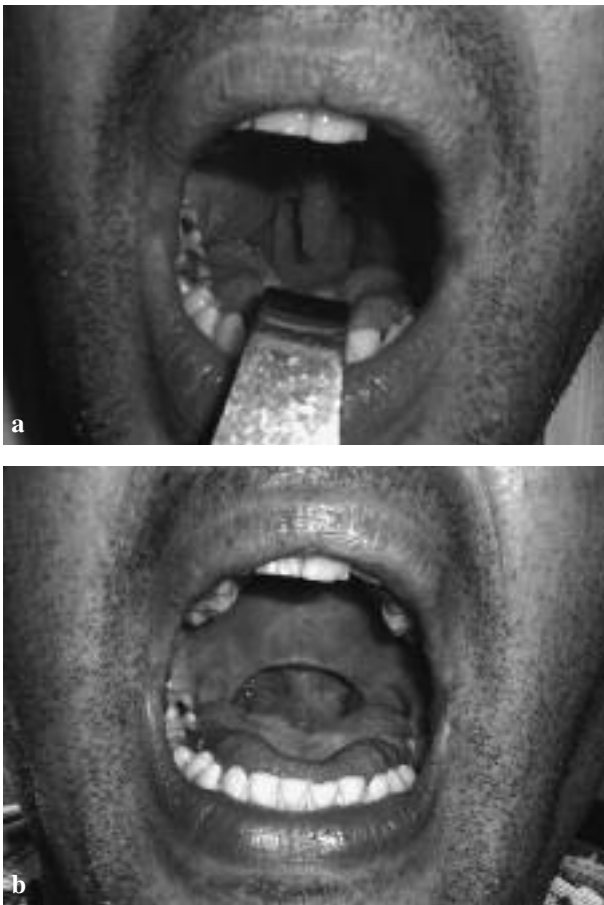


Figure 3

A patient affected by severe OSAS stage II who was treated with UPPP and tonsillectomy. a) Pre-operative photograph. b) Post-operative features after 6 months of follow-up.

muscles of the soft palate along with its mucosa in order to debulk the soft palate, which invited poor results. Implementation of these types of procedures was likely main reason behind the high prevalence of complications and failure in the treatment of OSAS.

Advances in diagnostic devices have allowed for more precise evaluation of patients who suffer from snoring. Endoscopic evaluation of upper respiratory tract collapse on Muller's maneuver and its grading have enabled more effective surgical approaches by

excluding those patients with hypopharyngeal (retroglossal and lateral wall) collapse from UPPP.<sup>10</sup>

For young patients in good general health, we propose surgical correction of the predominant cause of OSAS. Accurate patient selection and use of the least invasive technique that gives the best success rate are paramount for success. UPPP is a procedure with a reasonably short post-operative recovery period that is characterized by swallowing difficulty and pain.<sup>7</sup> In our series, all patients had complete resolution of pain and improvement in swallowing discomfort by the eighth post-operative day. The long-term success rate of UPPP ranges from 50% to 80%.<sup>11-14</sup> In a recent meta-analysis, Sher *et al.*<sup>11</sup> found an overall success rate of 40.7%. The success rate was related to the level of obstruction and was 52.3% in patients with only palatal narrowing or collapse, dropping to just 5.3% in patients with a retro-glossal obstruction with or without palatal component.<sup>11</sup> Because this surgery is performed in patients who have experienced labored breathing for a very long time before surgery, they should be observed closely following surgery. However, the views regarding post-operative observation vary. Spiegel and Raval<sup>15</sup> suggested monitoring patients for only 2-3 hours after surgery and then discharging them home. Kezirian *et al.*<sup>16</sup> reported a nonfatal complications rate of 1.5% and mortality of 0.2% in a series of more than 3000 cases of UPPP.

Great care should be exercised when intubating and extubating these patients for general anaesthesia, because patients with OSAS typically have difficult

Table 3  
Cardiopulmonary monitoring and daytime sleepiness variations

	Pre-operative median score (range)	Post-operative median score (range)
Apnea/Hypopnea index	45 (40-56)	4 (3-21)
Oxygen desaturation index	39 (36-43)	4 (4-24)
Sleeping oxygen saturation	71% (68-80)	92% (80-95)
Epworth sleepiness scale	15 (12-17)	5 (5-9)

airways. Riley *et al.*<sup>17</sup> reported that most post-operative complications were related to hypertension and at that only six of 182 patients had a post-operative saturation less than 90% (possibly attributable to narcotics used for general anaesthesia). It is mandatory that regular CPM be performed during surgical follow up in order to assess for residual disease and evaluate treatment efficacy. Indeed, the risk of developing cardiovascular complications in patients with unresolved OSAS is nearly 50%.<sup>18</sup>

UPPP is associated with both short-term and long-term complications. However, as noted by Sher *et al.*,<sup>11</sup> it is impossible to determine the true rate of complications because of the majority of papers on UPPP have not reported the presence or absence of complications. The more common complications described in literature are velopharyngeal insufficiency, post-operative bleeding, nasopharyngeal stenosis, and voice change. In our study, the main complications encountered were taste disturbance in two patients and mouth dryness in three patients. Damage to taste buds on the soft palate during UPPP might be a factor in post-operative taste function impairment, which is observed in 7-10% of patients.<sup>19</sup> However, taste function may recover over time, as was observed in our patients.

UPPP is contraindicated in those patients with only retroglossal obstruction. In a previous report, negative predictors of outcome were combined palatal and retroglossal obstruction and previous tonsillectomy.<sup>13</sup> A pharyngeal surgical approach may be recommended for patients with severe grade OSAS. As demonstrated by our data, a greater than 50%

reduction of the pre-operative AHI was obtained in 96% of patients with severe OSAS, indicating good efficacy of UPPP plus tonsillectomy. These data coincide with those reported by Friedman *et al.*,<sup>6</sup> who obtained an 80% success rate in stage I patients managed with UPPP. In our opinion, tonsillectomy should be performed during the same surgical session in a day-surgery regimen.<sup>20</sup> Friedman *et al.*<sup>21</sup> asserted that in patients with palatal obstruction who have undergone previous tonsillectomy, it might be better to perform a Z-palatoplasty during UPPP.

It is known that a BMI greater than 27 drastically reduces the efficacy of UPPP, even with combined genioglossus advancement and hyoid suspension. Symptomatic relief by UPPP is known to deteriorate during long-term follow-up. In a survey of patients at 17-20 years post UPPP, the percentage of symptomatic relief had decreased significantly.<sup>18</sup> Weight gain was the main predisposing factor for recurrence of symptoms.

### Conclusions

Patients suffering from OSAS should be evaluated using a multidisciplinary approach. Determining the site and grade of obstruction is mandatory for selecting the appropriate treatment strategy. Although surgery remains a second-line option, it can help to reduce snoring and the frequency of sleep apnea episodes. Our data suggest that UPPP associated with tonsillectomy can be safely employed to treat even those patients with severe OSAS with stage I-II disease and normal BMI.

### References

1. Woodhead CJ, Davies JE, Allen MB. Obstructive sleep apnoea in adults presenting with snoring. *Clin Otolaryngol Allied Sci.* 1991;16:401-405.
2. White DP. Sleep apnea. *Proc Am Thorac Soc.* 2006;3:124-128.
3. Ikematsu T. Study of snoring, 4th report: therapy. *J Jpan Otol Rhinol Laryngol Soc.* 1964;64:434-435.
4. Fujita S, Conway W, Zorick F, Roth T. Surgical correction of anatomic abnormalities in obstructive sleep apnea syndrome: uvulopalatopharyngoplasty. *Otolaryngol Head Neck Surg.* 1981;89:923-934.
5. Friedman M, Ibrahim H, Joseph NJ. Staging of obstructive sleep apnea/hypopnea syndrome: a guide to appropriate treatment. *Laryngoscope.* 2004;114:454-459.
6. Friedman M, Ibrahim H, Bass L. Clinical staging for sleep-disordered breathing. *Otolaryngol Head Neck Surg.* 2002;127:13-21.
7. Friedman M, Ibrahim H, Lowenthal S, Ramakrishnan V, Joseph NJ. Uvulopalatoplasty (UP2): a modified technique for selected patients. *Laryngoscope.* 2004;114:441-449.
8. Sher AE. Upper airway surgery for obstructive sleep apnea. *Sleep Med Rev.* 2002;6:195-212.
9. Walker RP, Durazo-Arvizu R, Wachter B, Gopalsami C. Preoperative differences between male and female patients with sleep apnea. *Laryngoscope.* 2001;111:1501-1505.
10. Stuck BA, Maurer JT. Airway evaluation in obstructive sleep apnea. *Sleep Med Rev.* 2008;12:411-436.
11. Sher AE, Schechtman KB, Piccirillo JF. The efficacy of surgical modifications of the upper airway in adults with sleep apnea syndrome. *Sleep.* 1996;19:156-177.
12. Pépin JL, Veale D, Mayer P, Bettiga G, Wuyam B, Lévy P. Critical analysis of the results of surgery in the treatment of snoring, upper airway resistance syndrome (UARS), and obstructive sleep apnea (OSA). *Sleep.* 1996;19(9 Suppl):S90-S100.
13. Hessel NS, de Vries N. Results of uvulopalatopharyngoplasty after diagnostic workup with polysomnography

- and sleep endoscopy: a report of 136 snoring patients. *Eur Arch Otorhinolaryngol.* 2003;260:91-95.
14. Rösli C, Schneider S, Häusler R. Long-term results and complications following uvulopalatopharyngoplasty in 116 consecutive patients. *Eur Arch Otorhinolaryngol.* 2006;263:754-758.
  15. Spiegel JH, Raval TH. Overnight hospital stay is not always necessary after uvulopalatopharyngoplasty. *Laryngoscope.* 2005;115:167-171.
  16. Kezirian EJ, Weaver EM, Yueh B, et al. Incidence of serious complications after uvulopalatopharyngoplasty. *Laryngoscope.* 2004;114:450-453.
  17. Riley RW, Powell NB, Guilleminault C, Pelayo R, Troell RJ, Li KK. Obstructive sleep apnea surgery: risk management and complications. *Otolaryngol Head Neck Surg.* 1997;117:648-652.
  18. Goh YH, Mark I, Fee WE Jr. Quality of life 17 to 20 years after uvulopalatopharyngoplasty. *Laryngoscope.* 2007;117:503-506.
  19. Kamel UF. Hypogeusia as a complication of uvulopalatopharyngoplasty and use of taste strips as a practical tool for quantifying hypogeusia. *Acta Otolaryngol.* 2004;124:1235-1236.
  20. Laureyns G, Lemkens P, Jorissen M. Tonsillectomy as a day-case surgery: a safe procedure? *B-ENT.* 2006;2:109-116.
  21. Friedman M, Ibrahim HZ, Vidyasagar R, Pomeranz J, Joseph NJ. Z-palatoplasty (ZPP): a technique for patients without tonsils. *Otolaryngol Head Neck Surg.* 2004;131:89-100.
  22. Riley RW, Powell NB, Guilleminault C. Obstructive sleep apnea syndrome: a review of 306 consecutively treated surgical patients. *Otolaryngol Head Neck Surg.* 1993;108:117-125.

F. Dispenza, M.D.  
Via Paolo Emiliani Giudici, 37  
90127 Palermo, Italy  
E-mail: francesco.dispenza@gmail.com