



A method of reconstruction after pancreaticoduodenectomy for pancreatic malignancies in very young children: Two cases reports



Angela Inviati^{a,*}, Marco Vito Martino Marino^a, Olena Kolesnik^b, Grigoriy Klimnuk^b, Galyna Shabat^b, Andrey Lukashenko^b, Gaspare Gulotta^a, Sebastiano Bonventre^a

^a Department of Surgical and Oncological Sciences, University of Palermo, Via L. Giuffrè 5, 90127 Palermo, Italy

^b National Cancer Institut of Ukraine, 33/43 Lomonosova str., Kyiv 03022, Ukraine

ARTICLE INFO

Article history:

Received 24 January 2016

Received in revised form

7 April 2016

Accepted 9 April 2016

Key words:

Pancreatic tumors

Young children

Pancreaticoduodenectomy

ABSTRACT

Pancreatic tumors are very rare diseases in very young children. Most information about those diseases in children was published in cases reports. Due to the rare nature of pancreatic tumors in children, there remains the absence of diagnostic algorithms, clear radiographic and morphological assessments as well as evidence based best treatment options. Because of the young age of patients and the rare occurrence of pancreatic neoplasms, tumor detection remains poor. For malignancies affecting the head of the pancreas the only possibility for achieving clear surgical margins is performing a pancreaticoduodenectomy (PD). We describe two cases of diagnostic and treatment of pancreatic tumor of very young children what was done in our institute.

© 2016 The Authors. Published by Elsevier Inc. This is an open access article under the CC BY-NC-ND license (<http://creativecommons.org/licenses/by-nc-nd/4.0/>).

Pancreatic tumors are very heterogeneous neoplasms, and very rare at a young age. Represent only 0.1% of all pancreatic malignancies in children and adults younger than 20 years of age [1]. The main histological types of pancreatic malignancies, among children, are: solid pseudopapillary tumors (SPTs), pancreatoblastomas, acinar cell carcinomas, neuroendocrine tumors, sarcomas and lymphomas [2–4]. The 5-year overall survival is approximately 88% for SPTs, 66% for pancreatoblastomas, 58% for neuroendocrine tumors, and 33% for carcinomas [3]. Despite a good prognosis, the rate of metastases and the local involvement of adjacent organs is 19.5% for SPTs and more than 33% for pancreatoblastomas at the time of diagnosis [5].

The radical surgery is the standard cure for nonmetastatic diseases, the pancreaticoduodenectomy (PD) is the best choice when the tumor is localized in the head of the pancreas.

The PD in adults is a complicated surgery that, in spite of a significantly reduced mortality, has a high morbidity, 30–50% [6,7]. The complications were related to the pancreatic remnant, such as a pancreatic fistula, anastomotic dehiscence, abscess formation, and septic hemorrhage [6,7]. In general, the PD has been avoided in children because of its technical difficulty and the problems associated with further growth and development, or chronic

cholangitis and reflux gastritis. Previous reports have described the long-term effects of pancreatic function [8] and morphological changes of the pancreatic remnant [9] after a PD in adults. However, these findings have not been confirmed in children. Determination of the best pancreatic anastomosis technique and reconstruction after PD, in young children, remains to be reported [8].

Therefore, the main objective of our study was to identify a reconstruction surgical technique that can reduce complications and, in particular, to prevent pancreatic fistula.

1. Case report

1.1. Case 1

A 5-year old girl was referred to our institute with a palpable abdominal mass in the right upper quadrant. One month earlier, the patient was underwent an intraoperative biopsy of a large tumor of the pancreatic head in another center, and she was referred after adjuvant chemotherapy by us. The histological type is a SPTs. There was no history of abdominal pain or steatorrhea. On hospital admission, the serum liver enzymes, tests of pancreatic function and tumor markers were normal. An abdominal ultrasound (US) and magnetic resonance imaging (MRI) were showed a well-defined heterogeneous mass measuring about $8.5 \times 7.7 \times 6.7$ cm³ that encased the superior mesenteric vein (SMV) at the level of the

* Corresponding author. Tel.: +39 3396085629.

E-mail address: surgeryangela@hotmail.it (A. Inviati).

inferior pancreaticoduodenal vein (IPDV) (Fig. 1 A and B). The MRI showed no metastatic lesions. Moreover, during a type 3 MRI arterial reconstruction of the hepatic artery, an anatomical variation as per Michel's classification was noted [10]. The right hepatic artery origin was by superior mesenteric artery (SMA) and was located behind the tumor. The patient was scheduled for a laparotomy.

1.2. Surgical approach

A standard bilateral subcostal (Chevron) incision was performed, the intraoperative exploration show the mass which involved the pancreatic head and adhered to the SMV at the region of the IPDV. Standard PD with distal gastrectomy and an intestinal reconstruction 'Totally isolated Roux-en-Y' was performed (Fig. 2 A and B). We chose this type of reconstruction to reduce the most feared complication of this type of surgical procedure, or the pancreatic fistula. Special attention was focused on meticulous dissection of the uncinate process from underneath the SMV and the SMA with identification and careful preservation of the variant right hepatic artery (Fig. 3).

Reconstruction times:

- 1 End-to-side duct-to-mucosa pancreaticojejunostomy.
- 2 Antecolic end-to-side gastrojejunostomy.
- 3 Hepaticojejunostom.
- 4 Braun's enteroenterostomy.

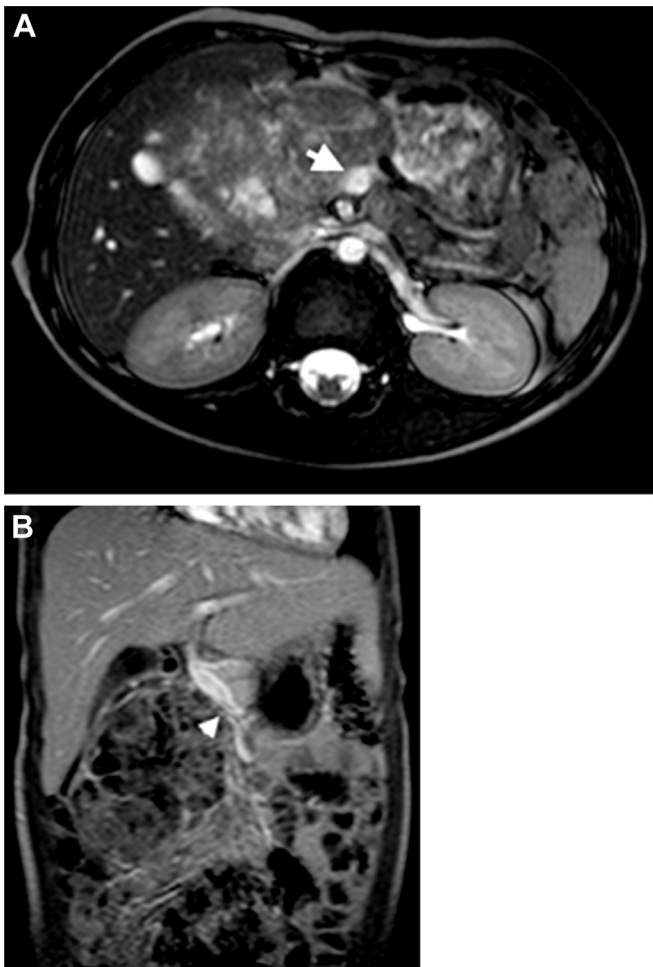


Fig. 1. (A) Case 1: Preoperative magnetic resonance imaging (MRI) showing tumor in the head of the pancreas encasing the superior mesenteric vein (arrow), (A) Axial MRI, (B) Frontal MRI. The tip of the arrow in the figure indicates the head of the pancreas tumor that wraps around the superior mesenteric vein.

5 A second enteroenterostomy "Roux-en-Y."

We have previously excluded jejunal loop, long about 40 cm, with this we have made a pancreatico-jejunal anastomosis end-to-side (T-L) and entero-enteric anastomosis "Roux-en-Y." The second jejunal loop was used for gastrojejunal anastomosis, hepaticojejunostomy end-to-side, entero-enteric anastomosis according to Braun downstream of the previous anastomosis biliary and gastric, The pancreaticojejunostomy was performed through the mesocolon and in an end-to-side manner.

The incision of the jejunum was performed on the anti-mesenteric side. A small hole to match the caliber of the pancreatic duct was made using electrocautery and forceps. Interrupted sutures were placed in the inner layer using 6–0 monofilament absorbable sutures with atraumatic double-ended needles. No stenting, external or internal drainage of the pancreatic duct was performed. The second blind end that formed the jejunal loop was used for an antecolic end-to-side gastrojejunostomy. Finally, a microgastrostomy, per Witzel's method, using 4–0 absorbable interrupted sutures, was performed; this avoided the need for postoperative nasogastric intubation.

Hepaticojejunostomy was performed at the antecolic pathway on the same jejunal loop, 30 cm downstream from the gastrojejunostomy. The remnant hepatic duct diameter was 4 mm; a typical end-to-side hepaticojejunostomy, in one-layer fashion, was put in place. Stenting, as well as external and internal drainage of the biliary duct was not performed.

In addition, a Braun anastomosis was added 10 cm downstream from the hepaticojejunostomy and then the afferent limb of the hepaticojejunostomy was closed with a linear stapler to isolate the gastric and biliary anastomoses from cross reflux and prevent back-flow of bile to the stomach. The hepaticojejunostomy was excluded from gastric passage using a two layer Braun anastomosis 10 cm from the gastrojejunostomy and then the afferent limb was closed with a linear stapler. The FJL was connected to the second jejunal loop in a Roux-en-Y fashion 10 cm downstream from the Braun anastomosis. At the end of the procedure, one drain was placed at the superior margin of the pancreatic anastomosis without any protection of the anastomosis. The patient's abdomen was closed in standard fashion.

1.3. Postoperative management

The patient was monitored closely for excessive discharge from the microgastrostomy and the abdominal drain, a high fever, elevation of the white blood cell count and C-reactive protein. Proton pump blockers and histamine H₂-receptor antagonists were administered for five days. Octreotide was used subcutaneously, 50 µg one times daily, for three days. The surgically placed drain was removed on day five after confirmation of the absence of a high amylase in the drain fluid. Oral fluids were started 12 h after surgery and oral nutrition on day 3 after contrast radiography confirmed sufficient passage through the true gastrojejunostomy. Pain medication was given by epidural catheter for 3 days. Currently, the patient is followed closely and doing well.

The structure of the neoplasm and its immunophenotype confirm a solid pseudopapillary tumor. The surgical margins of the pancreatic head, duodenum and gallbladder were negative for malignant cells (on histopathology). Two lymph nodes were free of metastatic disease.

1.4. Case 2

A 1-year-10-month-old boy was admitted to the hospital for a palpable mass in the right upper abdominal quadrant. No tumor-associated family history was noted. Physical examination showed

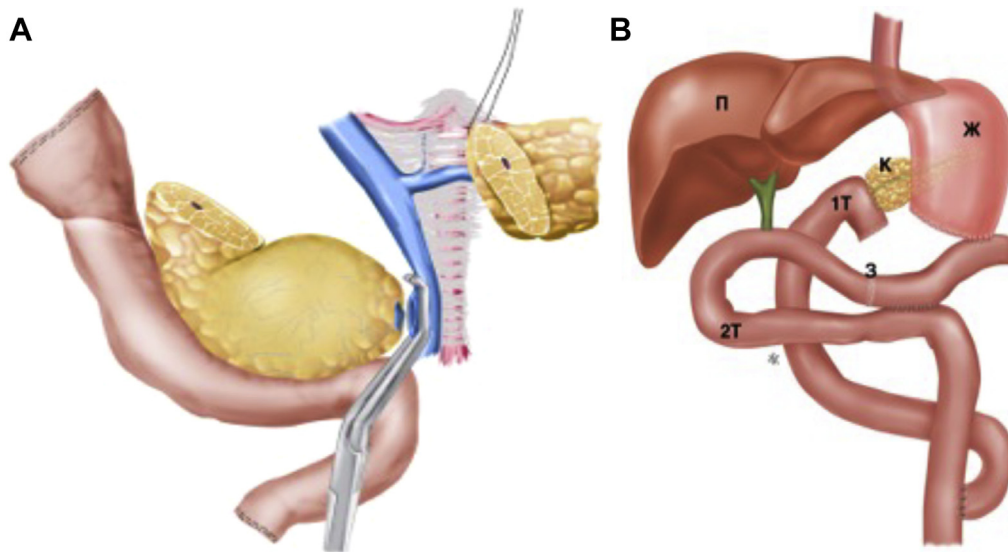


Fig. 2. A) Standard PD with distal gastrectomy, (B) Totally Isolated Roux-en-Y reconstruction after pancreaticoduodenectomy. K: pancreas, *: stomach, n: liver, 1T: first jejunal loop, 2T: second jejunal loop, 3: Braun's enteroenterostomy.

normal vital signs and a palpable mass in the right upper abdomen below the right costal margin. US of the abdomen showed a no well-defined heterogeneous mass in the head and body of the pancreas, extending to the root of the mesentery. The MRI showed a heterogeneous complex mass $8.4 \times 7.5 \times 8.6 \text{ cm}^3$ with a capsule that extended and shifted the portal vein up and to the left. In this case, the MRI arterial reconstruction revealed the same Michel's type 3 arterial variation as in the previous patient.

No metastatic lesions.

The biopsy is not been diagnostic (the removed tissue showed immature cells).

Therefore, an exploratory laparotomy was performed. During the surgery, a large abdominal mass with a complete capsule was detected that compressing the duodenum and enveloped in superior mesenteric vein sleeve and the common bile duct. So, we proceeded to perform PD.

The boy underwent resection of the mass in the pancreas on the seventh day after admission. The surgical approach to tumor removal and the isolated Roux-en-Y reconstruction were performed in the same manner as in the previous case. During postoperative

management, the same medications were used as in the previous case. The surgically placed drain was removed on day 4. Oral fluids were started 24 h after surgery and full oral nutrition by day 9. Currently, the patient is followed closely and doing well. The tumor was confirmed as undifferentiated teratoma; it weighed 310 mg and consisted of 2.6% of the child's body mass. Chemotherapy was started in view of tumor infiltration.

2. Discussion

In large-series reports, radical surgery for pancreatic head malignancies, in very young children, is generally avoided due to potential complications in 14.3%–45.5% [11].

Radical surgical excision is the gold standard of management, even at the price of aggressive resections, as this is associated with a good prognosis and of survival [12,13]. However, it is not rare that some teams choose a relatively conservative approach when it comes to operating on children (local and partial resections with dubious margins). Although the reluctance to perform aggressive surgery in this age group is understandable, this approach is associated with a higher incidence of recurrence, local or metastatic.

Most of the Japanese surgeons preferred a pancreaticogastrostomy with an external pancreatic drain, while other surgeons described a dunking pancreaticojejunostomy, and sewing the pancreatic stump without anastomosis in the earliest report [14,15]. Sugito et al. [14] analyzed later deterioration of the pancreatic stump after a pancreaticogastrostomy in two cases. The authors described decreasing thickness of the pancreatic remnant and the development of atrophic changes three years after surgery.

The exact mechanism causing the development of complications after a PD remains unclear. One theory, for all reconstruction types after a PD, is the presence of cross reflux of bile, pancreatic and gastric juices [14–16].

According to the pathological changes described above, the current method used for isolated Roux-en-Y reconstruction has a physiological basis. Our method of reconstruction has been successfully used in more than 80 adults [17] and now appears to be a safe and effective procedure for children. Our method for Roux-en-Y reconstruction leaves the patient closer to normal human digestive physiology than prior techniques and thus might

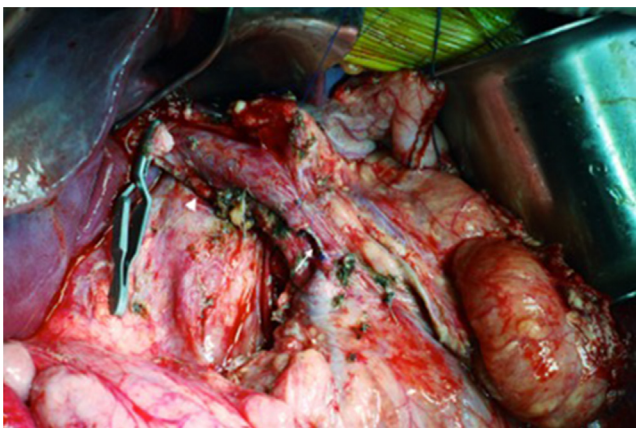

Fig. 3. The primary tumor has been completely resected with pancreaticoduodenectomy. Resection line of the superior mesenteric vein (arrow). The right hepatic artery (arrow-head), replaced from superior mesenteric artery. PV, portal vein; PS, pancreatic stump.

avoid cross reflux of bile or pancreatic juice to the stomach or vice versa to the biliary tree or pancreatic remnant.

The limited data available confirms that in very young children, PD is more difficult than in the adult population and requires meticulous surgical technique, especially in cases that need venous resection.

The question of long-term physiological outcome and morphological distortions of the pancreatic remnant after PD in a child is very important. Removing part of the pancreas may result in serious consequences: e.g. endocrine and/or exocrine deficiency and slowing of growth [14]. Lemaire et al. [18] showed that fat malabsorption usually developed in the first year after surgery and might be due to different mechanisms, such as inactivation of pancreatic enzymes as a result of low gastric pH, stenosis at the pancreatic ductal-gastric anastomosis, pancreatic atrophy secondary to anastomotic stenosis or abnormalities of neuro-hormonal stimulating factors. Currently, no conclusions can be determined regarding the influence of PD on physiology in children because of the extremely low number of cases. In addition, later complications and physiological changes, with bilio-digestive anastomoses in children after a PD, remain unclear. The presence of cholangitis is a unique factor affecting the incidence of cholangiocarcinoma [19]; however, there are no data available in the pediatric literature about bilio-digestive diversion techniques and the risk of cancer.

Cystic pancreatic tumors are rare in children and the immature cystic teratoma of the pancreas is even rarer. The preoperative evaluation of this lesion is rather questionable, with definitive diagnosis taking place intraoperatively. Pancreatic immature teratoma are extremely rare and are difficult to diagnose preoperatively, the diagnosis is often made in retrospect once the histology of the excised mass is studied. Treatment is surgical extirpation, i.e., simple excision of cyst. However, in our case, since the tumor had close relations of contiguity with neighboring structures (vessels and bile duct) we decided on a more radical surgical approach.

It's certainly difficult for the few data in the literature regarding the diagnostic and therapeutic approach to malignant tumors of the pancreas in children, be able to give clear information; therefore the use of this reconstructive variant refers to the excellent results obtained in a study of adults, cited in our study, placing this probably exposed to criticism.

However, we believe that, if properly performed this procedure, as described, a clear motivation on the pathophysiology of pancreatic fistula formation and thus the possibility of being able to reduce if not eliminate the risk to be realized.

Furthermore, there is a strong volume to outcome relationship reported for pancreatic resections in large-series studies [20,21]; therefore, young patients with pancreatic malignancies should be cared for in high-volume institutions. The number of cases undergoing PD, in very young children, is very low; thus, only experienced hepato-pancreato-biliary surgeons should perform such potentially complicated procedures. To obtain a negative surgical margin, surgeons must be prepared to dissect the superior mesenteric vein, portal vein or superior mesenteric-portal vein. The surgical technique in children demands very meticulous procedures with the mandatory use of an intraoperative scope for magnification. The best outcomes will likely be based on a multidisciplinary approach to patient care including not only the surgical team and anesthesiologists but also meticulous diagnostic and postoperative care, which can substantially affect surgical morbidity and mortality [22].

3. Conclusion

Surgical resection is the treatment of choice for tumors of the pancreatic head area. In the absence of regional or metastatic extension, the radicality of primary intervention is associated with

favorable outcomes. Good functionality results were observed after the PD was limited to the head of the pancreas.

The number of reported PD cases in very young children is extremely low; therefore, the best approaches with regard to surgical technique, anesthesia management, radiological imaging and pathological assessment remain unclear. All reviewed studies concluded that early, complete and even aggressive surgical resection is the key to improve the survival in children with pancreatic malignancies. In the absence of available data on later physiological outcomes, after PD in children, we propose our method of isolated Roux-en-Y reconstruction as a safe procedure and physiologically effective. PD, in children, should be carried out in institutions where they work experts surgeons that perform a high-volume of interventions per year.

Conflict of interest

No conflict of interest was declared by the authors.

Financial disclosure

The authors declared that this study has received no financial support.

Informed consent

Written informed consent was obtained.

Author contributions: Concept—M.V.M.M.; Design—O.K.; Supervision—A.L., S.B., G.G.; Resource—G.S.; Materials—G.K.; Data Collection&/or Processing - M.V.M.M., A.L.,; Analysis&/or Interpretation - G.S.; Literature Search - R.G., A.I.; Writing - M.V.M.M.; Critical Reviews - S.B., A.I.

References

- [1] Ahmed TS, Chavhan GB, Navarro OM, Traubici J. Imaging features of pancreatic tumors in children: 13-year experience at a pediatric tertiary hospital. *Pediatr Radiol* 2013;43:1435–43.
- [2] Dall'igna P, Cecchetto G, Bisogno G, Conte M, Chiesa PL, D'Angelo P, et al. Pancreatic tumors in children and adolescents: the Italian TREP project experience. *Pediatr Blood Cancer* 2010;54:675–80.
- [3] Brecht IB, Schneider DT, Kloppel G, Von Schweinitz D, Barthlen W, Hamre MR. Malignant pancreatic tumors in children and young adults: evaluation of 228 patients identified through the Surveillance, Epidemiology, and End Result (SEER) database. *Klin Pediatr* 2011;223:341–5.
- [4] Bien E, Godzinski J, Dall'igna P, Defachelles AS, Stachowicz-Stencel T, Orbach D, et al. Pancreatoblastoma: a report from the European cooperative study group for pediatric rare tumors (EXPeRT). *Eur J Cancer* 2011;47:2347–52.
- [5] Papavramidis T, Papavramidis S. Solid pseudopapillary tumors of the pancreas: review of 718 patients reported in English literature. *J Am Coll Surg* 2005;200:965–72.
- [6] Buchler MW, Friess H, Wagner M, Kulli C, Wagnener V, Z'Graggen K. Pancreatic fistula after pancreatic head resection. *Br J Surg* 2000;87:883–9.
- [7] Kleespies A, Albertsmeier M, Obeidat F, Seeliger H, Jauch KW, Bruns CJ. The challenge of pancreatic anastomosis. *Langenbecks Arch Surg* 2008;393:459–71.
- [8] Fish JC, Smith LB, Williams RD. Digestive function after radical pancreaticoduodenectomy. *Am J Surg* 1969;117:40–5.
- [9] Sato N, Yamaguchi K, Yokohata K, Shimizu S, Chijiwa K, Tanaka M. Long-term morphological changes of remnant pancreas and biliary tree after pancreaticoduodenectomy on CT. *Int Surg* 1998;83:136–40.
- [10] Michels NA. Newer anatomy of the liver and its variant blood supply and collateral circulation. *Am J Surg* 1966;112:337–47.
- [11] Choi SH, Kim SM, Oh JT, Park JY, Seo JM, Lee SK. Solid pseudopapillary tumor of the pancreas: a multicenter study of 23 pediatric cases. *J Pediatr Surg* 2006;41:1992–5.
- [12] Grosfeld JL, Vane DW, Rescorla FJ, McGuire W, West KW. Pancreatic tumors in childhood: analysis of 13 cases. *J Pediatr Surg* 1990;25:1057–62.
- [13] Rojas Y, Warneke CL, Dhamne CA, Tsao K, Nuchtern JG, Lally KP, et al. Primary malignant pancreatic neoplasms in children and adolescents: a 20 year experience. *J Pediatr Surg* 2012 Dec;47(12):2199–204.
- [14] Sugito K, Furuya T, Kaneda H, Masuko T, Ohashi K, Inoue M, et al. Long-term follow-up of nutritional status, pancreatic function, and morphological changes of the pancreatic remnant after pancreatic tumor resection in children. *Pancreas* 2012;41:554–9.

- [15] Pescio G, Cariati E. A new reconstructive method after pancreaticoduodenectomy: the triple Roux on a "P" loop. Rationale and radio-nuclide scanning evaluation. *HPB Surg* 1996;9:223–7.
- [16] Klaus A, Hinder RA, Nguyen JH, Nelson KL. Small bowel transit and gastric emptying after biliodigestive anastomosis using the uncut jejunal loop. *Am J Surg* 2003;186:747–51.
- [17] Shchepotin IB, Vasil'ev OV, Lukashenko AV, Rozumiĭ DA, Priĭmak VV. The method of the isolated reconstruction by gastropancreatoduodenal resection. *Khirurgiia (Mosk)* 2011;10:30–4.
- [18] Lemaire E, O'Toole D, Sauvanet A, Hammel P, Belghiti J, Ruszniewski P. Functional and morphological changes in the pancreatic remnant following pancreaticoduodenectomy with pancreaticogastric anastomosis. *Br J Surg* 2000;87:434–8.
- [19] Tocchi A, Mazzoni G, Liotta G, Lepre L, Cassini D, Miccini M. Late development of bile duct cancer in patients who had biliary-enteric drainage for benign disease: a follow-up study of more than 1,000 patients. *Ann Surg* 2001;234:210–4.
- [20] Birkmeyer JD, Siewers AE, Finlayson EVA, Stukel TA, Lucas FL, Batista I, et al. Hospital volume and surgical mortality in the United States. *N Engl J Med* 2002;346:1128–37.
- [21] Muller CO, Guerin F, Goldzmid D, Fouquet V, Franchi-Abella S, Fabre M, et al. Pancreatic resections for solid or cystic pancreatic masses in children. *J Pediatr Gastroenterol Nutr* 2012;54:369–73.
- [22] Faircloth AC, Noble J. Anesthetic management of a pediatric patient undergoing a pancreaticoduodenectomy with portal vein reconstruction. *AANA J* 2012;80:37–42.