

Comparison of minimally invasive parathyroidectomy under local anaesthesia and minimally invasive video-assisted parathyroidectomy for primary hyperparathyroidism: a cost analysis

G.I. MELFA¹, C. RASPANTI¹, M. ATTARD², G. COCORULLO¹, A. ATTARD³, S. MAZZOLA⁴,
G. SALAMONE¹, G. GULOTTA¹, G. SCERRINO¹

SUMMARY: Comparison of minimally invasive parathyroidectomy under local anaesthesia and minimally invasive video-assisted parathyroidectomy for primary hyperparathyroidism: a cost analysis.

G.I. MELFA, C. RASPANTI, M. ATTARD, G. COCORULLO, A. ATTARD, S. MAZZOLA, G. SALAMONE, G. GULOTTA, G. SCERRINO

Background. Primary hyperparathyroidism (PHPT) originates from a solitary adenoma in 70- 95% of cases. Moreover, the advances in methods for localizing an abnormal parathyroid gland made minimally invasive techniques more prominent. This study presents a micro-cost analysis of two parathyroidectomy techniques.

Patients and methods. 72 consecutive patients who underwent minimally invasive parathyroidectomy, video-assisted (MIVAP, group A, 52 patients) or "open" under local anaesthesia (OMIP, group B, 20 patients) for PHPT were reviewed. Operating room, consumable, anaesthesia, maintenance costs, equipment depreciation and surgeons/anaesthesiologists fees were evaluated. The patient's satisfaction

and the rate of conversion to conventional parathyroidectomy were investigated. T-Student's, Kolmogorov-Smirnov tests and Odds Ratio were used for statistical analysis.

Results. 1 patient of the group A and 2 of the group B were excluded from the cost analysis because of the conversion to the conventional technique. Concerning the remnant patients, the overall average costs were: for Operative Room, 1186,69 € for the MIVAP group (51 patients) and 836,11 € for the OMIP group ($p < 0,001$); for the Team, 122,93 € (group A) and 90,02 € (group B) ($p < 0,001$); the other operative costs were 1388,32 € (group A) and 928,23 € (group B) ($p < 0,001$). The patient's satisfaction was very strongly in favour of the group B (Odds Ratio 20,5 with a 95% confidence interval).

Conclusions. MIVAP is more expensive compared to the "open" parathyroidectomy under local anaesthesia due to the costs of general anaesthesia and the longer operative time. Moreover, the patients generally prefer the local anaesthesia. Nevertheless, the rate of conversion to the conventional parathyroidectomy was relevant in the group of the local anaesthesia compared to the MIVAP, since the latter allows a four-gland exploration.

KEY WORDS: Primary hyperparathyroidism - Minimally invasive parathyroidectomy - Costs.

Introduction

Primary hyperparathyroidism (PHPT) is the third most frequent disease among the endocrine disorders, with a prevalence of 1-3% in western countries. Moreover, it is the commonest cause of hypercalcemia (1-4). Nowadays, the PHPT is diagnosed increasingly due to the improvement of biochemical test; it allowed the precocious diagnosis and the identification of asymptomatic patients (5,

6). Conventional bilateral neck exploration remains the reference surgical technique, although the hyperproduction of the parathyroid hormone (PTH) is due to a single hyperfunctioning gland (most frequently a parathyroid adenoma) in a high percentage (70-95%) of cases. It could allow to perform a minimally invasive "focused" approach if the preoperative diagnosis of localization is not doubtful, especially in the presence of two concordant imaging procedures, such as ultrasounds (US) and ^{99m}Tc-Sestamibi Scintigraphy (MIBI) (2, 7-11). This focused approach can be performed under general as well as local anaesthesia and it is widely accepted for the sporadic, non-hereditary, uni-focal form (4). The goal of a minimally invasive approach can also be reached with the minimally invasive video-assisted parathyroidectomy (MIVAP), which is an adaptation of the mini-incision cervical procedures to the video-assisted gasless techniques (9, 12, 13). It allows to carry out the parathyroidectomy with even smaller incisions and it assures, at the same time, a wide

¹ Unit of General and Emergency Surgery, Policlinico "P. Giaccone", Palermo, Italy

² Unit of Endocrinology, "V. Cervello" Hospital, Palermo, Italy,

³ Unit of General and Thoracic Surgery, Policlinico "P. Giaccone", Palermo, Italy

⁴ Unit of Clinical Epidemiology and Cancer Registry, Policlinico "P. Giaccone", Palermo, Italy

Corresponding author: Gregorio Scerrino, e-mail: gregorio.scerrino@tiscali.it

© Copyright 2016, CIC Edizioni Internazionali, Roma

four-gland exploration similar to that of the conventional procedure (14). Parallel to the improvement of the surgical techniques, another tool that can optimize the results of a parathyroid excision is the intraoperative parathormone assay (ioPTH). Since it has been first described, during the early nineties, it resulted in an improvement of the cure rate of hyperparathyroidism over 95% of procedures (15-18).

The present study has been performed with the main goal of evaluating the difference in terms of hospitalization costs of the two minimally invasive procedures carried out at our Institution, the minimally invasive “focused” open parathyroidectomy (MIP) under local anaesthesia and the minimally invasive video assisted parathyroidectomy (MIVAP) through a micro-costing method (19). It should be underlined that the Italian Healthcare System is based on Diagnosis Related Groups (DRGs) System (20) adopted in accordance with the specific regional governance, that established a reimbursement of 2.926 Euros for each DRG 289 (parathyroid surgical procedures) (Decree May, the 14th, 2013). Moreover, we investigated the patient’s satisfaction and the conversion rate to conventional parathyroidectomy in the two groups of patients.

Patients and methods

This retrospective study concerned 72 consecutive patients suffering from a PHPT and consecutively enrolled at our institution from 2006 to 2015. The patients had at least one localization exam in which the site of the enlarged parathyroid was clear, concerning at least the side (left/right) of the enlarged gland. The diagnostic workup excluded a coexistent thyroid disease and it was clearly guiding for uni-glandular disease. Therefore, the patients with thyroid disease requiring simultaneous surgery, the multiglandular disease, the biochemical hyperparathyroidism in absence of diagnostic localization, the extra-cervical parathyroid localizations, the patients in which the diagnosis was done during the neck exploration for a thyroid disease, the parathyroid malignancies and the secondary hyperparathyroidism were excluded from the study.

The diagnosis of PHPT was biological and included a preoperative Calcium >10.5 mg/dl and/or a PTH >72 pg/ml. All the patients with a calcium and/or a PTH over the normal range underwent neck US exploration that was performed by an endocrinologist experienced in endocrine neck ultrasounds and repeated by a surgeon also experienced in neck ultrasonic imaging. This exam was carried out with an ultrasound device endowed with a 7,5-10 MHz linear probe. The typical findings indicative of a parathyroid adenoma were a strongly hypoechoic oval focal lesion sited behind the posterior edge of the thyroid gland or caudal the lower pole of the gland.

The vascular pattern could show in some cases a soft intralesional and peripheral signal. The first image is typically associated with an adenoma of the superior parathyroid gland (PIV), the second one could represent an inferior parathyroid adenoma (PIII) as well as a superior one migrated lower down. In this case, the differential diagnosis should be done in view of the position (anterior that mean PIII, or posterior, for PIV). The MIBI was performed using a single tracer, double phase protocol, with dose of 10 mCi of ^{99m}Tc -MIBI injected 15 minutes (early scan) and 120 minutes (late scan) before the planar acquisition of the images of the head, neck and mediastinum. The late acquisition showed the washout of the radioactive tracer from the thyroid and the persistent parathyroid image.

The patients in which the diagnostic workup steered clearly into a single enlarged orthotopic PIII (in particular, if US and MIBI were concordant) were scheduled for OMIP technique carried out under local anaesthesia. In the patients in which the diagnosis was unclear in terms of site of enlarged parathyroid gland (US and MIBI non concordant or one of the two imaging techniques non-diagnostic), or in the cases in which the preoperative diagnosis steered clearly into a PIV, that is deep and posteriorly sited as regards as the inferior laryngeal nerve close to its access into the larynx, we preferred the MIVAP technique, owing to the opportunity of a complete exploration of the thyroid cavity, that could be bilateral in case of need.

Surgical techniques

The OMIP is a well-known surgical technique that can be easily performed under loco-regional or local anaesthesia. Some technical details vary by different surgical groups. In our experience, we usually perform this technique under local anaesthesia and the assistance of an anaesthesiologist with the aim of a light intraoperative sedation. The local anaesthesia is performed just over the enlarged parathyroid gland, identified with a preoperative US, along a line of 2,5 centimetres. The incision is done overlying the anterior border of the sternocleidomastoid muscle (SCM). After the superficial cervical fascia has been prepared, the anterior border of the SCM is separated from the lateral border of the strap muscle, then the superficial component (sternohyoid muscle) is retracted medially, on the contrary the deep component (sternothyroid muscle) is retracted laterally: then, this “zig-zag” access allows to reach the gland head-on. Once the recurrent laryngeal nerve (ILN) has been identified, the parathyroid gland can be separated and removed. This technique is easy and safe for enlarged orthotopic PIII, because of its superficial position above the ILN. In case of a deep PIV it is difficult to carry out and, in our opinion, unsafe.

The MIVAP is a step forward compared to the conventional cervical exploration. In fact, its central approach

is similar and it allows to perform an excision of a parathyroid gland wherever it is sited. Under general anaesthesia, a 1,5 cm median longitudinal incision is performed 2 centimetres above the sternal notch, the preparation of the skin flap is moderate, the linea alba is sectioned for 3-4 centimetres in length. Once the thyroid is visualized, the lobe correspondent to the enlarged parathyroid gland is retracted medially, the skin and the strap muscle retracted laterally after its dissection from the thyroid lobe. A 30°, 5 mm endoscope is inserted through the incision for exploring the space created with the dissection and the retraction. A dissection of the soft tissues hiding the ILN and the parathyroid glands is carried out with dedicated thin spatulas, scissors and aspirators. Once the enlarged gland is identified and prepared, it can be excised with a ligature. We do not use the energy-based surgical device (21) usually adopted for MIVAT. The criteria that led to perform one of the two procedures were the localization of the enlarged gland and the patient's choice. We excluded from the OMIP procedure under local anaesthesia the PIV, because of its depth and its position behind the access of the recurrent laryngeal nerve into the larynx. Once it was clarified that the enlarged gland was a PIII in an orthotopic position, we asked the patients which type of anaesthesia they preferred. The patients that liked better the general anaesthesia underwent always MIVAP. In both cases, the intraoperative monitoring of PTH changes during and after the removal of the enlarged gland is always performed at our institution (ioPTH). The standard sampling is a four-step curve (anaesthesia induction; gland manipulation; 5 minutes after the gland removal; 20 minutes after the gland removal). A PTH drop $\geq 50\%$ in at least one value after the removal and at half events under the threshold limiting value (65 pg/ml) is considered successful.

Cost analysis

With the aim to assess the differences in economic impact of both procedures, we used a micro-costing bottom-

up method, which is the direct sum of every input consumed during the pathway of each patient, from the hospital enrolment to the first clinical examination after the discharge (19). The Table 1 summarizes the variable and fixed costs of each item and the respective sources. Concerning the item "operating room", we referred to the Hospital accounting for the total amount and compared these results to the assessments of Macario (23).

We should underline that the costs of preoperative diagnostic exams (US, MIBI), that have been regularly performed in each patient enrolled, are not considered in this list because these were carried in an outpatient management model. At last, we compared our hospitalization cost with the Sicilian tariff corresponding to the DRG 289.

Patient's satisfaction and conversion rate

We evaluated the overall patient's satisfaction with a Visual Analog 1-10 Scale (VAS) recorded at the first postoperative day. It concerned the entire anaesthetic and surgical experience of the patients that were questioned concerning their general feeling of postoperative comfort.

Statistical analysis

With the aim of verifying if the differences in terms of costs between the two procedures were casual or not, the variable costs of the two groups were compared with the T-Student's test and the Kolmogorov-Smirnov test for parametric variables. The comparison of the patient's satisfaction was performed by calculating the Odds Ratio.

The data were collected in a dedicated database (Microsoft Excel®, Microsoft Corporation, WA, USA).

Results

1 patient of the MIVAP group and 2 patients of the OMIP group have been converted to the conventional technique due to the inefficacious exploration with the minimally invasive procedure. Then the cost analysis con-

TABLE 1 - UNIT COSTS AND SOURCES.

Item	Data source
Operating Room (1)	Hospital accounting in comparison with ref. n. 23
Team (2)	Current Italian Wage Agreement
Other operative costs (3)	Hospital accounting
Hospital stay (two days)	FASDAC* price list, spending document 1/1/2014
Pre- and postoperative diagnostic tests (4)	FASDAC* price list, spending document 1/1/2014

(1) This cost is calculated on the basis of the hourly cost of the operative room.

(2) This cost is calculated according to the hourly pay (nominal gross wage/152) of two surgeons + one anesthesiologist.

(3) Consumable, anesthesia, maintenance costs, equipment depreciation.

(4) Pre- and intraoperative routinary laboratory tests, chest X-ray, ECG, other medical examinations (including ioPTH and postoperative calcemia dosage).

*Supplementary program for medical care, integrated with the national health service (SSN) (22).

cerned 51 patients that underwent MIVAP and 18 patients of the OMIP group.

Assuming that no patient was admitted to hospital before the day in which the surgical procedure was programmed, and that the hospital stay for each patient was 2 postoperative days, according to the available data, deduced from the FASDAC price list, the fixed cost of hospital stay was 560 Euros. By calculating the costs of the each routine exam (laboratory tests, ECG, chest X-ray) from the same source, the total amount of the pre-, intra- and postoperative workup, including ioPTH dosage, the postoperative calcemia and other medical complementary examination could be fixed in 300 Euros. The Table 2 summarizes the variable costs and shows the high significance in the cost differences in favor of the OMIP compared to the MIVAP.

Concerning the item “team” we would underline that only the medical professionals (2 surgeons and 1 anaesthesiologist) were calculated. Other professionals (nurses, technicians, etc.) costs are included in the hourly costs

of the operating room. The “other operative costs” include the equipment depreciation, that concerns the laparoscopic equipment only for the MIVAP procedure.

The Figure 1 summarizes the impact of each item in the total cost of each procedure. Moreover, both procedures are compared to the Sicilian DRG tariff. The MIVAP procedure performed under general anaesthesia was more expensive compared to the OMIP under local anaesthesia. These differences are very likely attributable to the operative time, the consumable and anaesthesia costs, that were all inferior in the OMIP procedure.

The Figure 2 represents in three box-plot graphics the comparison of the costs in the two techniques concerning the specific items “operating room”, “team” and “other operative costs”.

The patient’s satisfaction resulted excellent for 10 patients and fair for 41 of the MIVAP group; excellent for 15 and fair for 3 patients of the OMIP group (Odds Ratio 20,5 with a confidence interval of 95% in favour of the OMIP group, $p < 0,001$).

TABLE 2 - VARIABLE COSTS.

Item	MIVAP costs, Euros (51 patients)	OMIP costs, Euros (18 patients)	p-value
Operating room	1186,69±266,07	836,11±186,71	<0,001
Team	122,93±29,24	90,02±18,50	<0,001 KS=0,00004
Other operative costs	1388,32±295,48	928,23±205,17	<0,001 KS=0,0000026

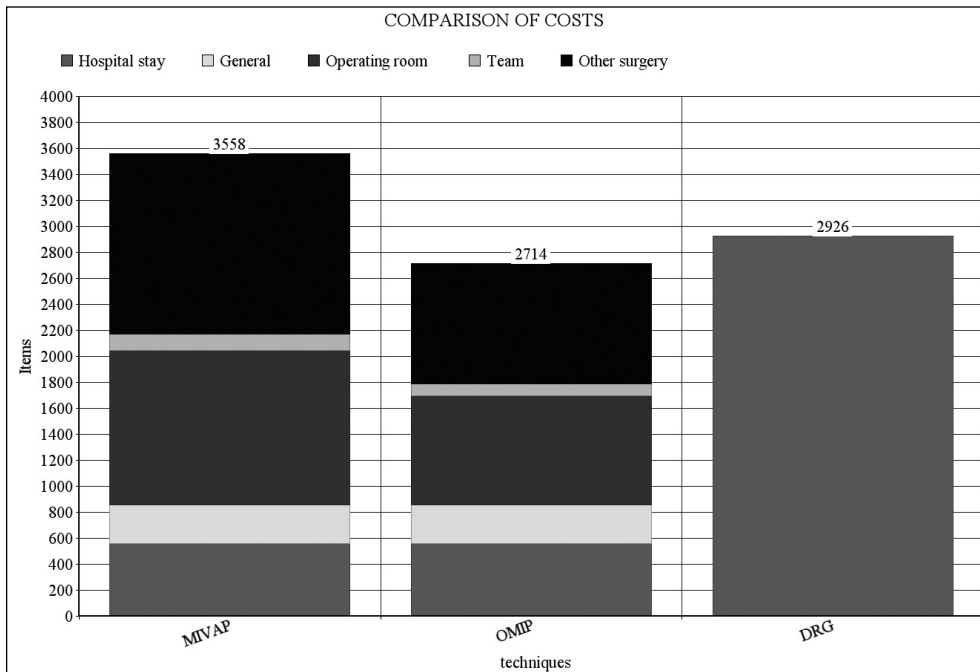


Fig. 1 - Impact of the single items in the total costs of each procedure and comparison of these costs to the DRG tariff in Sicily.

Discussion

As showed elsewhere (24), the present study confirmed that the OMIP, especially if performed under local anaesthesia, is a cost saving procedure compared to the MIVAP. Moreover, the OMIP on the contrary of the MIVAP is slightly cheaper compared to the provided reimbursement of the DRG tariff of the Regional Healthcare System of the Sicily. Although, our data need some specifications: first of all, in our workup we performed regularly two localization imaging exams (US and MIBI) that can be unnecessary in some cases and, on the contrary, even insufficient in other occurrences. In fact, the MIVAP is a technique that allows a wide, bilateral neck exploration, similar to that the conventional procedure at least for parathyroids kept in the neck and it is also indicated for the treatment of multiglandular disease (9). In this perspective, a clear result from a single technique of localization can be satisfying, moreover it could be proposed even for a four-gland neck exploration for primary hyperparathyroidism of unlocated origin. On the contrary, the preoperative imaging can result in a failure because of specific reasons concerning each diagnostic technique. The success of US depends on the skill and experience of the operator; moreover it is limited in obese patients, in looking for small glands, in the already operated neck, in non-typical parathyroid localization (retrotracheal, retroesophageal, in a para-carotid position in the carotid sheath, submandibular), in concomitant thyroid nodules and in multiglandular disease (25). The MIBI can be unsuccessful because of a low retention of the radioactive tracer in the enlarged parathyroid gland or hyperplasia. The two exams in combination reach a 95% of sensitivity, but there are some case of silent imaging (26). More advanced imaging techniques can be useful in some circumstances: the Multiphase Computed Tomography is a well-detailed diagnostic tool, the results of which are still under evaluation (27); the Magnetic Resonance Imaging can help in the localization of mediastinal parathyroid (26). Other advanced diagnostic methods, such as the 18F-fluorodeoxyglucose, 11C-methionine and the 8F-fluorocholine-PET/CT have been studied with debated result, and only the last one showed, in a pilot study, encouraging results (28) and, in any case, these are costly and not widely diffused tools. Due to the uncertainty of the preoperative diagnostic imaging, some intraoperative tools have been proposed for improving the diagnostic performance and the cure rate of the PHPT. The ioPTH is the most diffused tool, able in increasing the safety in the intraoperative recognition of the hyperfunctioning parathyroid(s) gland(s) if performed according to the available criteria for successful parathyroidectomy (18, 26). However, the efficacy and the cost-benefits of this tool if constantly applied are still controversial (29, 30), as well as for the in-

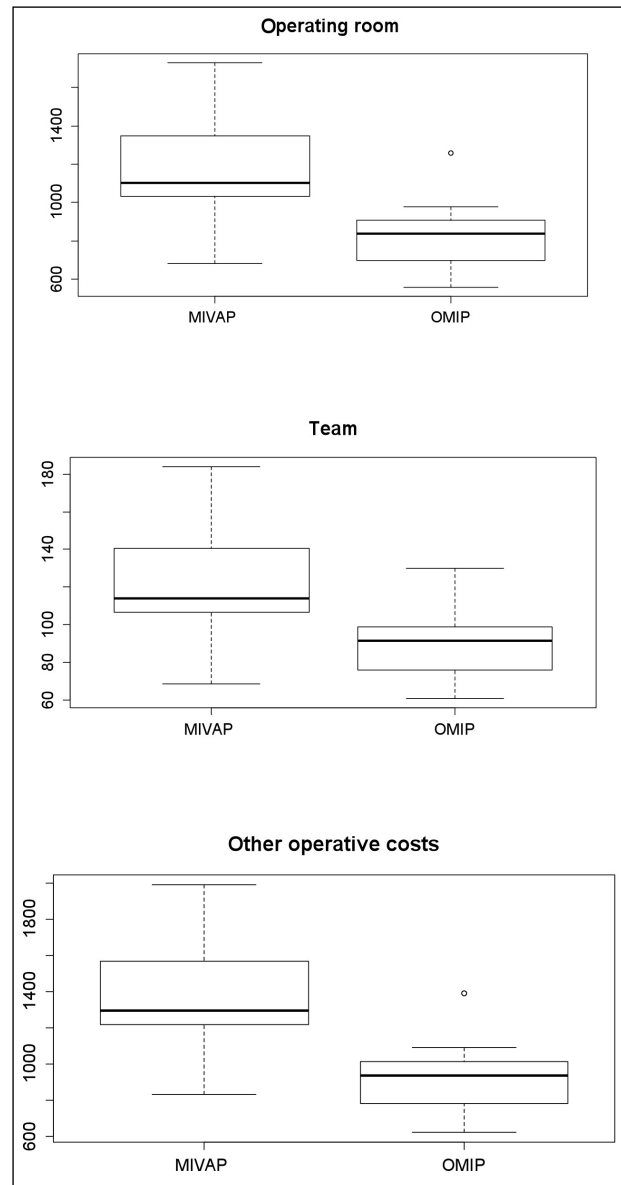


Fig. 2 - Comparison of mean costs of "operating room", "team" and "other operative costs" concerning the two procedures.

traoperative nuclear medicine imaging (31). Concerning the OMIP under local anaesthesia, although it is indicated in the excision of any enlarged parathyroid gland, it requires an intimate knowledge of the anatomic origin and location of the superior gland compared to the inferior one, their relation with the recurrent laryngeal nerve and the possible sites in which they can be found. It is our opinion that, with the OMIP technique, the excision of an enlarged PIII is easier and safer compared to that the PIV. It is due to the more superficial position of the PIII compared to the recurrent laryngeal nerve. On the contrary, the access of this nerve into the larynx resides in a more superficial plane compared to the PIV. Moreover, during

an OMIP procedure the traction could be stronger compared to the MIVAP (24), although no significant differences in terms of complications have been showed in the comparison of the two procedures (9, 24, 32). These are some anatomic pitfalls that led us to prefer to apply the OMIP only for the excision of an enlarged PIII. On the other hand, it should be taken into consideration the preference that the patients showed in favour of a procedure performed under local anaesthesia. In fact, although it is proven that the MIVAT too can be performed under local anaesthesia (24, 26), since it needs a deeper tissue dissection, we prefer the general anaesthesia for performing them. In our opinion, the worst feeling of the patients after a general anaesthesia, which is mainly due to its common symptoms (shivering, nausea, vomiting, dry mouth, sore throat, sleepiness, hoarseness) plays a crucial role, rather than the differences in terms of postoperative pain, in determining the general preference of the patients for the local anaesthesia.

Between the 72 patients of the initial group, 1 patient out of 52 MIVAPs (1,9%) and 2 out 20 OMIPs (10%) needed a conversion to the conventional procedure, in case of doubtful relation between the recurrent laryngeal nerve and the enlarged parathyroid gland.

Concerning the comparison of the costs of each technique of parathyroidectomy with the reimbursement based on the DRG, as layed down by the Regional adaptation of the National Healthcare System, it is clear that the majority of endocrine neck procedure are underfinanced, especially because it does not encourage the introduction of new/alternative surgical techniques, new technologies, devices, aids (33). It should be hoped to identify selection strategies of the patients that need some specific exams or tools in the perspective of curtailing unnecessary charges. In our specific field, we are convinced that the hospital stay could be reduced at only one overnight in a number of cases, given that the management in one-day surgery and even in day-care surgery have been proposed (34-36); moreover, we could select the use of

the ioPTH and start to perform some MIVAP procedures under local anaesthesia with the aim of reducing the specific charges of the general anaesthesia. These measures could increase the number of cases which cost are under the standard value of the reimbursement. In fact, the DRG system should be considered an iso-resource, all-inclusive model. In this perspective, the goal should be the implementation of "low cost" cases as much as possible with the aim of spreading the costs of the more expensive procedures in a wide range of different situations (37). Different strategic measures can be called into question: systematic assessments for improving the efficiency and, at the same time, for reducing the waste of unnecessary tools; implementation of case-selected clinical pathways. In this perspective, the diffusion of high volume surgical units for a narrow range of diseases could improve the outcomes while reducing the costs (38).

Conclusions

The two techniques of parathyroidectomy evaluated in the present study are widely validated procedures that showed to be safe and effective.

The higher costs of the MIVAP is justified because it allows a wide exploration of the neck, similar to that the conventional procedure and, probably, the availability of two concordant imaging exams is not mandatory for performing them. On the other hand, the OMIP showed a wide tolerability when performed under local anaesthesia. At present, this is a cost-saving procedure that meets the criteria stated in our protocols (orthotopic PIII, two imaging exams concordant, no concomitant thyroid disease) only in a minority of cases and that showed a high rate of conversion to the conventional procedure. Further studies are needed for evaluating if some items, usually carried out in our routine, can be avoided with the aim of getting ready less expensive clinical pathways that came close to the amount reimbursed from the Public healthcare System.

References

- Lubitz CC, Stephen AE, Hodin RA, Pandharipande P. Preoperative localization strategies for primary hyperparathyroidism: an economic analysis. *Ann Surg Oncol*. 2012;19(13):4202-9.
- Philippou M, Guérin C, Taieb D, Vaillant J, Morange I, Brue T, Conte-Devolx B, Henry JF, Slotema E, Sebag F, Castinetti F. Bilateral neck exploration in patients with primary hyperparathyroidism and discordant imaging results: a single-center study. *Eur J Endocrinol*. 2014;170(5):719-25.
- Marcocci C, Cetani F. Clinical practice: primary hyperparathyroidism. *N Engl J Med*. 2011;365:2389-97.
- Kelly CWP, Eng CY, Quraishi MS. Open mini-incision parathyroidectomy for solitary parathyroid adenoma. *Eur Arch Otorhinolaryngol*. 2014;271:555-60.
- Lee SW, Park H, Shin JM, Lee YM, Park JH, Koh YW, Mok JO, Kwon KW. Clinical analysis of parathyroid adenoma with primary hyperparathyroidism. *Korean J Otolaryngol- Head Neck Surg*. 2006;49(1):72-8.
- Kim HG, Kim WY, Woo SU, Lee JB, Lee YM. Minimally invasive parathyroidectomy with or without intraoperative parathyroid hormone for primary hyperparathyroidism. *Ann Surg Treat Res*. 2015;89(3):111-6.
- Schulte KM, Kupisti K, Dotzenrath C, Schabram J, Röher HD. The actual role of classic bilateral cervicotomy approach in the era of minimally invasive surgery. *Ann Ital Chir*. 2003;74(4):389-93.

8. Hughes DT, Miller BS, Park PB, Cohen MS, Doherty GM, Gauger PG. Factors in conversion from minimally invasive parathyroidectomy to bilateral parathyroid exploration for primary hyperparathyroidism. *Surgery*. 2013;154(6):1428-35.
9. Del Rio P, Vicente D, Maestroni U, Totaro A, Casoni Pattacini GM, Avital I, Stojadinovic A, Sianesi M. A comparison of minimally invasive video-assisted parathyroidectomy and traditional parathyroidectomy for parathyroid adenoma. *Journal of Cancer*. 2013;4(6):458-63.
10. Ebner Y, Garti-Gross Y, Levy Y, Nabrisky D, Ophir D, Rotman-Pikielny P. Parathyroid surgery: correlation between pre-operative localization studies and surgical outcomes. *Clinical Endocrinology*. 2015;83:733-8.
11. Lumachi F, Zucchetta P, Tregnaighi A, Marzola MC, Cecchin D, Marchesi P, Bui F, Iacobone M. Noninvasive parathyroid imaging in primary hyperparathyroidism. *Ann Ital Chir*. 2003;74(4):385-8.
12. Scerrino G, Paladino NC, Di Paola V, Morfino G, Inviati A, Amodio E, Gulotta G, Bonventre S. Minimally invasive video-assisted thyroidectomy: four-year experience of a single team in a general-surgery unit. *Minerva Chir*. 2013;68(3):307-14.
13. Miccoli P, Bendinelli C, Vignali E, Mazzeo S, Cecchini GM, Pinchera A, Marcocci C. Endoscopic parathyroidectomy: report of an initial experience. *Surgery*. 1998;124:1077-9; discussion 9-80.
14. Joliat GR, Demartines N, Portmann L, Boubaker A, Matter M. Successful minimally invasive surgery for primary hyperparathyroidism: influence of preoperative imaging and intraoperative parathyroid hormone levels. *Langenbecks Arch Surg*. 2015. DOI 10.1007/s00423-015-1358-z.
15. Irvin GL 3rd, Dembrow VD, Prudhomme DL. Operative monitoring of parathyroid gland hyperfunction. *Amer J Surg*. 1991;162(4):299-302.
16. Irvin GL 3rd, Solorzano CC, Carneiro GM. Quick intraoperative parathyroid hormone assay: surgical adjunct to allow limited parathyroidectomy, improve success rate and predict outcome. *World J Surg*. 2004;28(12):1287-92.
17. Romani AM, Panarese A, La torre V, Pironi D, Sardella D, Mancini E, Mazzaferro S, Arcieri S, Filippini A. The role of the intraoperative parathyroid hormone assay in the surgical management of hyperparathyroidism. *Ann Ital Chir*. 2007;78(2):91-6.
18. Kim HG, Kim WY, Woo SU, Lee JB, Lee Y-M. Minimally invasive parathyroidectomy with or without intraoperative parathyroid hormone for primary hyperparathyroidism. *Ann Surg Treat Res*. 2015;89(3):111-6.
19. Frick KD. Micro-costing quantity data collection methods. *Med Care*. 2009;47(7, Suppl. 1):S76-S81.
20. Alati E, Alati A. New aspects of the Italian Health System and the management of medical units and facilities. 3: proposals for the training of personnel for the management of health units and facilities. *Ann Ig*. 1997;9:341-4.
21. Scerrino G, Paladino NC, Di Paola V, Morfino G, Matranga D, Gulotta G, Bonventre S. Total Thyroidectomy performed with the Starion Vessel Sealing System versus the conventional technique: a prospective randomized trial. *Surg Innov*. 2010;17(3):242-7.
22. http://www.manageritalia.it/content/download/serviziFASDAC/regol/FASDAC Nomenclatore tariffario_2.
23. Macario A. What does one minute of operating room cost? *J. Clin Anesth (Editorial)*. 2010;22:233-6.
24. Barczynski M, Papier A, Kenig J, Nawrot I. A retrospective case-controlled study of video-assisted versus open minimally invasive parathyroidectomy. *Videosurgery Miniinv*. 2014;9(4):537-47.
25. Del Rio P, Arcuri MF, Bezer L, Cataldo F, Robuschi G, Sianesi M. Association between primary hyperparathyroidism and thyroid disease. Role of preoperative PTH. *Ann Ital Chir*. 2009;80(6):435-8.
26. Noureldine SI, Gooi Z, Tufano RP. Minimally invasive parathyroid surgery. *Gland Surgery*. 2015;4(5):410-9.
27. Noureldine S, Aygun N, Walden MJ, Assoon A, Gujar SK, Tufano RP. Multiphase computed tomography for localization of parathyroid disease in patients with primary hyperparathyroidism: how many phases do we really need? *Surgery*. 2014;156(6):1300-7.
28. Michaud L, Burgess A, Huchet V, Lefèvre M, Tassart M, Ohnoa J, Kerrou K, Balogova S, Talbot JN, Périé S. Is 18F-fluorocholine-positron emission tomography/computerized tomography a new imaging tool for detecting hyperfunctioning parathyroid glands in primary or secondary hyperparathyroidism? *J Clin Endocrinol Metab*. 2014;99(12):4531-6.
29. Rajeev P, Stechman MJ, Kirk H, Gleeson FV, Mihai R. Safety and efficacy of minimally-invasive parathyroidectomy (MIP) under local anesthesia without intra-operative PTH measurement. *Int J Surg*. 2013;11:275-7.
30. Barczynski M, Golkowski F, Nawrot I. The current status of intraoperative iPTH assay in surgery for primary hyperparathyroidism. *Gland Surgery*. 2015;4(1):36-43.
31. Scerrino G, Castorina S, Lo Piccolo C, Melfa GI, Raspanti C, Richiusa P, Costa RP, Gulotta G. The intraoperative use of the mini-gamma camera (MGC) in the surgical treatment of primary hyperparathyroidism. Technical reports and immediate reports from the initial experience. *Ann Ital Chir*. 2015;86(3):212-8.
32. Barczynski M, Cichon S, Konturek A, Cichon W. Minimally invasive video-assisted parathyroidectomy versus open minimally invasive parathyroidectomy for a solitary parathyroid adenoma: a prospective, randomized, blinded trial. *World J Surg*. 2006;30:721-31.
33. Dionigi G, Bacuzzi A, Boni L, Rausei S, Rovera F, Dionigi R. Visualization versus neuromonitoring of recurrent laryngeal nerves during thyroidectomy: what about the costs? *World J Surg*. 2012;36:748-54.
34. Dulfer RR, van Ginhoven TM, Geilvoet W, de Herder WW, van Eijck CH. Operative treatment of primary hyperparathyroidism in daycare surgery. *Scand J Surg*. 2015;104(3):196-9.
35. Kulkarni RP, Ituarte PH-G, Gunderson D, Yeh MW. Clinical pathways improve hospital resource use in endocrine surgery. *J Am Coll Surg*. 2011;212(1):35-41.
36. Paladino NC, Guérin C, Slotema E, Franco IF, Henry JF, Sebag F. Endoscopic parathyroidectomy. In: Minimally invasive therapies for endocrine neck diseases. (Lombardi C.P., Bellantone R.), Eds. Springer International Publishing, 2016:167-80.
37. Morris L, Arenas MAR, Cerny J, Berger JS, Borrer CM, Ong M, Cayo AK, Graham PH, Grubbs EG, Lee JE, Perrier ND. Streamlining variability in hospital charges for standard thyroidectomy: developing a strategy to decrease waste. *Surgery*. 2014;156(6):1441-9.
38. Abdulla AG, Ituarte PHG, Wiggins R, Teisberg EO, Harari A, Yeh MW. Endocrine Surgery as a model for value-based healthcare delivery. *Surgical Neurology International*. 2012;3:163. <http://www.surgicalneurologyint.com/text.asp?2012/3/1/163/105102>.