

Sarcomatoid Carcinoma of Urinary Bladder: Immunohistochemical Study of an Uncommon Case

Francesco Cappello^a Federico Aragona^a Vincenzo Serretta^b
Giuseppe Randazzo^b Darwin Melloni^b

Institutes of ^aPathological Anatomy and ^bUrology, University of Palermo, Italy

Key Words

Sarcomatoid carcinoma · Urinary bladder tumors · Human pancytokeratin · AE1/AE3 cytokeratins

Abstract

A case of sarcomatoid carcinoma of the bladder is reported herein. Immunohistochemical staining with human pancytokeratin antibody was negative, while vimentin staining was strongly positive, suggesting a diagnosis of sarcoma of the bladder. Further immunohistochemical analysis revealed positivity for AE1/AE3 cytokeratins, permitting a correct diagnosis of sarcomatoid carcinoma of the bladder. It can be difficult to distinguish between sarcomatoid carcinoma, undifferentiated carcinoma and sarcoma, particularly if the biopsy specimens are of small size. In rare cases, sarcomatoid tumors may express epithelial markers different from those revealed by human pancytokeratin staining.

Copyright © 2002 S. Karger AG, Basel

Introduction

Sarcomatoid carcinoma is a rare, malignant, spindle cell neoplasia in which epithelial differentiation can be demonstrated by immunohistochemical or ultrastructural

studies. It may arise in different sites, such as the digestive tract [1, 2], kidney [3], lung [4] and urinary bladder [5–7]. The most common clinical presentation is gross hematuria. Prognosis is poor since 66% of the patients develop metastases within 1 year from diagnosis [8].

Histological and immunohistochemical features of this neoplasm are variable and do not always allow an exact identification, making it difficult to distinguish between sarcomatoid carcinoma, carcinosarcoma and sarcoma, particularly if biopsy specimens are small in size and lack an evident epithelial component [9, 10].

Case Report

A 70-year-old woman was admitted to our hospital due to gross hematuria. Routine hematological examinations were within normal limits. Chest X-ray was normal. Upon abdominal ultrasound, a solid lesion of the left lateral wall of the bladder, 5 cm in diameter, was detected. The lesion was confirmed by IVP, showing a normal upper urinary tract. Abdominal CT scan revealed a solid lesion deeply infiltrating the vesical wall (fig. 1). Lymph node or distant metastases were not evident.

A single solid tumor of the left wall involving the left ureteric orifice was evident upon pre-operative cystoscopy. The pathological examination of TUR biopsy specimens revealed an 'undifferentiated carcinoma' deeply infiltrating the muscular layers.

Radical cystectomy with a Mainz-II diversion was immediately performed.

KARGER

Fax +41 61 306 12 34
E-Mail karger@karger.ch
www.karger.com

© 2002 S. Karger AG, Basel
0042-1138/02/0692-0141\$18.50/0

Accessible online at:
www.karger.com/journals/ui

Dr. Vincenzo Serretta
Via Malaspina 136
I-90145 Palermo (Italy)
Tel./Fax +39 091 6813277
E-Mail vserrett@mbox.incom.it

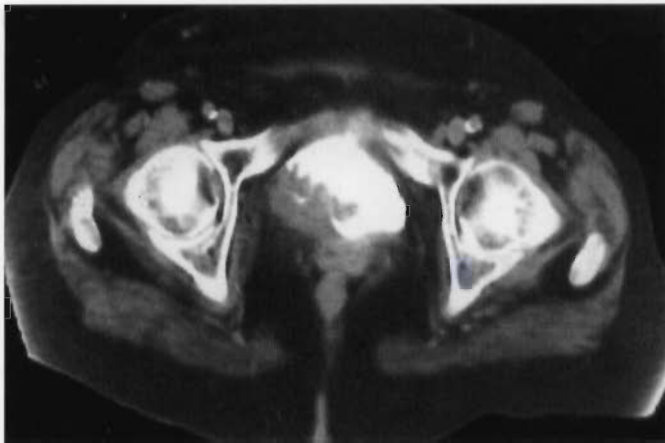


Fig. 1. Pelvic CT-scan revealing a solid lesion deeply infiltrating the vesical wall.

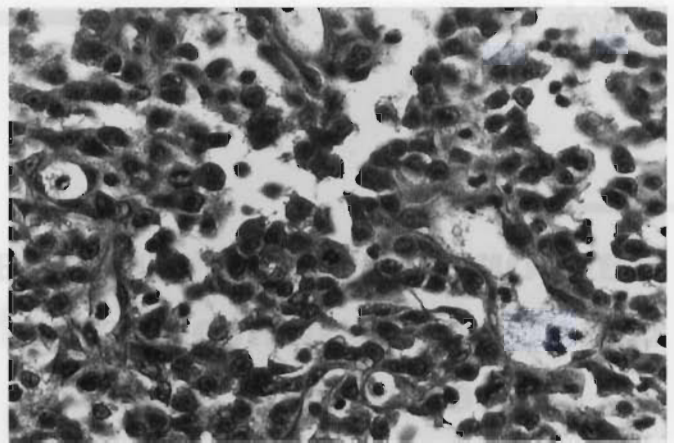


Fig. 2. Microscopic examination revealing the presence of anaplastic and atypical spindle cells, growing in a sarcoma-like fashion. Hyperchromatic nuclei, high mitotic rate and atypical features were present in many fields. HE. $\times 10$.

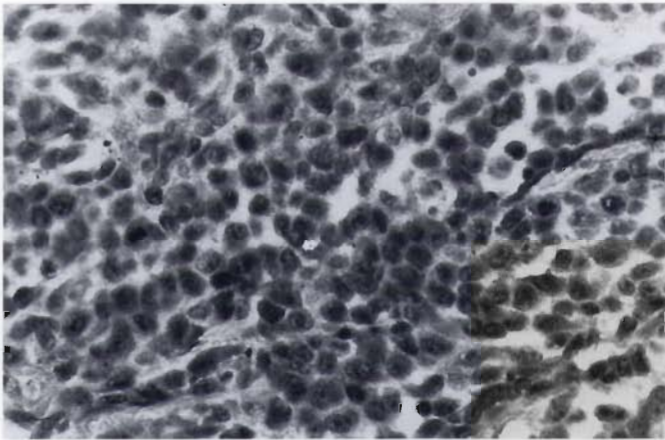


Fig. 3. Immunohistochemistry with AE1/AE3 cytokeratins resulted strongly positive permitting the diagnosis of sarcomatoid carcinoma of the bladder. $\times 10$.

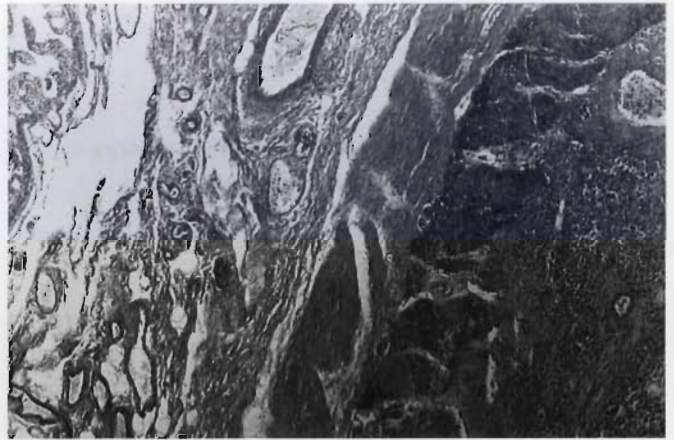


Fig. 4. Histological examination of a tumor lesion of the small bowel revealed microscopic and immunohistochemical features similar to those of the bladder. HE. $\times 4$.

Table 1. Immunohistochemical staining – antibody panel

Antibody	Type	Manufacturer	Catalog No.	Dilution	Presence
Human keratin	Monoclonal	DAKO	N1589	1:50	-
AE1/AE3 keratin	Monoclonal	DAKO	M3515	1:50	+++
Vimentin	Monoclonal	DAKO	H7095	1:50	+++
Actin	Monoclonal	DAKO	M0635	1:50	-
Desmin	Monoclonal	DAKO	M0760	1:50	-
CD34	Monoclonal	DAKO	M7080	1:50	-
FVIII	Monoclonal	DAKO	A0082	1:50	-
HMB45	Monoclonal	DAKO	M0634	1:50	-
EMA	Monoclonal	DAKO	M0613	1:50	-

Microscopic examination revealed the presence of anaplastic and atypical spindle cells, growing in a sarcoma-like fashion. Hyperchromatic nuclei, nucleolar prominence and high mitotic rate with atypical pictures were present in many fields (fig. 2). The muscular layers were infiltrated by neoplastic tissue. Immunohistochemical staining with streptavidin-biotin complex (LSAB2, DAKO) was performed, using the following antibodies at 1:50 dilution: human pancytokeratin, vimentin, actin, desmin, CD34, FVIII-VWF, HMB45 and EMA (table 1). Human cytokeratin was negative, while the neoplasm showed strong vimentin positivity, thus suggesting a diagnosis of sarcoma. All other markers were absent. In order to better immunocharacterize the neoplasm, we also searched for the presence of AE1/AE3 cytokeratins, which were strongly positive (fig. 3), allowing a definite diagnosis of sarcomatoid carcinoma.

Two months later, a lesion of the small bowel was detected. The patient was submitted to ileal resection. The histological examination revealed microscopic and immunohistochemical features similar to those of the bladder (fig. 4). Doubts still exist if this lesion was a metastasis or another primary sarcomatoid tumor. The patient died 3 months later due to pelvic recurrence and multiple lung metastases.

Discussion

High-grade transitional cell carcinoma is associated with squamous, glandular or spindled metaplasia in 20–30% of cases. In 1993, Reuter [6] stated that only when metaplasia involved more than 90% of the tissue can these tumors be termed ‘adenocarcinoma’, ‘squamous carcinoma’ or ‘sarcomatoid carcinoma’. According to this definition, sarcomatoid carcinoma of the bladder is a rare urinary tumor with an incidence of 0.3% of all bladder tumors [8]. The histogenesis of sarcomatoid carcinoma is uncertain and the nomenclature is not consistent. Frequently, sarcomatoid carcinoma and carcinosarcoma are used synonymously. Even if nowadays there is no practical advantage in differentiating sarcomatoid tumors from carcinosarcomas, in the future this distinction could imply a different therapeutic approach. Sarcomatoid carcinoma may be confused with pure sarcoma. The latter does not usually stain for epithelial markers. However, cytokeratin immunoreactivity may be present incidentally in smooth muscle tumors. In smooth muscle, however, keratin expression is never seen in the absence of desmin and vimentin. The use of a wide panel of antibodies to intermediate filament proteins may avoid erroneous diagnosis. Usually, sarcomatoid tumors show strong positivity to vimentin and human cytokeratins, as recently demonstrated in 14 cases by Ikegami et al. [11]. Our diagnosis of sarcomatoid carcinoma was performed using a wide panel of cytokeratin antibodies. Particularly ‘human pancytokeratin’ antibody is specific for 1, 5, 6, 8, 10, 14 and 18

cytokeratins, while ‘AE1/AE3 cytokeratin’ antibody recognizes 2, 4, 5, 6, 8, 9, 10, 14, 15, 16 and 19 cytokeratins. The spectrum of the latter is different and wider. The practical relevance of our observation lies in the evidence that sometimes bladder carcinoma may express epithelial markers different from those commonly used. Using human pancytokeratin only, the immunohistochemical diagnosis would have been that of sarcoma of the bladder.

Ikegami et al. [11], in their experience, reported that the areas of transition between carcinomatoid and sarcomatoid elements were focally evident in each tumor. Epithelial antigens were expressed in all sarcomatoid tumors even if the staining pattern varied from case to case. Moreover, cell adhesion molecules had a higher expression rate in the carcinomatoid than in the sarcomatoid component.

Often, the preoperative histological diagnosis at TUR biopsy is not that of sarcomatoid tumor [12]. In our case, the diagnosis was that of undifferentiated carcinoma.

Lopez-Beltan et al. [13] at the Mayo Clinic recently reviewed 26 cases of sarcomatoid tumors of the bladder. Pure spindle cell carcinoma without any apparent transitional cell carcinoma was detected in 19% of their cases. All the patients had advanced neoplasm at diagnosis and 81% died of sarcomatoid tumor at a mean of 10 months.

In patients with vesical sarcomatoid tumors, a conservative approach rarely provides prolonged survivals. Chemotherapy does not seem to give any additional advantage in survival and progression-free interval. Thus the treatment of patients with sarcomatoid tumors must be aggressive and these tumors must be promptly identified.

Conclusions

It can be difficult to distinguish between sarcomatoid carcinoma, undifferentiated carcinoma and sarcoma, particularly if the biopsy specimens are of small size. Usually, at immunohistochemical examination sarcomatoid tumors show a strong positivity to vimentin and human pancytokeratins. In rare cases, sarcomatoid tumors may express epithelial markers different from those commonly used. A wide panel of cytokeratins must be used and also AE1/AE3 cytokeratin positivity can help to avoid an erroneous diagnosis of sarcoma of the bladder.

RIASSUNTO

Viene presentato un caso di carcinoma sarcomatoide della vescica.

L'esame immunoistochimico è risultato inizialmente negativo per la pancitocheratina umana e positivo per la vimentina suggerendo la diagnosi di sarcoma della vescica. Un'ulteriore analisi immunoistochimica ha però dimostrato la marcata positività per le citocheratine AE1/

AE3 permettendo così la corretta diagnosi di carcinoma sarcomatoide della vescica.

Può essere talora difficile distinguere tra carcinoma sarcomatoide, carcinoma indifferenziato e sarcoma, particolarmente se i prelievi biotipici sono di piccole dimensioni. In rari casi, i tumori sarcomatoidi possono esprimere markers epiteliali differenti da quelli rappresentati dalla pancitocheratina umana.

References

- 1 Ellis GL, Langlos JM, Hefner DK, Hyams VJ: Spindle-cell carcinoma of the aerodigestive tract. An immunohistochemical analysis of 21 cases. *Am J Surg Pathol* 1987;11:335-342.
- 2 Leventon GS, Evans HL: Sarcomatoid squamous cell carcinoma of the mucous membranes of the head and neck: A clinicopathological study of 20 cases. *Cancer* 1981;148:994-1003.
- 3 Deitchman B, Sidhu GS: Ultrastructural study of a sarcomatoid variant of renal cell carcinoma. *Cancer* 1980;46:1152-1157.
- 4 Matsui K, Kitagawa M: Spindle cell carcinoma of the lung. A clinicopathologic study of three cases. *Cancer* 1991;67:2361-2367.
- 5 Ro JY, Ayala AG, Wishnow KI, Ordonez NG: Sarcomatoid bladder carcinoma: clinicopathological and immunohistochemical study on 44 cases. *Surg Pathol* 1988;1:359-374.
- 6 Reuter VE: Sarcomatoid lesions of the urogenital tract. *Semin Diagn Pathol* 1993;10:188-201.
- 7 Di Stefano C, Sebastio N, Pozzoli GL, Arena F, Incarbone GP, Cortellini P: Sarcomatoid carcinoma of the bladder. *Minerva Urol Nefrol* 1999;51:49-51.
- 8 Torenbeck R, Blomjous CEM, de Bruin PC, Newling DWW, Meijer CJLM: Sarcomatoid carcinoma of the urinary bladder: Clinicopathologic analysis of 18 cases with immunohistochemical and electron microscopy findings. *Am J Surg Pathol* 1994;18:241-249.
- 9 Young RH, Eble JN: Unusual forms of carcinoma of the urinary bladder. *Hum Pathol* 1991;22:948-965.
- 10 Cross PA, Eyden VM, Joglekar VM: Carcinosarcoma of the urinary bladder. A light, immunohistochemical and electron microscopical case report. *Virchows Arch A Pathol Anat Histopathol* 1989;415:91-95.
- 11 Ikegami H, Iwasaki H, Ohjimi Y, Takeuchi T, Ariyoshi A, Kikuchi M: Sarcomatoid carcinoma of the urinary bladder: A clinicopathologic and immunohistochemical analysis of 14 patients. *Hum Pathol* 2000;31:332-340.
- 12 Sejima T, Miyagawa I: Sarcomatoid carcinoma of the urinary bladder: 3 case reports. *Urol Intern* 1999;62:51-54.
- 13 Lopez-Beltran A, Pacelli A, Rothenberg HJ, Wollan PC, Zincke H, Blute ML, Bostwick DG: Carcinosarcoma and sarcomatoid carcinoma of the bladder: Clinicopathological study of 41 cases. *J Urol* 1998;159:1497-1503.