



CASE REPORT

Diagnostic laparoscopy in a Gartner's duct cyst

Marco Castagnetti*, Marcello Cimador, Enrico De Grazia

Department of Paediatric Surgery, "Istituto Materno-Infantile", University of Palermo, Via Cardinale Rampolla, 1 – 90142 – Palermo, Italy

Received 7 February 2007; accepted 1 April 2007
Available online 7 June 2007

KEYWORDS

Gartner's duct cyst;
Urinary incontinence;
Laparoscopy;
Single kidney;
Genital anomaly

Abstract Gartner's duct cysts associated with renal dysgenesis are rare malformations and represent a diagnostic challenge. We report on one such case in which final diagnosis was achieved by laparoscopy and discuss the possible role of minimally invasive surgery in the management of this condition.

© 2007 Journal of Pediatric Urology Company. Published by Elsevier Ltd. All rights reserved.

Introduction

Gartner's ducts are remnants of the mesonephric (Wolffian) ducts located on the vagina or cervix in females. Such ducts can sometimes give rise to a cystic mass within the pelvis, called the Gartner's duct cyst (GDC) [1]. GDCs are often associated with unilateral renal dysgenesis [1] and, indeed, such a condition should always be checked for whenever faced with a female patient with a retro-vesical cystic mass and an empty renal fossa [1,2]. Some 40 cases have been reported so far [2] and half of them also presented anomalies and subsequent obstruction of the Müllerian ducts [2].

We report on a case of GDC where final diagnosis was obtained by laparoscopy. The use of minimally invasive surgery in the management of this rare condition is discussed.

Case report

A 6-year-old girl was referred to our institution for urinary incontinence. Family history was negative. The mother reported that the child had had an antenatal diagnosis of left renal dilatation but did not attend any further follow up until referral to our institution. No report of any previous investigation was otherwise available.

An ultrasound scan (USS) showed an empty left renal fossa, a hypertrophic right kidney (longitudinal diameter 87 mm) with mild dilatation of the pelvis, and a septated cyst of 7 cm in diameter sitting behind the bladder (Fig. 1a). Both ovaries were visible and not associated with the cystic mass. The cyst caused compression of the bladder neck. After bladder emptying, a residue of about 30% of bladder capacity was observed (Fig. 1b).

Micturating cysto-urethrography showed no VUR. A 99mTc-DTPA scan was carried out and activity was noticed just above the bladder on the left-hand side (Fig. 2). On suspicion of an ectopic poorly functioning kidney, diagnostic cystoscopy was performed which showed a normal trigone with two ureteric ostia in normal position.

* Corresponding author. Via Ugo Betti, 46, 90147 – Palermo – Italy. Tel.: +39 3402921693; fax: +39 010390622.
E-mail address: marcocastagnetti@hotmail.com (M. Castagnetti).

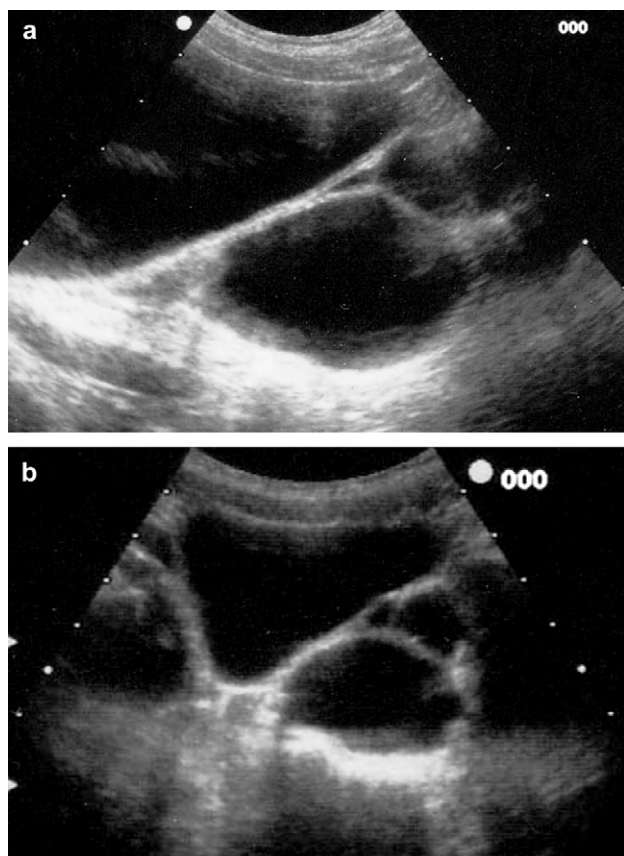


Figure 1 (a) Ultrasound scan showing the presence of a retro-vesical cyst compressing the bladder neck in the sagittal view. (b) Post-micturition residue in the longitudinal view.

Under the same anaesthesia, a 5-mm scope was placed via an open trans-umbilical approach and an accessory 5-mm port inserted in the right iliac fossa. The cystic mass appeared to be located between the vagina, which was displaced forward, and the rectum. No ureteric opening into the mass could be identified. Anatomy of uterus, Fallopian tubes and ovaries was normal (Fig. 3). The cystic mass was

marsupialized into the vagina and its complete emptying checked laparoscopically.

The postoperative course was uneventful and the child is currently well without any evidence of recurring cysts after a follow up of 16 months.

Discussion

GDC is a cystic dilatation of mesonephric duct remnants located on the vagina or cervix. The cyst can be posterior to the bladder, protrude into it mimicking an ureterocele, or protrude into the introitus presenting as an introital mass [1–3]. GDCs can be asymptomatic, cause infections or, as in the present case, cause voiding dysfunction due to extrinsic compression of the bladder neck [4].

The diagnosis should be considered whenever dealing with a female patient having a cystic mass within the pelvis and unilateral renal dysgenesis [1,2]. An ectopic ureter inserted into the cyst is often associated. This corresponds to the ureteric ectopy in the seminal vesicles in males, and, hence, has a defined embryological basis which can also account for the associated renal dysgenesis [1,2].

A variety of investigations have been proposed to assess GDCs including USS, intravenous pyelography, CT, MRI or injection of contrast into the cysts by direct puncture [1–4]. We report here a case in which final diagnosis was achieved by laparoscopy.

In our opinion, there are some major advantages to laparoscopy in this setting, as it can rule out the presence of ureteric ectopy and be used to verify the anatomy of the Müllerian ducts. The latter have been reported to be abnormal in up to 50% of patients with GDC and renal dysgenesis [2], although no such anomaly was present in our patient. Ureteric ectopy was not a real issue in our case since two ureteric ostia were seen on cystoscopy. A case of an ectopic upper pole ureter draining into a GDC has also been reported [5], but even this was unlikely in our patient given the lack of any visible lower pole parenchyma in the left renal fossa on the USS. We instead favour the hypothesis of renal atrophy following a congenital obstructive uropathy suspected antenatally but

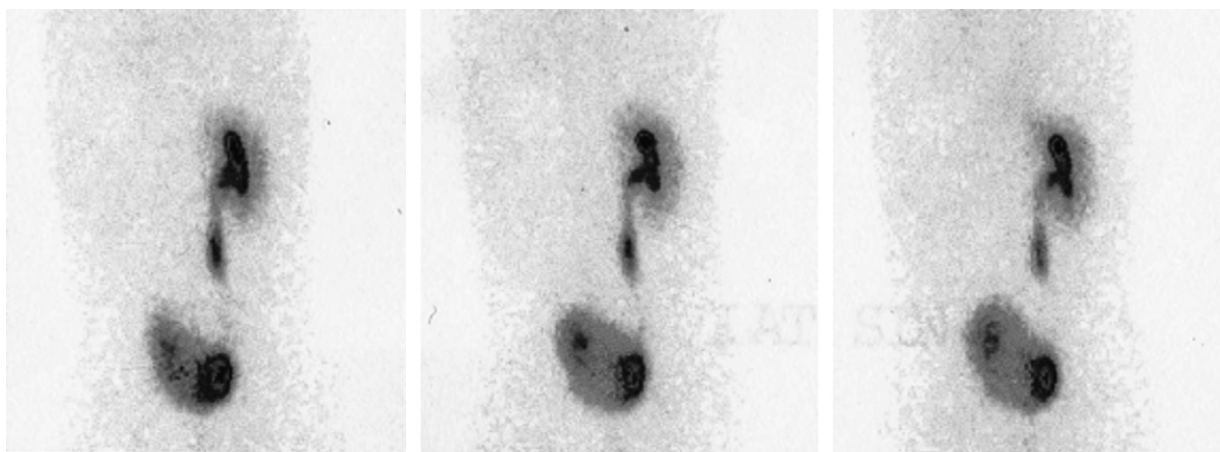


Figure 2 Scintigraphy showing a right kidney with normal activity and a mildly dilated ureter, and the presence of abnormal activity above the bladder on the left-hand side.

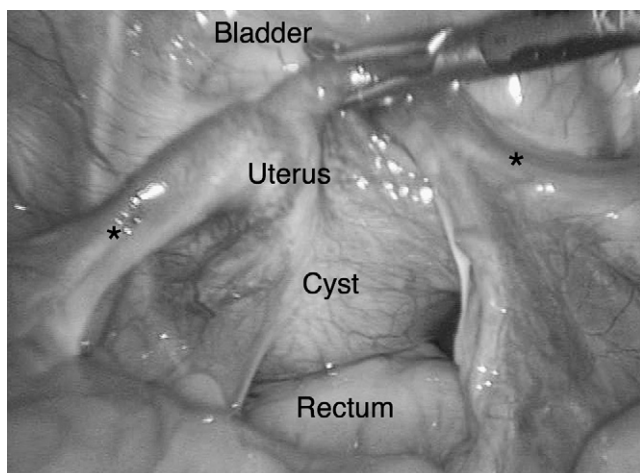


Figure 3 Laparoscopic view showing normal ovaries and tubes (*) opening into the uterus. The vagina is displaced anteriorly by a cystic structure sitting in front of the rectum.

untreated postnatally. An ascending pyelography would have been appropriate during cystoscopy in order to define the anatomy of the reno-ureteral system, but this was not possible for technical reasons. Most of the anatomical information we obtained by laparoscopy could otherwise have been obtained by MRI. Nevertheless, laparoscopy offers the opportunity to simultaneously treat the condition.

Surgical options for the treatment of GDCs include marsupialization into the vagina, cyst un-roofing via the vaginal opening, and partial removal of the cyst via a transperitoneal route [2–4]. The latter could be performed entirely laparoscopically. We opted for marsupialization of the cyst into the vagina in order to obtain external drainage

of the cyst, yet laparoscopy proved helpful to check for full decompression.

Besides, in cases with ureteric ectopy into the cyst, laparoscopy could allow removal of any residual dysplastic renal parenchyma and the associated ureter. Holmes et al. suggested nephro-ureterectomy to be appropriate in this scenario, based on a case in which recurrent infections settled only after nephro-ureterectomy [4].

In conclusion, laparoscopy seems a sensible approach in the diagnostic work up of GDCs in symptomatic patients with radiological evidence of a pelvic cyst and unilateral renal dysgenesis. This technique helps in clarifying the diagnosis, ruling out ureteric ectopy, detecting residual renal parenchyma and evaluating the anatomy of the Müllerian ducts. In addition to these diagnostic goals, laparoscopy allows treatment of the condition through partial excision of the cyst and nephro-ureterectomy in cases with ureteric ectopy in the cyst.

References

- [1] Currarino G. Single vaginal ectopic ureter and Gartner's duct cyst with ipsilateral renal hypoplasia and dysplasia (or agenesis). *J Urol* 1982;128:988–93.
- [2] Sheih CP, Li YW, Liao YJ, Huang TS, Kao SP, Chen WJ. Diagnosing the combination of renal dysgenesis, Gartner's duct cyst and ipsilateral Müllerian duct obstruction. *J Urol* 1998;159:217–21.
- [3] Ohya T, Arie S, Iwai T. Diagnosis and treatment for persistent Gartner duct cyst in an infant: a case report. *J Pediatr Surg* 2002;37:E4.
- [4] Holmes M, Upadhyay V, Pease P. Gartner's duct cyst with unilateral renal dysplasia presenting as an introital mass in a new born. *Pediatr Surg Int* 1999;15:277–9.
- [5] Sheih CP, Liao YJ, Hung CS, Huang TS, Li YW. Duplex kidney, Gartner's cyst and ipsilateral Müllerian duct obstruction. *J Urol* 1998;159:2120–1.