

ADRENAL CAVERNOUS HEMANGIOMA: WHICH CORRECT DECISION MAKING PROCESS?

AGRUSA ANTONINO¹, ROMANO GIORGIO¹, DOMINGUEZ LIGIA JULIANA², AMATO GIUSEPPE¹, CITARRELLA ROBERTO³, VERNUCCIO LAURA², DI BUONO GIUSEPPE¹, SORCE VINCENZO¹, GULOTTA LEONARDO¹, GALIA MASSIMO⁴, MANSUETO PASQUALE², GULOTTA GASPARE¹

¹Department of General Surgery, Urgency and Organ Transplantation, University of Palermo - ²Department of Clinical Medicine and Emerging Disease, Geriatric Unit, University of Palermo - ³Department of Experimental Biomedicine and Clinical Neurosciences, University of Palermo - ⁴Section of Radiology - Di.Bi.Me.F., University of Palermo

ABSTRACT

Introduction: Cavernous hemangioma of the adrenal gland is a rare benign tumor characterized by the presence of blood-filled, dilated vascular spaces. These adrenal masses are usually non-functioning and the patients have no symptoms so the diagnosis is incidental.

Methods: We performed a systematic literature review for all articles published until April 2015. The initial search identified 98 publications. We considered some characteristics: the mean age of the patients at diagnosis was 59 years (range 19 - 84); there were approximately 1.7 times more female patients than male patients; mean diameter of the lesions was 10.3 cm (range 2 - 25). Surgical treatment was more often open with midline or subcostal incision.

Results: From literature analysis we know that small adrenal hemangiomas are usually asymptomatic. Only four patients in our literature review show endocrinologic disturbances with three cases of subclinical Cushing's syndrome and a case of hyperaldosteronism. The pre-operative radiologic features play a fundamental role for correct surgical approach. On enhanced Computed Tomography (CT) scan adrenal hemangiomas tend to be heterogeneous, hypodense lesions with high-density rim of tissue at the periphery. On Magnetic Resonance Imaging (MRI) common findings associated with adrenal hemangiomas are hypointense inhomogeneous masses with central hyperintensity on T1 images and a high intensity peripheral rim on T2 images due to hemorrhage or necrosis.

Conclusion: Laparoscopic adrenalectomy is considered the standard treatment in case of benign lesions. Some authors suggest that the main limitation during laparoscopic dissection for large and potentially malign adrenal tumors is incomplete resection and capsular disruption with increased risk of local recurrence and intra-abdominal neoplastic dissemination. We recommend for these patients an integrated multidisciplinary approach that considers endocrine studies, preoperative radiologic findings and the experience of surgical team.

Key words: adrenal hemangioma, adrenal cavernous hemangioma, laparoscopic adrenalectomy, laparoscopy, laparoscopic surgery, adrenal surgery.

DOI: 10.19193/0393-6384_2016_2_58

Received May 30, 2015; Accepted January 02, 2016

Introduction

Cavernous adrenal hemangioma is a rare benign tumor with specific histological characteristics like the presence of blood-filled, dilated vascular spaces. The first report of cavernous hemangioma of adrenal gland was published in 1955 by Johnson and Jeppesen⁽¹⁾ and today there are more than 90 cases documented in literature. The diagnosis of this type of tumors is usually post-operative

on the basis of histological examination. Adrenal hemangioma is approximately 1,7 times more frequent in female patients than in male patients. The mean age is variable with a wide range (19 - 84 years). There are no data on incidence, but with use of ultrasonography, CT and MRI the discovery of these tumors is increased. Generally adrenal hemangiomas are non-functioning masses so the patients have no specific endocrine symptoms and the diagnosis is incidental.

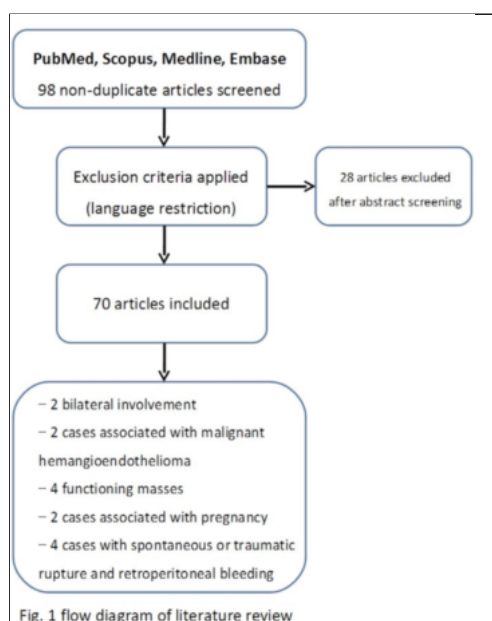
In large adrenal masses the most common symptoms are aspecific flank pain or discomfort, epigastric pain. In this article we consider the international literature to identify pre-operative tumor characteristics and the correct clinical approach.

Materials and methods

We performed a systematic literature search for all articles published until April 2015. We searched Medline, Embase, PubMed and Scopus. Electronic search terms focused on keywords: “adrenal hemangioma”, “adrenal cavernous hemangioma”. We included reports in English and the only inclusion criteria was the correct keywords. Two reviewers independently performed the searches, screened the title and abstracts, and excluded articles which did not met the inclusion criteria.

Results

The initial search identified 98 publications. After screening 28 studies were excluded for language restrictions (Fig. 1). Many articles were case reports, but we included also radiologic studies. We considered some characteristics: the mean age of the patients was 59 years (range 19 - 84); there were approximately 1.7 times more female patients than male patients; mean diameter of the lesions was 10.3 cm (range 2 - 25). Surgical treatment was more often open with midline or subcostal incision. Only in the last years we found the use of laparoscopic surgery with transperitoneal approach and in two cases retroperitoneoscopic technique^(2, 3). Only in two cases we found a bilateral involvement⁽⁴⁾.



In other two cases cavernous hemangioma was associated with malignant hemangioendothelioma^(5, 6). In this literature review adrenal hemangioma were functioning masses in four cases^(4, 7-9).

We reported also urgent laparotomy for retroperitoneal hemorrhage with hypovolemic shock due to rupture of this adrenal mass and in two articles adrenal hemangioma was associated with pregnancy^(10, 11).

Discussion

With the major diffusion in clinical practice of radiologic techniques like ultrasonography and CT scan we frequently find adrenal incidentalomas. These are non-functioning adrenal masses, greater than 1 cm, identified on imaging performed for other indications. At the same time typical known properties of laparoscopic surgery in elective and urgent setting⁽¹²⁻¹⁷⁾ extend the range of treatment of adrenal masses⁽¹⁸⁻²⁰⁾. The international guidelines for management of adrenal tumors consider three fundamental parameters: functional status, lesion size and pre-operative imaging features⁽²¹⁾.

Surgical treatment is generally advocated for all functioning masses, that are per se responsible of endocrine diseases, and for non-functioning lesions larger than 4 cm. Laparoscopic approach is today considered the better technique for treatment of benign small adrenal tumors. Many comparison studies show the decrease of the perioperative morbidity, lower complication rates, less operative blood loss, less postoperative pain and shorter hospital stay compared with open adrenalectomy^(22, 23). Size criteria are still the main subject discussed for the laparoscopic approach to adrenal lesion⁽²⁴⁾. In fact, size is an important variable in predicting malignancy. Tumors larger than 6 cm are likely to be malignant, however many adrenal adenomas are larger than 6 cm^(25, 26).

On the bases of the National Institutes of Health (NIH) consensus statement the incidence of adrenal cortical carcinoma (ACC) is 2% for lesion < 4 cm, 6% for tumors of 4,1- 6 cm in size and 25% for tumors larger than 6 cm⁽²⁷⁾. So, if size is the only criterion to choose the better surgical approach many patients with adrenal benign masses will have an unnecessary open adrenalectomy.

Particularly, for the correct management of these large adrenal lesions we can take advantage of pre-operative imaging features. CT scan and abdominal MRI can demonstrate signs of malignan-

cy like irregular tumor margins, local invasion or periadrenal and diaphragmatic tissue infiltration⁽²⁸⁾.

In these cases laparoscopic approach is contraindicated^(29, 30). From literature analysis we know that small adrenal hemangiomas are usually asymptomatic. Only the large masses manifest clinical non-specific symptoms like flank pain and discomfort, epigastric pain. Only four patients in our literature review show endocrinologic disturbances with three cases of subclinical Cushing's syndrome^(4, 7, 9) and a case of hyperaldosteronism⁽⁸⁾. Although these data all patients with adrenal mass have to undergo complete hormonal tests. The diagnosis of pheochromocytoma can be excluded with normal levels of urinary catecholamines on 24h collection. In these clinical cases of large non-functioning adrenal lesions, the pre-operative radiologic features play a fundamental role for correct surgical approach.

These tumors are primarily vasoformative neoplasms. On enhanced CT scan adrenal hemangiomas tend to be heterogeneous, hypodense lesions with high-density rim of tissue at the periphery. Characteristic calcifications are also reported in 28-87% of cases⁽³¹⁾. These represent phleboliths within the dilated vascular spaces of the lesion and are described as either speckled throughout the lesion or centrally. Although the irregular stellate pattern of calcifications is often considered pathognomonic of adrenal cavernous hemangioma, calcifications lack specificity because are also seen in other adrenal pathology like ACC, hemorrhagic cyst, tuberculosis, neuroblastoma and metastatic melanoma⁽³²⁾.

In the case of differential diagnosis with ACC becomes essential the identification of periadrenal infiltration. MRI may also be helpful. Common findings associated with adrenal hemangioma are hypointense inhomogeneous masses with central hyperintensity on T1 images⁽³³⁾ and a high intensity peripheral rim on T2 images due to hemorrhage or necrosis⁽³⁴⁾. The widespread use of abdominal ultrasonography, CT scan and MRI has resulted in an increased number of incidental findings of adrenal masses. As the frequency of adrenal mass detection has increased, the discovery of rare types of tumors such as hemangiomas has also increased. More frequently this neoplasm arises from liver and skin.

On pathologic analysis adrenal cavernous hemangiomas involve the adrenal cortex that is very thinned. We find multiple dilated vascular channels lined by a single layer of vascular endothelium, extensive central necrotic areas mixed

to sinusoidal dilation and fibrotic septa. These lesions generally present not only areas of hemorrhage, thrombosis, necrosis, but also degeneration and calcification. The etiology of these lesions is unknown and some authors think that arise from the endothelial cells lining blood vessels⁽¹⁰⁾.

They are felt to be congenital with a natural history of enlargement over time due to vascular ectasia. Some authors maintain that adrenal cavernous hemangiomas are much more frequent than reported, but that they are misdiagnosed as necrotic, non-functioning ACC or adrenal cyst with extensive necrosis^(35, 36). In literature we find also two case of coexisting malignant hemangioendothelioma^(5, 6). These hypotheses and observations are interesting for not to underestimate a disease considered benign and lead us to perform a detailed preoperative radiological study.

Because of the rarity of adrenal hemangioma there are currently no guidelines outlining the optimal diagnostic and therapeutic management. We know that more than half of the reviewed patients shows no clinical symptoms, especially when the size of the tumor is small. In fact in literature only four cases report endocrinological diseases. So, we can treat these lesions like non-functioning adrenal masses: when the size of tumor is small without clinical symptoms, a routine follow-up with periodic endocrinologic evaluation and image studies may be considered. However, adrenal hemangioma is a vascular neoplasm and generally presents areas of hemorrhage, thrombosis, necrosis on histological examination and hyperintense images on T2-weighted MRI, so, we must consider the risk of traumatic or spontaneous rupture with retroperitoneal bleeding. This is not an "hypothetical" event because we find four publications of this type in literature⁽³⁶⁻³⁹⁾.

So, rarely these tumors are associated with rupture, hypovolemia secondary to hemorrhage, acute thrombosis and Kasabach-Merritt syndrome⁽⁴⁰⁾. On the contrary, surgical excision seems to be a reasonable strategy for large adrenal cavernous hemangiomas. Laparoscopic adrenalectomy is considered the standard treatment in case of diagnosis of benign lesions. In these cases laparoscopic approach reduces the risk of bleeding due to surgical manipulation. The largest tumor removed with laparoscopic approach is 12 cm in diameter and the surgeons report that a large adrenal cavernous hemangioma should not be considered a contraindication to laparoscopic surgery.

On the other hand only a low percentage of cases of adrenal hemangiomas in our review receives a laparoscopic treatment.

Conclusion

Laparoscopic adrenalectomy is considered the standard treatment in case of diagnosis of benign lesions. Some authors suggest that the main limitation during laparoscopic dissection for large and potentially malignant adrenal tumors is incomplete resection and capsular disruption with increased risk of local recurrence and intra-abdominal neoplastic dissemination. For the correct management of adrenal lesions we can recur to the preoperative CT scan and abdominal MRI that can demonstrate signs of malignancy like irregular margins and peri-adrenal tissue invasion. In these cases laparoscopic approach is contraindicated. If we find these features on intraoperative exploration laparoscopic adrenalectomy should be converted to the open technique. So, we recommend an integrated multidisciplinary approach that considers endocrine studies, preoperative radiologic findings and the experience of surgical team.

References

- Johnson CC, Jeppesen FB. *Hemangioma of the adrenal*. J Urol. 1955 Nov; 74(5): 573-7.
- Todorov G, Iarūmov N, Lukanova TS, Angelov K. *Retroperitoneal endoscopic adrenalectomy for cavernous adrenal hemangioma*. Khirurgiia (Sofia). 2007; (5): 58-9.
- Yagisawa T, Amano H, Ito F, Horita S, Yamaguchi Y, Toma H. *Adrenal hemangioma removed by a retroperitoneoscopic procedure*. Int J Urol. 2001 Aug; 8(8): 457-8.
- Lorenzon L, Ziparo V, Caterino S, Vecchione A, Camboni A, Cavallini M. *Bilateral cavernous hemangiomas of the adrenal glands: presentation and management of an unusual incidental finding*. Ann Ital Chir. 2013 Nov-Dec; 84(6): 693-7.
- Bozkurt O, Demir Ö, Yener S, Tuna B, Seçil M, Yörükoğlu K. *Malignant epithelioid hemangioendothelioma of the adrenal gland treated by laparoscopic excision*. Urology. 2015 Mar;85(3):e15-6. doi: 10.1016/j.urology.2014.12.016.
- Nakagawa N, Takahashi M, Maeda K, Fujimura N, Yufu M. *Case report: adrenal haemangioma coexisting with malignant haemangioendothelioma*. Clin Radiol. 1986 Jan; 37(1): 97-9.
- Oishi M, Ueda S, Honjo S, Koshiyama H, Yuba Y, Takabayashi A. *Adrenal cavernous hemangioma with subclinical Cushing's syndrome: report of a case*. Surg Today. 2012 Oct;42(10):973-7. doi: 10.1007/s00595-012-0203-z.
- Ng AC, Loh HL, Shum CF, Yip SK. *A case of adrenal cavernous hemangioma presenting with progressive enlargement and apparent hormonal hypersecretion*. Endocr Pract. 2008 Jan-Feb; 14(1): 104-8.
- Stumvoll M, Fritsche A, Wehrmann M, Dammann F, Becker HD, Eggstein M. *A functioning adrenocortical hemangioma*. J Urol. 1996 Feb; 155(2): 638.
- Noh JJ, Choi SH, Hwang HK, Kang CM, Lee WJ. *Adrenal cavernous hemangioma: a case report with review of the literature*. JOP. 2014 May 27;15(3):254-7. doi: 10.6092/1590-8577/2402.
- Aftalion B, Chen SS. *Huge hemangioma of the adrenal gland associated with pregnancy. A case report*. J Reprod Med. 1988 Mar; 33(3): 327-8.
- Romano G, Agrusa A, Chianetta D, Frazzetta G, Sorce V, Di Buono G, Gulotta G. *Laparoscopic management of adrenal tumors: a four-year experience in a single center*. Minerva Chirurgica 2014; Vol. 69, Issue 2, Suppl. 1: 125-129.
- Agrusa A, Romano G, Frazzetta G, Chianetta D, Sorce V, Di Buono G, Gulotta G: *Role and outcomes of laparoscopic cholecystectomy in the elderly*. Int J Surg. 2014;12 Suppl 2:S37-9. doi: 10.1016/j.ijssu.2014.08.385
- Romano G, Agrusa A, Frazzetta G, De Vita G, Chianetta D, Di Buono G, Amato G, Gulotta G: *Laparoscopic drainage of liver abscess: case report and literature review*. G Chir. 2013 May-Jun; 34(5-6): 180-2.
- Agrusa A, di Buono G, Chianetta D, Sorce V, Citarrella R, Galia M, Vernuccio L, Romano G, Gulotta G: *Three-dimensional (3D) versus two-dimensional (2D) laparoscopic adrenalectomy: A case-control study*. Int J Surg. 2015 Dec 18. pii: S1743-9191(15)01441-7. doi: 10.1016/j.ijssu.2015.12.055. [Epub ahead of print]
- Agrusa A, Romano G, Di Buono G, Dafnomili A, Gulotta G: *Laparoscopic approach in abdominal emergencies: a 5-year experience at a single center*. G Chir. 2012 Nov-Dec; 33(11-12): 400-3.
- Agrusa A, Frazzetta G, Chianetta D, Di Giovanni S, Gulotta L, Di Buno G, Sorce V, Romano G, Gulotta G: *"Relaparoscopic" management of surgical complications: The experience of an Emergency Center*. Surg Endosc. 2015 Oct 21. [Epub ahead of print]
- Agrusa A, Romano G De Vita G, Frazzetta G, Chianetta D, Di Buono G, Gulotta G. *Adrenal gunshot wound: Laparoscopic approach. Report of a case*. Int J Surg Case Report 2014; 5(2): 70-2
- Romano G, Cocchiara G, Calderone F, Buscemi G, Gioè FP, Alongi G, Buscemi G, Romano M. *Laparoscopic treatment of adrenal myelolipoma: case report and review of the literature*. G Chir. 2006 May; 27(5): 228-31.
- Agrusa A, Romano G, Salamone G, Orlando E, Di Buono G, Chianetta D, Sorce V, Gulotta L, Galia M, Gulotta G. *Large cavernous hemangioma of the adrenal gland: Laparoscopic treatment. Report of a case*. Int J Surg Case Rep. 2015;16:150-3. doi: 10.1016/j.ijscr.2015.09.040
- Terzolo M, Stigliano A, Chiodini I, Loli P, Furlani L, Arnaldi G et al: *AME position statement of adrenal incidentaloma*. Eur J Endocr/European Federation of Endocrine Societies 2011; 164: 851-70.

- 22) Hazzan D, Shiloni E, Golijanin D, Jurim O, Gross D, Reissman P. *Laparoscopic vs open adrenalectomy for benign adrenal neoplasm*. *Surg Endosc* 2001; 15: 1356-8.
- 23) Pisano G, Calò PG, Piras S, Pisano U, Nicolosi A. *Laparoscopic adrenalectomy in a case of congenital duplication of the inferior vena cava. Case report*. *Ann Ital Chir*. 2013 Jul 25; 84.
- 24) Agrusa A, Romano G, Frazzetta G, Chianetta D, Sorce V, Di Buono G, Gulotta G. *Laparoscopic adrenalectomy for large adrenal masses: single team experience*. *Int J Surg*. 2014;12 Suppl 1:S72-4. doi: 10.1016/j.ijssu.2014.05.050
- 25) Conzo G, Musella M, Corcione F, De Palma M, Ferraro F, Palazzo A, Napolitano S, Milone M, Pasquali D, Sinisi AA, Colantuoni V, Santini L. *Laparoscopic adrenalectomy, a safe procedure for pheochromocytoma. A retrospective review of clinical series*. *Int J Surg* 2013, 11:152-156.
- 26) Conzo G, Musella M, Corcione F, De Palma M, Avenia N, Milone M, Della Pietra C, Palazzo A, Parmeggiani D, Pasquali D, Sinisi A, Santini L. *Laparoscopic treatment of pheochromocytomas smaller or larger than 6 cm A clinical retrospective study on 44 patients. Laparoscopic adrenalectomy for pheochromocytoma*. *Ann Ital Chir* 2012; 84: 417-422.
- 27) *NIH state-of-the-science statement on management of the clinically inapparent adrenal mass ("incidentaloma")*. *NIH Consens State Sci statements* 2002; 19: 1-25.
- 28) Agrusa A, Romano G, Chianetta D, De Vita G, Frazzetta G, Di Buono G, Sorce V, Gulotta G. *Right diaphragmatic injury and lacerated liver during a penetrating abdominal trauma: case report and brief literature review*. *World J Emerg Surg*. 2014 Apr 28;9:33. doi: 10.1186/1749-7922-9-33.
- 29) Lombardi CP, Raffaelli M, De Crea C, Boniardi M, De Toma G, Marzano LA, Miccoli P, Minni F, Morino M, Pelizzo MR, Pietrabissa A, Renda A, Valeri A, Bellantone R. *Open versus endoscopic adrenalectomy in the treatment of localized (stage I/II) adrenocortical carcinoma: results of a multiinstitutional Italian survey*. *Surgery*. 2012 Dec; 152(6): 1158-64.
- 30) Benassai G, Desiato V, Benassai G, Bianco T, Sivero L, Compagna R, Vigliotti G, Limite G, Amato B, Quarto G. *Adrenocortical carcinoma: what the surgeon needs to know. Case report and literature review*. *Int J Surg*. 2014;12 Suppl 1:S22-8. doi: 10.1016/j.ijssu.2014.05.030.
- 31) Edwards JP, Stuart HC, Urbanski SJ, Pasiaka JL. *A rare cavernous hemangioma of the adrenal gland*. *Int J Surg Case Rep*. 2014;5(2):52-5. doi: 10.1016/j.ijscr.2013.11.003.
- 32) Quildrian SD, Silberman EA, Vigovich FA, Porto EA. *Giant cavernous emangioma of the adrenal gland*. *Int J Surg Case Rep* 2013; 4: 219-221.
- 33) Telem DA, Nguyen SQ, Chin EH, Weber K, Divino CM. *Laparoscopic resection of giant adrenal cavernous hemangioma*. *JLS*. 2009 Apr-Jun; 13(2): 260-2.
- 34) Kieger AJ, Nikolaidis P, Casalino DD. *Adrenal gland emangioma*. *J Urol* 2011; 186: 2415-6.
- 35) Hamrick-Turner JE, Cranston PE, Shipkey FH. *Cavernous hemangioma of the adrenal gland: MR findings*. *Magnetic Resonance Imaging* 1994; 12: 1263-7.
- 36) Gómez Rebollo C, Rojo Carmona LE, Márquez Moreno AJ, Domínguez Gallego E, Aguilar Cuevas R, Castillo Gallardo E, Ruiz Escalante JF, Acebal Blanco MM. *Adrenal cavernous hemangioma: is presurgical diagnosis with imaging test possible*. *Arch Esp Urol*. 2013 Apr; 66(3): 313-6.
- 37) Paluszkiewicz P, Ambroziak I, Hołyńska-Dąbrowska K, Siezieniewska-Skowrońska Z, Paluszkiewicz A. *Spontaneous rupture of adrenal haemangioma mimicking abdominal aortic aneurysm rupture*. *Arch Med Sci*. 2010 Mar 1; 6(1): 122-5.
- 38) Forbes TL. *Retroperitoneal hemorrhage secondary to a ruptured cavernous hemangioma*. *Can J Surg*. 2005 Feb; 48(1): 78-9.
- 39) Fernández Ruiz M, Díez Ferez P, Vizcaino López A, Fernández Fernández A, Martínez Pardavila R, Pou Santonja G, Gracia Marzo A. *Adrenal hemangioma: unusual cause of retroperitoneal hemorrhage*. *Arch Esp Urol*. 1995 Jan-Feb; 48(1): 82-5.
- 40) Novo G, Corrado E, Tortorici E, Novo A, Agrusa A, Saladino V, Marturana I, Lentini R, Ferrandes M, Visconti C, Massenti F, D'Arienzo M, Vitale F, Gulotta G, Novo S. *Cardiac risk stratification in elective non-cardiac surgery: role of NT-proBNP*. *Int Angiol*. 2011 Jun; 30(3): 242-6.

Corresponding author

AGRUSA ANTONINO

Department of General Surgery, Urgency and Organ Transplantation, University of Palermo (Italy)