



Association between asymptomatic carotid atherosclerosis and degenerative aortic stenosis

Giuseppina Novo, Francesco Paolo Guarneri*, Giovanni Ferro, Rosario Russo, Khalil Fattouch, Salvatore Novo

Division of Cardiology, University of Palermo, Via del Vespro n.129, C.A.P. 90127 Palermo, Italy

ARTICLE INFO

Article history:

Received 8 March 2012

Received in revised form

1 June 2012

Accepted 6 June 2012

Available online 16 June 2012

Keywords:

Aortic stenosis

Atherosclerosis

Echocardiogram

Echo-color doppler

ABSTRACT

Objective: Degenerative aortic stenosis shows similarities with atherosclerosis. To confirm the hypothesis that aortic stenosis is an “atherosclerosis-like” disease, we investigated the association between degenerative aortic stenosis and atherosclerosis of carotid arteries.

Methods: We studied 270 consecutive patients, 135 with degenerative aortic stenosis (trans-aortic peak velocity ≥ 2 m/sec) and other 135 subjects without aortic valve disease. All patients underwent echocardiography and ultrasound scan of the supra-aortic trunks to assess the presence of plaque and/or intima-media thickening (IMT).

Results: Atherosclerosis of carotid arteries (IMT and plaque) was significantly more frequent in patients with aortic stenosis than in controls (95.5% vs. 66.6%, $p < 0.0001$). The same result was confirmed as concerns carotid plaques (69.6% vs. 42.2%, $p < 0.0001$). In addition, there was a significant association between aortic stenosis and degenerative carotid plaque (OR = 3.13; 95% C.I. = 1.90–5.17). Thus the presence of a linear correlation between the trans-aortic peak velocity of the cases and the thickness of the plaques and IMT was evaluated by calculating the coefficient of correlation ($R = 0.15$ for plaque and $R = 0.53$ for IMT).

Conclusions: The presence of carotid atherosclerosis is associated with degenerative aortic stenosis and the severity of aortic stenosis corresponds to an increase of the thickness of plaque and IMT. This relationship is quite new.

Our result strengthens the pathogenetic hypothesis “atherosclerosis-like” of degenerative aortic stenosis and suggest the ultrasound scan as a non invasive method for risk stratification in patient with aortic stenosis, with therapeutic implications especially for higher risk subgroups.

© 2012 Elsevier Ireland Ltd. All rights reserved.

1. Introduction

In the past aortic stenosis was considered a disease related to aging and based on the *passive* phenomenon of “wear and tear”. Today, many studies have shown that it is rather caused by an *active* process, related not only to age but also to the contribution of multiple risk factors and to genetic predisposition. So it shows lots of similarities with the atherosclerotic process.

The aortic valve stenosis is probably an inflammatory disease similar to atherosclerotic process. The carotid district can be easily explored by Doppler ultrasound and it can be used as a valid surrogate marker of coronary atherosclerosis and multi-district atherosclerotic disease [1]. So a frequent coexistence of asymptomatic carotid atherosclerosis and degenerative aortic stenosis could

confirm the hypothesis “atherosclerosis-like” of the pathogenesis of aortic stenosis. As result, we could suggest ultrasound scan of carotid arteries as useful technique in the stratification of cardiovascular risk in patients with degenerative aortic stenosis, with several implications on the treatment strategy, especially for higher risk subgroups, that is those with at least one of the following characteristics: presence of manifest CV disease, renal impairment, diabetes mellitus type 2, hypertension with left ventricular hypertrophy, estimated risk of 20% at ten years. So, the finding of elevated intima-media thickness or atherosclerotic plaque in patients with degenerative aortic stenosis is an index of higher cardiovascular risk as it is related to the presence of coronary atherosclerosis.

2. Materials and methods

We performed a case–control study evaluating 270 consecutive patients, of whom 135 with degenerative aortic stenosis and other

* Corresponding author. via Giuseppe pagano n.14, C.A.P.90129 palermo, Italy. Tel.: +39 3283739828; fax: +39 916554301.

E-mail address: francescoguarneri@hotmail.it (F.P. Guarneri).

135 subjects without aortic valve disease matched to cases by sex, age and the presence or absence of coronary artery disease. All patients were admitted to echocardiographic laboratory in the Department of Cardiology of the University of Palermo and evaluated between 2007 and 2011. All the patients gave their consent by signing a form of informed consent. The diagnosis of aortic stenosis had been made on the basis of physical examination and trans-thoracic echocardiogram. All the patients underwent a trans-thoracic echocardiogram at the time of enrollment using an Acuson Sequoia echocardiograph with a 2.5 MHz probe. Patients with a trans-aortic peak velocity ≥ 2 m/sec were included in the group of cases. We excluded patients with a different etiology from a degenerative one (congenital or rheumatic). In particular we excluded patients with bicuspid or unicuspid valve.

Trans-aortic peak velocity, mean and maximum gradient, ejection fraction of each patient in the group of cases were recorded. We also recorded trans-aortic peak velocity and ejection fraction in the group of controls. The severity of valvular disease was classified according to the guidelines of European Association of Echocardiography/American Society of Echocardiography 2009 (E.A.E./A.S.E.) [2]. This is the easiest and the least invasive way to determine the degree of the valvular disease.

Medical history of all patients was collected, taking notes of age, sex, presence of cardiovascular risk factors (hypertension, diabetes mellitus, cigarette smoking, family history of cardiovascular disease, Chronic Kidney Disease, dyslipidemia) as well as their history of ischemic heart disease. All underwent a complete lipid evaluation (total cholesterol, HDL-C, LDL-C, triglycerides) and an echo-color Doppler of the supra-aortic trunks in order to assess the presence of plaque or intima-media thickening (IMT) using an ultrasound Esaote MyLab 30 with a 7.5 MHz linear probe. The intima-media thickness, measured as a distance between the edge of the vessel lumen and adventitia margin, was considered increased if between 0.9 and 1.5 mm [3], instead circumscribed plaque was defined a protrusion >1.5 mm.

We also measured the thickness of atherosclerotic plaques and IMT in the two groups of study.

Data were expressed as mean \pm standard deviation (S.D.) or as a percentage. It was considered statistically significant a value of $p < 0.05$. The presence of a statistically significant association between the analyzed variables was estimated by odds ratio.

We calculated the χ^2 value and the t -test to assess the differences between the variables.

We also measured the Pearson's coefficient of correlation (R) between the trans-aortic peak velocity and the thicknesses of plaque and IMT in the population of cases and controls.

3. Results

Table 1 shows the baseline characteristics of the patients studied and the distribution of risk factors. The male/female ratio was 130/140, mean age was 74.47 ± 7.84 years.

The groups of cases and controls were homogeneous for cardiovascular risk factors and lipid profile (Table 2). In fact there were no statistically significant differences.

Table 3 shows some of the main echocardiographic parameters of the group of cases in reference to the presence of aortic stenosis and in the group of controls.

95.5% of the 135 patients with aortic stenosis, studied by echo-color Doppler of the supra-aortic trunks, had an atherosclerotic disease of carotid arteries. In particular, 51.8% had intima-media thickening and 69.6% had an atherosclerotic plaque (haemodynamically significant in 9.57% of patients).

Echo-color Doppler evaluation allowed to detect the presence of asymptomatic carotid atherosclerosis in 66.6% of the 135 controls;

Table 1
Comparison of the baseline characteristics of cases and controls.

	Cases	Controls	p
Age	74.47 ± 7.84 ($n = 135$)	74.06 ± 7.67 ($n = 135$)	0.664 ^a
Sex (m/f)	65/70 ($n = 135$)	65/70 ($n = 135$)	0.995 ^b
Diabetes mellitus	46.1%	39.2%	0.328 ^b
Smoke	46.9%	36.6%	0.956 ^b
Hypertension	75.8%	71.85%	0.564 ^b
Family history	51.6%	36.6%	0.141 ^b
Obesity	21.2%	18.1%	0.826 ^b
Renal failure	13.5%	5.26%	0.145 ^b
Dyslipidemia	40.7%	38.1%	0.868 ^b

^a t -Test.

^b χ^2 Pearson with Yates' correction.

Table 2
Comparison of laboratory characteristics in cases and controls.

	Cases ($n = 135$)	Controls ($n = 135$)	t -Test
TOTAL CHOL [mg/dL]	194.27 ± 48.06	187.63 ± 54.27	$p = 0.551$
TRIG [mg/dL]	103.76 ± 45.55	97.33 ± 39.80	$p = 0.503$
HDL-C [mg/dL]	47.47 ± 16.90	52.24 ± 19.80	$p = 0.233$
LDL-C [mg/dL]	100.83 ± 43.42	93.52 ± 29.34	$p = 0.394$

42.2% presented a plaque atherosclerotic (of which 7.59% were haemodynamically significant), while 31.62% had intima-media thickening.

Carotid atherosclerosis was statistically more frequent in patients with aortic stenosis than in controls (95.5% vs. 66.6%; $p < 0.0001$). Moreover the presence of carotid plaques was significantly more frequent in cases (69.6%) compared to controls (42.2%) ($p < 0.0001$). In addition, there was a significant association between aortic stenosis and degenerative carotid plaque which was quantified and the extent of such correlation was significant ($OR = 3.13$; 95% confidence interval between 1.90 and 5.17). It was also estimated the mean thickness of the plaque and the IMT in the two populations and it was shown that in the cases the mean thickness of plaques was 2.68 ± 0.43 and the IMT was 1.34 ± 0.3 , while in the controls the mean thickness of the plaques was 2.31 ± 0.23 and the IMT was 0.30 ± 1.2 . Moreover we calculated the mean values of carotid overall thickness and it resulted to be higher in the group of cases (2.48 ± 0.80 vs. 1.78 ± 0.35) (Table 4). Thus the presence of a linear correlation between the trans-aortic peak velocity of the cases and the thickness of the plaques and of the IMT was evaluated by calculating the Pearson's coefficient of correlation (R). So R values were 0.15 for plaque and 0.53 for IMT (Fig. 1). Therefore there is a positive correlation between these variables and this shows that to the increasing of the severity of aortic stenosis corresponds an increase of the thickness of plaque and IMT. In addition there is not a positive correlation between trans-aortic peak flow velocity and the values of IMT in the control group ($R = -0.21$). This finding further strengthens the hypothesis of an association between carotid atherosclerosis and degenerative aortic stenosis and the correlation between the severity of aortic stenosis and the values of intima-media thickness.

Table 3
Main echocardiographic parameters of the population of cases and controls in the study.

	Cases ($n = 135$)	Controls ($n = 135$)
Max ao vel [m/s]	2.71 ± 0.81	1.37 ± 0.74
Max grad [mmHg]	40 ± 23.87	n.v.
Mean grad [mmHg]	28.95 ± 16.58	n.v.
EF [%]	54.39 ± 9.02	55.5 ± 2.31

Table 4

Mean values of carotid thickness in the study groups.

	Cases	Controls
Carotid overall thickness (mm)	2.48 ± 0.80	1.78 ± 0.35
Plaques thickness (mm)	2.68 ± 0.43	2.31 ± 0.23
Intima-media thickness (mm)	1.34 ± 0.3	0.30 ± 1.2

4. Discussion

In the last century the pathogenesis of degenerative aortic stenosis was attributed to a “passive” process. It was believed that it was secondary to the progressive deposition of calcium on the valve leaflets, due to a prolonged “wear and tear” [4]. Many predisposing factors such as age, hypertension, and the turbulence of perivalvular blood flow, contribute to increase this process and favor the deposition of aggregates of calcium in the aortic cusps, especially on the arterial side of the valve leaflets, more subject to hemodynamic stress.

However, as suggested by several recent studies, the pathogenesis of degenerative aortic stenosis is a real “active” process, which provides significant similarities with atherogenesis, and, because of this analogy, it is legitimate to speak of a pathogenesis “atherosclerosis-like” [5–7].

Many clinical studies have now confirmed that the detection of asymptomatic carotid atherosclerosis is an early marker of ischemic heart disease and increased cardiovascular risk [8,9]. Moreover, it has been shown that the presence of carotid atherosclerotic disease is a valid marker of coronary atherosclerosis in subjects with symptomatic aortic stenosis [10].

Other studies have then shown that intima-media thickening (IMT) increases in patients with aortic stenosis and higher IMT values have been observed in patients with aortic stenosis and coronary artery disease [11]. According to other studies the value of IMT also increases linearly with the extent of valvular calcification [12].

Aim of our study was to verify the presence of an association between degenerative aortic stenosis and carotid plaque. This relationship is quite new in this field of study. We have thus demonstrated the frequent coexistence of carotid atherosclerosis and aortic stenosis and the presence of a strong statistically significant association between these two variables.

Moreover a positive linear correlation between the severity of aortic stenosis and thickness of the plaque and IMT has been demonstrated only in the group of cases and not in controls.

This result is a novelty and it strengthens the pathogenic hypothesis “atherosclerosis-like” of degenerative aortic stenosis.

One of the clinical implications of these results could be the application of the drugs currently used to slow the progression of atherosclerosis also in the treatment of aortic stenosis.

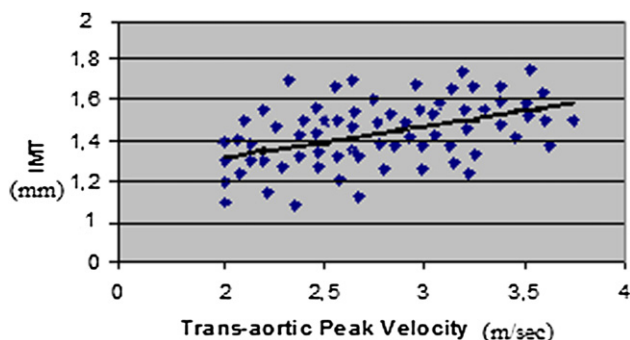


Fig. 1. Scatter Plot representation of the correlation between the severity of aortic stenosis and Intima-media thickness.

However, the outcomes collected so far in literature did not lead to unequivocal results, and, although the majority of retrospective studies have demonstrated the validity of the statins as cholesterol-lowering therapy in slowing the progression of aortic stenosis; on the other hand, the majority of prospective studies has not confirmed this result [13–18].

The most likely hypothesis, therefore, is that there is a common pathogenetic background (particularly inflammation and deposition of cholesterol), but the disease evolution is influenced by several different factors. As regards aortic stenosis, these factors may be the mechanical stress, the mediators of calcification and genetic factors.

As concerns the clinical implications, it is important to apply preventive measures, in particular in the correction of risk factors common to both diseases. About the therapeutic prospects, the application of the drugs currently used to slow the progression of atherosclerosis (i.e. statins) in the treatment of aortic stenosis is effective whether the pathophysiological rationale of their application is strong.

According to the results published by our group in another study, only the subgroup of patients with degenerative aortic stenosis and simultaneously a high cardiovascular risk could probably benefit from this treatment [18].

So, in patients with aortic stenosis, the execution of an ultrasound scan of carotid arteries could be a useful guide to identify higher risk of coronary heart disease subgroups who could benefit from treatment with statins unlike lower risk groups [18]. In fact on the basis of the strong association between carotid atherosclerosis and degenerative aortic stenosis, the echo-color Doppler of the carotid arteries can be a rather simple, low cost and non invasive method to stratify the cardiovascular risk, so preventing the execution of more invasive techniques, such as coronary angiography to identify coronary risk. So, as result, we could suggest ultrasound scan of carotid arteries as useful technique in the stratification of cardiovascular risk in patients with degenerative aortic stenosis, with several implications on the treatment strategy, especially for higher risk subgroups.

5. Conclusions

The carotid atherosclerotic disease is more common in patients with degenerative aortic stenosis compared to controls. So the presence of carotid atherosclerosis is associated with degenerative aortic stenosis.

This result contribute to strengthening the pathogenetic hypothesis “atherosclerosis-like” of aortic stenosis.

So, it was verified the presence of an association between degenerative aortic stenosis and carotid plaque and the existence of a positive linear correlation between the severity of aortic stenosis and the thickness of the plaque and IMT. This relationship is quite new in this field of study.

Considering these results and in light of the fact that the lipid-lowering therapy is effective in the subgroup of patients at higher risk [18], ultrasound scan of carotid arteries could be useful in the stratification of cardiovascular risk in patients with degenerative aortic stenosis. So, the identification of high risk patients, might have some implications on the treatment strategy for both diseases, particularly in reference to the lipid-lowering therapy and to the correction of common risk factors.

References

- [1] Amato M, Montorsi P, Ravani A, et al. Carotid intima-media thickness by B-mode ultrasound as surrogate of coronary atherosclerosis: correlation with quantitative coronary angiography and coronary intravascular ultrasound findings. *Eur Heart J* 2007;28:2094–101.

- [2] Baumgartner H, Hung J, Bermejo J, et al. Echocardiographic assessment of valve stenosis: EAE/ASE recommendations for clinical practice. *J Am Soc Echocardiogr* 2009;22:1–23.
- [3] Pignoli P, Tremoli E, Poli A, Oreste P, Paoletti R. Intimal plus medial thickness of the arterial wall: a direct measurement with ultrasound imaging. *Circulation* 1986;74:1399–406.
- [4] Otto CM, Lind BK, Kitzman DW, Gersh BJ, Siscovick DS. Association of aortic valve sclerosis with cardiovascular mortality and morbidity in the elderly. *N Engl J Med* 1999;341:142–7.
- [5] Agmon Y, Khandheria BK, Meissner I. Aortic valve sclerosis and aortic atherosclerosis: different manifestations of the same disease? Insights from a population-based study. *J Am Coll Cardiol* 2001;38:827–34.
- [6] Otto CM, Knusisto J, Reichenbach DD, Gown AM, O'Brien KD. Characterization of the early lesion of degenerative valvular aortic stenosis; Historical and immunohistochemical studies. *Circulation* 1994;90:844–53.
- [7] Pohle K, Maffert R, Ropers D, et al. Progression of aortic valve calcification: association with coronary atherosclerosis and cardiovascular risk factors. *Circulation* 2001;104:1927–32.
- [8] Rohani M, Jogestrand T, Ekberg M, et al. Interrelation between the extent of atherosclerosis in the thoracic aorta, carotid intima-media thickness and the extent of coronary artery disease. *Atherosclerosis* 2005;179:311–6.
- [9] Granér M, Varpula M, Kahri J, et al. Association of carotid intima-media thickness with angiographic severity and extent of coronary artery disease. *Am J Cardiol* 2006;97:624–9.
- [10] Antonini-Canterin F, Leiballi E, Capanna M. Association between carotid and coronary artery disease in patients with aortic valve stenosis: an angiographic study. *Angiology* 2009;60:596–600.
- [11] Kablak-Ziembicka A, Przewlocki T, Tracz W. Prognostic value of carotid intima-media thickness in detection of coronary atherosclerosis in patients with calcified aortic valve stenosis. *J Ultrasound Med*; 24:461–467
- [12] Sgorbini L, Scuteri A, Leggio M. Association of mitral anulus calcification, aortic valve calcification with carotid intima media thickness. *Cardiovasc Ultrasound* 2004;2:19.
- [13] Bellamy MF, Pellikka PA, Klarich KW. Association of cholesterol levels, hydroxymethylglutaryl coenzyme-A reductase inhibitor treatment, and progression of aortic stenosis in the community. *J Am Coll Cardiol* 2002;40:1723–30.
- [14] Cowell SJ, Newby DE, Prescott RJ, Bloomfield P, Reid J, Northridge, Scottish aortic stenosis and lipid lowering trial, impact on regression (SALTIRE) investigators. *N Engl J Med* 2005;352:2389–97.
- [15] Rossebø AB, Pedersen TR, Boman K, et al. SEAS Investigators. Intensive lipid lowering with simvastatin and ezetimibe in aortic stenosis (SEAS). *N Engl J Med* 2008;359:1343–56.
- [16] Jassal DS, Bhagirath KM, Karlstedt E, et al. Evaluating the effectiveness of rosuvastatin in preventing the progression of diastolic dysfunction in aortic stenosis: a substudy of the aortic stenosis progression observation measuring effects of rosuvastatin (ASTRONOMER) study. *Cardiovasc Ultrasound* 2011;9:5.
- [17] Novo G, Fazio G, Visconti C, et al. Atherosclerosis, degenerative aortic stenosis and statins. *Curr Drug Targets* 2011;12:115–21.
- [18] Novo G, Noto D, Averna M, Novo S. Statin therapy in patients with aortic stenosis after the ASTRONOMER trial: is there still any space? *Intern Emerg Med* 2011:592–9.