

Case Report

Management of Distal Radius Fractures in the Elderly Patients

D'Arienzo M*, Conti A and D'Arienzo A

Università degli Studi Di Palermo, Clinica Ortopedica e Traumatologica, Italy

*Corresponding author: D'Arienzo M, Università degli Studi Di Palermo, Clinica Ortopedica e Traumatologica, Italy

Received: April 04, 2015; Accepted: September 05, 2015; Published: September 10, 2015

Abstract

Distal radius fractures are one of the most common injuries treated by the orthopedic surgeons representing almost 1/6 of the fractures that are treated in the emergency departments and the 75% of all fractures of the upper limb and are second only to hip fractures in elderly population. The age distribution of this kind of injury is typically bimodal with peaks in the young patients (6-25) and in the elderly patients older than 65. In the first case the mechanism of injury is usually a high energy trauma, such as a car accident, whilst in the second one is usually a low energy trauma like a domestic fall. Various classification systems have been proposed for these fractures. The classic eponymy-based classification, which divides the fractures in "Colles, Smith, Hutchinson, etc" is always useful but we think that the best system could be a combination with the classic eponymy-based classification with the one proposed by the AO Trauma. Distal radius fractures are frequent in elderly active patients and are usually treated with closed reduction and cast immobilization for 5-6 weeks. Decision for surgical treatment in osteoporotic and elderly patients is difficult as there are no significant differences of functional outcome after non surgical and surgical treatment, patient's comfort, pre-injury activity level, life style requirement, stage of osteoporosis, fracture stability, joint congruency, loss of previous reduction and bilateral fractures should be considered in decision making. Of different kinds of surgical treatment we prefer k-wires fixation, epibloc or ORIF with locking plate.

Abbreviations

DASH: Disability of Arm, Shoulder, and Hand; AAOS: American Academy of Orthopaedic Surgeons; ORIF: Open Reduction and Internal Fixation

Case Presentation

In our Clinic, from January 2010 to December 2013, we treated 434 distal radius fractures, 38% of them occurred in elderly patients, usually for a low-energy trauma (Figure 1a,b). In every cases, except one, we performed closed reduction and in 45% of them we casted them. In the other 55% we performed a k-wire fixation or an epibloc fixation. The only case that we treated with open reduction was one patient with bilateral wrist fracture. Results has been evaluated looking at the x-rays one month, 5 months and one year after the surgery or non-operative treatment and analyzing the scores in DASH and Mayo Clinic wrist. The scores showed excellent results in

51%, good in 38%, fair in 9% and poor in 2%. In our opinion every patient should be individually assessed basing on the balance of risks and benefits. Since it seems to be no great difference in long-term functional outcome, we suggest informing the patient about the risk and benefits of operative versus non operative treatment and treating operatively those patients that wanted to come back at their own activities as soon as possible. We also suggest to treat operatively also those patients who have a bilateral distal radius fracture for not limitate too much their life. The patients with reduction cannot be maintained with cast, the fractures which lose reduction at one or two weeks, because in osteoporotic bone, repeated manipulations are ineffective and often correlate to complex regional pain syndrome [1]. And further more. It has been demonstrated correlation between increasing displacement and low bone mineral density [2].

Among all types of treatment, we prefer angular stabilization plate using in most of cases volar approach (Figure 2a, 2b) epibloc (Figure 3a, 3b) or percutaneous K wires (Figure 4a, 4b).

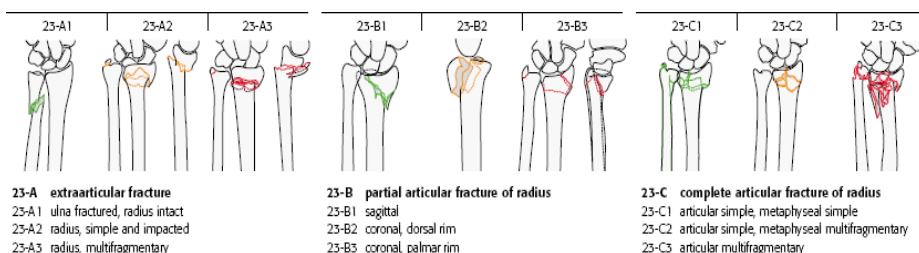


Figure 1: The AO- Muller classification is the most widely used system to assess the distal radius fractures.

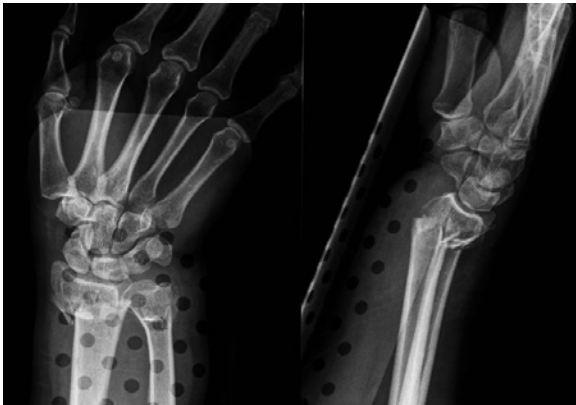

Figure 2a: Woman, 71 years old fell from stairs at her home and sustained a bilateral wrist fracture.

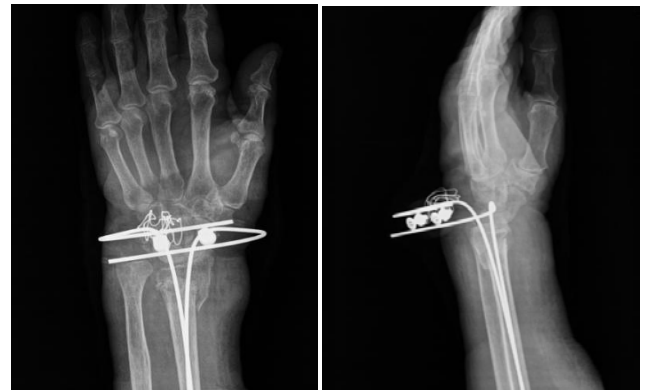

Figure 3b: We choose a closed reduction and a fixation with Epibloc.

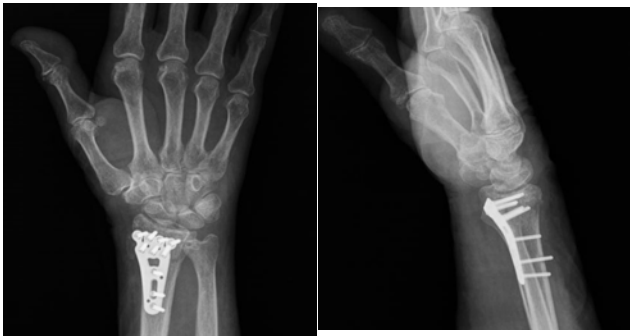


Figure 2b: We choose to treat one wrist conservatively and the dominant one with ORIF using a volar access.

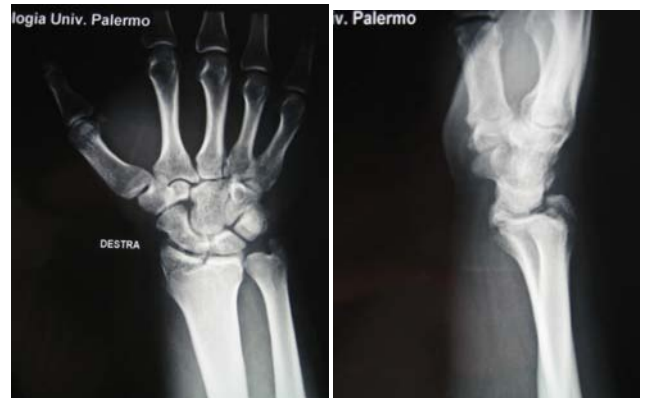

Figure 4a: This 70 years old woman fell in a supermarket and sustained this articular fracture of the radial styloid.

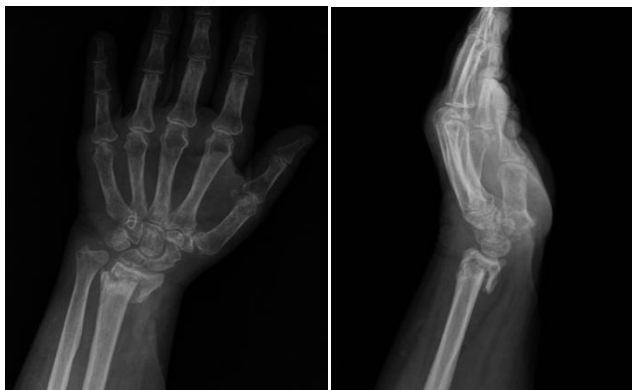

Figure 3a: This 75 years old retired man fell in his garden and sustained a distal radius fracture.

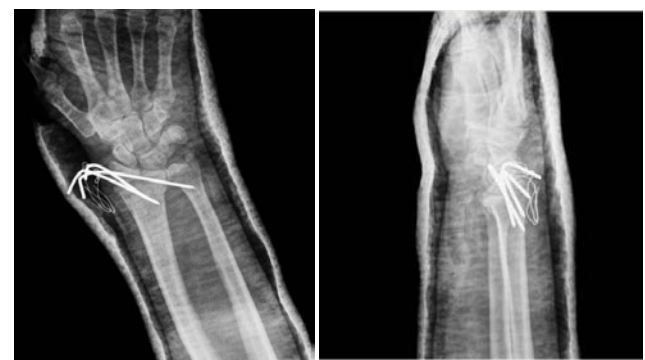

Figure 4b: We choose to treat this fracture with closed reduction and k-wires fixation, removed after one month.

Discussion

The treatment of distal radius fractures has been well documented in the literature due to increasing life expectancy, an appropriate management is of growing importance. Decision whether operative or non operative treatment is taken is based on patient's comfort, pre injury activity level, life style requirement, stage of osteoporosis, fracture stability according to La Fontaine criteria (Table 1), intra-articular involvement, joint congruency, loss of previous reduction and bilateral fracture. However, it is important to acknowledge that

most of the literature is based on findings in younger patients. When geriatric distal radius fractures are considered, clear indications for operative treatment become more controversial and sometimes even contradictory. Distal radial fractures in the elderly have different characteristics to those in younger patients. The fracture is usually the result of low-energy trauma, which is most often caused by a simple fall on level ground. This kind of low-energy trauma usually results in an extra-articular distal radial fracture, which is dorsally displaced (the well-known Colles' fracture). There is no consensus on the best treatment for the distal radial fracture in elderly patients

Table 1: La Fontaine criteria are useful to make a decision about treating conservatively or operatively a distal radius fracture or to verify if a closed reduction can be satisfying.

Acceptable Reduction
<15° dorsal and <20° palmar tilt
>15 ° radial inclination
<5mm radial shortening
Ulnar variance negative or neutral
Articular gap<2mm
Articular step<1mm

because there is insufficient evidence as to whether operative or non operative treatment is better with regards to long-term functional outcome. Anzarut [3] in his prospective study demonstrates that acceptable radiographic reduction was not associated with better physical or mental health status, lesser degrees of disability, or greater satisfaction than was unacceptable reduction. Young [3], in his retrospective review of 25 elderly patients treated closed found out that functional outcome was satisfactory in most cases; a high level of personal satisfaction and return to previous activity level was observed, regardless of the radiographic result. Diaz-Garcia [4]. Meta-analysis; 2039 papers narrowed down to 21 to look at the

60+population. Despite worse radiographic outcomes associated with cast treatment, functional outcomes were no different from those of surgically treated groups for patients over 60 years. In 2009, the American Academy of Orthopaedic Surgeons (AAOS) issued a clinical guideline on the treatment of the distal radius fractures. Many of the recommendations in the guideline were considered inconclusive, particularly for the elderly patients; the AAOS was unable to make a recommendation for or against operative treatment in these cases.

References

1. Beumer A, McQueen MM. Fractures of the distal radius in low-demand elderly patients: closed reduction of no value in 53 of 60 wrists. *Acta Orthop Scand.* 2003; 74: 98-100.
2. Chung KC, Squitieri L, Kim HM. Comparative outcomes study using the volar locking plating system for distal radius fractures in both young adults and adults older than 60 years. *J Hand Surg Am.* 2008; 33: 809-819.
3. Anzarut A, Johnson JA, Rowe BH, Lambert RG, Blitz S, Majumdar SR. Radiologic and patient-reported functional outcomes in an elderly cohort with conservatively treated distal radius fractures. *J Hand Surg Am.* 2004; 29: 1121-1127.
4. Diaz-Garcia RJ1, Oda T, Shauver MJ, Chung KC. A systematic review of outcomes and complications of treating unstable distal radius fractures in the elderly. *J Hand Surg Am.* 2011; 36: 824-835.