

PROGRAM BOOK



AMERICAN ROENTGEN RAY SOCIETY



Studying for exams? **You'll need RadCases.**



- 12 books**
- 3,000 cases**
- 15,000+ radiographs**
- 1 must-have online learning tool**

Come to booth #511



TABLE OF CONTENTS



Meeting Overview

1	President's Welcome
2	General Information
4	Disclosures of Commercial Interest
8	Floor Plan of the Manchester Grand Hyatt
9	Floor Plan of Commercial Exhibit Hall
11	Categorical Course Schedule
13	Review Course Schedule
17	Sunday Schedule
23	Monday Schedule
33	Tuesday Schedule
41	Wednesday Schedule
47	Thursday Schedule
53	Friday Schedule
57	Subspecialty Tracks
73	Electronic Exhibits
109	Commercial Exhibitors
119	Officers and Committees

MEETING OVERVIEW



Sunday, May 2	Monday, May 3	Tuesday, May 4	Wednesday, May 5	Thursday, May 6	Friday, May 7	
7:30 am–6:00 pm Categorical course on efficient imaging	7:00 am–8:00 am Power hours on breast imaging and nuclear medicine	7:00 am–8:00 am Power hours on abdominal imaging and vascular and interventional radiology	7:00 am–8:00 am Power hours on cardiopulmonary and pediatric imaging	7:00 am–8:00 am Power hours on emergency radiology and musculoskeletal imaging	7:00 am–8:00 am Power hours on neuro-radiology and ultrasound	
8:00 am–12:00 noon Item-writing workshop	7:30 am–6:10 pm Categorical course on efficient imaging	7:00 am–12:00 noon Categorical course on efficient imaging	7:30 am–10:00 am Review course on breast imaging	7:30 am–10:00 am Review course on gastrointestinal imaging	7:30 am–10:00 am Review course on genitourinary imaging	
1:30 pm–5:00 pm Seminars on education and business and practice management	8:00 am–9:30 am Instructional courses on breast and cardiac imaging, nuclear medicine and vascular and interventional radiology. Scientific session on efficacy, education and PACS	8:00 am–9:30 am Instructional courses on breast, gastrointestinal and musculoskeletal imaging, neuroradiology and nuclear medicine	8:00 am–9:30 am Instructional courses on chest, gastrointestinal, musculoskeletal and pediatric imaging, neuro-radiology and vascular and interventional radiology	8:00 am–9:30 am Instructional courses on chest, musculoskeletal and pediatric imaging, emergency radiology and vascular and interventional radiology. Scientific session on neuroradiology	8:00 am–9:30 am Instructional courses on chest imaging, competencies, emergency radiology, neuroradiology and ultrasound	
4:30 pm–5:30 pm SRS guest program	9:30 am–10:30 am Caldwell Lecture: Benjamin Chu, MD, MPH, President, Kaiser Permanente Southern California Region	10:00 am–11:30 am Instructional courses on musculoskeletal imaging and neuroradiology. Scientific sessions on breast, cardiopulmonary and gastrointestinal imaging and vascular and interventional radiology	10:00 am–12:00 noon Instructional courses on musculoskeletal and pediatric imaging, neuroradiology and vascular and interventional radiology. Scientific sessions on cardiopulmonary and gastrointestinal imaging	10:00 am–12:00 noon Instructional courses on chest imaging. Scientific sessions on emergency radiology, gastrointestinal imaging and neuroradiology	10:00 am–12:00 noon Instructional courses on neuroradiology and ultrasound. Scientific session on musculoskeletal imaging	
6:15 pm–7:30 pm Presidential address and Gold Medal presentations	10:30 am–12:00 noon Instructional courses on breast and cardiac imaging, nuclear medicine and vascular and interventional radiology. Scientific session on efficacy, education and PACS	12:00 noon–1:00 pm Lunch in the exhibit hall	12:00 noon–1:00 pm Lunch in the exhibit hall	10:30 am–1:00 pm Review course on musculoskeletal imaging	10:30 am–1:00 pm Review course on chest imaging	
There are additional fees for the categorical course and the review course.	12:00 noon–1:00 pm Lunch in the exhibit hall	1:00 pm–3:30 pm Review course on nuclear medicine	1:00 pm–3:00 pm Instructional courses on breast, chest and genitourinary imaging and vascular and interventional radiology. Scientific sessions on musculoskeletal imaging and neuroradiology	1:00 pm–3:00 pm Instructional courses on chest and genitourinary imaging, emergency radiology, neuro-radiology and ultrasound	1:00 pm–3:00 pm Instructional courses on competencies and neuroradiology. Scientific session on genitourinary imaging	
	1:00 pm–3:00 pm Instructional courses on cardiac imaging and nuclear medicine. Scientific sessions on breast and gastrointestinal imaging and vascular and interventional radiology	1:00 pm–3:00 pm Instructional courses on gastrointestinal and musculoskeletal imaging and neuroradiology. Scientific sessions on breast and cardiopulmonary imaging and vascular and interventional radiology	1:00 pm–3:30 pm Review course on pediatric imaging	1:00 pm–3:30 pm Review course on musculoskeletal imaging and neuroradiology	12:30 pm–2:00 pm Instructional courses on chest and genitourinary imaging, emergency radiology, neuro-radiology and ultrasound	2:00 pm–4:30 pm Review course on ultrasound
	2:30 pm–3:30 pm Awards session	4:00 pm–6:00 pm Instructional courses on breast and musculoskeletal imaging, neuroradiology and vascular and interventional radiology. Scientific sessions on gastrointestinal and pediatric imaging	2:45 pm–3:15 pm Member business meeting	2:30 pm–5:00 pm Review course on neuroradiology	2:30 pm–5:00 pm Instructional courses on chest imaging, competencies, emergency radiology and ultrasound. Scientific sessions on genitourinary and musculoskeletal imaging	Power Hours are one-hour sessions that feature oral presentations by electronic exhibit authors.
	4:00 pm–6:00 pm Instructional courses on breast, cardiac and gastrointestinal imaging and vascular and interventional radiology. Scientific sessions on musculoskeletal imaging and nuclear medicine	4:00 pm–6:30 pm Review course on cardiovascular imaging	4:00 pm–6:00 pm Instructional courses on breast, chest, genitourinary, musculoskeletal and pediatric imaging and neuroradiology	3:00 pm–5:00 pm Review course on vascular and interventional radiology		

PRESIDENT'S WELCOME



An enthusiastic welcome to you as a participant in the 2010 ARRS Annual Meeting at the Manchester Grand Hyatt in San Diego, CA! Our 110th annual meeting offers 57 CME credits, and is designed to meet your educational requirements, whether you need credits in a particular subspecialty area, are interested in courses that cover a variety of subspecialties, or obtaining SAM credit towards Maintenance of Certification.



I'm proud this year that our popular Categorical Course is on the topic of practical approaches to common clinical conditions. Chaired by Drs. Ruth Carlos, Yoshimi Anzai, Craig Blackmore, Paul Cronin and Santiago Medina, this program focuses on appropriate use of imaging in the wide spectrum of diseases with an emphasis on an evidence-based approach. Attendees will learn practical tips, protocols and algorithms to incorporate into their daily practice. The accompanying syllabus is a resource that attendees will refer to again and again.

ARRS is again offering our popular Case-Based Imaging Review Course, designed for both residents and physicians in practice. Directed by Drs. Deborah Baumgarten, Sanjeev Bhalla, Lonie Salkowski and Donald Yoo, the course includes 330 cases across 11 subspecialty areas.

The 2010 annual meeting also includes three half-day courses on Sunday focusing on radiology education, item writing and business in practice. Our instructional courses taught by respected radiology educators, scientific sessions highlighting the latest in radiology research and power hour sessions that feature authors of electronic exhibits discussing their exhibits complete the program.

This annual meeting is made possible through the contributions of hundreds of dedicated volunteers and the ARRS staff. Dr. Mauricio Castillo chairs our Instructional Courses Committee, which is responsible for the development of our instructional courses, the categorical course, case-based review course and the Sunday half-day courses. Dr. Jonathan Lewin chairs our Program Committee, which is responsible for the annual meeting scientific sessions and the electronic exhibits, including the power hours. Bringing this all together is our Education/CME Committee, which is responsible for our overall educational programs, and is chaired by Dr. Norman Beauchamp. The intellectual contributions and time commitment of our volunteer leaders, our committee members and our volunteer faculty members makes it possible for the ARRS to bring you this outstanding meeting.

We are delighted and honored that you have joined us in San Diego, and look forward to seeing you in Chicago for the 2011 Annual Meeting, May 1st through the 6th.

Ella A. Kazerooni, MD, MS
ARRS President

GENERAL INFORMATION



Annual Meeting Program Objectives

The 2010 Annual Meeting of the American Roentgen Ray Society has three goals:

- to offer an educational forum in the practice and science of radiology based on recognized needs;
- to provide a forum to report on, exchange information on and disseminate new developments and expert knowledge in radiology; and
- to ensure that the educational activities have influenced participants' knowledge, skills, behavior and practice performance.

Who Should Attend: Radiologists, radiologists-in-training and other health professionals interested in the science and practice of radiology.

Accreditation Statement: The ARRS is accredited by the Accreditation Council on Continuing Medical Education (ACCME) to sponsor continuing medical education activities for physicians.

Designation Statement: The ARRS designates this educational activity for a maximum of 57 AMA PRA Category 1 credits™. Each physician should claim only those credits that he/she actually spent in the activity.

How to Obtain CME Credits: CME credit may be claimed for attendance at the categorical course, case-based imaging review course, education seminar, item-writing workshop, business management seminar, instructional courses, scientific paper presentation sessions, and power hours. Additional CME credit is available for selected electronic exhibits. Attendance logs and evaluations are available at <http://cme.rrs.org>. It is the individual's responsibility to complete the forms online in order to receive CME credit. Once the individual has completed the form, he or she can save a copy for his/her records. In addition, ARRS members may access their CME records through the educational services portal of the ARRS Web site (www.rrs.org). Note that credit may not be claimed for the categorical course, or the case-based imaging review course unless the attendee has registered for the course and paid the separate registration fee.

Content Codes

To assist meeting attendees in maintaining more complete CME records, the attendance log and attendee CME transcripts will include the content codes for every activity in which the attendee participates.

Content Codes:

- BI Biopsy
- BR Breast Radiology (Imaging and Interventional)
- CA Cardiac Radiology
- CH Chest/Pulmonary Radiology
- CT Computed Tomography
- ED Education
- ER Emergency Radiology
- GI Gastrointestinal Radiology
- GN General Radiology
- GU Genitourinary Radiology
- HN Head and Neck Radiology
- HP Health Policy/Management/Informatics
- MI Molecular Imaging
- MK Musculoskeletal Radiology
- MO Mammography
- MR Magnetic Resonance Imaging
- NM Nuclear Medicine

- NR Neuroradiology
- OB Obstetric/Gynecologic Radiology
- OT Other
- PD Pediatric Radiology
- PH Physics and Basic Science
- PS Patient Safety
- PT PET-CT
- RO Radiation Oncology
- SO Socioeconomic Concepts
- US Ultrasound
- VI Vascular and/or Interventional Radiology

ARRS Booth #315

Monday-Wednesday, May 3-5

9:15 am-4:00 pm

Elizabeth Ballroom, Second Level

Thursday, May 6

9:00 am-4:30 pm

Registration, Elizabeth Foyer, Second Level

Friday, May 7

9:00 am-2:00 pm

Registration, Elizabeth Foyer, Second Level

ARRS educational products and resources are available for purchase in the ARRS booth. ARRS staff will answer questions and demonstrate online resources, including access to the *American Journal of Roentgenology*, Web lectures, CME/SAM tracker and the PQI template.

Automated Teller Machines (ATMs)

There are two ATMs located in the lobby of the Manchester Grand Hyatt. There is a \$3.50 transaction fee.

Business Center

The Business Center is located on the Lobby Level of the Seaport Tower of the Manchester Grand Hyatt and provides a variety of business services. The Business Center is open daily from 7:00 am to 7:30 pm.

Car Rental

Hertz is the official car rental company for this meeting. To reserve a car, call Hertz at (800) 654-2240 and refer to the discount number **CV#04FN0001**. For online bookings, visit www.hertz.com, check "I have a discount," select "Convention Number (CV)" and enter **04FN0001**. There is a Hertz desk at the Manchester Grand Hyatt. Advance reservations are recommended as cars are subject to availability.

Case of the Day

Monday-Wednesday, May 3-5

9:15 am-4:00 pm

Elizabeth Ballroom, Second Level

Thursday, May 6

6:30 am-7:00 pm

Registration, Elizabeth Foyer, Second Level

Friday, May 7

6:30 am-1:00 pm

Registration, Elizabeth Foyer, Second Level

Winners will be posted on the Case of the Day computers. Winner ribbons may be claimed at the ARRS booth Tuesday and Wednesday in the commercial exhibit hall (Elizabeth Ballroom, Second Level) and Thursday and Friday at the ARRS booth in the ARRS registration area (Elizabeth Foyer, Second Level).

Cell Phones and Pagers

As a courtesy to your fellow attendees, please turn off cell phones and pagers or set them to vibrate. Phone conversations should not be conducted in meeting rooms.

GENERAL INFORMATION



Commercial Exhibits

The ARRS encourages you to visit the commercial exhibit hall during your time at the 2010 ARRS Annual Meeting. If you visit a commercial exhibitor and allow your name badge to be scanned, you are providing the exhibitor with your name, organization, address, email and phone number. If you do not wish for an exhibitor to have this information, please do not allow your name badge to be scanned.

Commercial Exhibit Installation

Elizabeth Ballroom, Second Level
Saturday, May 1 2:00 pm–6:00 pm
Sunday, May 2 7:30 am–6:00 pm

Commercial Exhibit Hours

Elizabeth Ballroom, Second Level
Monday–Wednesday, May 3–5 9:15 am–4:00 pm

Commercial Exhibit Dismantling

Elizabeth Ballroom, Second Level
Wednesday, May 5 4:00 pm–12:00 midnight
Thursday, May 6 8:00 am–2:00 pm

Commercial Exhibit Hall Prize Drawings

ARRS will hold daily prize drawings Monday–Wednesday, May 3–5 in the commercial exhibit hall. The prize drawings will be held during the afternoon breaks.

Disabilities

The ARRS is committed to meeting all our attendees' needs which includes providing an accessible environment and accommodating any needs of people with disabilities. The Manchester Grand Hyatt has wheelchair services, accessible elevators, accessible restroom stalls, public telephones available at varying heights, and sit-down TTY units. Attendees should inquire about special services at ARRS Registration (Registration, Elizabeth Foyer, Second Level).

Electronic Exhibit Hours

Sunday, May 2
1:00 pm–6:00 pm Randle D/E, Fourth Level
Monday–Thursday, May 3–6
7:00 am–12:00 midnight Randle D/E, Fourth Level
Friday, May 7
7:00 am–1:00 pm Randle D/E, Fourth Level

Emergencies/First Aid

In the Manchester Grand Hyatt, dial 55 on any house phone for emergencies of any nature. The hotel's trained professionals will assist you directly, or if necessary, arrange for proper support from EMS or police. All Security personnel are AED, CPR and First Aid Certified. Please do not call 911 before contacting hotel emergency.

Foreign Currency Exchange

For registered Manchester Grand Hyatt guests, a foreign currency exchange is available at the front desk. The maximum amount that can be changed daily is \$100. Guests must present a valid picture ID as well as a major credit card.

Internet Café

Computers are available to check email in the Commercial Exhibit Hall (Elizabeth Ballroom, Second Level) Monday, May 3–Wednesday,

May 5 from 9:15 am to 4:00 pm. The Internet Café will be located in ARRS Registration (Elizabeth Foyer, Second Level) on Thursday, May 6, 6:30 am–7:00 pm, and Friday, May 7, 6:30 am–1:00 pm.

Lost and Found

For any lost and found items at the Manchester Grand Hyatt, contact 4203. The lost and found office is monitored by security personnel and kept locked 24 hours a day.

Luggage Check

The ARRS does not provide a luggage check. Luggage should be checked at your hotel.

Parking

Valet and self-parking are available at the Manchester Grand Hyatt at hourly and overnight rates.

Valet Parking

Overnight guest	\$32.00	Self-Parking	Overnight guest	\$22.00
First Hour	\$10.00		First Hour	\$6.00
After the first hour	\$5.00 per hour		After the first hour	\$6.00 per hour

For additional information regarding parking, please call the hotel at (619) 358-6658. Prices are subject to change.

Restaurant Reservations/Sightseeing

The hotel's concierge desk will assist attendees in making restaurant reservations. The concierge desk also has information on transportation, golf, tours, etc.

Security

In the Manchester Grand Hyatt dial 55 to reach security on any house or guest room phone.

Smoking Policy

The ARRS has a no-smoking policy for all of its meetings. This policy applies to all meeting space in the Manchester Grand Hyatt, including the commercial exhibit hall, meeting rooms, foyers, lobbies and all restaurants. The Manchester Grand Hyatt is a smoke-free hotel. There is a designated smoking area in front of the hotel by the clock tower, harbor side of the front drive.

Speaker Preview Room

Friday, April 30
Saturday, May 1
Sunday, May 2
Monday, May 3
Tuesday, May 4
Wednesday, May 5
Thursday, May 6
Friday, May 7

Molly A/B, Second Level

1:00 pm–5:00 pm
7:00 am–6:00 pm
6:30 am–6:00 pm
6:00 am–5:30 pm
6:00 am–6:00 pm
6:00 am–6:00 pm
6:00 am–5:30 pm
6:00 am–3:30 pm

Telephones

Public telephones are available on the lobby, the second, third and fourth levels of the Manchester Grand Hyatt.

Telephone Numbers

Police and medical emergencies outside the hotel 911
Manchester Grand Hyatt Main Number (619) 232-1234

DISCLOSURES OF COMMERCIAL INTEREST



Since its inception in 1900, the ARRS has maintained a tradition of scientific integrity and objectivity in its educational activities. In order to preserve this integrity and objectivity, all individuals participating as planners, presenters and moderators in an ARRS educational activity or an activity jointly sponsored by the ARRS must appropriately disclose any financial relationship with a commercial organization that may have an interest in the content of the educational activity.

ACCME Definitions of a Financial Relationship

Financial relationships are those relationships in which the individual benefits by receiving a salary, intellectual property rights, consulting fee, honoraria, ownership interest (e.g. stocks, stock options or other ownership interest, excluding diversified mutual funds) or other financial benefit. Financial benefits are usually associated with roles such as employment, management position, independent contractor (including contracted research), consulting, speaking and teaching, membership on advisory committees or review panels, board membership, and other activities from which remuneration is received or expected. The ACCME considers relationships of the person involved in the CME activity to include financial relationships of a spouse or partner.

Disclosures

All of the speakers and planners with the exception of the following have indicated that they do not have a financial relationship with a commercial organization that may have an interest in the content of the educational activity.

Categorical Course

- K. Applegate has a book contract with Springer Publishers on EBM Imaging.
- C. Blackmore is the recipient of book royalties from Springer Publishers.
- R. Carlos is a board member of GE-AUR Academic Radiology Research Fellowship (travel expenses paid, no honorarium).
- P. Cronin is a GERRAF Fellow (2007-2009).
- D. Hallam received honorariums from Penumbra, Inc. and Concentric Medical to compensate expenses for User's meeting.
- J. Jarvik is a consultant for HealthHelp, Inc.
- S. Medina is the co-editor of the "Evidence-Based Imaging" book and is recipient of royalties from Springer Publishers.
- U.J. Schoepf is a consultant for and recipient of research support from Bayer-Schering Pharma, Bracco Diagnostics, Inc., General Electric Healthcare, Medrad, Inc., and Siemens Medical Solutions.
- M. Siegel provides research support for Siemens Medical Solutions and is a member of the Speaker's Bureau.
- G. Zoarski provides research support for Terumo Medical Corporation, and is an investor with NFocus Neuromedical.

Approach to Diagnosis: Case-Based Imaging Review Course

- G. Abbott is an author for Amirsys, Inc. and Thieme Medical Publishers.
- S. Bhalla is a consultant for Medtronic, Inc.
- C. Glastonbury is a shareholder and consultant for Amirsys, Inc.
- A. Nees provides research for General Electric.
- A. Nemcek is a consultant for B. Braun Interventional, Inc.
- C.D. Phillips has an affiliation with Amirsys, Inc.
- C. Santillan is a member of the General Electric Advisory Board.
- L. Scoutt is a consultant for Philips Healthcare.
- B. Yeh is the recipient of a grant from NIH. He has pending clinical grants with General Electric, Bayer Healthcare, and Medrad, Inc.
- S. Zangan is a consultant for Bard Peripheral Vascular

Business/Practice Management Course

- J. Berlin is a stockholder and member of the Radiology Advisory Board, Nuance Communications (owner of Powerscribe voice recognition software).
- D. Levin is a consultant to Healthhelp, Inc.
- F. Lexa is a member of the Board of Eagle Eye.

Item-Writing Workshop

- J. Collins receives book royalties and is an editor for Elsevier. She also receives book royalties from Lippincott Williams & Wilkins.

Instructional Courses

- IC102** S. Abbara received an honorarium from Siemens Medical Solutions for speaker/course director at the European Congress of Cardiology. He is also a member of the Medical Advisory Boards for Partners Imaging and Magellan Healthcare, Inc., a consultant for Perceptive Informatics, Inc., and the recipient of funded research support from Bracco Diagnostics, Inc.
- IC102** U.J. Schoepf is the recipient of research support and a consultant for Bayer-Schering Pharma, Bracco Diagnostics, Inc., General Electric Healthcare, Medrad, Inc., and Siemens Medical Solutions.
- IC103** H. Agress is a member of GEMS PET/CT Board of Directors (non-financial).
- IC106** D. Mankoff is the recipient of a research grant from Pfizer, Inc. and Merck. He is also a consultant for Pfizer, Inc.
- IC106** G. Mercier is a member of Siemens Medical Solutions Molecular Imaging Advisory Board.
- IC107** G. Reddy is the recipient of research funding from General Electric Healthcare.
- IC107** S. Teague is the recipient of an honorarium and a consultant for Philips Medical Systems. He has a stock receipt from 3DR and is a member of their Advisory Board.
- IC111** R. Gilkeson is the recipient of research support from Siemens Medical Solutions.
- IC113** J. Thrall is a stockholder with GE Healthcare and Microsoft. He is a Board Member with Mobile Aspects and Worldcare, and an advisor for Genetech.
- IC114** D. Morgan is the recipient of research support from Bracco Diagnostics, Inc. and Daiichi Sankyo.
- IC116** M. Atalay is a consultant for General Electric.
- IC117** A. Nemcek is a consultant for B. Braun Interventional, Inc.
- IC201** J. Leyendecker is the recipient of consulting fees from Bayer Healthcare. He is also a member of the Speakers Bureau for Bracco Diagnostics, Inc. and Bayer Healthcare.
- IC202** J. Harvey has an affiliation with Matekema, Ltd.
- IC204** R. Harnsberger is a stockholder and CEO of Amirsys, Inc.
- IC205** H. Jacene is the recipient of research support from GlaxoSmithKline.
- IC206** J. Jacobson is a consultant for Philips Medical Systems, SonoSite, Inc., Terason, and BioClinica. He is also the recipient of book royalties from Elsevier, Inc.
- IC209** W. Morrison is a member of the Scientific Advisory Board (unpaid) for Oni, Inc., and is a consultant for AprioMed, Inc.
- IC213** J. Ross is a stockholder with Amirsys, Inc.
- IC214** D. Madoff is a consultant for BioSphere Medical, Inc.
- IC214** R. Murthy provides medical research for Sirtex Medical, Inc.
- IC214** S. Rose is a consultant for Sirtex Medical, Inc., Terumo Medical Corporation and Onyx Pharmaceuticals. He is also a stockholder with Sirtex Medical, Inc. and Boston Scientific Corporation.

DISCLOSURES OF COMMERCIAL INTEREST



- IC301** D. Kim is a consultant for Viatronix and Medicsight, and a co-founder for VirtuoCTC, LLC.
- IC301** J. Yee is the recipient of a research grant from General Electric Healthcare.
- IC302** H. McAdams is the recipient of a research grant from General Electric, and an author with Elsevier, Inc.
- IC305** J. MacKenzie is the recipient of a research grant from GE Medical Systems.
- IC307** L. Bancroft is the recipient of book royalties from Lippincott Publishing. She is a speaker for IICME.
- IC310** S. Tutton is a consultant for Benvenue Medical, Inc.
- IC312** J. Sumkin is a PI on a Hologic-funded research agreement between the University of Pittsburgh and Hologic.
- IC312** M. Zuley is a member of the Hologic, Inc. Advisory Board and a recipient of grant funding for research.
- IC313** G. Abbott is an author for Amirsys, Inc. and Thieme Medical Publishers.
- IC317** J. Kanne is a consultant for PTC Therapeutics, Inc. and superDimension, Inc.
- IC319** S. Mukherji is a consultant for Philips Medical Systems.
- IC401** S. Bhalla is a consultant for Medtronic, Inc.
- IC403** K. Buckwalter is the recipient of a research grant from Siemens Medical Solutions.
- IC406** H. MacMahon is a consultant for and a recipient of research support from Riverain Medical, LLC. Dr. MacMahon also receives honoraria from Konica Minolta, and has stock options with Hologic, Inc.
- IC406** I. Vlahos is a consultant for Siemens Medical Solutions and General Electric Healthcare. He is also the recipient of research grant support from Bayer Healthcare, and honoraria for lectures from Siemens Medical Solutions.
- IC408** B. Yeh is the recipient of a grant from NIH. He also has pending clinical grants with General Electric, Bayer Healthcare, and Medrad, Inc.
- IC412** S. Wilson is the recipient of a research grant from Lantheus Medical Imaging, and a member of the Ultrasound Advisory Board for Philips Medical Systems.
- IC413** O. Mawlawi is the recipient of a research grant from General Electric Healthcare.
- IC414** G. Butler is Chair of Real Time Radiology, Inc.
- IC415** K. Shanmuganathan is an Advisor to Philips Healthcare.
- IC416** B. Hashimoto is a member of the following organizations' Advisory Boards: Philips Medical Systems, General Electric Healthcare and Siemens Medical Solutions. She is also a consultant for GE Ultrasound and Philips Ultrasound.
- IC504** W. Pope is the recipient of consulting fees from Genentech and Exelixis.
- IC505** L. Scoutt is an education consultant for Philips Healthcare.
- IC506** J. Ellis is an unpaid investigator supporting two contrast media research projects funded by General Electric Healthcare. He is a consultant to a legal firm representing General Electric Healthcare.
- IC506** P. Kuo is a consultant for NSF litigation.
- IC507** C. Glastonbury is a consultant and stockholder with Amirsys, Inc.
- IC508** D. Pretorius provides software support for research for Philips Medical Systems and General Electric Healthcare.
- IC509** M. Parker is a co-author for Thieme Medical Publishers
- D. Channin is officer and stockholder of Hotlight, Inc. He is also a paid speaker for Carestream Healthcare, Inc.
- C. Glastonbury is an investor and consultant for Amirsys, Inc.
- D. Ikeda is a grant recipient from Spectros Corporation and Advanced Research Technology.
- C. Khan is principal and officer of Hotlight, Inc.
- D. Madoff is a consultant for BioSphere Medical, Inc.
- M. Michel is an author and co-editor for Amirsys, Inc.
- W. Morrison is an advisor on the Scientific Advisory Board of ONI, Inc. He is also a consultant for AprioMed, Inc.
- A. Nees provides research support for General Electric.
- A. Nemcek is a consultant for B. Braun Interventional, Inc.
- G. Newstead has an institutional research agreement with Philips Healthcare. She also serves on the advisory boards of Bayer Healthcare and Naviscan, Inc.
- A. Oto is the recipient of an honoraria and a consultant for GE Healthcare, and provides research support for Philips Healthcare and Bayer Healthcare.
- M. Parker is the recipient of book royalties and a co-author of "Teaching Atlas of Chest Imaging".
- N. Safdar provides research support to General Electric, and is a shareholder with iVirtuoso, Inc.
- K. Salzman is an author and consultant for Amirsys, Inc.
- C. Santillan serves on the advisory board for General Electric Healthcare.
- B. Yeh has a pending research agreement with General Electric Healthcare. He also has a research agreement with Medrad, Inc.
- J. Yee is a recipient of a research grant from General Electric Healthcare.

Oral Presentations/Scientific Sessions

- 006** W. Boonn is the co-founder of iVirtuoso, Inc., and the recipient of a research grant from Siemens AG.
- 014** J. Berlin is a stockholder and member of the Advisory Board of Nuance Communications, the Company that owns PowerScribe Voice Recognition Software. The financial analysis described in this abstract is independent of any financial relationship with Nuance and is not an endorsement of any commercial product.
- 015** M. Laks is the CEO of Meromorphic Enterprises Corporation.
- 020** H. Ojeda-Fournier is an educational consultant for SenoRx.
- 022** A. Penn and G. Newstead are consultants to Invivo Corp, a subsidiary of Philips Medical Systems. S. Thompson is an employee of Invivo Corporation.
- 027** W. Huda is the recipient of research funding from Siemens.
- 028** W. Huda is the recipient of research funding from Siemens.
- 029** S. Kalra is the recipient of funding from GE Healthcare. J. Hsieh and P. Licato are employees of GE Healthcare. The rest of the authors has no financial relationship pertinent to the study.
- 030** L. Tannenbaum is a consultant for GE Healthcare.
- 032** S. Kalra is the recipient of funding from GE Healthcare. A. Forsberg is an employee of Sharpview. The rest of the authors has no financial relationship pertinent to the study.
- 033** R. Nelson is a consultant for GE Healthcare.
- 042** R. Nelson is a consultant for GE Healthcare.
- 045** R. Wissman provides research support for DePuy.
- 054** T. Turkington is the recipient of research support from GE Healthcare, the manufacturer of the scanner used for this study. T. Turkington is a consultant to Data Spectrum Corp., the manufacturer of some of the phantom equipment used for this study.
- 066** S. Fischer and M. Ivancevic are employed by Philips Healthcare.
- 068** M. Zuley is the recipient of a research grant from Hologic, Inc. and is a member of Hologic's Scientific Advisory Board.

Scientific Sessions: Moderators and Keynote Speakers

M. Atalay is a consultant for General Electric.

DISCLOSURES OF COMMERCIAL INTEREST



- 070** G. Newstead is the recipient of research support from Philips Medical Systems and Naviscan Inc., and a member of Three Palm Software's Medical Advisory Board. R. Schmidt is a stockholder with Hologic, Inc., and a member of Three Palm Software's Medical Advisory Board. R. Nishikawa is the recipient of royalties and research funds and a shareholder with Hologic, Inc; as well as a consultant for Siemens Medical Solutions, and a member of the Scientific Advisory Board for Dexela, Ltd., UK.
- 071** E. Mendelson is a member of the Medical Advisory Committees for Hologic, Inc. and Philips Ultrasound; the recipient of research support and a consultant for Siemens Medical Solutions (Ultrasound); the recipient of research support and a speaker for SuperSonic Imagine; and a speaker for Toshiba.
- 074** U. Numburi is affiliated with Siemens Healthcare.
- 085** J. Yee is the recipient of a grant from GE Healthcare.
- 086** E. Merkle is an advisor and a member of the Speaker's Bureau for Bayer Health Care.
- 087** L. Chu is the recipient of research support from Bracco Diagnostics, Inc.
- 089** E. Merkle is a consultant for Bayer Health Care. D. Boll is a member of the Speaker's Bureau for Bayer Health Care.
- 091** D. Marin is a current radiology fellow at Bracco Diagnostics, Inc.
- 092** S. Wilson is the recipient of a research grant from Lantheus Medical Imaging, and a member of the Advisory Boards for Contrast Ultrasound for Philips Healthcare and Siemens Medical Solutions.
- 098** W. is a consultant and member of the Medical Advisory Board for General Electric Healthcare.
- 100** S. Destounis is a research consultant for Carestream Health, Inc.; an investigator and member of the Medical Advisory Board for Siemens AG; an investigator for FUJIFILM Medical Systems USA, Hologic, Inc., and U-Systems, Inc.; and a sub-investigator for Konig Corporation. P. Seifert is a sub-investigator for FUJIFILM Medical Systems USA and Hologic, Inc., and an investigator for Konig Corporation. P. Somerville is a sub-investigator for FUJIFILM Medical Systems USA, Hologic, Inc., and Konig Corporation. P. Murphy is a sub-investigator for FUJIFILM Medical Systems USA and Konig Corporation, and an investigator for Hologic, Inc. W. Young is a sub-investigator for FUJIFILM Medical Systems USA and Konig Corporation, and an investigator for Hologic, Inc.
- 110** The project was supported by Toshiba Canada. H. Mehrez is employed by Toshiba Canada.
- 111** L. Ciancibello is affiliated with Siemens Medical Solutions, GE Healthcare and Philips Healthcare.
- 114** M. Kalra is the recipient of a research grant from GE Healthcare. J. Hsieh is an employee of GE Healthcare.
- 116** L. Ciancibello is affiliated with Siemens Medical Solutions, GE Healthcare and Philips Healthcare.
- 121** R. Salem is an advisor to MDS Nordion.
- 125** O. Kolokythas is a consultant, member of the Advisory Board and the recipient of a grant from Philips Healthcare Ultrasound. T. Gauthier and R. Kemkers are engineers and employees at Philips Healthcare Ultrasound.
- 143** M. Kalra is the recipient of research support form GE Healthcare.
- 145** D. Naidich is a consultant for Siemens Medical Solutions. V. Anand is a Siemens Medical Solutions employee.
- 148** N. Paul is affiliated with Actisight Ltd. - the manufacturers of the Actiview Optical Guidance system, and provided research support for this project.
- 154** D. Kim is a consultant for Viatronix and Medicsight, and the co-founder of Medicsight.
- 155** L. Bogoni, M. Salganicoff, M. Wolf, and V. Raykar are employees of Siemens Medical Solutions, USA.
- 157** P. Pickhardt and D. Kim are consultants for Medicsight and Viatronix, and are co-founders of VirtuoCTC.
- 174** K. Davis is the recipient of research support for cryoablation from Endocare, Inc. P. Anderson is a consultant for Titan, Pioneer Aesculap and Medtronic; the recipient of royalties from Stryker and Pioneer; and owns stock in Pioneer and Titan.
- 181** D. Porter, T. Feiweier and A. Padua are employees of Siemens Medical Solutions AG.
- 182** K. Weiss and J. Weiss have intellectual property rights in Hybrid Convolution Kernel Technology.
- 184** K. Weiss and J. Weiss have intellectual property rights to ASSIST technology.
- 195** D. Husarik is an advisor and a member of the Speaker's Bureau for Bayer Healthcare Pharmaceuticals, Inc. D. Boll is a member of Speaker's Bureau for Bayer Healthcare Pharmaceuticals, Inc.

Electronic Exhibits

- E021** H. Ojeda-Fournier is an educational consultant for SenoRx.
- E025** R. Ellis is a consultant for Three Palm Software.
- E030** J. Ecanow is a member of the Advisory Board for Philips Healthcare, a consultant for Three Palm Software. J. Ecanow and spouse are minor stockholders with Hologic, Inc.
- E037** R. Ellis is a consultant for Three Palm Software.
- E044** The Hitachi Corporation provided the Ultrasound equipment for this study.
- E050** C. Rojas is the recipient of honoraria and a member of the Speaker's Bureau for Siemens Medical Solutions; a consultant for E-Z-EM, Inc., Partners Imaging, Perceptive Informatics, Inc. and Magellan Healthcare, Inc.; and the recipient of a research grant from Bracco Diagnostics, Inc.
- E051** A. El-Sherief is the recipient of honoraria and a member of the Speaker's Bureau for Siemens Medical Solutions; a consultant for E-Z-EM, Inc., Partners Imaging, Perceptive Informatics, Inc. and Magellan Healthcare, Inc.; and the recipient of a research grant from Bracco Diagnostics, Inc.
- E052** C. Rojas is the recipient of honoraria and a member of the Speaker's Bureau for Siemens Medical Solutions; a consultant for E-Z-EM, Inc., Partners Imaging, Perceptive Informatics, Inc. and Magellan Healthcare, Inc.; and the recipient of a research grant from Bracco Diagnostics, Inc.
- E054** W. Shuman is a consultant for GE Healthcare.
- E057** R. Cury is the recipient of grant support from Astellas Pharma, Inc. US (which is one of the manufacturers of adenosine, a drug used during the acquisition of perfusion CT scans).
- E074** R. Gilkeson and L. Ciancibello are the recipients of research support from Siemens Medical Solutions.
- E076** J. Leipsic is a member of the Speaker's Bureau for GE Healthcare. J. Leipsic and B. Heilbron are the recipients of research grants from GE Healthcare.
- E110** C. Caluser and B. Gheorghie have a financial interest in Metritrack, LLC.
- E112** A. Friedman - CTC at home, content provider and medical advisor.
- E115** K. Chui has a financial interest in the publication as he is the General Manager/owner of Image Enhancement Technology Ltd. S.L. Chui is a field-trial research collaborator who has no financial interest in the abstract works.

DISCLOSURES OF COMMERCIAL INTEREST

- E145** E. Siegel is the recipient of research grants from General Electric Company and Siemens Medical Solutions AG; a member of the Speaker's Bureau for TeraRecon, Inc.; a member of the Advisory Board for Mercury Computer Systems, Inc.; and a member of the Board of Directors for Carestream Health, Inc.
- E199** L. Tanenbaum is a member of the Speaker's Bureau for GE Healthcare.
- E218** M. Prince has patent agreements with GE Healthcare, Siemens Medical Solutions, Philips Healthcare, Hitachi, Medrad, Mallinckrodt, Nemoto, Bracco Diagnostics, Bayer, Epix, Lantheus and Topspins.
- E221** P. Pickhardt and D. Kim have a consultation relationship with Viatronix, Inc.
- E266** B. Friedman is a member of the Speaker's Bureau for Eovist (Bayer Pharmaceuticals).
- E269** C. Sirlin is the recipient of research grants from GE Healthcare, Bayer Pharmaceuticals, and Bracco Diagnostics; and a consultant and member of the Advisory Board for Bayer Pharmaceuticals.
- E277** H. Tchelepi is a Speaker and the recipient of honoraria from GE Healthcare Ultrasound.
- E286** P. Woodward has an affiliation with Amirsys, Inc.
- E323** E. Fishman is the recipient of research support and a member of the Advisory Board for Siemens Medical Solutions AG, as well as co-founder of Hip Graphics, Inc. and a member of the Company Advisory Board for General Electric.
- E437** F. Gaillard is the founder and editor-in-chief of Radiopaedia.org – an educational organisation devoted to providing and developing collaborative radiology reference material online. We accept sponsorship and display sponsor banners on the site. There is no editorial control.
- E459** R. Wissman provides research support for DePuy Orthopedics.
- E472** S. Lee's abstract was supported by the 2004 Inje University research grant.
- E651** E. Fishman is the recipient of grants/research support and a consultant for Siemens Medical Solutions, USA, and a stock shareholder in Hip Graphics, Inc.
- E673** B. Mansouri has intellectual property in the field (BJW) Cooperative research and a development agreement with Philips Healthcare.
- E702** R. Lin owns Zig and Tuff, LLC, which funded this research.

Planners

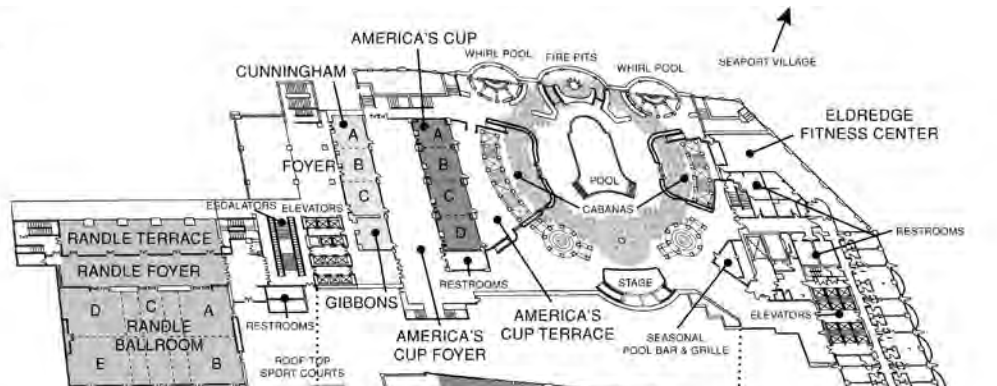
M. Rosado de Christenson is an author for the American Registry of Pathology, Amirsys, and Thieme Medical Publishers.



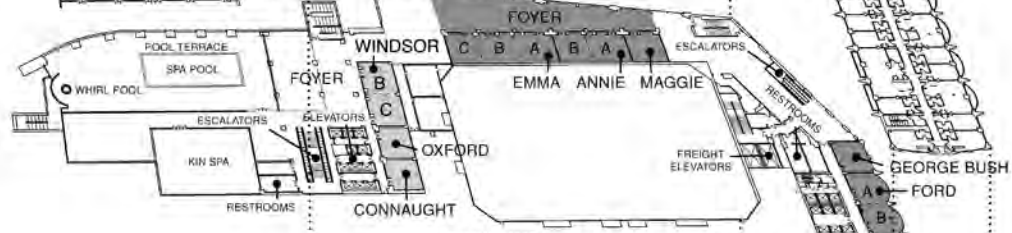
MANCHESTER GRAND HYATT



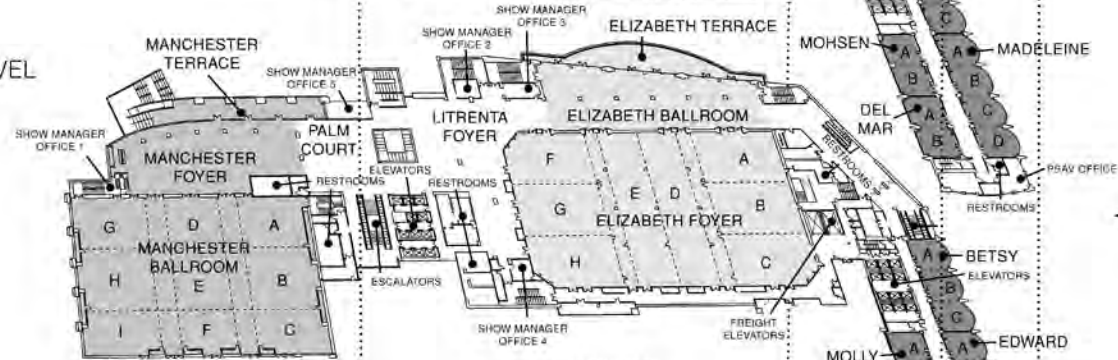
FOURTH LEVEL



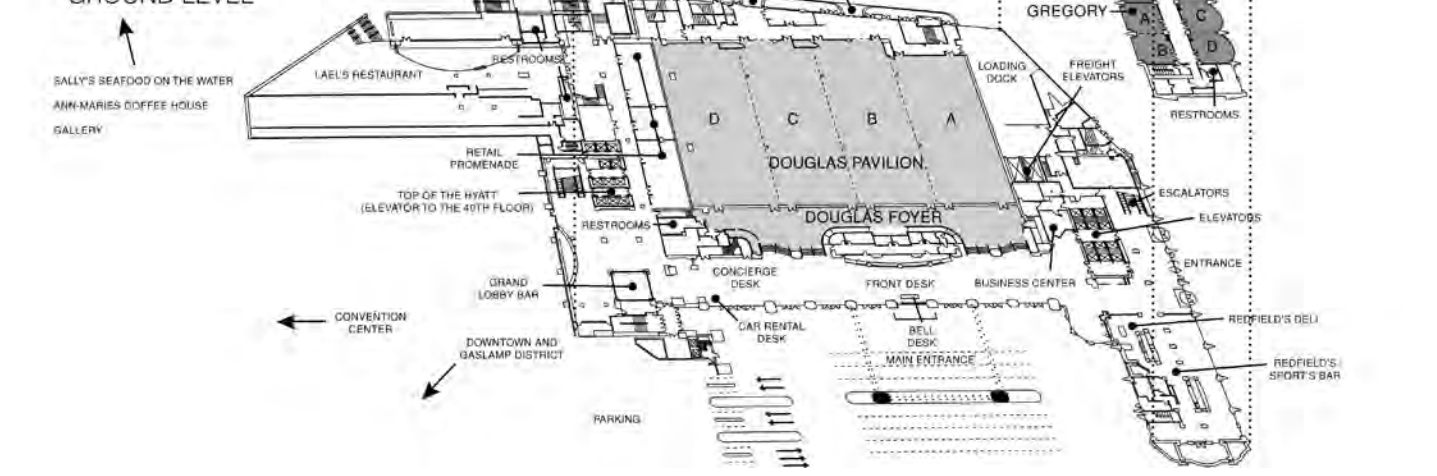
THIRD LEVEL



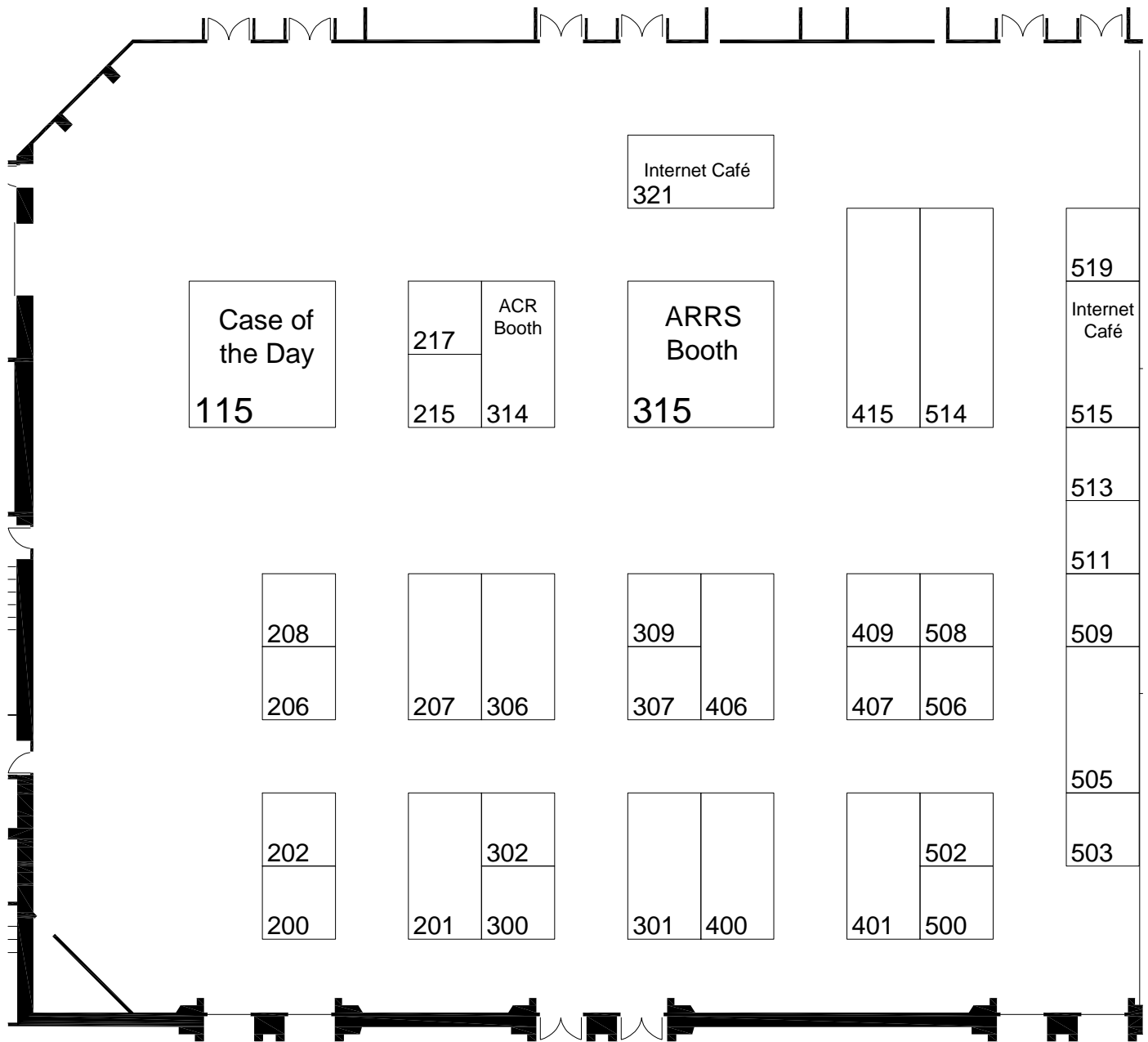
SECOND LEVEL



GROUND LEVEL



COMMERCIAL EXHIBIT HALL



Company	Booth	Company	Booth	Company	Booth
American Board of Radiology	202	EagleEye Radiology, Inc.	506	Sheridan Healthcare, Inc.	500
American College of Radiology	314	Elsevier-Mosby/Saunders	415	Siemens Healthcare	306
American Roentgen Ray Society	315	Ethicon Endo-Surgery	307	Sunset Radiology, Inc.	519
Amirsys, Inc.	409	GE Healthcare	301	TeraRecon, Inc.	207
Apriomed, Inc.	508	Hologic	406	Thieme Publishers	511
Aris Teleradiology	208	iCRco, Inc.	509	Third Eye Teleradiology, Inc.	513
Bard Biopsy Systems	300	Lippincott Williams & Wilkins	400	Toshiba Medical Systems USA	514
Bassett Medical Center	200	McKesson	407	U.S. Radiology On-Call	309
Bayer Healthcare Pharmaceuticals	201	Medical Doctor Associates, Inc.	302	Vital Images, Inc.	503
Bracco Diagnostics, Inc.	401	MEDRAD, Inc.	502	Whitaker Medical	215
DR Systems, Inc.	217	Physicians Business Network, Inc.	505		
		SenoRx, Inc.	206		

Floor plan is subject to Fire Marshal approval.



**ARRS 2010 Annual Meeting
CME Credit Forms and
Course Evaluations are
available online at
<http://cme.rrs.org>**

**Your user name is arrs then your badge number
(for example, *arrs123456*).**

The password is arrs2010.

**Please note that your badge number
(which is found on the back of your badge)
is also your ARRS ID number.**

**<http://cme.rrs.org>
Opens May 2, 2010
Closes May 21, 2010**

***ARRS is going green and saving four trees by not
including CME credit forms and evaluations
in your registration packet.***

CATEGORICAL COURSE SCHEDULE



PRACTICAL APPROACHES TO COMMON CLINICAL CONDITIONS: EFFICIENT IMAGING (PAC³E)-SETTING THE PAC³E OF IMAGING

Course Directors: *Ruth C. Carlos, MD, MS; Yoshimi Anzai, MD, MPH; C. Craig Blackmore, MD, MPH; Paul P. Cronin, MD, MS; L. Santiago Medina, MD, MPH*

Registration and a separate fee are required for this course.

Manchester Ballroom, Second Level

Who Should Attend: Radiologists, radiologists-in-training and other health professionals interested in practical and efficient application of imaging in the evaluation of common cardiothoracic, neuroradiologic, pediatric, and emergency radiology conditions.

Goals and Objectives: Following completion of the program, participants should have an understanding of practical approaches for appropriate use of imaging in the wide spectrum of diseases and disorders affecting the heart, lungs, brain, spine, gastrointestinal tract and musculoskeletal system for efficient evidence-based management of adult and pediatric patients in the ambulatory and emergency settings.

SUNDAY, MAY 2

7:30 am–10:00 am

7:30 am–7:35 am	Introduction— <i>R. Carlos</i>
7:35 am–8:00 am	Introduction to Evidence Based Imaging— <i>S. Medina</i>
8:00 am–9:00 am	Acute Chest Pain in the Emergency Department: Overview, Protocol, Application and Scientific Basis— <i>C. White</i>
9:00 am–9:20 am	Imaging in Pulmonary Embolus: Imaging Findings in Thromboembolic Disease— <i>A. Kelly</i>
9:20 am–9:40 am	Imaging in Pulmonary Embolus: Current Controversies in PE Imaging— <i>P. Cronin</i>
9:40 am–10:00 am	Imaging in Pulmonary Embolus: Accuracy of Imaging PE/Current Guidelines— <i>A. Kelly</i>

10:30 am–12:30 pm

10:30 am–10:50 am	Diagnosing Coronary Artery Disease: Technique and Novel Technologies— <i>U.J. Schoepf</i>
10:50 am–11:30 am	Diagnosing Coronary Artery Disease: Coronary CTA— <i>U.J. Schoepf</i>
11:30 am–11:50 am	Imaging of Aortic Aneurysms: Screening— <i>P. Cronin</i>
11:50 am–12:10 pm	Imaging of Aortic Aneurysms: Diagnosis— <i>A. Kelly</i>
12:10 pm–12:30 pm	Imaging of Aortic Aneurysms: Surgical versus Endovascular Treatment— <i>P. Cronin</i>

1:30 pm–3:30 pm

1:30 pm–2:30 pm	Updates in Lung Cancer: Role of Imaging in Screening, Staging and Restaging Lung Cancer— <i>J. Ravenel</i>
-----------------	--

2:30 pm–2:50 pm

Imaging of the Pediatric Chest: Chest Infection—*S. Westra*

2:50 pm–3:10 pm

Imaging of the Pediatric Chest: Mediastinal Non-Vascular Masses—*E. Lee*

3:10 pm–3:30 pm

Imaging of the Pediatric Chest: Vascular Rings, Slings, Tracheal Rings—*R. Krishnamurthy*

4:00 pm–6:00 pm

4:00 pm–4:30 pm

Stroke: Role of Imaging for Diagnosis of Acute Stroke—*N. Beauchamp*

4:30 pm–5:00 pm

Stroke: Treatment of Acute Stroke—*D. Hallam*

5:00 pm–5:30 pm

Low Back Pain: When and How Do You Image Back Pain—*J. Jarvik*

5:30 pm–6:00 pm

Low Back Pain: How Do You Treat Low Back Pain—*G. Zoarski*

MONDAY, MAY 3

7:30 am–9:30 am

7:30 am–8:00 am

Dementia: Role of MR Imaging for Diagnosis—*M. Petrou*

8:00 am–8:30 am

Dementia: Role of PET Imaging for Prognosis—*S. Minoshima*

8:30 am–9:10 am

Traumatic Brain Injury: When and How to Image and Prediction Criteria—*Y. Anzai*

9:10 am–9:30 am

Traumatic Brain Injury: Advanced Imaging Techniques—*R. Lee*

10:00 am–12:00 noon

10:00 am–10:30 am

Nontraumatic Acute Intracerebral Hemorrhage: Diagnostic Work-Up and Algorithm—*J. Kim*

10:30 am–11:00 am

Nontraumatic Acute Intracranial Hemorrhage: Treatment of Cerebral AVM—*B. Ghodke*

11:00 am–11:30 am

Imaging in Cervical Spine Trauma: Use of CT—*S. Mirvis*

11:30 am–12:00 noon

Imaging in Cervical Spine Trauma: Use of MRI—*A. Flanders*

1:00 pm–3:00 pm

1:00 pm–2:00 pm

Appendicitis—*C. Blackmore, J. Rhea*

2:00 pm–2:30 pm

Imaging of Appendicitis in Pregnancy—*D. Katz*

2:30 pm–3:00 pm

Abdominal Ischemia—*I. Kirkpatrick*

3:30 pm–6:10 pm

3:30 pm–4:00 pm

Obstruction—*M. Staunton*

4:00 pm–4:30 pm

Abdominal Trauma—*J. Gross*

4:30 pm–5:00 pm

Imaging in Acetabular Trauma—*A. Wilson*

5:00 pm–5:30 pm

Evidence-Based Imaging of Injuries of the Hip: Current Concepts—*J. Yu*

5:30 pm–5:50 pm

Pediatric Musculoskeletal Imaging: Slipped Capital and Femoral Epiphysis and Obesity—*R. Restrepo*

5:50 pm–6:10 pm

Pediatric Musculoskeletal Imaging: Imaging in Scoliosis—*G. Khanna*

CATEGORICAL COURSE SCHEDULE

TUESDAY, MAY 4

7:00 am–10:00 am

- 7:00 am–7:30 am Imaging in Nonaccidental Pediatric Trauma: CNS Injury—*Y. Sato*
- 7:30 am–8:00 am Imaging of Child Abuse: Non-CNS Injury—*K. Applegate*
- 8:00 am–8:40 am Imaging of the Pediatric Abdomen: Pyloric Stenosis and Malrotation—*M. Hernanz-Schulman*
- 8:40 am–9:20 am Imaging of the Pediatric Abdomen: Appendicitis/Intussusception—*K. Applegate*
- 9:20 am–10:00 am Imaging of the Pediatric Abdomen: Abdominal Neoplasms—*M. Siegel*

10:30 am–12:00 noon

- 10:30 am–10:35 am Beyond the Pale—A 5mP³ on EBM—*J. Crowe*
- 10:35 am–11:05 am Where the Rubber Meets the Road: IT in Critical Results Reporting—The Challenges and the Promises Where We Are Now and Where We Are Going—*J. Chen*
- 11:05 am–11:35 am Where the Rubber Meets the Road: Evidence-Based Medicine and the Courts—*A. Relyea-Chew*
- 11:35 am–12:00 noon Where the Rubber Meets the Road: Evidence-Based Medicine and Economics/Regulations—*D. Larson*

Lunch will be served in the exhibit hall Monday-Wednesday from 12:00 noon–1:00 pm



REVIEW COURSE SCHEDULE



APPROACH TO DIAGNOSIS: A CASE-BASED IMAGING REVIEW

Course Directors: *Deborah Baumgarten, MD, MPH, Sanjeev Bhalla, MD, Lonie Salkowski, MD, Donald Yoo, MD*

Registration and a separate fee are required for this course.

Manchester Ballroom, Second Level

Who Should Attend: Radiology professionals at all career stages with an interest in a review of diagnostic imaging cases representing a wide array of specialty areas.

Goals and Objectives: Upon completion of the course, participants should be able to: detect, comprehensively assess and correctly diagnose various conditions and diseases from 11 radiology subspecialties; identify and recommend the most advantageous imaging modality or interventional technique for cases encountered in their practice; and describe the distinguishing characteristics that aid in pinpointing the correct diagnosis of cases that are imaged in practice.

TUESDAY, MAY 4

1:00 pm–3:30 pm Nuclear Medicine

PET/CT—*D. Yoo**
Endocrine—*E. Akin*
Gastrointestinal—*H. Jacene*
Pediatrics—*T. Wong*
Skeletal—*C. Rajadhyaksha*

4:00 pm–6:30 pm Cardiovascular Imaging

Cardiac MR: Common Applications—*C. Javidan-Nejad*
Cardiac CT: Common Applications—*J. Hsu*
Pulmonary Artery CT and MR—*K. Birchard*
Plain Film—*S. Bhalla**
Aortic CT and MR—*S. Seth*

WEDNESDAY, MAY 5

7:30 am–10:00 am Breast Imaging

Calcifications—*T. Stephens*
Ultrasound Evaluation of Mammographic Findings—*A. Nees*
Architectural Distortion and Asymmetries—*L. Salkowski**
Ductal Pathology—*M. Szabunio*
Breast MRI—*A. Soetaert*

1:00 pm–3:30 pm Pediatric Imaging

Chest/Pulmonary—*E. Lee**
Musculoskeletal—*E. Mann*
Abdominal—*S. Anupindi*
Neurology—*D. Rivard*
Genitourinary—*S. DiPerna*

4:00 pm–6:30 pm Vascular and Interventional Radiology

Arterial Diagnosis—*B. Funaki*
Arterial Therapy—*S. Zangan**
Venous Interventions—*C. Ray*
Nonvascular Interventions—*M.G. Knuttinen*
Interventional Oncology—*A. Nemcek*

THURSDAY, MAY 6

7:30 am–10:00 am Gastrointestinal Imaging

Liver—*C. Santillan**
Gallbladder/Biliary—*B. Yeh*
Pancreas—*C. Menias*
Small Bowel—*Z.J. Wang*
Colon—*H. Zafar*

10:30 am–1:00 pm Musculoskeletal Imaging

Injuries—*D. Blankenbaker**
Funny Looking Bones—*K. Davis*
Soft Tissue Tumors—*C. Gaskin*
Bone Tumors—*N. Safdar*
Arthritis—*S. Smith*

2:30 pm–5:00 pm Neuroradiology

Head and Neck—*M. Michel*
Spine—*J. Anderson**
Pituitary—*C. Glastonbury*
Intracranial Tumors—*C.D. Phillips*
Vascular—*M. Strother*

FRIDAY, MAY 7

7:30 am–10:00 am Genitourinary Imaging

Male Pelvis—*D. Casalino*
Kidney/Retroperitoneum—*E. Remer*
Female Pelvis—*C. Peterson*
Collecting System, Ureter, Bladder—*M. Hartman*
Miscellaneous—*D. Baumgarten**

10:30 am–1:00 pm Chest Imaging

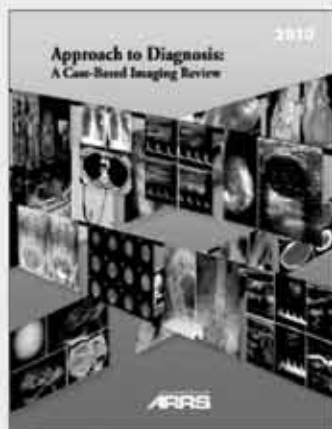Radiographic Signs—*G. Abbott**
Congenital Abnormalities—*E. Donnelly*
Autoimmune/Idiopathic—*D. Manos*
Trauma/Iatrogenic—*E. Moore*
Diffuse Lung Disease—*A. Sharma*

2:00 pm–4:30 pm Ultrasound

Obstetrics—*B. Hertzberg**
Gynecology—*O. Baltarowich*
Abdomen—*U. Hamper*
Small Parts—*D. Rubens*
Vascular—*L. Scoutt*

**Section Chair*

ARRS – Your Print Resource



ISBN: 978-1-890705-15-2
330+ diagnostic cases covering
11 areas of radiology



ISBN: 978-1-890705-13-8
330+ diagnostic cases covering
11 areas of radiology



ISBN: 1-890705-12-8
330+ diagnostic cases covering
11 areas of radiology



ISBN: 1-890705-09-8
330+ diagnostic cases covering
11 areas of radiology

APPROACH TO DIAGNOSIS: A CASE-BASED IMAGING REVIEW

Member Price: SPECIAL – \$200 for four **\$65 each**
SPECIAL – \$155 for three
SPECIAL – \$110 for two

Member-In-Training Price: SPECIAL – \$155 for four **\$50 each**
SPECIAL – \$120 for three
SPECIAL – \$85 for two

Nonmember Price: SPECIAL – \$495 for four **\$150 each**
SPECIAL – \$385 for three
SPECIAL – \$270 for two

Each workbook includes more than 330 challenging diagnostic radiology cases covering 11 broad categories of disease and technology. Readers will be able to improve their ability to detect, assess, and diagnose various conditions and diseases using multiple imaging techniques. Answers to cases are presented in the back of the book. These workbooks are appropriate for radiology professionals at all career stages with an interest in a case-based review of diagnostic imaging cases.

Sample chapters are available at www.arrs.org. These workbooks are a must-have for every radiology professional.

Order at www.arrs.org

Visit the ARRS Booth #315 in the Exhibit Hall and Purchase Your Workbooks Today.

SUNDAY, MAY 2



6:30 am– 6:30 pm

Registration

Elizabeth Foyer, Second Level

6:30 am–6:00 pm

Speaker Preview

Molly A/B, Second Level

7:30 am–6:00 pm

Categorical Course on Efficient Imaging

There is an additional fee to attend this course.

Manchester Ballroom, Second Level

8:00 am–12:00 noon

Item-Writing Workshop

Randle A, Fourth Level

1:00 pm – 6:00 pm

Electronic Exhibits

Randle D/E, Fourth Level

1:30 pm–5:00 pm

Business/Practice Management Seminar

Education Seminar

Elizabeth G, Second Level

Elizabeth H, Second Level

SPECIAL EVENTS

4:30 pm–5:30 pm

Glimpses Into Our Submarine Service During the Cold War—A. Van Moore, J. Moorefield

Randle A, Fourth Level

6:15 pm–7:30 pm

Opening Ceremonies

Installation of Joseph K.T. Lee, MD by Ella A. Kazerooni, MD

Gold Medal Presentations to Philip O. Alderson, MD,

Barry Goldberg, MD and David E. Kuhl, MD

Best Educator Award

Elizabeth F, Second Level

CC=Categorical Course

IC=Instructional Course

SS=Scientific Session

The abstracts included in the scientific sessions and power hours are available at www.ajronline

2010 ARRS Categorical Course Syllabi

Practical Approaches to Common Clinical Conditions: Efficient Imaging (PAC³E)

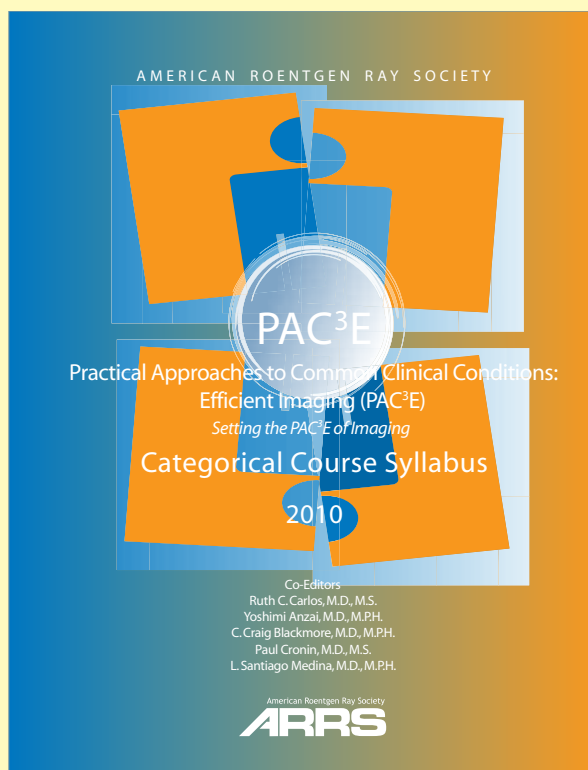
Setting the PAC³E of Imaging

21.5 Category 1 CME Credits

The book will offer practical approaches for appropriate use of imaging in the wide spectrum of diseases and disorders affecting the heart, lungs, brain, spine, gastrointestinal tract and musculoskeletal system for efficient evidence-based management of adult and pediatric patients in the ambulatory and emergency settings.

Co-Editors:

Ruth C. Carlos, M.D., M.S.
Yoshimi Anzai, M.D., M.P.H.
C. Craig Blackmore, M.D., M.P.H.
Paul P. Cronin, M.D., M.S.
L. Santiago Medina, M.D., M.P.H.



Pricing:

Members (with CME)	\$80
Nonmembers (with CME)	\$215
Nonmembers (no CME)	\$108

Visit the ARRS Booth #315 in the Exhibit Hall to Purchase Your Copy Today.

SUNDAY SCHEDULE



7:30 am–6:00 pm

Categorical Course: Practical Approaches to Common Clinical Conditions: Efficient Imaging (PAC³E) Setting the PAC³E of Imaging

Registration and a separate fee required for this course.

Manchester Ballroom, Second Level

- 7:30 am–7:35 am
Introduction—*R. Carlos*
- 7:35 am–8:00 am
Introduction to Evidence-Based Imaging—*S. Medina*
- 8:00 am–9:00 am
Acute Chest Pain in the Emergency Department: Overview, Protocol, Application and Scientific Basis—*C. White*
- 9:00 am–9:20 am
Imaging in Pulmonary Embolus: Imaging Findings in Thromboembolic Disease—*A. Kelly*
- 9:20 am–9:40 am
Imaging in Pulmonary Embolus: Current Controversies in PE Imaging—*P. Cronin*
- 9:40 am–10:00 am
Imaging in Pulmonary Embolus: Accuracy of Imaging PE/Current Guidelines—*A. Kelly*
- 10:30 am–10:50 am
Diagnosing Coronary Artery Disease: Technique and Novel Technologies—*U.J. Schoepf*
- 10:50 am–11:30 am
Diagnosing Coronary Artery Disease: Coronary CTA—*U.J. Schoepf*
- 11:30 am–11:50 am
Imaging of Aortic Aneurysms: Screening—*P. Cronin*
- 11:50 am–12:10 pm
Imaging of Aortic Aneurysms: Diagnosis—*A. Kelly*
- 12:10 pm–12:30 pm
Imaging of Aortic Aneurysms: Surgical versus Endovascular Treatment—*P. Cronin*
- 1:30 pm–2:30 pm
Updates in Lung Cancer: Role of Imaging in Screening, Staging and Restaging Lung Cancer—*J. Ravenel*
- 2:30 pm–2:50 pm
Imaging of the Pediatric Chest: Chest Infection—*S. Westra*
- 2:50 pm–3:10 pm
Imaging of the Pediatric Chest: Mediastinal Non-Vascular Masses—*E. Lee*
- 3:10 pm–3:30 pm
Imaging of the Pediatric Chest: Vascular Rings, Slings, Tracheal Rings—*R. Krishnamurthy*
- 4:00 pm–4:30 pm
Stroke: Role of Imaging for Diagnosis of Acute Stroke—*N. Beauchamp*
- 4:30 pm–5:00 pm
Stroke: Treatment of Acute Stroke—*D. Hallam*
- 5:00 pm–5:30 pm
Low Back Pain: When and How Do You Image Back Pain—*J. Jarvik*
- 5:30 pm–6:00 pm
Low Back Pain: How Do You Treat Low Back Pain—*G. Zoarski*

8:00 am–12:00 noon

Item-Writing Workshop

Course Director: *Jannette Collins, MD*

Randle A, Fourth Level

Who Should Attend: Radiology professionals with an interest in writing multiple choice items for ABR exams, SAMs and other adult educational activities.

Goals and Objectives: Upon completion of the program, the participants should be able to write and edit multiple choice items appropriate for adult educational activities, in particular ABR examinations and ABR-qualified self-assessment modules (SAMs).

- 8:00 am–8:30 am
Update on ABR Written Exams and SAMs—*G. Becker*
- 8:30 am–9:30 am
The Role of Objectives in Writing MCQs—*B. Wood*
- 9:30 am–10:40 am
Writing Good MCQs—*J. Collins*
- 10:40 am–12:00 noon
Review of Participant and Instructor MCQs—*J. Collins*

1:30 pm–5:00 pm

Business and Practice Management Seminar

Course Director: *Jonathan Berlin, MD*

Elizabeth G, Second Level

Who Should Attend: Radiologists and other health care professionals at all levels of training with an interest in the business and management of radiology as well as the impact of the current political and economic climate on radiology practice.

Goals and Objectives: Upon completion of the business and practice management seminar, participants will be able to describe the current and anticipated policy, economic and legislative changes and actions that will have an impact on radiology practice; and identify any changes regarding the participant's role and business practices that he/she plans to implement to assure his/her significance and viability in the healthcare system and environment.

- 1:30 pm–2:00 pm
Issues in Radiology Utilization: The Payer's Perspective—*R. Leithiser*
- 2:00 pm–2:30 pm
Federal Health Care Reform and Its Impact on Radiology—*F. Lexa*
- 2:30 pm–3:00 pm
Radiology Benefit Managers—St. George or the Dragon?—*D. Levin*
- 3:30 pm–4:00 pm
Voice Recognition: Financial and Non-Financial Factors—*J. Berlin*
- 4:00 pm–4:30 pm
Why Radiologists Are Losing Their Hospital Contracts: Is Your Contract Safe?—*L. Muroff*
- 4:30 pm–5:00 pm
Leadership Challenges for Radiology in the Future—*A. Kaye*

SUNDAY SCHEDULE



1:30 pm–5:00 pm

Education Seminar: Effective Feedback

Course Director: *Richard Gunderman, MD*

Elizabeth H, Second Level

Who Should Attend: Radiology professionals and educators seeking to better understand feedback and enhance the quality of feedback in their organizations.

Goals and Objectives: Upon completion of this course, attendees will be able to define feedback in education and the different forms it can take; outline the features that characterize effective feedback; and develop strategies for improving the frequency and quality of feedback in their educational programs.

1:30 pm–1:35 pm

Introduction—*R. Gunderman*

1:35 pm–2:05 pm

Feedbacks Pros and Cons—*R. Gunderman*

2:05 pm–2:30 pm

Feedback 101—*B. Wood*

2:30 pm–3:00 pm

Why We Hate to Evaluate—*S. Gay*

3:30 pm–3:50 pm

Promoting Critical Reflection—*S. Chan*

3:50 pm–4:10 pm

What Shall We Do With All This Feedback?—*A. Douglas-Akinwande*

4:10 pm–5:00 pm

Critical Communications and Difficult Conversations—*J. Lewin*

4:30 pm–5:30 pm

SRS Sponsored Lecture: Glimpses Into Our Submarine Service During the Cold War—*A. Van Moore, J. Moorefield*

Randle A, Fourth Level

6:15 pm–7:30 pm

OPENING CEREMONIES

Elizabeth F, Second Level

Call to Order

**Installation of Joseph K.T. Lee, MD as 110th President
by Ella A. Kazerooni, MD**



Joseph K.T. Lee, MD

110th President

American Roentgen Ray Society

2010–2011

ARRS, Your Trusted Partner in Lifelong Learning

Gold Medal Presentations

Philip O. Alderson, MD—introduced by *Joseph K.T. Lee, MD*

Barry Goldberg, MD—introduced by *Christopher R.B. Merritt, MD*

David E. Kuhl, MD—introduced by *James H. Thrall, MD*

Best Educator Award

Presented to Melissa Rosado de Christenson

2010 GOLD MEDAL PRESENTATIONS



PHILIP O. ALDERSON, MD



Dr. Philip Alderson, a former president of the American Roentgen Ray Society, was born in San Francisco, CA, and raised in St. Louis, MO. He earned his bachelor's degree and MD from Washington University in St. Louis, and completed his residency in nuclear medicine and radiology at the Mallinckrodt Institute of Radiology at Washington University School of Medicine. Dr. Alderson is board certified by the American Board of Nuclear Medicine and the

American Board of Radiology. He currently serves as dean of the School of Medicine and vice president for Health Sciences at Saint Louis University.

Dr. Alderson served as a major in the U.S. Air Force from 1975–1977, conducting research for the Defense Nuclear Agency at the Armed Forces Radiobiology Research Institute (AFRRI) in Bethesda, MD. He was a faculty member at the Johns Hopkins Medical Institutions from 1975–1980, starting as a part-time lecturer while he was at the AFRRI and completing his career at Johns Hopkins as an associate professor of radiology and environmental health sciences.

Dr. Alderson was appointed professor of radiology at the College of Physicians and Surgeons of Columbia University (Columbia-Presbyterian Medical Center) in 1980. He was appointed chair of the department of radiology in 1988, and served until he was appointed dean of the Saint Louis University School of Medicine in April 2008. As dean, he currently oversees the education, research and clinical service missions of the school. In 2009, he also was appointed vice president for Health Sciences at the university. In this role he oversees seven other schools and centers on the health sciences campus.

Dr. Alderson has been active and held office in many professional organizations throughout his career. In addition to being a past president of the American Roentgen Ray Society, Dr. Alderson has served as president of the American Board of Radiology; the Association of University Radiologists; the Association of Program Directors in Radiology; the Academy of Radiology Research; the Fleischner Society; the Society of Chairmen of Academic Radiology Departments; the New York State Radiological Society; and the New York (City) Roentgen Society. He also served as vice president of the American College of Radiology and the Society of Nuclear Medicine. Dr. Alderson is a Fellow of the American College of Radiology; the American College of Nuclear Physicians; the American Institute for Medical and Biological Engineering; and the American Association for the Advancement of Science.

Dr. Alderson has more than 200 publications; including four books, 40 book chapters, and more than 150 journal articles. He has made more than 200 presentations at local, national, and international meetings and scientific symposia including 10 named lectureships, and is listed in *Who's Who in the World*, *Who's Who in America*, *Who's Who in American Education*, *Who's Who Among America's Teachers*, *Who's Who in Medicine and Healthcare*, and *Best Doctors in America*. He has received the Gold Medal of the Association of University Radiologists and the Achievement Award of both the Association of Program Directors in Radiology and the New York Roentgen Society.

Dr. Alderson resides in St. Louis, MO, with his wife, Marjorie. They have two children and two grandchildren.

BARRY B. GOLDBERG, MD



Dr. Barry Benson Goldberg, a native of Philadelphia, PA, is a professor of radiology with tenure at Thomas Jefferson University Medical College in Philadelphia, PA, and a clinical professor in the department of diagnostic imaging at Thomas Jefferson University's College of Health Professions where he also serves as the medical director of the diagnostic medical sonography program. He is also director of the division of diagnostic ultra-

sound; director of the Jefferson Ultrasound Research and Education Institute; and vice chairman of strategic planning in the department of radiology at Thomas Jefferson University Hospital.

Dr. Goldberg earned his undergraduate degree and MD from the University of Pennsylvania. He completed his internship and radiology residency at Albert Einstein Medical Center where he developed a special interest in ultrasound.

Dr. Goldberg first came in contact with ultrasound during his first year of residency when Dr. Gershon-Cohen, former chair of the Albert Einstein Medical Center radiology department, had just bought one of the first three commercially produced ultrasound machines in the United States. Dr. Goldberg expressed interest in the new imaging machine and began spending countless days and nights performing extensive research to see what could be imaged with it.

During his early work, Dr. Goldberg spent many early mornings before starting work performing ultrasound on cadavers. During the work day, in between learning and reading cases, whenever a radiologist would point out that there was a mass seen on X-ray in the kidney, uterus, ovaries, or elsewhere, he would also take the ultrasound machine and image the mass. His other area of research at the time involved pregnant women. He learned from reading literature that it was possible to determine the measurement of the fetal head with an ultrasound examination, and so he began doing just that. Dr. Goldberg's wife Phyllis would often accompany him on the delivery floor and record the fetal head measurements while he performed the examinations.

Dr. Goldberg established the ultrasound division at Thomas Jefferson University Hospital which is one of the largest ultrasound facilities in the world, performing more than 40,000 examinations a year in 20 clinical examination rooms. In 1992, the university created the Jefferson Ultrasound Research and Education Institute (JUREI), with Dr. Goldberg as its director. JUREI is recognized by the World Health Organization as its only collaborating center for continuing and general education in diagnostic ultrasound and has trained more than 20,000 physicians, scientists, and sonographers world-wide. The institute has opened ultrasound education programs and training centers in developing and emerging countries around the world through funding from foundations, corporations, and U.S. Government agencies.

Dr. Goldberg presented his first scientific paper during his second year of residency. It was, in fact, the first scientific paper on ultrasound to ever be presented at the Radiological Society of North America's (RSNA's) annual meeting. Since then he has written 313 peer-reviewed papers and 96 book chapters. He has also written and/or edited 29 books and has received more than 140 grants for ultrasound research.

2010 GOLD MEDAL PRESENTATIONS



Dr. Goldberg has received many honorary professorships and fellowships from around the world. He has been named as a fellow of the American College of Radiology; the American Institute of Ultrasound in Medicine; the Society of Radiologists in Ultrasound; the American Heart Association; the Council of Cardiovascular Radiology; and the American Institute for Medical and Biological Engineering. He is also an honorary fellow of the Royal College of Radiologists in London, England.

The RSNA recognized Dr. Goldberg's research accomplishments and educational achievements when they granted him the Outstanding Researcher Award and the Outstanding Educator Award. The International Society of Radiology recognized him for his contributions to the advancement of International Radiology with its highest honor, the Antoine Beclere Medal at the 23rd International Congress of Radiology in Montreal, Canada.

Founder and president of the Global Ultrasound Equipment Donation Foundation (GUEDF), Dr. Goldberg helps provide donated ultrasound equipment to needy clinics, hospitals, and teaching facilities in emerging and developing countries around the world. To date, GUEDF has donated more than 300 ultrasound machines to needy centers. He is a past president of the Radiology Outreach Foundation (ROF), a non-profit foundation whose goal is to help improve healthcare in developing countries by providing radiology educational materials and equipment.

Dr. Goldberg has been married to his wife Phyllis for 46 years. His two children have brought him great joy. However, if you really want to see him smile, ask him about his grandchildren, Bradley and Hannah.

DAVID E. KUHL, MD



Dr. David E. Kuhl, of Ann Arbor, MI, who has been called the father of emission tomography, has contributed greatly to the development of tomographic imaging in nuclear medicine. He is a professor of radiology at the University of Michigan Medical School.

Dr. Kuhl received his undergraduate degree in physics from Temple University and his MD from the University of Pennsylvania. After completing a rotating internship at the Hospital of the University of Pennsylvania, he served two years in the United States Navy at the U.S. Naval Hospital in Portsmouth, VA. He completed his residency and fellowship in radiology shortly after at the Hospital of the University of Pennsylvania.

In the late 1950s, Dr. Kuhl developed a novel method of tomographic imaging of the distribution of radioactive isotopes in the body. In the mid-1960s, he succeeded in the axial transverse tomographic imaging of humans. This was before the development of X-ray CT, and the technology had a great impact on the development and evolution of various methods of computed tomography, including positron emission tomography (PET).

Dr. Kuhl has held various positions at several academic universities. He began his academic career at the University of Pennsylvania School of Medicine where he was a professor of radiology; a professor of bioengineering; the chief of the division of nuclear medicine; and vice chairman of the department of radiology. In 1976, he left the University of Pennsylvania for the University of California at Los Angeles School of Medicine where he served as professor of radiological sciences; chief of the division of nuclear

medicine; associate director of the Laboratory of Biomedical and Environmental Sciences; and vice chairman of the department of radiological sciences. Since 1986, Dr. Kuhl has worked at the University of Michigan School of Medicine. Currently a professor of radiology, he has also served as a professor of internal medicine; the chief of the division of nuclear medicine; and director of the PET center.

Dr. Kuhl has been an active member of numerous professional societies and organizations. He was a founding trustee of the American Board of Nuclear Medicine and is a fellow of the American College of Radiology and of the American Institute of Medical and Biological Engineering. He serves as an elected member of the Institute of Medicine of the National Academy of Sciences.

As a respected member of the radiological community, Dr. Kuhl has participated in more than 400 visiting professorships and invited lectureships. To his credit, he has published more than 200 journal articles, 102 book chapters, two books, and more than 300 abstracts.

Dr. Kuhl has received honors and awards throughout his career. His most recent was the Japan Prize from the Science and Technology Foundation of Japan. He was awarded for his work in the field of technological integration of medical science and engineering and his contribution to tomographic imaging in nuclear medicine. He was also awarded the Charles F. Kettering Prize from the General Motors Cancer Research Foundation in 2000 for the most outstanding recent contribution to the diagnosis and treatment of cancer.

Dr. Kuhl has a special research interest to introduce new measures of neurochemical and metabolic processes determined within the living brain using radioactive molecular tracers and emission reconstruction tomography (PET and SPECT). A goal is to enable drug development targeted to the earliest stages of degenerative brain disease.

MONDAY, MAY 3



6:00 am–5:30 pm
Speaker Preview Room

Molly A/B, Second Level

6:30 am–4:30 pm
Registration

Elizabeth Foyer, Second Level

7:00 am–12:00 midnight
Electronic Exhibits

Randle D/E, Fourth Level

7:30 am–6:00 pm
Categorical Course on Efficient Imaging
There is an additional fee to attend this course.

Manchester Ballroom, Second Level

9:30 am–10:30 am
Caldwell Lecture: Dr. Benjamin Chu
(coffee will be served at the Caldwell Lecture)
Coffee Break in the Exhibit Hall

Douglas B, Lobby Level

Elizabeth Ballroom, Second Level

12:00 noon–1:00 pm
Lunch in the Exhibit Hall

Elizabeth Ballroom, Second Level

2:30 pm–3:30 pm
Scholars and Awards Session

Elizabeth F, Second Level

3:00 pm–4:00 pm
Soda Break in the Exhibit Hall

Elizabeth Ballroom, Second Level

*CC=Categorical Course
IC=Instructional Course
SS=Scientific Session*

CORPORATE SPONSORED ACTIVITY

7:00 am–8:00 am
Latest Clinical Investigations using 320 Detector Row CT—*Frank Rybicki, MD*
Sponsored by Toshiba America Medical Systems
(Breakfast will be available for the first 130 attendees)

Douglas D, Lobby Level

Annual Scholarship Program

Medical schools, affiliated hospitals and clinical research institutions are invited to nominate one candidate for the 2011 ARRS scholarship program. The candidate must be a member of the ARRS at the time the application is submitted and for the duration of the award.

The scholarships are intended to support study that will enable the scholar to acquire knowledge, skills and training in areas that are vital to the future of radiology and to attain his or her professional career goals.

Up to two scholarships of \$140,000 each are funded annually. Scholars may choose a one-year program requiring a minimum 80% time commitment or a two-year program requiring a minimum 50% time commitment. The scholarships are funded through a grant from The Roentgen Fund®.

The general requirements for candidates are:

- MD or DO from an accredited institution;
- completion of all required residency, fellowship training or equivalent;
- certification by the American Board of Radiology or equivalent;
- full-time faculty appointment as a lecturer, instructor, assistant professor or equivalent for no more than five years beyond completion of training.
- The candidate must be a member of the ARRS at the time the application is submitted and for the duration of the award.

The appointment must be in a department of radiology, nuclear medicine, or an associated department in the radiological sciences of a medical school teaching hospital in the U.S. or Canada.

Selection will be based on the competence and promise of the candidate in research, education or administration related to medical imaging as indicated by the institution making the nomination; evidence that an environment will be provided that is conducive to well-rounded professional development; and personal qualities of the candidate that indicate that he or she is a scholar and leader with exceptional potential.

Acceptance of an award from another source for the same or similar project is prohibited unless one source provides salary support only and the other source provides support only for non-personnel research expenses.

For more information about the scholarship program and application procedures, visit the ARRS Website (www.arrs.org) or telephone 800-347-7748 or 703-648-8900.

The deadline for submission of applications is November 15, 2010.



MONDAY SCHEDULE



7:00 am-8:00 am

Power Hour: Breast Imaging—*G. Newstead, moderator*

Randle B, Fourth Level

- E001. Radiologic-Pathology Correlations in Breast Imaging: A Primer for Radiologists—*J. Bykowski*
E017. Mammographic Asymmetries: Review of Terminology and Strategies for Increasing Cancer Detection—*D. March*
E024. Detection and Reporting of Extramammary Findings During Breast MRI—*H. Ojeda-Fournier*
E025. Optimal Timing of Breast MRI Examinations for Premenopausal Women Who Do Not Have a Normal Menstrual Cycle—*R. Ellis*
E027. Breast MRI: An Algorithm for Successful Cancer Diagnosis—*M. Yepes*
E029. Optimizing 1.5 T and 3.0 T Contrast-Enhanced Dynamic Breast MRI in Your Practice—*M. Lewis*
E031. Magnetic Resonance Imaging Findings of Pseudoangiomatous Stromal Hyperplasia (PASH) With Clinical and Pathologic Correlation—*K. Glazebrook*
E044. Diagnostic Performance of Elastography in the Evaluation of Lesions Referred for Breast Biopsy. Combined Use of Color and Strain Ratio Assessment—*T. Kumm*

7:00 am-8:00 am

Power Hour: Nuclear Medicine—*E. Rohren, moderator*

Randle A, Fourth Level

- E595. Is an 18-FDG PET/CT Superior to Tc-99m MDP Bone Scan With SPECT in the Initial Staging of Skeletal Metastases in Advanced Breast Cancer?—*A. Sacks*
E598. 18F-FLT PET/CT: Early Predictive Imaging Biomarker for Therapy Response—*D.S. Surasi*
E603. The Value of FDG-PET/CT in the Management of HIV-Related Malignancies—*R. Subramaniam*
E608. Outside The Box: Utilizing Balloon Models As a New Technique to Teach Concepts of Nuclear Cardiology—*P. Gerard*
E614. Extramedullary Disease of Multiple Myeloma: Multimodality Imaging With Emphasis on MR and PET/CT—*B. Nguyen*
E615. Out of the Box: The Unique Role of PET-CT in the Diagnosis and Management of Unusual Male Malignancies—*P. Gerard*

7:30 am-6:10 pm

Categorical Course: Practical Approaches to Common Clinical Conditions: Efficient Imaging (PAC³E)—*Setting the PAC³E of Imaging*

Manchester Ballroom, Second Level

- 7:30 am-8:00 am
Dementia: Role of MR Imaging for Diagnosis—*M. Petrou*
8:00 am-8:30 am
Dementia: Role of PET Imaging for Prognosis—*S. Minoshima*
8:30 am-9:10 am
Traumatic Brain Injury: When and How to Image and Prediction Criteria—*Y. Anzai*
9:10 am-9:30 am
Traumatic Brain Injury: Advanced Imaging Techniques—*R. Lee*
10:00 am-10:30 am
Nontraumatic Acute Intracerebral Hemorrhage: Diagnostic Work-Up and Algorithm—*J. Kim*

10:30 am-11:00 am

Nontraumatic Acute Intracranial Hemorrhage: Treatment of Cerebral AVM—*B. Ghodke*

11:00 am-11:30 am

Imaging in Cervical Spine Trauma: Use of CT—*S. Mirvis*

11:30 am-12:00 noon

Imaging in Cervical Spine Trauma: Use of MRI—*A. Flanders*

1:00 pm-2:00 pm

Appendicitis—*C. Blackmore, J. Rhea*

2:00 pm-2:30 pm

Imaging of Appendicitis in Pregnancy—*D. Katz*

2:30 pm-3:00 pm

Abdominal Ischemia—*I. Kirkpatrick*

3:30 pm-4:00 pm

Obstruction—*M. Staunton*

4:00 pm-4:30 pm

Abdominal Trauma—*J. Gross*

4:30 pm-5:00 pm

Imaging in Acetabular Trauma—*A. Wilson*

5:00 pm-5:30 pm

Evidence-Based Imaging of Injuries of the Hip: Current Concepts—*J. Yu*

5:30 pm-5:50 pm

Pediatric Musculoskeletal Imaging: Slipped Capital and Femoral Epiphysis and Obesity—*R. Restrepo*

5:50 pm-6:10 pm

Pediatric Musculoskeletal Imaging: Imaging in Scoliosis—*G. Khanna*

8:00 am-9:30 am

IC101. Breast Ultrasound: Basics Principles and Future—*S. Raza, M. Kettler*

Douglas C, Lobby Level

IC102. Cardiac CTA: Setting up a Cardiac Service; Reimbursement Issues—*D. Dowe*; Technical Considerations and Principles of Cardiac CTA—*S. Abbara*; Protocols and Reconstructions—*U.J. Schoepf*

Elizabeth G, Second Level

IC103. PET/CT for Solitary Pulmonary Nodule, Lung Cancer, and After Thermal Ablation—*S. Nayak, H. Agress, D. Yoo*

Elizabeth F, Second Level

IC104. Malpractice Issues in Radiology: Update 2010—*L. Berlin*

Douglas A, Lobby Level

IC105. Thromboembolic Axis of Evil: DVT, PE and IVC Filters—*T. Burdick, T. Kooy, L. Findeiss*

Elizabeth H, Second Level

SS1. Efficacy, Education and PACS: Safety and Communication—
Moderators: *J. Eng, R. Agarwal*; Keynote: Improving Communication of Radiology Results—*C. Kahn*

Connaught, Third Level

001. Ultra Low Dose MDCT Evaluation of the Axial Skeleton: A Comparison of Dose and Subjective Clinical Efficacy
Lu, M.; Chen, J.; Daly, B.; Yang, Z.; Siegel, E. University of Maryland, Baltimore, MD*

002. Valkyrie: Automated Framework for Digital Radiation Dose Reporting from CT Dose Reports
Shih, G.¹; Lu, Z.²; Kennedy, D.³; Loftus, M.¹; Shih, W.⁴; Osborne, J.¹; Zabih, R.¹; Nickoloff, E.² 1. Weill Cornell Medical Center, New York, NY; 2. Columbia University Medical Center, New York, NY; 3. Cornell University, Ithaca, NY; 4. University of Kentucky, Lexington, KY

MONDAY SCHEDULE



003. Intravenous Contrast Extravasation Events During CT Scans: Documentation and Outcomes at an University Teaching Hospital
Lee, E.; Solle, M.; Fielding, J. UNC School of Medicine, Chapel Hill, NC*

004. Simulation Lab Training for Radiology Residents in the Management of Contrast Reactions
Sarwani, N.; Tappouni, R. Penn State Milton S. Hershey Medical Center, Hummelstown, PA*

005. Analysis of Communication and Follow-Up of Urgent and Unexpected Findings on Diagnostic Imaging Studies
Mittal, D.^{1}; Siegel, E.^{1,2} 1. University of Maryland School of Medicine, Baltimore, MD; 2. Baltimore VA Medical Center, Baltimore, MD*

006. Do Patients Get Follow-Up Studies on Schedule? Analysis of the Follow-Up Timeline for Pulmonary Nodules Using PRESTO
Cook, T.; Itri, J.; Boonn, W.; Kim, W. Hospital of the University of Pennsylvania, Philadelphia, PA*

007. Patient Management-Changing Errors in Recall of Radiologic Results
Yerubandi, V.; Brus-Ramer, M.; Newhouse, J. Columbia University, New York, NY*

008. Assessment of Integrated PET/CT and Diagnostic CT Structured Report for Oncologic Patients
Gandhi, N.; Shah, S.; Raghavan, D.; Pohlman, B.; Obuchowski, N.; Herts, B. Cleveland Clinic Foundation, Cleveland, OH*

* Presenting Author



9:30 am-10:30 am

CALDWELL LECTURE

Benjamin Chu, MD, MPH, President, Kaiser Permanente Southern California Region

Douglas B, Lobby Level



Dr. Benjamin K. Chu has been the regional president of Kaiser Permanente Southern California since 2005. He directs health plan and hospital operations for 13 hospitals and 130 medical offices in an area that ranges from Bakersfield to San Diego to serve more than 3.2 million members. A primary care Internist by training, Dr. Chu possesses extensive health care Experience as a clinician, administrator, and policy advocated. He has a strong Interest

in and supports the use of the electronic health record as a powerful tool for improving quality and outcomes for patient care.

Early in his career, Dr. Chu became absorbed With trying to understand the health care delivery system in the United States. His Experiences and work have focused on efforts to mold and change the system to encompass vulnerable segments of the population not broadly cared for by the mainstream. His strength has not been in the pursuit of an academic approach to these problems but rather in his ability to balance complex Interests and issues in an attempt to forge practical approaches to improving the system.

Before joining Kaiser Permanente, Dr. Chu served for three years as president of New York City's Health and Hospitals Corporation (HHC), the largest public hospital system in the country. He served as senior vice president for medical and professional affairs at HHC from 1990 to 1994. During that time, he also served as acting Commissioner of Health for the New York City Department of Health.

Dr. Chu also has extensive experience working in academics. He served as senior associate dean at Columbia University College of Physicians and Surgeons and served at the New York University School of Medicine and Medical Center in a variety of leadership roles.

In addition, he was also a Robert Wood Johnson Policy Fellow and a past health policy legislative assistant for former New Jersey Senator Bill Bradley.

In 1974, Dr. Chu received his bachelor's degree in psychology from Yale University and in 1978 received his medical degree from New York University. He earned his master's of public health from Columbia University in 1989.

MONDAY SCHEDULE



10:30 am-12:00 noon

IC106. Breast Nuclear Medicine: PEM and PET—*D. Mankoff, G. Mercier*
Douglas A, Lobby Level

IC107. Cardiac CTA: Anatomy—*S. Patel*; Anomalies, Bypass Grafts and Stents—*G. Reddy*; Clinical Cases: Tips and Tricks—*S. Teague*
Douglas C, Lobby Level

IC108. PET/CT in Head and Neck Cancer—*R. Subramaniam, E. Rohren*
Douglas B, Lobby Level

IC109. ABR Update—*G. Becker, J. Crowe, N.R. Dunnick, E. Kazerooni*
Elizabeth H, Second Level

IC110. Pulmonary Interventions: AVMs and Bronchial Artery Embolization; Diagnosis—*A. Funaki*; Pulmonary Embolization—*C. Burke*; Bronchial Embolization—*B. Funaki*
Elizabeth G, Second Level

SS2. Efficacy, Education and PACS: Policy and Operations—Moderators: *E. Fraile-Moreno, B. Richmond*; Keynote: Informatics for Operational Efficiency 2.0—*D. Channin*
Randle A, Fourth Level

009. The Misleading Impression Created by the 2008 Government Accountability office (GAO) Report on the Effects of the Deficit Reduction Act (DRA) on Utilization of Outpatient Imaging
Levin, D.; Rao, V.; Parker, L.; Frangos, A. Thomas Jefferson University Hospital, Philadelphia, PA*

010. Quality Control Checking of Pediatric CT Scans by a Radiologist: Is it Necessary Before the Patient Leaves the Scanner?
Podberesky, D.; Fadell, M.; Salisbury, S.; Larson, D. Cincinnati Children's Hospital Medical Center, Cincinnati, OH*

011. Do Digital Pictures Add to the Interpretation of Diagnostic Imaging: A Survey Along the Spectrum of Experience
Weiss, F.; Safdar, N. University of Maryland Medical Center, Baltimore, MD*

012. Pain in the Neck: Evaluation of Work Habits, Workstation Ergonomics, and their Influence on Radiologists' Symptoms
Prabhakar, A.; Saksena, M.; Hahn, P.; Mueller, P.; Harisinghani, M. Massachusetts General Hospital, Boston, MA*

013. A Neural Network to Expedite and Standardize Editorial Review of AJR Manuscripts
Lee, S.; Hahn, P.; Scott, J. Massachusetts General Hospital, Boston, MA*

014. Construction of a Model to Assess the Financial Impact of Voice Recognition in a Diagnostic Radiology Department
Berlin, J.; Hawes, H.; Zawodniak, A. NorthShore University Health System, Evanston, IL*

015. New Software Models for Next Generation PACS Workstations
Laks, M. Albert Einstein Medical School-Montefiore Medical Center, Flushing, NY*

016. Verification Bias: An Under-Recognized Source of Error in Assessing the Efficacy of Medical Imaging
Petscavage, J.; Richardson, M. University of Washington, Seattle, WA*

1:00 pm-2:30 pm

IC111. Cardiac CTA: Assessment of Noncoronary Cardiac Disease—*G. Gladish*; Adult Congenital Heart Disease—*R. Gilkeson*; Chest Pain in the Emergency Department—*C. White*
Douglas C, Lobby Level

IC112. Optimizing PET/CT Imaging Protocols, PET/CT for Breast Cancer and Dementia—*T. Wong, E. Akin, A. Siegel*
Elizabeth H, Second Level

IC113. Overutilization—*J. Thrall, P. Basu*
Elizabeth G, Second Level

1:00 pm-3:00 pm

SS3. Breast Imaging: MRI—Moderators: *D. Rausch, L. Salkowski*; Keynote: Breast MRI Controversies—*D. Ikeda*
Douglas B, Lobby Level

017. Incidental Pleural Effusions on Screening Breast MRI
Nguyen, J.; Harvey, J. University of Virginia Health System, Charlottesville, VA*

018. Indeterminate Breast Lesions Detected on MR Imaging in Women With a High Risk of Breast Cancer: Value of Short-Term Follow-up for Diagnosis
Korzeniowski, M.; Figueira, K.; Phang, S.; Minuk, T.; Dhamanaskar, K. McMaster University, Hamilton, Canada*

019. Role of MRI in the Planning of Breast Conservation Surgery in Patients With Paget Disease of the Nipple
Dominelli, V.; Pediconi, F.; Luciani, M.; Telesca, M.; Vasselli, F.; Casali, V.; Catalano, C.; Passariello, R. University of Rome "La Sapienza", Rome, Italy*

020. Retrospective Analysis of Post-Surgical Changes Seen on Breast MRI
Ojeda-Fournier, H.; Aiken, M.; Brogoch, L. University of California San Diego, San Diego, CA*

021. Breast Biopsy Markers—Conventional Versus Carbon Coated, Affect on MR Susceptibility Artifact and Local Signal Disturbance
Ghate, S.; Hawkins, A.; Baker, J.; Soher, B. Duke University Medical Center, Durham, NC*

022. Effectiveness of Morphology Assessment Using a CAD System for Detection of Infiltrating Lobular Carcinoma at Dynamic Contrast-Enhanced MRI
Penn, A.; Thompson, S.²; Jansen, S.³; Newstead, G.³ 1. Alan Penn & Associates, Inc., Rockville, MD; 2. Invivo Corp, Gainesville, FL; 3. University of Chicago, Chicago, IL*

023. Does Breast Density Have an Impact on the Indications for MRI?
Luciani, M.; Pediconi, F.; Dominelli, V.; Telesca, M.; Vasselli, F.; Casali, V.; Catalano, C.; Passariello, R. University of Rome "La Sapienza", Rome, Italy*

024. Should Routine Breast Cancer Staging Include MRI?
Pediconi, F.; Dominelli, V.; Luciani, M.; Telesca, M.; Vasselli, F.; Casali, V.; Catalano, C.; Passariello, R. University of Rome "La Sapienza", Rome, Italy*

MONDAY SCHEDULE



025. Preoperative MRI of the Breast: Does It Affect Local Recurrence Rates? *Dominelli, V.*; Pediconi, F.; Luciani, M.; Telesca, M.; Casali, V.; Vasselli, F.; Catalano, C.; Passariello, R. University of Rome "La Sapienza", Rome, Italy*

026. SER Volume Predicts Malignancy in MRI-Detected Breast Lesions Occult to Mammography and Palpation
Arasu, V.; Chen, R.; Newitt, D.; Chang, B.; Tso, H.; Hylton, N.; Joe, B. University of California, San Francisco, San Francisco, CA*

1:00 pm-3:00 pm

SS4. Gastrointestinal Imaging: CT Radiation Dose—Moderators:
F. Coakley, R. Mezzrich; Keynote: CT Radiation Risk: A Phantom Menace—R. Mezzrich; CT Radiation Risk: A Clear and Present Danger—F. Coakley

Douglas A, Lobby Level

027. Age and Sex Specific Radiation Risks at Abdominal CT
Koonce, J.; Hardie, A.; Moore, B.; Tipnis, S.; Huda, W. MUSC, Charleston, SC*

028. How Does Patient Size Affect Radiation Doses at Abdominal CT With Automatic Exposure Control?
Koonce, J.; Hardie, A.; Moore, B.; Tipnis, S.; Huda, W. MUSC, Charleston, SC*

029. Comparison of Iterative and Filtered Back Projection Techniques for Abdominal CT: A Prospective Double Blinded Clinical Study
Singh, S.; Kalra, M.*; Hsieh, J.*; Doyle, M.*; Licato, P.*; Blake, M.* 1. Massachusetts General Hospital, Boston, MA; 2. GE Healthcare, Waukesha, WI*

030. Adaptive Statistical Iterative Reconstruction (ASIR) of Raw Chest, Abdomen and Pelvis CT Data Reduces Radiation Dose while Maintaining Image Quality
Kaplan, J.; Simpson, W.; Lee, K.; Tanenbaum, L. Mount Sinai Medical Center, New York, NY*

031. Effect of Different Percentages of Adaptive Statistical Iterative Reconstruction on the Image Quality of Low Dose 64 Slice Liver MDCT Exams
Mitsumori, L.; Kolokythas, O.; Koprowicz, K.; Alessio, A.; May, J.; Gunn, M.; Shuman, W. University of Washington, Seattle, WA*

032. Prospective Evaluation of Effect of 2D Adaptive Filters on Low Radiation Dose Chest and Abdominal CT
Singh, S.; Kalra, M.*; Sharma, A.*; Forsberg, A.*; Shepard, J.*; Digumarthy, S.* 1. Massachusetts General Hospital, Boston, MA; 2. Sharpview, Linköping, Sweden*

033. Low Dose Iodine Contrast Media Monitoring Scan for CT: Is it Reliable to Assess Hepatic Steatosis?
Husarik, D.; Boll, D.; Nelson, R.; Merkle, E. Duke University Medical Center, Durham, NC*

034. Logarithmic Pixel Transformation to Increase Contrast to Noise Ratios for Detection of Liver Lesions: Does it Work?
Grand, D.; Machan, J.; Beland, M.; Mayo-Smith, W. Warren Alpert School of Medicine, Brown University, Providence, RI*

035. Value of the Unenhanced and Delayed Series in MDCT of the Liver in Screening for Hepatocellular Carcinoma: Can One Series Be Eliminated to Reduce Dose?
Luke, F.; Jaffe, T.; Massey, C. Duke University Medical Center, Durham, NC*

1:00 pm-2:30 pm

SS5. Vascular and Interventional Radiology—Moderators:
M.G. Knuttinen; T. Carrillo; Keynote: Endovascular Management of Massive Pulmonary Embolism—C. Owens

Randle A, Fourth Level

036. To Evaluate the Diagnostic Quality of 64-Slice CT Angiography of the Pulmonary Arteries Using a Bolus-Chase Contrast Agent Injection Protocol for Ruling out Pulmonary Embolism
Douwes, D.; Vries, de, M.*; Schiereck, J.*; Graaf, de, R.*; Dannenberg, E.*; Wildberger, J.*; Lussanet, de, Q.* 1. Maastricht University Medical Center, Maastricht, Netherlands; 2. Erasmus Medical Center, Rotterdam, Netherlands; 3. Slingeland Ziekenhuis, Doetinchem, Netherlands; 4. Groene Hart Ziekenhuis, Gouda, Netherlands*

037. Detection of Reperfused Pulmonary Arteriovenous Malformations With Contrast-Enhanced MR Angiography
Schneider, G.; Massmann, A.*; Katoh, M.*; Geithoff, U.*; Buecker, A.* 1. Saarland University Hospital, Homburg, Germany; 2. Klinik der Stadt Koeln (HNO Klinik), Koeln, Germany*

038. Can CT Features Differentiate Between Inferior Vena Cava Leiomyosarcomas and Primary Retroperitoneal Masses?
Webb, E.; Wang, Z.; Westphalen, A.; Nakakura, E.; Coakley, F.; Yeh, B. University of California, San Francisco, San Francisco, CA*

039. Interventional Oncology Research: Slowing Growth, Limited Focus, and Inadequate Funding
Chow, D.; Itagaki, M. University of California, Los Angeles, Los Angeles, CA*

040. Catheter-Free Survival Following Primary Percutaneous Stenting of Malignant Bile Duct Obstruction
Frank, B.; Thornton, R.*; Covey, A.*; Maybody, M.*; Solomon, S.*; Getrajdman, G.*; Brown, K.* 1. Weill Cornell Medical School, New York, NY; 2. Memorial Sloan Kettering Cancer Center, New York, NY*

041. Refractory Ascites and TIPS With Covered Stents: A Single Center Experience
Christenson, B.; Ray, C.; Gupta, R.; Kondo, K.; Forman, L.; Durham, J. University of Colorado, Golden, CO*

042. Low kVp Contrast-Enhanced CT: Can Imaging Closer to the k-edge of Iodine Allow for a Reduction in Contrast Media?
Husarik, D.; Nelson, R.*; Weber, P.*; Howle, L.*; Nichols, E.*; Boll, D.*; Marin, D.* 1. Duke University Medical Center, Durham, NC; 2. Duke University, Durham, NC*

* Presenting Author

MONDAY SCHEDULE



2:30 pm-3:30 pm

SCHOLARS AND AWARDS SESSION

Elizabeth F, Second Level

Final Report of the 2008 ARRS Berlin Scholar in Medical Professionalism

Stephen D. Brown, MD

2010 ARRS Scholar

Karen Ordovas, MD

University of California San Francisco



Dr. Karen Ordovas received her MD from the Universidade Federal do Rio Grande do Sul in Brazil and completed her radiology residency training in Porto Alegre, Brazil, in 2001. After two years of private practice radiology in Brazil, Dr. Ordovas moved to the United States and completed her three-year research and clinical fellowship training in cardiothoracic radiology at the University of California San Francisco (UCSF). She has a special interest in advanced cardiothoracic imaging including MRI and coronary CTA.

Dr. Ordovas is currently an assistant professor of cardiothoracic radiology at UCSF where she is also chair of the cardiothoracic section research committee. As chair, she is involved in the mentoring of local and international fellows and residents in their research efforts.

The ARRS Scholarship Award will help Dr. Ordovas solidify her skills as a clinical researcher and engage in activities that will augment her knowledge and experience in several aspects necessary for a successful academic career. She will enroll in the UCSF Department of Epidemiology and Biostatistics master's degree program on clinical research, which will allow her to learn additional methods required to perform clinical research and improve her data analysis, interpretation, and presentation skills. Her long-term career goal is to become a national leader in cardiothoracic imaging by continuing her research using state of the art imaging methods for understanding and diagnosing cardiovascular disease.

Her current research project aims to determine the accuracy of coronary CTA for measuring severity of wall thickening and luminal loss in coronary allograft vasculopathy. If demonstrated to be accurate, CTA could be used to detect early disease in transplant patients. It is an attractive noninvasive, safer, and less expensive alternative to conventional coronary angiography for long-term surveillance and could be used for monitoring coronary allograft vasculopathy severity and response to treatment. In addition, this study could provide further knowledge in the ability of coronary CTA to identify coronary wall thickening which could be an important predictor for cardiac disease in multiple clinical scenarios.

Dr. Ordovas is a member of several professional organizations including the ARRS, where she serves on the Maintenance of Certification Subcommittee; the Society for Cardiovascular Magnetic Resonance, where she serves on the program committee; the Radiological Society of North America (RSNA), where she serves on both the meeting abstract committee

on cardiac imaging and the radiographics panel on cardiac imaging; and the North American Society for Cardiac Imaging, where she serves on the research committee.

In the past three years, Dr. Ordovas has published 15 peer-reviewed papers, and has presented 14 scientific abstracts at meetings of the ARRS, the RSNA, the Society of Cardiovascular Magnetic Resonance, and the American Heart Association. She received the RSNA R&E research fellow grant in 2006 for a project entitled "MRI Assessment of Right Ventricular Function After Repair of Tetralogy of Fallot." She also received a certificate of merit from the RSNA for her educational exhibit entitled "Tetralogy of Fallot: MRI Evaluation of Late Postoperative Complications" in 2005.

2010 ARRS Berlin Scholar in Medical Professionalism

Bruce J. Barron, MD, MHA, FACNM

Emory University



Dr. Bruce Barron received his MD from the University of South Florida College of Medicine in Tampa, FL, and completed his Internship and residency in pediatrics at Miami Children's Hospital in Miami, FL. He completed his residency in nuclear medicine at the George Washington University Medical Center in Washington, DC, in 1981, and attained his master's of health care administration (MHA) degree at Texas Women's University School of Healthcare Administration in Houston, TX, in 2000. He has a special interest in developing and promoting competency in medical professionalism.

Dr. Barron is currently a professor of radiology at the Emory University School of Medicine in Atlanta, GA; a visiting professor of radiology at the University of Texas-Houston; and an adjunct associate professor of radiology at the Baylor College of Medicine in Houston. Dr. Barron also works as a physician for the Emory University Hospital; the Department of Veterans Affairs Medical Center; Grady Memorial Hospital; and is the chief of the nuclear medicine department at Emory University Hospital Midtown.

The Berlin Scholarship Award will help Dr. Barron participate in a new master's program in bioethics at Emory University which will help him expand his knowledge of medical professionalism. The program deals with many of the current issues faced by ethics committees, physicians, and residents. Dr. Barron is interested in researching the actual and expected aspects of medical professionalism in various cultures and he has planned a project that focuses on changes in medical professionalism as a patient ages and approaches end-of-life situations. He will look at imaging and radiological therapy patterns in end-of-life situations and hopes to develop some guidelines to help radiologists face these issues.

Passionate about his career, Dr. Barron is a member of various professional organizations, including the American Roentgen Ray Society; the Radiological Society of North America; the Society of Nuclear Medicine, where he serves on the ethics committee; and the American College of Nuclear Medicine, where he is a fellow.

To his credit, Dr. Barron has had more than 30 articles published in various trade and medical publications. In addition, he has had five book chapters, and more than 80 abstracts published to date.

MONDAY SCHEDULE



2010 Melvin M. Figley Fellowship in Radiology Journalism

Manjiri K. Dighe, MD

University of Washington School of Medicine, Seattle, WA



Dr. Manjiri Dighe is an assistant professor in body imaging and director of ultrasound at the University of Washington School of Medicine in Seattle, WA. She received her MD from the University of Bombay in Mumbai, India, after completing her radiology residency in 2002. She completed a fellowship in body imaging at the University of Washington School of Medicine in 2004. Dr. Dighe will use the Figley fellowship to gain Insight Into the fundamentals

of medical journalism.

Jeffrey P. Kanne, MD

University of Wisconsin School of Medicine, Madison, WI



Dr. Jeffrey Kanne is associate professor and vice chair of quality and safety in the division of cardiothoracic imaging at the University of Wisconsin School of Medicine and Public Health in Madison, WI. He received his MD from the Emory School of Medicine in Atlanta, GA, and completed his radiology residency at the University of Washington in Seattle, WA, in 2005. He completed a fellowship in thoracic radiology at Vancouver General Hospital in

Vancouver, BC, in 2006. Dr. Kanne will use the Figley fellowship to further his skills as a medical writer and gain knowledge of and Insight Into the editorial process.

2010 Lee F. Rogers International Fellowship in Radiology Journalism

Arumugam Rajesh, FRCR

University Hospitals of Leicester, England



Dr. Arumugam Rajesh is a staff radiologist at the University Hospitals of Leicester in England where he completed his radiology residency in 2002. He completed a fellowship in abdominal imaging at Indiana University Medical Center in Indianapolis, IN. As part of the same program, he spent one month at the University of California San Francisco Medical Center learning MR spectroscopy. Dr. Rajesh will use the Rogers fellowship as an opportunity to enhance his publishing and editing skills.

Residents in Radiology President's Award

Andrew L. Rivard, MD, MS

University of Florida, Gainesville, FL



Coronary Artery Pediatric Heart Transplant Evaluation Using CT (CAPHTECT) Study

Objective: This study was initiated to assess whether coronary CTA is a clinically relevant noninvasive option to evaluate coronary artery disease in pediatric heart transplant patients.

Materials and Methods: Pediatric heart transplant patients had been clinically chosen for a coronary CTA based upon age and risk benefit factors versus conventional catheter coronary angiograms. Patient Information was retrospectively reviewed following IRB approval. All patients were imaged using a scanner following IV contrast administration. The images were processed on a workstation and graded for quality, contrast opacification, and coronary artery disease. Estimated effective radiation dose for each patient was calculated in mSv based upon height and weight. Standard transplant risk factors for coronary disease including rejection, number of donor to recipient HLA mismatches, graft ischemic time, and donor or recipient age were compared.

Results: Thirteen pediatric heart transplant patients underwent coronary CTA studies. The mean scan time and effective dose were 2.8 ± 1.5 sec. and 22.7 ± 9.3 mSv, respectively. Out of a four point scale, the scores for image quality and contrast opacification were 2.4 and 2.6. Six patients had positive studies for coronary artery disease; three with nonsignificant (<50% narrowing); and three with significant (>50%) disease. Coronary artery disease correlated to biopsy positive rejection ($p=0.05$) but not to mismatches, ischemic time, or age.

Conclusions: This is the first study to demonstrate that coronary artery disease correlates With prior rejection episodes and can be noninvasively detected in pediatric heart transplant patients using coronary CTA. Thus, first line surveillance of rejection in pediatric heart transplant recipients using coronary CTA should be considered prior to catheter based angiograms.

This award winning abstract will be presented as part of the pediatric imaging power hour on Wednesday, May 5 at 7:00 am-8:00 am.

MONDAY SCHEDULE

Residents in Radiology Executive Council Award

Matthew Scott Davenport, MD
University of Michigan, Ann Arbor, MI



Hyperglycemia in Hospitalized Patients Receiving Corticosteroid Premedication

Objective: To assess the effect of short-term corticosteroid premedication on serum glucose in hospitalized patients.

Material and Methods: Serum glucose in adult inpatients before and after corticosteroid premedication was compared to serum glucose

in non pre-medicated controls. Patients were placed into nine cohorts. Cohorts were defined by the use or non-use of intravascular nonionic contrast medium (IV or IA) and corticosteroid premedication (oral or IV). Patients were further subdivided by the presence or absence of diabetes mellitus (type I or type II). Results were analyzed with ANOVA and a stepwise linear regression analysis.

Results: There were 426 corticosteroid premedication episodes in 426 patients; 877 examinations in 848 patients served as controls. Cohorts receiving corticosteroid premedication experienced a brief (24-48 hours) increase in mean maximum post-baseline serum glucose (IV, +80 mg/dl; oral, +69 mg/dl) that was greater than the increase in non pre-medicated controls (+46 mg/dl). Type I (+144 mg/dl) and type II (+109 mg/dl) diabetics had a greater elevation than non-diabetics (+34 mg/dl). Both corticosteroid premedication (IV, $p=0.02$; oral, $p=0.01$) and diabetes mellitus (type I, $p=0.0002$; type II, $p<0.0001$) were significant independent risk factors of hyperglycemia. The use of nonionic intravascular contrast medium was not ($p=0.7$). There was no significant difference between IV and oral premedication ($p=0.6$), or type I and type II diabetes mellitus ($p=0.8$).

Conclusions: Diabetes mellitus (type I and type II) and corticosteroid premedication (oral and IV) are significant independent risk factors for the development of brief hyperglycemia near the time of inpatient radiology studies.

This award winning abstract will be presented as part of the general/emergency power hour on Thursday, May 6 at 7:00 am-8:00 am.

Residents in Radiology Executive Council Award

Jeffrey Parke Otjen, MD
University of Washington, Seattle, WA



Clinical Radiology Practice Quality Improvement: Can We Eliminate the Routine Chest Radiograph for Mechanically Ventilated Patients?

Objective: Routine daily chest radiographs are often obtained for mechanically ventilated patients. There are conflicting data in the literature regarding the utility of this practice. Combining a clinician survey with radiology

findings, we examined the utility of this practice.

Materials and Methods: Patients in a university affiliated level 1 trauma center were identified by review of electronic medical records, from surgical and medical intensive care units. Radiograph reports were categorized into three groups – no significant new findings, minor new findings, or major new findings. Scoring was performed by two radiology residents. To better determine their clinical significance, a survey was devised using the report analysis, and was given to intensive care unit clinicians.

Results: 4070 studies for 562 patients were evaluated. 83%, 16%, and 1% were placed in the no new finding, minor new finding, and major new finding groups, respectively. Based on the survey, some findings were universally regarded as valuable, though many findings found valuable by some clinicians had little value to others. Approximately 50% stated a “no change” radiograph was valuable, yet this would change management for less than 2%. Integrating the results of the clinician survey with the report analysis data clarified which findings were truly significant. Combining data showed that for most clinicians, more than 95% of studies would not alter management.

Conclusions: As defined by the potential to alter management, these studies are of low utility. However there are other difficult to quantify measurements of utility and these will continue to fuel future debate.

This award winning abstract will be presented as part of the cardiopulmonary power hour on Wednesday, May 5 at 7:00 am-8:00 am.

MONDAY SCHEDULE



4:00 pm-5:30 pm

IC114. Pancreatic Imaging: Practical Approach to the Cystic Lesion—
K. Mortelet; Pitfalls in Pancreatic Imaging—M. Federle; Solid Pancreatic Neoplasms—D. Morgan

Douglas C, Lobby Level

IC115. Basic Screening Principles—*D. Georgian-Smith; Controversies on High Risk Lesions at Core Biopsy: Radiology and Pathology Perspectives—T. Lawton*

Elizabeth H, Second Level

IC116. Cardiac MRI: The Basics—*M. Atalay; Cardiomyopathies and Dysplasias—J. Jeudy; Ischemic Heart Disease: Perfusion, Function, Viability—M. Krishnam*

Douglas B, Lobby Level

IC117. Interventional Radiology for the Diagnostic Radiologist—*C. Ray, A. Nemcek, K. Kondo*

Elizabeth G, Second Level

4:00 pm-6:00 pm

SS6. Musculoskeletal Imaging: Upper and Lower Extremity: Diagnostic Advances—Moderators: *C. Roberts, T. Pope; Keynote: Total Knee Arthroplasty Component Rotation: Importance and Easy Technique for Measurement—C. Roberts*

Douglas A, Lobby Level

043. Shoulder Glenoid "Dysplasia": Is Glenoid Morphology Related to Weightlifting at an Early Age?
Delpont, A.; Morrison, W.; Zoga, A. Thomas Jefferson University Hospital, Philadelphia, PA*

044. Prevalence of Glenoid Paralabral Cysts and Their Association With Labral Tears
Dobre, C.; Ziegelbein, J.; Bennett, D.; Ahn, J. University of Iowa Hospitals and Clinics, Iowa City, IA*

045. Cysts Within and Adjacent to the Lesser Tuberosity: Correlation With Shoulder Arthroscopy
Wissman, R.; Hendry, D.; Gorman, D.; Kapur, S.; Ingalls, J.; Ying, J.; Kenter, K. University of Cincinnati, West Chester, OH*

046. Revisiting Erosive Osteoarthritis—A Radiographic Review of 69 Patients
Bricker, K.; Sykes, J.; Singh, D.; Anandarajah, A.; Seo, G.; Monu, J. University of Rochester, Rochester, NY*

047. "Bone Marrow Edema" of the Femoral Head in Hip Osteoarthritis: MR Imaging Findings With Histological Correlation
Le Corroller, T.; Leydet-Quilici, H.; Bouvier, C.; Pham, T.; Argenson, J.; Lafforgue, P.; Champsaur, P. Hôpital Sainte Marguerite, Marseille, France*

048. MR Arthrographic Appearance of the Ligamentum Teres: Variations of Normal and Patterns of Injury
Sadej, P.; Zoga, A.; Morrison, W. Thomas Jefferson University Hospital, Philadelphia, PA*

049. Maturation of Bioabsorbable Interference Screw Fixation of Anterior Cruciate Ligament Grafts as Evaluated by MRI
Umans, H.; Park, B.*; Bakhr, P.*; DiFelice, G.* 1. Jacobi Medical Center, Bronx, NY; 2. Albert Einstein College of Medicine, Bronx, NY*

050. Wrisberg Variant of the Discoid Lateral Meniscus Presenting as Bucket-Handle Tear: MRI and Arthroscopic Correlation
Yue, B.; Gupta, A.; Garrett, W.; Helms, C. Duke University Medical Center, Durham, NC*

051. The Diaphyseal Adult Femoral "Torus" Fracture - DAFT From Focal Flare to Frank Fracture Non-Traumatic Lateral Cortical Diaphyseal Femoral Fracture
Feldman, F. Columbia Presbyterian Medical Center, Bronx, NY*

052. The Spring Recess of the Anterior Subtalar Joint: Depiction on MR Images With Cadaveric Correlation
Desai, K.; Beltran, L.*; Bencardino, J.*; Sadka Rosenberg, Z.*; Petchprapa, C.* 1. Mount Sinai School of Medicine, New York, NY; 2. NYU Hospital for Joint Diseases, New York, NY*

053. Predictive Value of Knee Symptoms Identified on Patient Questionnaire for MRI Findings of Knee Pathology
Mathews, J.; Utz, M.; Zoga, A.; Sadej, P.; Morrison, W. Thomas Jefferson University Hospital, Philadelphia, PA*

4:00 pm-6:00 pm

SS7. Nuclear Medicine—Moderators: *D. Yoo, T. Wong; Keynote: PET Response Criteria in Solid Tumors (PERCIST 1.0)—H. Jacene*

Randle A, Fourth Level

054. Impact of Image Reconstruction Parameters on SUV in FDG-PET
Adams, M.; Wong, T.; Wilson, J.; Turkington, T. Duke University, Durham, NC*

055. Semiquantitative Analysis of Maximum Standardized Uptake Values of Regional Lymph Nodes in Inflammatory Breast Cancer Patients: Is There a Reliable Threshold for Differentiating Benign from Malignant?
Carkaci, S.; Adrada, B.; Rohren, E.; Wei, W.; Quraishi, M.; Mawlawi, O.; Buchholz, T.; Yang, W. MDACC, Houston, TX*

056. Brown Fat on PET/CT: Correlation With Patient Characteristics
Cronin, C.; Prakash, P.; Daniels, G.; Kalra, M.; Palmer, E.; Blake, M. Massachusetts General Hospital, Boston, MA*

057. Systematic Review of Brown Adipose Tissue Uptake in Pediatric FDG PET/CT
Chien, D.; Cho, S. Johns Hopkins Medical Institute, Baltimore, MD*

058. Correlation of Estrogen, Progesterone and Her2neu Receptor Status and 18-Fluorodeoxyglucose in Positron Emission Mammography
Wang, C.; MacDonald, L.*; Rogers, J.*; Haseley, D.*; Beatty, D.* 1. University of Washington, Seattle, WA; 2. No Institutional Affiliation*

059. Optical Imaging of Neural Progenitor Cell Homing to Patient-Derived Chronic Myelogenous Leukemia
Newton, I.; Messina-Graham, S.; Shih, A.; Abrahamsson-Schairer, A.; Jamieson, C.; Mattrey, R. UCSD, San Diego, CA*

060. The Impact of FDG PET/CT in the Management of the Unknown SCC Primary in the Head and Neck: Results of a Prospective Trial
Nasoodi, A.; McCaul, D.; Fahy, C.; Primrose, W.; Ullah, R.; Hughes, S. Royal Victoria Hospital, Belfast, United Kingdom*

061. The Diagnostic Correlation of the Pattern of Sulcal Atrophy With the Pattern of Metabolism on PET/CT Imaging
Wilner, A.; Birnie, K.; Lu, S. Monmouth Medical Center, Long Branch, NJ*

062. Changes in Patient Selection Greatly Alter Helpfulness of the 99m-Tc Sestamibi Parathyroid Scan in Clinical Practice
Rodgers, B.; Blank, B.; Kandil, E.; Palacios, E.; Friedlander, P. Tulane University, New Orleans, LA*

TUESDAY, MAY 4



6:00 am–6:00 pm
Speaker Preview Room

Molly A/B, Second Level

6:30 am–4:30 pm
Registration

Elizabeth Foyer, Second Level

7:00 am–12:00 noon
Categorical Course on Efficient Imaging
There is an additional fee to attend this course.

Manchester Ballroom, Second Level

7:00 am–12:00 midnight
Electronic Exhibits

Randle D/E, Fourth Level

8:00 am–9:30 am
As part of ARRS' Global Exchange with South Korea, we are honored to have Dr. Joon Koo Han participate in IC201 as follows:
IC201. Navigating CT and MRI of the Liver: MRI Technique and Diffuse Liver Disease—*J. Leyendecker*; Hepatocellular Disease—*T. Desser*; Cholangiocarcinoma—*J.K. Han*

Douglas C, Lobby Level

9:30 am–10:30 am
Coffee Break in the Exhibit Hall

Elizabeth Ballroom, Second Level

12:00 noon–1:00 pm
Lunch in the Exhibit Hall

Elizabeth Ballroom, Second Level

1:00 pm–6:30 pm
Case-Based Imaging Review Course
There is an additional fee to attend this course.

Manchester Ballroom, Second Level

3:00 pm–4:00 pm
Soda Break in the Exhibit Hall

Elizabeth Ballroom, Second Level

*CC=Categorical Course
IC=Instructional Course
SS=Scientific Session*

CORPORATE SPONSORED ACTIVITY

7:00 am–8:00 am
New Advances in CT Radiation Dose Reduction—*William Shuman, MD*
Sponsored by GE Healthcare
(Breakfast will be available for the first 130 attendees)

Douglas D, Lobby Level



Will I be an artist?



Will I be a doctor?



Will I live to be 100?

By integrating imaging, lab diagnostics, and healthcare IT, we can advance the science of medicine to add years to life, and life to years.

Imagine a healthcare system that keeps us healthier by detecting disease earlier. Quality of life increases and costs are better controlled. Genomics and the integration of molecular diagnostics, advanced imaging, and healthcare IT open up new possibilities for a lifetime of care. Together, we can deliver on the promise of personalized medicine.
www.usa.siemens.com/integrated-healthcare 1-888-826-9702

Answers for life.

SIEMENS

TUESDAY SCHEDULE



7:00 am–8:00 am

Power Hour: Abdominal Imaging—*A. Qayyum, moderator*

Randle B, Fourth Level

- E239. Laparoscopic Port Complications: Cruising Issues; An Imaging Perspective!—*C. Lall*
- E243. Twists and Turns in the Abdomen: A Pictorial Review of Solid Organ, Hollow Viscus, and Abdominal Fat Torsions With Pathologic Correlation—*R. Jesinger*
- E244. Guide to Hollow Viscous Surgical Procedures—*A. Roberts*
- E259. Save the Liver Transplant: A Radiology Resident's On-Call Guide—*D. Rausch*
- E267. Hepatocyte-Specific MR Contrast Agent: Improved Lesion Characterization With Gd-EOB-DTPA—*A. Purysko*
- E276. Parasitic Disease of the Liver: A Review of the Spectrum of Disease and Appearance—*J. Shriki*
- E318. MRI and the Pregnant Patient: A Complete Guide to Evaluating the Pregnant Patient Presenting With Clinically Suspected Appendicitis—*S. Palmer*
- E352. MR Imaging of Pelvic Floor Dysfunction: A Practical Diagnostic Approach—*R. Ram*

7:00 am–8:00 am

Power Hour: Vascular and Interventional Radiology—*A. Nemcek, moderator*

Randle A, Fourth Level

- E655. Estimated Effective Dose of CT-Guided Thoracic Procedures—*G. Foltz*
- E656. Incidence and Clinical Outcome of Acute Ischemic Cholecystitis After Transarterial Chemoembolization (TACE) of Hepatocellular Carcinoma—*U. Wagnetz*
- E663. Fluoroscopic Guided Removal of Renal Transplant Ureteral Stents: Technique of Choice—*S. Shamimi-Noori*
- E669. Solid Visceral Injuries: Imaging and Intervention—*B. Kapoor*
- E676. Pulmonary Arteriovenous Malformations: Imaging and Intervention—*B. Kapoor*
- E694. Transhepatic and Translumbar Central Venous Catheters. A Reappraisal—*J. Tisnado*
- E695. The Role of Interventional Radiology in Venous Blood Sampling Revisited—*J. Tisnado*

7:00 am–12:00 noon

Categorical Course: Practical Approaches to Common Clinical Conditions: Efficient Imaging (PAC³E)—*Setting the PAC³E of Imaging*

Manchester Ballroom, Second Level

- 7:00 am–7:30 am
Imaging in Nonaccidental Pediatric Trauma: CNS Injury—*Y. Sato*
- 7:30 am–8:00 am
Imaging of Child Abuse: Non-CNS Injury—*K. Applegate*
- 8:00 am–8:40 am
Imaging of the Pediatric Abdomen: Pyloric Stenosis and Malrotation—*M. Hernanz Schulman*
- 8:40 am–9:20 am
Imaging of the Pediatric Abdomen: Appendicitis/Intussusception—*K. Applegate*

9:20 am–10:00 am

Imaging of the Pediatric Abdomen: Abdominal Neoplasms—*M. Siegel*

10:30 am–11:00 am

Where the Rubber Meets the Road: IT in Critical Results Reporting—The Challenges and the Promises Where We Are Now and Where We Are Going—*J. Chen*

11:00 am–11:30 am

Where the Rubber Meets the Road: Evidence-Based Medicine and the Courts—*A. Relyea-Chew*

11:30 am–12:00 noon

Where the Rubber Meets the Road: Evidence-Based Medicine and Economics/Regulations—*D. Larson*

8:00 am–9:30 am

IC201. Navigating CT and MRI of the Liver: MRI Technique and Diffuse Liver Disease—*J. Leyendecker*; Hepatocellular Tumors—*T. Desser*; Cholangiocarcinoma—*J.K. Han*

Douglas C, Lobby Level

IC202. Basic Principles of Breast Imaging: The Risks of Breast Density Challenging Cases: An Interactive Review—*J. Harvey, L. Bassett*

Douglas B, Lobby Level

IC203. Rotator Cuff of the Shoulder: Why, How and Where It Fails—*D. Resnick*

Douglas A, Lobby Level

IC204. State of the Art Imaging of the Temporal Bone: Pre- and Postoperative Evaluation—*R. Harnsberger, T. Larson*

Elizabeth H, Second Level

IC205. Nuclear Medicine Therapies for Cancer: Radioimmunotherapy, Microspheres Therapy and Radioiodine Therapy—*A. Sheikh, H. Jacene, S. Goetze*

Elizabeth F, Second Level

10:00 am–11:30 am

IC206. Lateral Elbow Injuries: MRI—*Z.S. Rosenberg*; Ligament and Other Tendon Injuries of the Elbow: MRI—*V. Khoury*; Ultrasound Evaluation—*J. Jacobson*

Douglas C, Lobby Level

IC207. Differential Diagnosis of Basal Ganglia Lesions—*M. Castillo, Z. Rumbolt*

Douglas A, Lobby Level

10:00 am–12:00 noon

SS8. Breast Imaging: Novel Techniques—Moderators: *J. Leung, A. Nees*; Keynote: Advances in Multimodal Breast Imaging—*G. Newstead*

Elizabeth G, Second Level

063. Ductal Carcinoma in Situ (DCIS): Detection Sensitivity and Apparent Diffusion Coefficient Measures on Diffusion-Weighted MRI of the Breast *Rahbar, H.^{1,2*}; Partridge, S.^{1,2}; Eby, P.^{1,2}; DeMartini, W.^{1,2}; Gutierrez, R.^{1,2}; Peacock, S.^{1,2}; Lehman, C.^{1,2} 1. University of Washington, Seattle, WA; 2. Seattle Cancer Care Alliance, Seattle, WA*

064. Characterization and Evaluation of DCIS Early Phase Contrast Uptake With High Temporal and Spatial Resolution MRI *Fan, X.*; Jansen, S.; Medved, M.; Abe, H.; Shimauchi, A.; Olopade, O.; Karczmar, G.; Newstead, G. The University of Chicago, Chicago, IL*

TUESDAY SCHEDULE



065. MRI Detection of Small Calcium Crystals in Air Bubble-Free Phantoms: Potential Applications to Imaging Microcalcifications in Breast Cancer
Mustafi, D.; Peng, B.; Foxley, S.; Palgen, J.; Holmes, R.; Hipp, E.; Newstead, G.; Karczmar, G. The University of Chicago, Chicago, IL*

066. Pre-Contrast High Spectral and Spatial (HiSS) MRI for Classification of Benign and Malignant Breast Lesions: A Reader Study
Medved, M.; Fan, X.¹; Newstead, G.¹; Fischer, S.²; Ivancevic, M.²; Olopade, O.¹; Karczmar, G.¹ 1. University of Chicago, Chicago, IL; 2. Philips Healthcare, Cleveland, OH*

067. Elastography's Role in Predicting Benign from Malignant Breast Lesions
Proscia, N.; Baker, J.; Ghatge, S.; Stinnett, S. Duke University Medical Center, Chapel Hill, NC*

068. Detection and Classification of Calcification on Digital Breast Tomosynthesis and 2D Digital Mammography: A Comparison
Spangler, M.; Zuley, M.; Sumkin, J.; Abrams, G.; Ganott, M.; Hakim, C.; Perrin, R.; Shah, R. University of Pittsburgh Medical Center, Pittsburgh, PA*

069. Monitor Zooming and Detection of Microcalcifications on Digital Screening Mammograms
Haygood, T.¹; Arribas, E.¹; Liu, Q.¹; Brennan, P.²; Santiago, L.¹; Carkaci, S.¹; Lane, D.¹; Whitman, G.^{1} 1. MD Anderson Cancer Center, Houston, TX; 2. University of Sydney, Sydney, Australia*

070. Can Smaller Pixel Size and Use of Digital Phase Contrast Mammography (PCM) Improve Observer Performance in Diagnostic Mammography?
Schmidt, R.; Nishikawa, R.; Shimauchi, A.; Newstead, G.; Karkani, K.; Edwards, A.; Papaioannou, J.; Makin, S. The University of Chicago, Chicago, IL*

071. Multimodality Breast Lesion Localization: Mathematical Relationships With Respect to Breast Size and Tissue Compliance
Popuri, D.; Konda, S.; Mendelson, E. Northwestern University, Chicago, IL*

072. Imaging Appearance of Human Acellular Tissue (AlloDerm) After Breast Reconstruction
Ojeda-Fournier, H.; Tran Cao, H.; Tokin, C.; Konop, J.; Chao, J.; Blair, S. University of California San Diego, San Diego, CA*

10:00 am-12:00 noon

SS9. Cardiopulmonary Imaging—Moderators: S. Patel, M. Atalay; Keynote: Late Gadolinium Enhanced Cardiac MRI—M. Atalay

Elizabeth H, Second Level

073. Accuracy of Cardiac MRI in Diagnosing Constrictive Pericarditis Using Diastolic Filling Fraction
Ghadimi Mahani, M.^{1}; Knollmann, F.²; Agarwal, P.¹ 1. University of Michigan Health Center, Ann Arbor, MI; 2. University of Pittsburgh Medical Center, Pittsburgh, PA*

074. Contrast Volumes for Short Duration Cardiovascular MDCT: How Much Do We Need?
Numburi, U.^{1,2}; Halliburton, S.^{1,2} 1. Cleveland Clinic, Cleveland, OH; 2. Cleveland State University, Cleveland, OH*

075. Initial Evaluation of 256-Slice Cardiac CTA for Acute Chest Pain in the Emergency Department
Lu, M.; Chen, J.; Judy, J.; White, C. University of Maryland, Baltimore, MD*

076. Cardiac CTA Interpretation: Radiology Resident Versus Senior Cardiac Imaging Radiologist
Khashper, A.; Gaspar, T.; Peled, N. Carmel Medical Center, Haifa, Israel*

077. Cardiac CT for Diagnosis and Characterization of Mitral Valve Prolapse
Morris, M.; Young, P.; Suri, R.; Martinez, M.; Williamson, E. Mayo Clinic, Rochester, MN*

078. Cardiac MRI of Acute Myocardial Infarction: What is the Ideal Dose of Gadobenate Dimeglumine to Depict Delayed Enhancement?
Carbone, I.; Francone, M.; Cannavale, G.; Bertaccini, L.; Cannata, D.; Ciolina, F.; Cannavale, A.; Passariello, R. Sapienza University of Rome, Rome, Italy*

079. Hypertrophic Cardiomyopathy: Usefulness of Cardiac MR for the Improvement of Sudden Cardiac Death Risk Stratification
Carbone, I.; Francone, M.; Cannavale, A.; Musumeci, B.; Bertaccini, L.; Cannavale, G.; Cannata, D.; Passariello, R. Sapienza University of Rome, Rome, Italy*

080. Characterization of Infiltrative Myocardial Diseases Using Cardiac Diffusion Weighted Imaging
Donepudi, S.; Pandey, T.; Shaikh, R.; Malak, S.; Lizotte, P.; Viswamitra, S.; Jambhekar, K. UAMS, Little Rock, AR*

081. Marginal Incremental Benefit of Late Gadolinium Enhancement Imaging by MRI in the Screening of Referrals for Arrhythmogenic Right Ventricular Cardiomyopathy
Paproski, J.; Nguyen, E.; Paul, N.; Crean, A. Toronto General Hospital, Toronto, Canada*

082. Cardiac MRI: Comparison of a 2-D Imaging Technique to a Conventional I-D Approach in LVOT Quantification
Weininger, M.; Sagmeister, F.; Weidemann, F.; Koestler, H.; Ritter, C.; Hahn, D.; Beer, M. University Hospital of Wuerzburg, Wuerzburg, Germany*

10:00 am-12:00 noon

SS10. Gastrointestinal Imaging: Liver—Moderators: A. Qayyum, K. Sandrasegaran; Keynote: State-of-the-Art Imaging of Diffuse Liver Disease—A. Qayyum

Douglas B, Lobby Level

083. Detection of Liver Fibrosis: Comparison of MR Elastography and Diffusion Weighted MRI
Venkatesh, S.^{1}; Teo, L.¹; Ang, B.¹; Ehman, R.² 1. National University Health System, Singapore, Singapore; 2. Mayo Clinic, Rochester, MN*

TUESDAY SCHEDULE



084. Influence of Intravenous Gadolinium on Estimation of Liver Stiffness With MR Elastography for Evaluation of Liver Fibrosis
Venkatesh, S.^{1}; Teo, L.¹; Ang, B.¹; Lim, S.¹; Wee, A.¹; Ehman, R.²* 1. National University Health System, Singapore, Singapore; 2. Mayo Clinic, Rochester, MN

085. Contrast-Enhanced CT Quantification of the Fractional Extracellular Space Volume Correlates With Diffuse Liver Disease Severity
Zissen, M.^{1}; Aslam, R.¹; Wang, Z.²; Yee, J.¹; Monto, A.¹; Yeh, B.^{1,2}* 1. San Francisco VAMC, San Francisco, CA; 2. UCSF, San Francisco, CA

086. Gd-EOB-DTPA Enhanced Hepatic MRI: Dose-Dependent Contrast-Dynamics of Hepatic Parenchyma and Portal Vein
Feuerlein, S.^{1}; Boll, D.²; Gupta, R.²; Marin, D.²; Merkle, E.²* 1. University of Ulm, Ulm, Germany; 2. Duke University, Durham, NC

087. Gadobenate Dimeglumine-Enhanced Liver MRI: Value of Dynamic and Delayed Imaging for Evaluation of Hepatocellular Carcinoma Tumor Response Following Transarterial Chemoembolization
Chu, L.; Bonekamp, S.; Jolepalem, P.; Mensa, M.; Geschwind, J.; Kamel, I.* Johns Hopkins University, Baltimore, MD

088. What Defines Hepatic "Washout" in Triphasic MDCT?
Liu, Y.; Shin, L.; Jeffrey, R.; Kamaya, A.* Stanford University, Los Altos, CA

089. Hepatic Hemangioma: Enhancement Pattern at Gadobenate Dimeglumine and Gadoxetate Disodium-Enhanced 3T MRI
Marin, D.¹; Gupta, R.^{1}; Boll, D.¹; Feuerlein, S.²; Husarik, D.¹; Merkle, E.¹* 1. Duke University Medical Center, Durham, NC; 2. University of Ulm, Ulm, Germany

090. Categorization of Liver Lesions for Screening of Hepatocellular Carcinoma (HCC): MRI With Pathologic Correlation
Wable, S.; Weinstein, J.; Chen, M.* Albert Einstein Medical Center, Philadelphia, PA

091. Hepatocellular Carcinoma (HCC) With Indeterminate Findings at Initial CT or MRI: Does Imaging Follow-Up Allow Detection of Conclusive Imaging Findings Before Significant Tumor Growth?
Furlan, A.¹; Agnello, F.^{2}; Marin, D.³; Midiri, M.²; Lagalla, R.²; Brancatelli, G.²* 1. Pittsburgh Medical Center, Pittsburgh, PA; 2. Università di Palermo, Palermo, Italy; 3. Università di Roma la Sapienza, Rome, Italy

092. New Noninvasive Ultrasound Techniques: Can They Predict Liver Cirrhosis?
Yu, H.^{1,2}; Valin, C.¹; Wilson, S.^{1,2}* 1. Foothills Medical Centre, Calgary, Canada; 2. University of Calgary, Calgary, Canada

10:00 am-11:30 am

SS11. Vascular and Interventional Radiology—Moderators: *J. Lorenz, T. Kinney*; Keynote: Hepatic Chemoembolization: Is it Time for a Paradigm Change?—*C. Ray*

Randle A, Fourth Level

093. Fluoroscopic Guided Percutaneous Gallstone Removal in High-Risk Surgical Patients With Acute Cholecystitis
Yeo, S.^{1}; Rho, B.¹; Kim, Y.¹; Kim, Y.²* 1. Dong San Medical Center, Daegu, Korea; 2. Andong General Hospital, Andong, Korea

094. Closure of Chronic Enterocutaneous Fistulae With Porcine Extracellular Matrix: Early Results With Image Guided Placement
Stavas, J.; Koruda, M.; Burke, C.; Dixon, R.; Sadiq, T.; Mauro, M.* University of North Carolina, Chapel Hill, NC

095. Covalent Gadolinium Binding to Vein Graft Wall Durably Enhances MRI Conspicuity
Rybicki, F.; Vemula, P.; Mitsouras, D.; Yu, P.; Campagna, C.; Nguyen, B.; Mulkern, R.; Karp, J.* Brigham and Women's Hospital, Boston, MA

096. Post-Operative Monitoring of Aortic Stent Grafts: Can Wireless Implantable Pressure Sensors Replace CT Angiography (CTA) in the Detection of Endoleaks?
Moshiri, S.; Ho, L.; Suhocki, P.; Paulson, E.* Duke University Medical Center, Durham, NC

097. Estimated Effective Dose of CT Guided Abdominal Procedures
Dixon, R.¹; Maymani, H.^{1}; Ogden, K.²; Yu, H.¹; Burke, C.¹; Stavas, J.¹* 1. University of North Carolina in Chapel Hill, Chapel Hill, NC; 2. Syracuse University, Syracuse, NY

098. Velocity Compensated Aortoiliac CT Angiography
Budovec, J.^{1}; Foley, W.¹; Levenhagen, M.¹; Barnes, B.²* 1. Medical College of Wisconsin, Milwaukee, WI; 2. Froedtert Memorial Hospital, Milwaukee, WI

1:00 pm-3:30 pm

Review Course: Nuclear Medicine

Manchester Ballroom, Second Level

PET/CT—*D. Yoo*
Endocrine—*E. Akin*
Gastrointestinal—*H. Jacene*
Pediatrics—*T. Wong*
Skeletal—*C. Rajadhyaksha*

1:00 pm-2:30 pm

IC208. Acute Bowel—Current Imaging: Bowel Obstruction—*W. Thompson*; MDCT Techniques and Trauma—*R. Thoeni*; Small Bowel Ischemia and Obstruction—*C. Menias*; Diverticulitis and Appendicitis—*E. Webb*

Douglas C, Lobby Level

IC209. Hip Imaging and Sports Hernia—*W. Morrison, D. Blankenbaker, I. Omar*

Douglas A, Lobby Level

IC210. Glands of the Visceral Space: Thyroid and Parathyroid Imaging—*Y. Anzai, L. Loevner, D. Shatzkes*

Douglas B, Lobby Level

* Presenting Author

TUESDAY SCHEDULE



1:00 pm-3:00 pm

SS12. Breast Imaging: Biopsy and Breast Imaging Outcomes—
Moderators: *A. Campbell, T. Stephens*; Keynote: Imaging Guided Needle
Biopsies of the Breast—A Moving Target—*V. Jackson*

Elizabeth H, Second Level

099. Incidence of Pleomorphic and Classic Lobular Carcinoma In-Situ in
Percutaneous Biopsies of the Breast: An Institutional Review
Lee, J.^{1,2}; Mercado, C.¹; Hernandez, O.^{1,2}; Moy, L.^{1,2}; Toth, H.^{1,2}* 1. NYU
School of Medicine, Scarsdale, NY; 2. NYU Cancer Institute, New York, NY

100. Management of Patients Diagnosed With Lobular Carcinoma in Situ
(LCIS) at Needle Core Biopsy
Destounis, S.; Young, W.; Somerville, P.; Murphy, P.; Seifert, P.; Arieno,
A.; Morgan, R.* Elizabeth Wende Breast Care, LLC, Rochester, NY

101. Flat Ductal Intraepithelial Neoplasia (DIN1A) Diagnosed at Stereotactic
Core Needle Biopsy: Is Excisional Biopsy Indicated?
Becker, A.^{1}; Gordon, P.²; Harrison, D.³; Hassell, P.³; Hayes, M.³; van
Niekerk, D.³; Wilson, C.³* 1. The University of British Columbia, Vancouver,
Canada; 2. BC Women's Hospital and Health Centre, Vancouver, Canada;
3. British Columbia Cancer Agency, Vancouver, Canada

102. Comparison of Histologic Upgrade Rates for Atypical Ductal
Hyperplasia and Complication Rates Between the 11- and 8-Gauge
Stereotactic Vacuum-Assisted Breast Biopsy Systems
Chesebro, A.^{1}; Andrejeva, L.²; Philpotts, L.²* 1. New York Medical College,
Valhalla, NY; 2. Yale University School of Medicine, New Haven, CT

103. Value of Pathologic Analysis of Lost Tissue Fragments in the Vacuum
Canister During a Vacuum-Assisted Stereotactic Biopsy of the Breast
El Khoury, M.^{1,2}; Mesurolle, B.²; Omeroglu, A.²; infusini, N.²; Pare,
M.²; Kao, E.²; Fleischer, D.²* 1. CHUM, Montreal, Canada; 2. MUHC,
Montreal, Canada

104. The Effect of Including BI-RADS 0 Assessments on Positive Predictive
Value for Biopsy in Diagnostic Mammography
Alsheik, N.; Knudson, C.; Woods, R.; Burnside, E.; Salkowski, L.; Sisney,
G.; Lindstrom, M.* University of Wisconsin Hospitals and Clinics, Madison,
WI

105. Synchronous Bilateral Breast Cancer: Mammography, Sonography,
and Histopathologic Correlation
Adrada, B.; Wei, W.; Quraishi, A.; Yi, M.; Hunt, K.; Gilcrease, M.; Yang, W.*
The University of Texas M. D. Anderson Cancer Center, Houston, TX

106. Clinical and Imaging Features Associated With Breast Cancers
Diagnosed in Women <50
Kasales, C.; Mauger, D.; Van Hook, D.; Mack, J.; Schetter, S.* Penn State
Hershey Medical Center, Hershey, PA

107. Mammography Findings and Clinical Features of Triple Negative Breast
Cancer
Krizmanich-Conniff, K.; Aramagul, C.; Roubidoux, M.; Helvie,
M.; Patterson, S.; Sabel, M.; Myles, J.; Jiang, Q.* University of Michigan, Ann
Arbor, MI

108. Invasive Micropapillary Carcinoma: Radiographic Features in 18
Patients With This Unusual Variant

Mercado, C.; Guth, A.; Mercado, C.; Moy, L.; Lee, J.; Toth, H.; Cangiarella,
J.* NYU School of Medicine, New York, NY

109. Outcomes Analysis of Semiannual Ipsilateral Mammographic
Surveillance Following Breast Conservation Therapy: 12-Year Experience
Arasu, V.^{1}; Joe, B.¹; Lvoff, N.²; Leung, J.³; Brenner, R.⁴; Flowers, C.¹; Chang,
B.¹; Sickles, E.¹* 1. University of California, San Francisco, San Francisco,
CA; 2. California Advanced Imaging Medical Associates, Novato, CA; 3.
California Pacific Medical Center, San Francisco, CA; 4. Bay Imaging
Consultants Medical Group, Inc, Walnut Creek, CA

1:00 pm-3:00 pm

SS13. Cardiopulmonary Imaging—Moderators: *R. Munden, M. Parker*;
Keynote: CT Radiation Risks: What Patients Really Need to Know—
M. Parker

Elizabeth G, Second Level

110. Quantitative Evaluation of Techniques that Target Dose Reduction to
the Female Breast during CT Coronary Angiography: Assessing Helical and
Volumetric Data Acquisitions
Abadi, S.; Mehrez, H.; Ursani, A.; Parker, M.; Paul, N.* University Health
Network, Toronto, Canada

111. Bismuth Breast Shielding and its Effect on Calcium Score and Dose in
Dual Source MDCT
Ciancibello, L.; Gilkeson, R.* University Hospitals Case Medical Center,
Cleveland, OH

112. Effect of Age, Indication and Weight-Based Automatic Exposure
Control Technique for Chest CT Scanning
Prakash, P.; Kalra, M.; Abujudeh, H.; Digumarthy, S.; Gilman, M.;
Shepard, J.* Massachusetts General Hospital, Boston, MA

113. Low-Dose Thoracic Aortic Angiography Using Wide Detector Array CT
Rajiah, P.; Schoenhagen, P.; Halliburton, S.* Cleveland Clinic Foundation,
Cleveland, OH

114. Does ASIR Solve the Issues With Image Quality in Obese Patients?
Prakash, P.^{1}; Kalra, M.¹; Hsieh, J.²; Gilman, M.¹; Shepard, J.¹; Digumarthy,
S.¹* 1. Massachusetts General Hospital, Boston, MA; 2. No Institutional
Affiliation

115. CT Fluoroscopy Versus Conventional CT: An Examination of Radiation
Exposure and Diagnostic Yield During Intrathoracic Biopsy
Javidan-Nejad, C.^{1,2}; Joshi, G.^{3}; Pilgram, T.²; Whiting, B.^{1,2}* 1. Washington
University School of Medicine, Saint Louis, MO; 2. Mallinckrodt Institute of
Radiology, Saint Louis, MO; 3. Medical University of South Carolina,
Charleston, SC

116. The Use of 100kVp and its Effect on Total Calcium Score in MDCT
Ciancibello, L.; Gilkeson, R.* University Hospitals Case Medical Center,
Cleveland, OH

TUESDAY SCHEDULE



117. Selective Enhancement of Pulmonary Arteries for Detection of Pulmonary Emboli at 64 Slice MDCT Angiography: Test Bolus Versus Automatic Bolus Tracking Technique
Figueira, K.^{1,2}; Dhamanaskar, K.^{1,2}; Jerome, S.¹; Yemen, B.^{1,2}* 1. Hamilton Health Sciences, Hamilton, Canada; 2. McMaster University, Hamilton, Canada

118. Judicious Use of CT Pulmonary Angiograms in the Emergency Department
La Plante, J.^{1}; McWey, R.²* 1. University of Utah, Salt Lake City, UT; 2. University of Virginia, Charlottesville, VA

119. Sensitivity of Low Dose CT Thorax for PAVM Detection in HHT
Budhani, F.; Marcuzzi, D.; Common, A.; Faughnan, M.; Prabhudesai, V.* St. Michael's Hospital-University of Toronto, Toronto, Canada

1:00 pm-2:30 pm

SS14. Vascular and Interventional Radiology—Moderators: S. Zangan, U. Pua; Keynote: Minimally Invasive Management of Neuroendocrine Hepatic Metastases—D. Madoff

Randle A, Fourth Level

120. Changes in the Volume of Enhancing Tumor on MDCT as the Predictor of Hepatocellular Carcinoma Response to 90-Yttrium (90Y) Radioembolization Therapy
*Tochetto, S.; Galizia, M.; Rezai, P.; Yaghmai, V.** Northwestern University, Chicago, IL

121. Can a Peripheral Pattern of Necrosis Predict Intrahepatic Cholangiocarcinoma Response to Yttrium-90 Microsphere Treatment?
Horowitz, J.; Yaghmai, V.; Miller, F.; Lewandowski, R.; Nikolaidis, P.; Salem, R.* Northwestern University, Chicago, IL

122. Evaluation of Hepatic Tumor Necrosis on MDCT: Comparison of Qualitative and Quantitative Assessment of Treatment Response
Yaghmai, V.; Tochetto, S.; Galizia, M.; Rezai, P.; Salem, R.; Miller, F.* Northwestern University, Chicago, IL

123. Color Flow Doppler Imaging for the Assessment and Treatment of Liver Biopsy-Associated Bleeding
Ripley, B.; Durelle, J.; Lavine, J.; Schwimmer, J.; Rose, S.* UCSD, San Diego, CA

124. Percutaneous CT and US Guided Radiofrequency Ablation of Renal Masses: Long Term Efficacy
McClure, T.; Chow, D.; Raman, S.* University of California, Los Angeles, Los Angeles, CA

125. Ultrasound Guided Percutaneous Interventions on Liver Masses Using Real Time Navigation With Image Fusion and Needle-Tip Tracking
Kolokythas, O.^{1}; Gauthier, T.^{1,2}; Kemkers, R.²; Cuevas, C.¹; Lee, J.¹; Green, D.¹; Warren, B.¹; Mitsumori, L.¹* 1. University of Washington, Seattle, WA; 2. Philips Healthcare, Ultrasound, Bothell, WA

126. Radiation Dose Reduction for CT-Guided Renal Tumor Cryoablation
Leng, S.; Atwell, T.; Yu, L.; Mandrekar, J.; Liewis, B.; Woodrum, D.; Bruesewitz, M.; McCollough, C.* Mayo Clinic, Rochester, MN

4:00 pm-5:30 pm

IC211. Breast MRI: Basic Clinical Principles and Navigating the New ACR Accreditation Breast MR Program—C. Comstock, M. Boston

Douglas A, Lobby Level

IC212. Lesions of the Jaw and Larynx—R. Daffner, A. Lupetin

Douglas B, Lobby Level

IC213. Bars, Screws, Struts, Cages and Scars: A Review of the Postoperative Spine—J. Ross, T. Naidich

Douglas C, Lobby Level

IC214. Management of Challenging Cases in Interventional Liver Oncology: A Case-Based Approach—D. Madoff, R. Murthy, S. Rose

Randle A, Fourth Level

4:00 pm-6:00 pm

SS15. Gastrointestinal Imaging: Small and Large Bowel—Moderators: C. Santillan, R. Aslam; Keynote: MR and CT Enterography: Indications and Technical Considerations—C. Santillan

Elizabeth G, Second Level

127. CT of Blunt Traumatic Gastrointestinal and Mesenteric Injuries: Subtle Signs, How Significant Are They?
Mahajan, A.^{1}; Kv, R.²; Smiti, S.²; Rao, V.²; Thakur, M.¹* 1. Tata Memorial Hospital, Mumbai, India; 2. Kasturba Medical College, Manipal, India

128. MR Enterography in the Assessment of Crohn's Disease
Paspulati, R.^{1}; Katz, J.¹; Splawsky, J.^{1,2}; Chelimsky, G.^{1,2}* 1. University Hospital, Case Western Reserve University, Solon, OH; 2. Rainbow Babies and Children Hospital, Cleveland, OH

129. Grading of Active Inflammation With MR Enterography: Comparison to Widely Used Clinical Indices
Grand, D.; Kerstetter, D.; Shah, S.* Warren Alpert School of Medicine, Brown University, Providence, RI

130. CT Findings of Cecal Volvulus
Rosenblat, J.; Levsky, J.; Den, E.; DuBrow, R.; Wolf, E.; Rozenblit, A.* Montefiore Medical Center, Bronx, NY

131. Mimics of Acute Appendicitis: CT Predictors of Appendiceal Disease Confirmed at Pathology
Duda, J.; Lynch, M.; Bhatt, S.; Dogra, V.* University of Rochester, Rochester, NY

132. MRI of Appendicitis in Pregnancy: Comparison of Experienced and Inexperienced Readers
Champion, V.; Corwin, M.; Lazarus, E.; Woodfield, C.* Brown University, Providence, RI

133. Multi-Detector CT for Suspected Acute Appendicitis: Diagnostic Performance in 1,666 Adults
Lawrence, E.; Pickhardt, P.* University of Wisconsin School of Medicine and Public Health, Madison, WI

134. Accuracy of CT Without Versus With Oral Contrast in the Diagnosis of Acute Appendicitis
Tappouni, R.; Mohamed Ali, R.; Sarwani, N.* Penn State, Hershey, PA

TUESDAY SCHEDULE



135. Correlation of MRI Defecography With Conventional Fluoroscopic Defecography in the Evaluation of Chronic Constipation
Paspulati, R.; Delaney, C.; Champagne, B. University Hospital, Case Western Reserve University, Solon, OH*

4:00 pm-6:00 pm

SS16. Pediatric Imaging—Moderators: *E. Lee, T. Huisman*;
Keynote: Advanced MRI of the Pediatric Brain: Why?—*T. Huisman*
Elizabeth H, Second Level

136. Prevalence of Choroid Plexus Cysts in Near Term and Term Neonates With Congenital Heart Disease
Rai, B.; Desai, H.; Cohen, M.; Norton, K. Children's Hospital of New Jersey, Tenafly, NJ*

137. The Role of Cardiac CT in the Evaluation of Tracheobronchial Abnormalities in Patients With Tetralogy of Fallot
Poach, C.^{1,2}; Richardson, R.¹; Umstead, E.¹; Saghari, A.¹*
1. St. Joseph's Hospital and Medical Center, Phoenix, AZ; 2. The University of Arizona, Tucson, AZ

138. Role of Coronary CT Angiography in Pediatric Patients With Coronary Artery Fistulas
Shah, P.; Saghari, A.; Alboliras, E.; Diab, K.; Pophal, S.; Cleveland, D.; Nigro, J.; Richardson, R. St Josephs Hospital and Medical Center, Phoenix, AZ*

139. Detection of Scarring in Children with Renal Transplants and Urinary Tract Infection: Comparison of DMSA and Ultrasound
Shah, V.¹; Shah, S.²; Fernando, R.²; Anderson, P.²; Marks, S.²; Biassoni, L.²
1. Imperial Healthcare NHS Trust, Hemel Hempstead, UK; 2. Great Ormond Street Hospital NHS Trust, London, UK

140. To Assess the Role of Abdominal Sonography in the Preoperative Diagnosis of Extrahepatic Biliary Atresia in Children <90 Days of Age
Saxena, A.; Mittal, V.; Sodhi, K.; Thapa, B.; Rao, K.; Das, A.; Khandelwal, N.*
Post Graduate Institute of Medical Education and Research, Chandigarh, India

141. Renal Excretion of Gastrografin after Gastrografin Enema in Neonates and Infants; When Does it Occur?
Je, B.^{1}; Kim, S.²; Lee, K.¹; Cha, S.¹* *1. Korea University Hospital, Ansan, Gyeonggido, Korea; 2. Dongshin Hospital, Seoul, Korea*

142. Effect of kVp on Noise, Dose and Contrast-to-Noise Ratio for Pediatric Low Dose CT
Gamberoni, J.; Dong, F.; Davros, B.; Reid, J. Cleveland Clinic, Cleveland, OH*

143. Comparison of Adaptive Iterative and Filtered Back Projection Reconstruction Techniques for Pediatric CT Acquired at Lower Radiation Dose
Singh, S.; Kalra, M.; Doyle, M.; Shenoy-Bhangle, A.; Westra, S.*
Massachusetts General Hospital, Boston, MA

144. Safety of Gadobenate Dimeglumine (Gd-BOPTA) in Cardiovascular Imaging of Pediatric Patients
Schneider, G.; Schuerholz, H.; Buecker, A.; Fries, P. Saarland University Hospital, Homburg, Germany*

4:00 pm-6:30 pm

Review Course: Cardiovascular Imaging
Manchester Ballroom, Second Level

Cardiac MR: Common Applications—*C. Javidan-Nejad*

Cardiac CT: Common Applications—*J. Hsu*

Pulmonary Artery CT and MR—*K. Birchard*

Plain Film—*S. Bhalla*

Aortic CT and MR—*S. Seth*

* Presenting Author



WEDNESDAY, MAY 5



6:00 am–6:00 pm
Speaker Preview Room

Molly A/B, Second Level

6:30 am–4:30 pm
Registration

Elizabeth Foyer, Second Level

7:00 am–12:00 midnight
Electronic Exhibits

Randle D/E, Fourth Level

7:30 am–10:00 am
Case-Based Imaging Review Course
There is an additional fee to attend this course.

Manchester Ballroom, Second Level

8:00 am–9:30 am
As part of ARRS' Global Exchange with South Korea, we are honored to have Dr. Kyung Soo Lee participate in IC302 as follows:
IC302. Radiographic and CT Imaging of Pulmonary Infections: TB/NTMB, Community-Acquired, Immunocompromised—*K. Soo Lee; J. Fishman; L. Ketaj; H. Page McAdams*

Douglas C, Lobby Level

9:30 am–10:30 am
Coffee Break in the Exhibit Hall

Elizabeth Ballroom, Second Level

10:00 am–11:30 am
As part of ARRS' Global Exchange with South Korea, we are honored to have Dr. In-One Kim participate in IC309 as follows:
IC309. Cranial Ultrasound: State of the Art—*L. Lowe*;
Pediatric Spine Imaging: State of the Art—*N. Kadom*;
Pediatric Leukodystrophies: Review—*I. Kim*

Douglas A, Lobby Level

12:00 noon–1:00 pm
Lunch in the Exhibit Hall

Elizabeth Ballroom, Second Level

1:00 pm–6:30 pm
Case-Based Imaging Review Course
There is an additional fee to attend this course.

Manchester Ballroom, Second Level

2:45 pm–3:15 pm
Member Business Meeting

Elizabeth F, Second Level

3:00 pm–4:00 pm
Soda Break in the Exhibit Hall

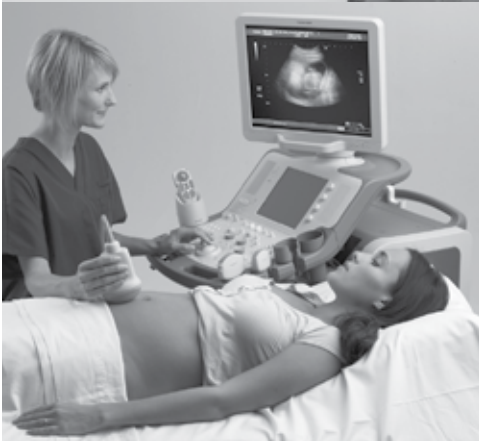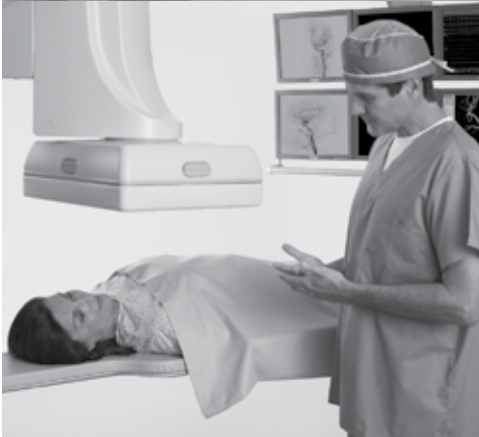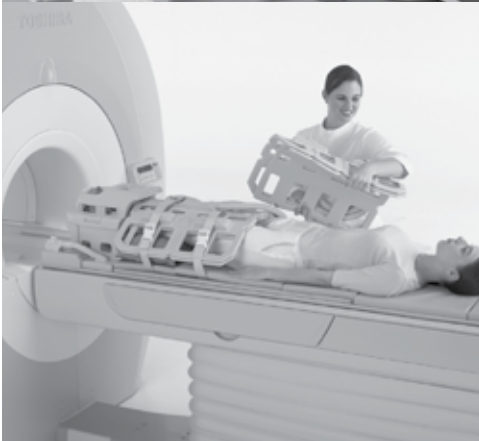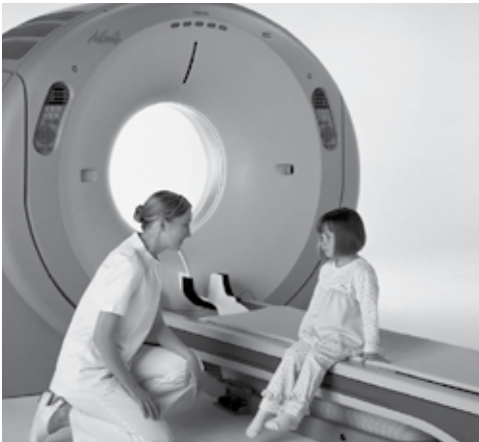Elizabeth Ballroom, Second Level

*IC=Instructional Course
SS=Scientific Session*

CORPORATE SPONSORED ACTIVITY

7:00 am–8:00 am
State of the Art CT: From Data to Knowledge—*Elliot K. Fishman MD*
Sponsored by Siemens Healthcare
(Breakfast will be available for the first 130 attendees)

Douglas D, Lobby Level



For patients.
For practitioners.
For life.

(Innovation made for all the right reasons.)

With the ultimate goal of providing the best diagnostic images in medicine, Toshiba has delivered innovative imaging solutions for nearly a century. We develop safer, more efficient ways to scan while providing the kind of service that has earned us MD Buyline's top rating in customer satisfaction.



2009 Top 20 Best In KLAS Awards: Medical Equipment
**Ranked #1: Aquilion® CT-64 Slice +,
Vantage MRI 1.5T, Xario™ Ultrasound.**

www.KLASresearch.com ©2009 KLAS Enterprises,LLC. All rights reserved.

TOSHIBA
Leading Innovation >>>

WEDNESDAY SCHEDULE



7:00 am-8:00 am

Power Hour: Cardiopulmonary Imaging—*C. Meyer, moderator*

Randle B, Fourth Level

- E52. Echocardiography and MDCT, Complimentary Techniques—*C. Rojas*
E57. Optimal Viewing Parameters for Myocardial Stress Perfusion Computed Tomography—*T. Techasith*
E62. Myocardial BOLD Imaging: A New Frontier for Ischemic Heart Disease—*S. Peter*
E75. Pulmonary Valve Disease: Improved Diagnosis With Advanced CT and MRI Technology—*E. Vogelius*
E82. Imaging of Malignant Pleural Neoplasms—*F. Souza*
E96. Assessment of Collateral Pathway Formation in Severe Occlusive Coronary Artery Atherosclerotic Disease Using Multidetector 64-Slice CT Coronary Angiography With Conventional Coronary Angiography Correlation—*I. Chan*
E98. Video-Assisted Thorascopic Surgery (VATS): What the Radiologist Needs to Know—*C. Parghi*

7:00 am-8:00 am

Power Hour: Pediatric Imaging—*T. Huisman, moderator*

Randle A, Fourth Level

- E618. Pediatric Osteomyelitis: An Interactive Case Series With Emphasis on MRI and Radiologic Correlation—*H. Yarmohammadi*
E619. Imaging of Absent Septum Pellucidum on Prenatal Ultrasound: Correlation With Prenatal MRI—*A. Chaturvedi*
E623. Neonatal Cranial Sonography: A Pictorial Review—*S. Neville*
E635. MR Imaging of Typical and Atypical Focal Nodular Hyperplasia in Treated Pediatric Oncologic Patients—*S. Shaylor*
E641. Help Me! Somebody Hurt Me: A Pictorial Quiz of Nonaccidental Trauma—*L. Wu*
E645. Demystifying Skeletal Dysplasias: Skull and Craniocervical Junction—*S. Foster*
E646. Pictorial Review of Pediatric Scrotal Disorders—*J. Goldberg*
E649. Vascular Anomalies in Children: Update and Review of Classification—*S. Abedin*

7:30 am-10:00 am

Review Course: Breast Imaging

Manchester Ballroom, Second Level

- Calcifications—*T. Stephens*
Ultrasound Evaluation of Mammographic Findings—*A. Nees*
Architectural Distortion and Asymmetries—*L. Salkowski*
Ductal Pathology—*M. Szabunio*
Breast MRI—*A. Soetaert*

8:00 am-9:30 am

- IC301. CT Colonography—Technique, Interpretation and the Future: New Strategies for CTC Interpretation—*J. Yee*; Noncathartic CT Colonography—*M. Zalis*; State-of-the-Art CTC Technique—*D. Kim*; CTC Reimbursement and the Future—*J. Yee*

Douglas A, Lobby Level

- IC302. Radiographic and CT Imaging of Pulmonary Infections: TB/NTMB, Community-Acquired, Immunocompromised—*K. Soo Lee, J. Fishman, L. Ketai, H.P. McAdams*

Douglas C, Lobby Level

- IC303. MR Imaging of the Knee—*M. Recht, C. Glaser*

Douglas B, Lobby Level

- IC304. Cerebral Venous Imaging: Current Techniques and Diagnostic Pitfalls—*J. Leach, T. Abruzzo*

Elizabeth G, Second Level

- IC305. Upper Extremity Sports Injuries in Children: State of the Art—*J. Mackenzie*; Painful Topics in Pediatric Orthopedics: Review—*M. Dempsey-Robertson*; Pediatric Bone Lesions: Review—*P. Karakas*

Elizabeth H, Second Level

- IC306. Aortic Stent Grafts: Imaging and Intervention—Thoracic Stent Grafts, Overview of Devices and Cases—*R. Hieb*; Planning Abdominal Aortic Grafts—*F. Facchini*; Secondary Interventions: When and How—*M. Neisen*

Elizabeth F, Second Level

10:00 am-11:30 am

- IC307. Arthritis: Basic and Advanced Imaging—*D. Flemming, M. Bruno, L. Bancroft*

Douglas C, Lobby Level

- IC308. You've Got a Lot of Nerve... Until You Don't! Perineural Tumor Spread and Patterns of Denervation—*L. Ginsberg, W. Smoker*

Douglas B, Lobby Level

- IC309. Cranial Ultrasound: State of the Art—*L. Lowe*; Pediatric Spine Imaging: State of the Art—*N. Kadam*; Pediatric Leukodystrophies: Review—*I. Kim*

Douglas A, Lobby Level

- IC310. Vertebroplasty: The Beginner's Course—*S. Tutton, M. Davidian*

Randle A, Fourth Level

10:00 am-12:00 noon

- SS17. Cardiopulmonary Imaging—Moderators: *B. Sundaram, M. Truong*; Keynote: Update on Imaging of the Solitary Pulmonary Nodule—*M. Truong*

Elizabeth G, Second Level

145. CAD for Lung Nodule Detection Using Compressed CT Data: Benefit to Readers on Thick-Section Images
Sussmann, A.^{1}; Ko, J.¹; Girvin, F.¹; Naidich, D.¹; Babb, J.¹; Shah, M.¹; Brusca-Augello, G.¹; Anand, V.² 1. New York University Langone Medical Center, New York, NY; 2. No Institutional Affiliation*

146. Fissural Nodular Densities: Inherent Stability and Benignity, and Variability in Descriptive Nomenclature
Pryluck, D.; Shiau, M.; Wnorowski, A.; Naidich, D.; Sanger, J.; Rom, W. NYU School of Medicine, New York, NY*

147. Nomenclature of Mediastinal, Pleural and Diaphragmatic Disease: Standardization of Reporting: What the Video Assisted Thoracic Surgeon Wants to Know
Parghi, C.; Tu, R.; Daluvoy, S.; Akin, E. The George Washington University, Washington, DC*

* Presenting Author

WEDNESDAY SCHEDULE



148. To Evaluate the Safety and Accuracy of an Optically Guided Stereotactic Computer Needle Guidance System in Patients Undergoing CT-FNAB of Lung Nodules
Paul, N.; Hoang, D.; Carillo, M.; Alturkistany, S.; Summerfield, R.; Chung, T.; Patsios, D.; Rogalla, P. University of Toronto, Toronto, Canada*

149. Do Follow-Up Chest Radiographs Change Management in Patients With no Pneumothorax on Immediate Post Procedure CT after Transthoracic Needle Biopsy of the Lung?
Pan, L.; Berkmen, T. Hospital of St. Raphael, New Haven, CT*

150. Feasibility of Focal Lung Nodule Biopsy Following Prior Contralateral Pneumonectomy: Our Experience to Date
Cronin, C.; Sharma, A.; Digumarthy, S.; Wu, C.; Gilman, M.; Shepard, J. Massachusetts General Hospital, Boston, MA*

151. A Best-Fit Model for Determination of Total Lung Volume from Unidimensional Diameters at MDCT
Rezai, P.; Galizia, M.; Tochetto, S.; Yaghamai, V. Northwestern University, Chicago, IL*

152. Utility of Thin Section CT in Assessing the Response of Systemic Sclerosis to Stem Cell Transplant
Dill, K.; Roytberg, A.; Wood, C.; Grant, T. Northwestern University, Chicago, IL*

153. Can Chest CT Predict the Presence of Pulmonary Infection in Hematopoietic Stem Cell Transplantation Recipients?
Bogot, N.; Lieberman, S.; Maslak, J.; Digandomeico, S.; Kaul, D.; Kazerooni, E.; Yanik, G. University of Michigan, Ann Arbor, MI*

10:00 am-12:00 noon

SS18. Gastrointestinal Imaging: Evaluation and Screening for Colorectal Cancer—Moderators: *L. Hinshaw, J. Yee*; Virtual Colonoscopy at the University of Wisconsin: How and Why—*L. Hinshaw*

Elizabeth H, Second Level

154. Standardized Reporting Utilizing CT Colonography Reporting and Data Systems (C-RADS) in Over 5,000 Colorectal Cancer Screening Individuals
Kim, D.; Pickhardt, P.; Lubner, M.; Robbins, J.; Hinshaw, J. University of Wisconsin, Middleton, WI*

155. Effect of a Concurrent Virtual Dissection With CAD for CTC Interpretation: A Multi-Reader Study Evaluating Accuracy and Interpretation Times
Afshan, A.1; Macari, M.1; Cho, K.1; Bonavita, J.1; Robinson, E.1; Bogoni, L.2; Salganicoff, M.2; Wolf, M.2; Raykar, V.2* 1. NYU Langone Medical Center, New York, NY; 2. Siemens, Malvern, PA

156. Colonic Insufflation During CT Colonography—How Much Gas?
McLaughlin, P.; Suhail, A.; McWilliams, S.; O'Connor, O.; Kelly, D.; Maher, M. University College Cork, Cork, Ireland*

157. Frequency for Performing an Additional Imaging Series at CT Colonography
Buchach, C.; Pickhardt, P.; Kim, D. University of Wisconsin, Madison, WI*

158. Incidental Renal Masses Identified at Screening CT Colonography: Frequency and Clinical Relevance
O'Connor, S.1; Pickhardt, P.1; Kim, D.1; Oliva, M.2; Silverman, S.2* 1. University of Wisconsin, Madison, WI; 2. Brigham and Women's Hospital, Boston, MA

159. Comparison of Accuracy of PET/CT With MRI for Detecting Hepatic Metastases in Patients With Newly Diagnosed or Suspected Recurrent Colorectal Carcinoma
Tannaphai, P.; Lee, J.; Khandani, A.; Warshauer, D.; Calvo, B.; O'Connor, W. University of North Carolina, Chapel Hill, NC*

160. The Utility of PET/CT in the Management of Colorectal Cancer Patients With Suspected Recurrence
Liong, S.1,2; Kochhar, R.2; Manoharan, P.2* 1. Manchester Radiology Training Scheme, Altrincham, United Kingdom; 2. The Christie, Manchester, United Kingdom

161. Tertiary Centre Experience of the Impact of PET/CT on the Management of Patients with Metastatic Colorectal Cancer
Kochhar, R.1; Liong, S.1,2; Manoharan, P.1* 1. The Christie, Manchester, UK; 2. Manchester Radiology Training Scheme, Altrincham, UK

162. Quantitative Methodology Using CT for Predicting Survival in Patients With Metastatic Colorectal Carcinoma: A Pilot Study
Gottlieb, R.; Raczky, C.; Hanna, T.; Fora, A.; Tan, W.; Nayyar, R.; Fakh, M. Roswell Park Cancer Institute, Williamsville, NY*

163. Can We Predict Prognosis of Carcinoma of the Colon?
*Botchu, R.; Khan, A.; Patel, R.; Elabassy, M.** University Hospitals of Leicester, Leicester, United Kingdom

1:00 pm-2:30 pm

IC311. Benign Diseases of the Female Pelvis: Imaging of Infertility: From HSG to MRI—*J. Fielding*; Urogynecology and Pelvic Floor Imaging—*A. Thurmond*; Problematic Early Pregnancies—*R. Goldstein*; The Cystic Ovarian Mass—*M. Patel*

Douglas A, Lobby Level

IC312. Digital Breast Tomosynthesis—*D. Gur, M. Zuley, J. Sumkin*

Elizabeth G, Second Level

IC313. HRCT Imaging of Lung—*G. Abbott, A. Sharma, M. Gosselin*

Douglas C, Lobby Level

IC314. Radiation Safety (vascular and interventional radiology)—*B. Dixon, K. Ogden, R. Thornton*

Randle A, Fourth Level

1:00 pm-3:00 pm

SS19. Musculoskeletal Imaging: Neoplastic, Metabolic and Spine Imaging—Moderators: *B. Sabb, S. Smith*; Keynote: Imaging of Neoplastic Disease and Mimickers—*S. Smith*

Elizabeth H, Second Level

WEDNESDAY SCHEDULE



164. Tumor Necrosis Quantification on Imaging as a Predictor of Therapy Response for Soft Tissue Sarcoma—Comparison Between Estimates Obtained by MRI Volumetry and Pathology

Singh, A.; Harmon, D.; Rosenthal, D.; Lawrimore, T.; Cai, W.; Yoshida, H.; McGowan, J.; Harris, G. Massachusetts General Hospital, Boston, MA*

165. Imaging of Peripheral Multiple and/or Plexiform Schwannomas
Song, A.^{1}; Murphey, M.¹; Kransdorf, M.²; Miettinen, M.¹ 1. Armed Forces Institute of Pathology, North Bethesda, MD; 2. Mayo Clinic Jacksonville, Jacksonville, FL*

166. Describe Negative or Misleading Imaging Findings in Unusual Variants of Multiple Myeloma-Nonsecretory Myeloma and Nonexcretory Myeloma
Feldman, F. Columbia Presbyterian Medical Center, Bronx, NY

167. Bone Marrow Alteration in Patients With Type 1 Gaucher Disease on Enzyme Replacement Therapy
Lerner, D.; Simpson, W.; Hermann, G.; Balwani, M. Mount Sinai Medical Center, New York, NY*

168. Numeric Correlation Between Lumbar Spine DEXA Scores and Hounsfield Units of CT Scans of the Lumbar Spine in Noncontrast CT
Zonoy, A.; Mulligan, M.; Safdar, N. University of Maryland, Baltimore, MD*

169. Measuring the Density of a Lumbar Vertebral Body in Routine Multidetector CT of the Abdomen: A Feasibility Study
Didolkar, M.; Vinson, E.; Barnhart, H. Duke University Medical Center, Durham, NC*

170. Prevalence and Under-Reporting of Vertebral Fractures on CT Lateral Scout Views in Cancer Patients
Feeney, J.; Hwang, S. Memorial Sloan Kettering Cancer Center, Dublin, Ireland*

171. Utilization of Lumbar Spine MRI: Which Factors Affect Subsequent Intervention?
Kato, K.^{1}; Yoon, H.² 1. John A. Burns School of Medicine, Honolulu, HI; 2. Kaiser, Honolulu, HI*

172. High Resolution Quantitative PET/CT/MRI for Measuring Early Response to Therapy in Rheumatoid Arthritis
Chaudhari, A.; Bowen, S.; Naguwa, S.; Shelton, D.; Boone, J.; Buonocore, M.; Hunter, J.; Badawi, R. University of California Davis Medical Center, Sacramento, CA*

173. Relationship Between Elevated Serum Parathyroid Hormone, Sesamibi Scans and Radiographic Changes
Balogun, Y.; Barshay, V.; Dieudonne, G.; Monu, J. University of Rochester, Rochester, NY*

174. Are Radiographs of the Thoracic Spine Truly Inadequate in the Setting of Trauma? Accuracy of Thoracic Radiographs for Diagnosing Injuries of Varying Severity
Huddleston, J.^{1}; Davis, K.¹; Blankenbaker, D.¹; Lee, K.¹; Anderson, P.¹; Haaland, B.² 1. University of Wisconsin School of Medicine and Public Health, Madison, WI; 2. University of Wisconsin, Madison, WI*

* Presenting Author

1:00 pm-2:30 pm

SS20. Neuroradiology: Head and Neck—Moderators: *M. Michel, K. Salzman*; Keynote: Radiation Dose-Reduction in Head and Neck Imaging: Issues and Insights for Radiologists—*J. Hoang*

Randle B, Fourth Level

175. The Value of On-Site Pathology in Determining Adequacy for Ultrasound Guided Biopsy of Thyroid Nodules
Chong, W.; Parikh, A.; Hartz, D.; Paul, B.; Weinstein, L.; Maygarden, S. University of North Carolina, Chapel Hill, NC*

176. Learning a Bayesian Classifier for Thyroid Nodule Evaluation
Liu, Y.; Kamaya, A.; Desser, T.; Rubin, D. Stanford University, Los Altos, CA*

177. A Systemic Search for Patterns for Thyroid Nodule Evaluation Using a Bayesian Classifier
Liu, Y.; Kamaya, A.; Desser, T.; Rubin, D. Stanford University, Los Altos, CA*

178. Can the Ultrasound Appearance of a Thyroid Nodule Predict Ultimate Cytology Upon FNA?
Sacks, B.^{1,2}; Sacks, A.^{3}; Pallotta, J.²; Faquin, W.³ 1. Metrowest Medical Center, Framingham, MA; 2. Beth Israel Deaconess Hospital, Boston, MA; 3. Boston University Medical Center, Boston, MA; 3. Massachusetts General Hospital, Boston, MA*

179. 18FDG Standardized Uptake Value Ratio as a Biomarker for Differentiating Squamous Cell Carcinoma of the Base of Tongue from Physiological Uptake
Davison, J.; Surasi, D.; Grillone, G.; Subramaniam, R. Boston University School of Medicine, Boston, MA*

1:00 pm-3:30 pm

Review Course: Pediatric Imaging

Manchester Ballroom, Second Level

Chest/Pulmonary—*E. Lee*
Musculoskeletal—*E. Mann*
Abdominal—*S. Anupindi*
Neurology—*D. Rivard*
Genitourinary—*S. DiPerna*

2:45 pm-3:15 pm

Member Business Meeting

Elizabeth F, Second Level

4:00 pm-6:00 pm

IC315. Renal Parenchyma, Vessels and Urothelium: Renal Parenchyma—*V. Dogra*; GU Vasculature—*M. Lockhart*; Urothelium—*E. Caoili*; Renal Neoplasms—*Z. Wang*

Douglas C, Lobby Level

WEDNESDAY SCHEDULE

4:00 pm-5:30 pm

IC316. Ethical and Medical-Legal Issues in Radiology—*P. Kornguth, L. Berlin*

Elizabeth H, Second Level

IC317. HRCT: Airway and Smoking-Related Lung Disease—*A. Bankier, C. Meyer, J. Kanne, E. Donnelly*

Douglas A, Lobby Level

IC318. Musculoskeletal Tumors and PET Imaging—*M. Murphey, J. Peterson*

Douglas B, Lobby Level

IC319. Advanced Imaging Techniques for Head and Neck Disease—*S. Mukherji, A. Srinivasan*

Elizabeth F, Second Level

IC320. Pediatric Abdominal Imaging: State of the Art—*R. Goodman*;
Intestinal Obstruction in Children: State of the Art—*L. Fenton*; Neonatal
Abdominal Emergencies: Review—*J. Reid*

Elizabeth G, Second Level

4:00 pm-6:30 pm

Review Course: Vascular and Interventional Radiology

Manchester Ballroom, Second Level

Arterial Diagnosis—*B. Funaki*


Arterial Therapy—*S. Zangan*

Venous Interventions—*C. Ray*

Nonvascular Interventions—*M.G. Knuttinen*

Interventional Oncology—*A. Nemcek*

* *Presenting Author*



6:00 am–5:30 pm
Speaker Preview Room

Molly A/B, Second Level

6:30 am–4:30 pm
Registration

Elizabeth Foyer, Second Level

7:00 am–12:00 midnight
Electronic Exhibits

Randle D/E, Fourth Level

7:30 am–1:00 pm

Case-Based Imaging Review Course
There is an additional fee to attend this course.

Manchester Ballroom, Second Level

9:30 am–10:30 am
Coffee Break

Manchester Foyer, Douglas Foyer, Elizabeth Foyer

10:00 am–12:00 noon

As part of ARRS' Global Exchange with South Korea, we are honored to have Dr. Joon Koo Han participate in SS23 as follows:
SS23. Gastrointestinal Imaging: Pancreaticobiliary-Moderators:
J.K. Han, B. Yeh; Keynotes: Contemporary Imaging of Cystic Pancreatic Lesions—J.K. Han; Imaging of Biliary Obstruction—B. Yeh

Elizabeth G, Second Level

12:30 pm–2:00 pm

As part of ARRS' Global Exchange with Korea, we are honored to have Dr. Dong Ik Kim participate in IC411 as follows:
IC411. Noninvasive Vascular Neuroimaging: Ultrasound, CT Angiography and MR Angiography—*J. Gemmete, D. Kim, B. Huang*

Elizabeth G, Second Level

2:00 pm–3:00 pm
Soda Break

Manchester Foyer, Douglas Foyer, Elizabeth Foyer

2:30 pm–5:00 pm

Case-Based Imaging Review Course
There is an additional fee to attend this course.

Manchester Ballroom, Second Level

*IC=Instructional Course
SS=Scientific Session*

CORPORATE SPONSORED ACTIVITY

7:00 am–8:00 am

Maximizing Safety and Efficacy in Enhanced MRI and CT: What's New?
*Sponsored by Bracco Imaging
(Breakfast will be available for the first 280 attendees)*

Douglas D, Lobby Level

ARRS GoldMiner[®]: Tap into an image goldmine!

Search **200+** peer-reviewed journals and the EuroRad image database in seconds.

New images are added to ARRS GoldMiner[®] monthly.

ARRS GoldMiner[®] is available at www.arrs.org which now features **hot light**
HOTLIGHT makes learning easy by revealing word meanings
and providing the ARRS GoldMiner[®] search in one click.



A service of the American Roentgen Ray Society
www.arrs.org



PB2010

THURSDAY SCHEDULE



7:00 am-8:00 am

Power Hour: Emergency/General Radiology—*D. Katz, moderator*

Randle B, Fourth Level

- E188. CT Artifacts in the Obese Patient—*M. Gunn*
E172. Anatomic Positioning System (APS): Accuracy of Localization of Mock Blast Fragments on CT in Three Dimensions—*P. Shogan*
E177. What has Changed Between RECIST and RECIST 1.1?—*G. Oliveira*
E182. The Evolving Face of 3D-Imaging as a Biomarker: Clinical Significance and Evidence-Based Support—*A. Singh*
E194. The Essentials of Ectopic Pregnancy: An On-Call Guide—*D. Rausch*
E198. CT of the Skin—*G. Ganson*
E204. Emphysematous Infections of the Abdomen and Pelvis: A Comprehensive Review—*V. Ojili*
E205. Imaging the Pregnant Woman for Non-Obstetric Reasons: What You Need to Know—*S. Reddy*

7:00 am-8:00 am

Power Hour: Musculoskeletal—*L. Cerezal, N. Safdar, moderators*

Randle A, Fourth Level

- E402. The Spectrum of Irradiated Bone Marrow on MRI—*G. Bean*
E415. New and Improved: Orthopedic Hardware for the 21st Century—*J. Petscavage*
E440. Practical MR Evaluation of Knee Cartilage: Normal, Abnormal, and Why it Matters—*M. Robbins*
E449. Imaging Features of Glomus Tumors—*K. Glazebrook*
E450. Imaging Review of Synovial Disorders—*S. Baccei*
E453. MR Neurography Evaluation of Peripheral Nerve Surgery—*S. Thawait*
E455. MRI of Upper Extremity Peripheral Neuropathy—*A. Goud*

7:30 am-10:00 am

Review Course: Gastrointestinal Imaging

Manchester Ballroom, Second Level

- Liver—*C. Santillan*
Gallbladder/Biliary—*B. Yeh*
Pancreas—*C. Menias*
Small Bowel—*Z.J. Wang*
Colon—*H. Zafar*

8:00 am-9:30 am

- IC401. CTA of the Thorax: Pulmonary Thromboembolic Disease, Arterial and Venous Malformations, Acute Aortic Syndromes and Postoperative Evaluation of the Aorta—*L. Washington, S. Bhalla, C. Chiles, K. Birchard*
Douglas A, Lobby Level
IC402. Emergency Radiology: CT Protocols and Techniques: Evolving Concepts in MDCT Imaging of Abdominal Pain—*S. Anderson*; Imaging the Obese Patient in the Emergency Department—*M. Gunn*; MDCT in the Emergency Department: Update Your Protocols—*A. Sodickson*
Douglas C, Lobby Level
IC403. Multimodality Imaging of the Shoulder—*K. Buckwalter, K. Schreibman*
Douglas B, Lobby Level

- IC404. Pediatric Large Airway Disease: State of the Art—*E. Lee*; Pediatric Interstitial Lung Disease: State of the Art—*P. Guilleman*; Congenital Lungs: Review—*C. Carrico*

Elizabeth G, Second Level

- IC405. Pharmacology in Interventional Radiology: Sedation and Analgesia Primer, Anti-Coagulation and Anti-Platelet Therapy and Antibiotics, etc.—*H. Ferral, P. Gamboa, J. Lopera*
Elizabeth H, Second Level
SS21. Neuroradiology: Imaging Strategies and Techniques—Moderators: *D. Gandhi, M. Mullins*; Keynote: PET/CT and PET/MRI: Intracranial Applications of Metabolic Imaging—*R. Subramaniam*

Elizabeth F, Second Level

181. Evaluation of a Novel Readout Segmented Diffusion Weighted MR Sequence: Initial Clinical Experience
Morelli, J.^{1}; Runge, V.¹; Porter, D.²; Feiweier, T.²; Rangaswamy, R.¹; Vu, L.¹; Padua, A.²; Dix, J.³* 1. *Scott and White Memorial Hospital and Clinic, Temple, TX*; 2. *Siemens AG, Erlangen, Germany*; 3. *Methodist Hospital, San Antonio, TX*

182. Hybrid Convolution Kernel: Optimized CT of the Head, Neck, and Spine
Weiss, K.^{1}; Cornelius, R.¹; Greeley, A.²; Sun, D.^{1,3}; Boyce, W.¹; Chang, I.¹; Weiss, J.¹* 1. *University of Cincinnati, Cincinnati, OH*; 2. *No Institutional Affiliation*; 3. *Beijing Jiaotong University, Beijing, China*

183. Optimization of Patient Dose and Image Quality With Z-Axis Dose Modulation For CT Head Protocol
Zacharia, T.; Nguyen, D.* *Penn State Hershey Medical Center, Hummelstown, PA*

184. Rapid MRI Detection of Vertebral Numerical Variation
Akbar, J.^{1}; Weiss, K.¹; Saafir, M.²; Weiss, J.¹* 1. *University of Cincinnati, Cincinnati, OH*; 2. *No Institutional Affiliation*

185. Diffusion Tensor Imaging and Fibertracking at 7T
Sammet, S.^{1}; Irfanoglu, O.¹; Koch, R.^{1,2}; Schmalbrock, P.¹; Choi, S.¹; Achiraju, R.¹; Yuh, W.¹; Knopp, M.¹* 1. *The Ohio State University, Columbus, OH*; 2. *Brigham and Women's Hospital, Boston, MA*

186. Role of Intrathecal Gadolinium Myelocisternography in Evaluation of Cerebrospinal Fluid Rhinorrhoea
Singh, P.; Khandelwal, A.; Khandelwal, N.; Gupta, A.; Gupta, S.; Prabhakar, S.* *PGIMER, Chandigarh-23, India*

10:00 am-11:30 am

- IC406. Hot Topics in Thoracic Imaging: Radiation Dose, CAD-SPN, PE, Decision Analysis, Dual Source, Dual Energy CT, Functional Imaging—*L. Hurwitz, H. MacMahon, J. Vlahos, J. Goldin*
Douglas C, Lobby Level
IC407. Extreme Radiology and Interventions in Modern Warfare and National Disaster Relief—*R. Boucher, S. Ferrara*
Elizabeth H, Second Level
SS22. General/Emergency Radiology—Moderators: *K. Klein; M. Bruno*; Keynote: CT Radiation Safety and the Modern Emergency Department—*M. Bruno*
Douglas A, Lobby Level

THURSDAY SCHEDULE



187. Superfluous Radiographs of the Thoracic and Lumbar Spines in Trauma Patients Undergoing CT of the Chest, Abdomen and Pelvis—A Retrospective Review
Ciura, V.; Hahn, L.; Kirkpatrick, A.; Mahallati, H. University of Calgary, Foothills Medical Centre, Calgary, Canada*

188. Pelvic Fractures in the ED: Is a Thin Section Reformatted Bone CT Necessary?
Larrison, M.; Lopez, R. UAB, Birmingham, AL*

189. Subspecialty and Imaging Modality Analysis of Cross-Sectional Interpretation Discrepancies Between On-Call Radiology Residents and Subspecialty Faculty Radiologists
Ruma, J.; Klein, K.; Kazerooni, E.; Ellis, J.; Chong, S.; Wesolowski, J. University of Michigan Health System, Ann Arbor, MI*

190. Reduction of Overranging in Helical MDCT by an Adaptive Collimator
Van Der Molen, A.; Joemai, R.; Geleijns, K. Leiden University Medical Center, Leiden, Netherlands*

191. Quantitative Analysis of the Spleen in Patients With Blunt Abdominal Trauma: Is Splenic Volume a CT Indicator of Systemic Shock?
McLaughlin, P.; Coyle, J.; Brennan, C.; O'Connor, O.; Ryan, M.; O'Sullivan, I.; Maher, M. University College Cork, Cork, Ireland*

192. Is IVC Size Predictive of Shock?
Vu, C.^{1}; Ray, C.¹; Vu, T.²; Guzelian, J.¹ 1. University of Colorado Denver, Aurora, CO; 2. Denver Health Medical Center, Denver, CO*

193. Diffusion-Weighted MRI of Abdominopelvic Fluid Collections: Can We Differentiate Abscess from Noninfected Fluid?
Orrin, S.; Lakadamyali, H.; Kayhan, A.; Dahil, F.; Fan, X.; Thomas, S.; Oto, A. The University of Chicago, Chicago, IL*

194. Whole Body MRI—An Effective Total Body Imaging Tool for Metastases Work-Up in Patients With Breast Carcinoma
Singh, J.; Kelkar, D. Deenanath Mangeshkar Hospital and Research Center, Pune, India*

10:00 am-12:00 noon

SS23. Gastrointestinal Imaging: Pancreaticobiliary—Moderators: *J.K. Han, B. Yeh*; Keynotes: Contemporary Imaging of Cystic Pancreatic Lesions—*J.K. Han*; Imaging of Biliary Obstruction—*B. Yeh*

Elizabeth G, Second Level

195. Contrast Enhanced Liver MRI in Patients With Primary Sclerosing Cholangitis: Inverse Appearance of Focal Fibrotic Lesions With Hepatocyte Specific Versus Extracellular Gadolinium Based Contrast Agents
Husarik, D.^{1}; Gupta, R.¹; Ringe, K.²; Boll, D.¹; Merkle, E.¹ 1. Duke University Medical Center, Durham, NC; 2. Medical School of Hannover, Hannover, Germany*

196. Utility of Gd-EOB-DTPA Enhanced T1-Weighted MR Cholangiography in Diagnosis of Biliary Ductal Diseases: Initial Experience
Ji, H.; Maetani, T.; Yucel, K. Tufts Medical Center, Boston, MA*

197. Use of 3D and 4D Volume Acquisition Ultrasound of the Gallbladder for Assessment of Gallbladder Dyskinesia
Irshad, A.; Lewis, M.; Ackerman, S.; Anis, M.; Hashmi, A.; Campbell, A. Medical University of South Carolina, Charleston, SC*

198. Gallstone Detection in vitro at Dual-Energy Compared to Conventional CT
Tran, D.^{1}; Wang, Z.¹; Benedetti, N.¹; Prevrhal, S.¹; Yeh, B.² 1. UCSF, San Francisco, CA; 2. San Francisco VAMC, San Francisco, CA*

199. Diffusion Weighted MRI in Acute Pancreatitis
Thomas, S.; Kayhan, A.; Lakadamyali, H.; Yacoub, J.; Oto, A. University of Chicago, Chicago, IL*

200. Malignant Potential of Mucinous Cystic Neoplasm of the Pancreas: Utility of Size as a Biomarker
Rezai, P.; Galizia, M.; Tochetto, S.; Miller, F.; Yaghmai, V. Northwestern University, Chicago, IL*

201. Prevalence and Significance of Periceliac Stranding on Multidetector CT in Asymptomatic Patients
Munir, R.; Aslam, R.; Yeh, B. San Francisco VA Medical Center, San Francisco, CA*

202. Diffusion Weighted Imaging of the Abdomen: Comparing Artifacts in Different Techniques Using 1.5T and 3T Magnets
Jalili, M.^{1}; Sefidbakht, S.^{1,2}; Quane, L.¹; Saremi, F.¹ 1. University of California Irvine, Orange, CA; 2. Shiraz University of Medical Sciences, Shiraz, Iran*

203. Interpatient Variability of Enhancement of Five Abdominal Organs in Triphasic MDCT
Liu, Y.; Shin, L.; Jeffrey, R.; Kamaya, A. Stanford University, Los Altos, CA*

10:00 am-11:30 am

SS24. Neuroradiology: Imaging and Clinical Outcomes—Moderators: *D. Nguyen, P. Kranz*; Keynote: Advanced CT and MR Imaging of Acute Stroke Infarct Core and Ischemic Penumbra: Where Do We Stand?—*P. Schaefer*

Elizabeth F, Second Level

204. Use of MRI Criteria for Predicting Successful Trans-Sphenoidal Surgery of Pituitary Macroadenomas
Boxerman, J.^{1,2}; Rogg, J.^{1,2}; Donahue, J.^{1,2}; Doberstein, C.^{1,2} 1. Rhode Island Hospital, Providence, RI; 2. Brown University, Alpert Medical School, Providence, RI*

205. Outcomes of Intracranial Aneurysms Monitored by CT Angiography
Guo, Y.; Young, N.; Dorsch, N.; Kang, A.; Rubin, G. Westmead Hospital, Sydney, Australia*

206. Iron Deposition in the Basal Ganglia: A Longitudinal Quantitative MRI Study
Honce, J.; Kido, D.; Oyoyo, U. Loma Linda University Medical Center, Loma Linda, CA*

* Presenting Author

THURSDAY SCHEDULE



207. Carotid mm—Stenosis: What is the Threshold that Determines Cerebrovascular Symptoms?

Saba, L.; Sanfilippo, R.; Atzeni, M.; Ribuffo, D.; Montisci, R.; Mallarini, G. Azienda Ospedaliero Universitaria, Cagliari Sardegna, Italy*

208. Routine CTA of the Neck in Trauma: Yes We Can, But at What Cost?
Hadley, J.1;* *Braswell, A.2;* *Chatterjee, A.1* 1. *University of Tennessee, Collierville, TN;* 2. *No Institutional Affiliation*

209. Spontaneous Hemorrhage in Intracranial Arachnoid Cysts
Vakhariya, S.1;* *Parmar, H.1;* *Castillo, M.2* 1. *University of Michigan, Ann Arbor, MI;* 2. *University of North Carolina, Chapel Hill, NC*

10:30 am-1:00 pm

Review Course: Musculoskeletal Imaging

Manchester Ballroom, Second Level

Injuries—*D. Blankenbaker*
Funny Looking Bones—*K. Davis*
Soft Tissue Tumors—*C. Gaskin*
Bone Tumors—*N. Safdar*
Arthritis—*S. Smith*

12:30 pm-2:00 pm

IC408. Beyond the Visceral Organs—The Mesentery and Peritoneum:
Peritoneal Spaces: Emphasis on Compartmentalization of the Perihepatic
Space—*P. Min;* Vasculature and Improved Abdominopelvic Diagnosis—
B. Yeh; Retroperitoneal Spaces—*J. Brink*

Douglas A, Lobby Level

IC409. CT and PET/CT: SPN, Lung Cancer and Other Thoracic
Malignancies—*J. Bruzzi, E. Rohren, J. Ko*

Douglas B, Lobby Level

IC410. Emergency Radiology: Simplifying the Diagnosis of Complex
Musculoskeletal Injuries: Simplifying Intra-Articular Calcaneus
Fractures—*O.C. West;* Less Common and Sometimes Confusing Injuries
in and About the Hip—*L. Rogers;* Simplifying Radiographic Indicators of
Major Ligamentous Injuries of the Knee—*J. Yu*

Douglas C, Lobby Level

IC411. NonInvasive Vascular Neuroimaging: Ultrasound, CT
Angiography and MR Angiography—*J. Gemmete, D. Kim, B. Huang*

Elizabeth G, Second Level

IC412. Contrast-Enhanced Ultrasound in Radiology—Where Are We in
2010: Physics and Safety of Bubbles, Instrumentation, Monitoring
Angiogenesis, and Future Innovations—*P. Burns;* The Clinical Role for
CEUS in Abdominal/Pelvic Imaging—*S. Wilson*

Elizabeth H, Second Level

2:30 pm-5:00 pm

Review Course: Neuroradiology

Manchester Ballroom, Second Level

Head and Neck—*M. Michel*
Spine—*J. Anderson*
Potpourri—*C. Glastonbury*
Intracranial Tumors—*C.D. Phillips*
Vascular—*M. Strother*

3:00 pm-4:30 pm

IC413. Thoracic PET/CT: Interpretation Predicaments and Future
Developments—*O. Mawlawi, J. Erasmus, M. Truong, T. Wong*

Elizabeth F, Second Level

IC414. Medical Professionalism—*G. Butler;* Beyond Substance Abuse:
Stress, Burnout, and Depression—*S. Brown* (2009 Berlin Scholar)

Randle A, Fourth Level

IC415. Emergency Radiology: Current Concepts in Thoracic and
Abdominal Trauma: MDCT of Thoracic Trauma—*R. Novelline;* MDCT of
Splenic Trauma: New Concepts—*K. Shanmuganathan;* MDCT of Bowel
and Mesenteric Injuries—*J. Soto*

Douglas C, Lobby Level

IC416. Renal Sonography: Renal Lesions Hiding in Plain Sight—
B. Hashimoto; Duplex and Color Doppler of the Kidneys—*S. Teefey*

Douglas A, Lobby Level

3:00 pm-5:00 pm

SS25. Genitourinary Imaging: Pelvis—Moderators: *D. Grand, A. Oto;*
Keynote: MR Imaging of Acute Abdominal Pain in Pregnant Patients—
A. Oto

Elizabeth G, Second Level

210. Added Value of Pelvic Ultrasound Immediately Following MDCT in
Female Patients With Abdominal/Pelvic Pain: Is it Always Necessary?
Yitta, S.1;* *Mausner, E.1;* *Im, A.1;* *Hecht, E.2;* *Bennett, G.1* 1. *NYU, New York, NY;* 2. *University of Pennsylvania, Philadelphia, PA*

211. Is CT a Reliable Diagnostic Modality in Detecting Placenta Injuries in
the Setting of Acute Trauma?

Bollepalli, S.;* *Srinivas, G.;* *Manriquez, M.;* *Britt, L.;* *Drachman, D. Maricopa Medical Center, Phoenix, AZ*

212. Prevalence of Microlithiasis and its Association With Cancer in the
Contralateral Testis in Patients With a History of Orchidectomy for
Testicular Cancer

Kobayashi, K.1;* *Jackson, J.2;* *Eftekhari, F.2* 1. *Michael E. DeBakey VA Medical Center, Houston, TX;* 2. *MD Anderson Cancer Center, Houston, TX*

213. Adenoma Malignum of the Uterine Cervix: Imaging Features With
Clinicopathologic Correlation in 22 Patients

Park, S.1;* *Moon, M.1;* *Lee, Y.1;* *Kim, J.2;* *Cho, K.2;* *Lee, J.3* 1. *Cheil General Hospital and Women's Healthcare Center, Kwandong University College of Medicine, Seoul, Korea;* 2. *Asan Medical Center, University of Ulsan, Seoul, Korea;* 3. *Ulsan University Hospital, University of Ulsan, Ulsan, Korea*

214. Incidental Adnexal Lesions Detected at Low-Dose Noncontrast CT in
Asymptomatic Peri- or Post-Menopausal Women

Hanson, M.;* *Pickhardt, P.;* *Kim, D. University of Wisconsin School of Medicine and Public Health, Madison, WI*

215. Manifestations of Atypical Metastases of Prostate Cancer: A 10 Year
Retrospective Review

Vinjamoori, A.1,2;* *Ramaiya, N.2;* *Jagannathan, J.2;* *Van den Abbeele, A.2* 1. *Harvard Medical School, Boston, MA;* 2. *Dana Farber Cancer Institute, Boston, MA*

THURSDAY SCHEDULE



216. The Comparison of Radiological Response Versus Biochemical Response in Ovarian Cancer Patients Receiving Chemotherapy During Phase II Trials

Ma, X.^{1,2}; Guo, M.²; Yap, J.²; Jagannathan, J.²; Matulonis, U.²; Harris, G.¹; Ramaiya, N.²* 1. Massachusetts General Hospital, Boston, MA; 2. Dana-Farber Cancer Institute, Boston, MA

217. Outcome of Early First-Trimester Pregnancies (<6 weeks 2 days) With Slow Embryonic Heart Rate

Arleo, E.; Troiano, R.* NY Presbyterian Hospital-Weill Cornell Medical Center, New York, NY

218. Prostate MRI and Surgical Planning in Robotic Assisted Laparoscopic Prostatectomy (RALP)

McClure, T.; Margolis, D.; Thomas, A.; Raman, S.; Reiter, R.* University of California, Los Angeles, Los Angeles, CA

219. MRI of Small Adnexal Masses

Narayanan, P.^{1}; Sohaib, A.²; Sahdev, A.³; Rockall, A.³; Reznak, R.³* 1. Chelsea and Westminster Hospital, London, United Kingdom; 2. Royal Marsden Hospital, London, United Kingdom; 3. Barts and the London NHS Trust, London, United Kingdom

3:00 pm-5:00 pm

SS26. Musculoskeletal Imaging: Ultrasound and Interventions—Moderators: *W. Morrison, D. Blankenbaker*; Keynote: Musculoskeletal Ultrasound Interventions: Moving Beyond Ordinary—*D. Blankenbaker*

Douglas B. Lobby Level

220. Dynamic Ultrasonography in Evaluation of Muscular Trauma

Nath, A.; Bouras, R.* Khoula Hospital, Muscat, Oman

221. Ultrasound of Distal Triceps Brachii Tendon Tear

Downey, R.; Jacobson, J.; Tran, N.; Fessel, D.; Matta, N.; Chen, N.* University of Michigan, Ann Arbor, MI

222. An Update on Use of Ultrasound in Osteomyelitis and Importance of Power Doppler and Correlation With MRI

Nath, A.; Sethu, A.; Mahrouqi, K.* Khoula Hospital, Muscat, Oman

223. Ultrasound-Guided Tenotomy of the Patellar Tendon: Prognostic Value of Pre-Procedure Ultrasound Findings and Symptoms

Kanaan, Y.; Jamadar, D.; Jacobson, J.; Caoili, E.; Housner, J.; Northway, R.; Pujalte, G.* University of Michigan, Ann Arbor, MI

224. Sonographic Assessment of the Anterior Oblique Ligament of the Trapeziometacarpal Joint in Cadavers and Asymptomatic Volunteers

Chiavaras, M.¹; Harish, S.^{1}; Popowich, T.¹; Wainman, B.²; Oomen, G.²; Bain, J.²* 1. St. Joseph's Healthcare/McMaster University, Hamilton, Canada; 2. McMaster University, Hamilton, Canada

225. Diagnostic Ultrasound as an Essential Screening Procedure in the Detection of Nonradiopaque Foreign Bodies in the Musculoskeletal System and Importance of Color Power Doppler

Nath, A.; Sethu, A.* Khoula Hospital, Muscat, Oman

226. Utility of High Resolution Ultrasound in Evaluation of the Common Peroneal Nerve in Patients With Foot Drop

DuBois, D.; Grant, T.; Omar, I.* Feinberg School of Medicine, Northwestern University, Chicago, IL

227. Fluoroscopic Guided Steroid Injection of the Proximal Hamstring Attachment for the Treatment of Tendinitis in Athletes

Kumaravel, M.; Punjwani, N.; Amanullah, F.; Ramos, J.* University of Texas at Houston, Houston, TX

228. CT Guided Percutaneous Core Needle Biopsy of Musculoskeletal Lesions: Factors Associated With Biopsy Specificity, Accuracy and Efficacy


Omura, M.; Motamedi, K.; UyBico, S.; Nelson, S.; Seeger, L.* UCLA, Los Angeles, CA

229. Core Needle Biopsy of Musculoskeletal Lesions: Characterizing Non-Diagnostic Lesions

Rissmiller, J.; Hochman, M.; Goldsmith, J.; Anderson, M.; Gebhardt, M.; Wu, J.* Beth Israel Deaconess Medical Center, Boston, MA

230. Which Is Superior? A Comparison of Anteromedial and Lateral Patellofemoral Approaches For Knee Injection

Rutkowski, A.; Davis, K.; Blankenbaker, D.; Tuite, M.; Haaland, B.* University of Wisconsin Hospital, Madison, WI



FRIDAY, MAY 7



6:00 am–3:30 pm
Speaker Preview Room

Molly A/B, Second Level

6:30 am–2:00 pm
Registration

Elizabeth Foyer, Second Level

7:00 am–1:00 pm
Electronic Exhibits

Randle D/E, Fourth Level

7:00 am–1:00 pm
Case-Based Imaging Review Course
There is an additional fee to attend this course.

Manchester Ballroom, Second Level

9:30 am–10:30 am
Coffee Break

Manchester Foyer, Douglas Foyer, Elizabeth Foyer

2:00 pm–4:30 pm
Case-Based Imaging Review Course
There is an additional fee to attend this course.

Manchester Ballroom, Second Level

*IC=Instructional Course
SS=Scientific Session*



ARRS
2011
CHICAGO
ANNUAL MEETING ■ MAY 1-6

SAVE THE DATE
Hyatt Regency Chicago

Future ARRS Annual Meetings:

- April 29–May 4, 2012
Vancouver Convention Center
Vancouver, BC, Canada
- April 14–19, 2013
Marriott Wardman Park Hotel
Washington, DC

FRIDAY SCHEDULE



7:00 am-8:00 am

Power Hour: Neuroradiology—*C. Glastonbury, moderator*

Randle B, Fourth Level

- E499. Radiology of Ataxia—*S. Kanekar*
E509. Radiation Necrosis: When to Suspect and How to Diagnose by Imaging—*P. Borghei*
E524. Enhancement-Perfusion Mismatch is Useful in Differentiation of Primary CNS Lymphomas from Other Enhancing Malignant Tumors of the Brain—*R. Mangla*
E528. An Image-Based Approach to MR Artifacts in Neuroradiology—*J. Morelli*
E530. Cavernous Sinus Pathology: Characteristic Findings and Clinically Relevant Differential Diagnoses—*G. Gill*
E549. The Clivus: from Embryology and Anatomy to Pathology—*G. Dhillon*
E565. Cerebrospinal Fluid Leaks: Work Up and Diagnostic Imaging in 2009—*B. Rodgers*
E586. CT-Guided Cervical Nerve Root Blocks: Tips, Traps and Contrast Utilization—*J. Hoang*

7:00 am-8:00 am

Power Hour: Ultrasound—*M. Dighe, moderator*

Randle A, Fourth Level

- E207. Clinical Mimickers of Lower Extremity Deep Venous Thrombosis: Ultrasound Diagnosis—*G. Gunabushanam*
E277. The Role of Ultrasound Fusion Imaging in Abdominal Interventions—*H. Tchelepi*
E340. Fetal Cardiac Anomalies—Recent Advances in Ultrasonographic Evaluation: A Pictorial Review With Pathological Correlation—*P. Rajiah*
E347. Hemorrhagic Ovarian Cysts, Endometriomas, and Cystic Teratomas: Keys to Diagnosis and Management of these Common "Complex" Ovarian Cysts—*L. Shah-Patel*
E367. Segmental Testicular Infarction—*P. Saxon*
E392. Imaging the Endometrium: Pearls and Pitfalls—*A. Sunnapwar*
E570. Carotid Artery Doppler Ultrasound: Pearls and Pitfalls With Multimodality Comparative Imaging—*V. Dogra*

7:30 am-10:00 am

Review Course: Genitourinary Imaging

Manchester Ballroom, Second Level

- Male Pelvis—*D. Casalino*
Kidney/Retroperitoneum—*E. Remer*
Female Pelvis—*C. Peterson*
Collecting System, Ureter, Bladder—*M. Hartman*
Miscellaneous—*D. Baumgarten*

8:00 am-9:30 am

- IC501. Radiographs and CT: Back to the Basics (chest imaging)—*J. Shepard, A. Rubinowitz, S. Copley, S. Rossi*

Douglas C, Lobby Level

* Presenting Author

- IC502. Exposure to Low Dose Radiation from Medical Imaging—*R. Fazel; Measuring the Quality of Life Effects of Diagnostic Tests—S. Swan*

Elizabeth H, Second Level

- IC503. Emergency Radiology: Neuroradiology, Head and Neck Emergencies—Acute Head and Neck Infections—*W. Kubal; MDCT of Cranio-Facial Trauma—M. Bernstein; Neck CTA in Trauma—F. Munera*

Douglas A, Lobby Level

- IC504. A Basic Review of Brain Tumors and New Entities According to the WHO Classification—*K. Salzman, M. Omojola*

Elizabeth G, Second Level

- IC505. Gynecologic Ultrasound: Update on Ultrasound Evaluation of the Endometrium—*U. Hamper; A Practical Approach to Ultrasound Evaluation of Pelvic Masses—L. Scoutt*

Douglas B, Lobby Level

10:00 am-11:30 am

- IC506. Contrast Materials—Critical Update: Contrast Induced Nephropathy—*B. Herts; Allergic Reactions to Contrast Material—J. Ellis; Nephrogenic Systemic Fibrosis—P. Kuo (abdominal imaging)*

Douglas A, Lobby Level

- IC507. Imaging of the Post-Treatment Neck With CT and MRI—*C. Glastonbury, D. Williams*

Elizabeth H, Second Level

- IC508. Pearls and Pitfalls in Obstetric Ultrasound: First Trimester—*T. Angtuaco; Second and Third Trimesters Part 1—L. Romine; Second and Third Trimesters Part II—D. Pretorius*

Douglas C, Lobby Level

10:00 am-12:00 noon

- SS27. Musculoskeletal Imaging: Upper and Lower Extremity: MR and CT Advances—Moderators: *M. Robbin, A. Gentili; Keynote: Technical Advances in Imaging of the Knee—A. Gentili*

Elizabeth F, Second Level

231. Indirect MR Arthrography of the Shoulder for Evaluation of Labral Pathology
Vogelius, E.; Robbin, M.; Young, P.; Shishani, Y.; Gobezie, R. UH Case Medical Center, Cleveland, OH*

232. Comparison of 3 Tesla MR Versus 3 Tesla MR Arthrography of the Hip for Detection of Acetabular Labral Tears in the Same Patient Population
Magee, T. NSI, Satellite Beach, FL*

233. Is Conventional MRI as Accurate as MR Arthrography of the Hip?
Strickland, C.; Blankenbaker, D.; Davis, K.; De Smet, A.; Keene, J. University of Wisconsin, Madison, WI*

234. Accuracy of 3 Tesla 3DFSE-XETA Isotropic Imaging Versus Conventional Imaging as Compared with Arthroscopy
Magee, T. NSI, Satellite Beach, FL*

235. Comparison of 3D Versus 2D Fast Spin Echo Imaging for Evaluation of Articular Cartilage in the Knee on a 3 Tesla System
Haims, A.; Milewski, M.; Essig, D.; Medvecky, M.; Katz, L.; Moukaddam, H. Yale University, New Haven, CT*

FRIDAY SCHEDULE



236. Clinical Evaluation of the Knee Using Fat-Suppressed SPACE: Three-Dimensional, Isotropic Proton Density-Weighted MR Imaging at 1.5T
Krug, D.^{1}; Casal, S.²; Harris, B.¹; Major, N.³* 1. *Duke University Medical Center, Durham, NC*; 2. *VA Medical Center, Durham, NC*; 3. *Hospital of the University of Pennsylvania, Philadelphia, PA*

237. Comparison of 3D Isotropic Resolution Fast Spin-Echo MR Imaging With Conventional 2D MR Imaging of Knee Ligaments and Menisci at 3.0 T
Subhas, N.; Kao, A.; Freire, M.; Polster, J.; Obuchowski, N.; Winalski, C.* *Cleveland Clinic, Cleveland, OH*

238. Evaluation of Image Quality of MR of the Knee With MR Safe Knee External Fixation Device at 3 Tesla
Mehta, N.^{1}; Elsisy, P.¹; Chien, A.¹; Kjellin, I.²; Unis, J.¹; Oyoyo, U.¹; Holshouser, B.¹; Cheng, W.¹* 1. *Loma Linda University Medical Center, Loma Linda, CA*; 2. *No Institutional Affiliation*

239. Pelvic Fractures: in the CT Era, Is There a Role of Radiography?
Ali, Z.; Daffner, R.; Smith, B.* *West Penn Allegheny Health System, Pittsburgh, PA*

240. Staging of Dupuytren's Disease: Novel Use of 3T MR Scanning Validated With Immunohistochemistry Measures Disease Extent and Activity
Parmar, V.^{1}; Bhatti, W.²; Hutchinson, C.¹; Muir, L.¹; Mcgrouther, D.¹; Bayat, A.¹* 1. *University of Manchester, Manchester, United Kingdom*; 2. *Wythenshawe Hospital, Manchester, United Kingdom*

10:30 am-1:00 pm

Review Course: Chest Imaging

Manchester Ballroom, Second Level

Radiographic Signs—*G. Abbott*
Congenital Abnormalities—*E. Donnelly*
Autoimmune/Idiopathic—*D. Manos*
Trauma/Iatrogenic—*E. Moore*
Diffuse Lung Disease—*A. Sharma*

1:00 pm-2:30 pm

IC509. Radiation Issues Related to CT Utilization—*M. Parker*; Strategies to Reduce CT Dose—*M. Gunn*

Douglas B, Lobby Level

IC510. Imaging of Children and Adults With Epilepsy—*N. Salamon, R. Lee*

Elizabeth G, Second Level

1:00 pm-3:00 pm

SS28. Genitourinary Imaging: Renal/Adrenal—Moderators: *E. Remer, V. Dogra*; Keynote: Cystic Renal Masses: Beyond Benign Versus Malignant—*E. Remer*

Douglas D, Lobby Level

241. MASS Criteria: A Contrast Enhanced CT Response Assessment and Predictive Tool in Metastatic Renal Cell Carcinoma
*Smith, A.; Remer, E.; Lieber, M.; Rini, B.; Shah, S.** *Cleveland Clinic, Broadview Heights, OH*

242. Outcomes of Renal Lesions Designated Bosniak 3 Cysts
Smith, A.; Remer, E.; Portier, B.; Shah, S.; Zhou, M.; Herts, B.* *Cleveland Clinic, Cleveland, OH*

243. Prognostic Significance of Adrenal Gland Morphology at Baseline CT in Three Common Malignancies
Meehan, C.; Fuqua, III, J.; Reiner, A.; Moskowitz, C.; Schwartz, L.; Panicek, D.* *Memorial Sloan-Kettering Cancer Center, New York, NY*

244. How Much Dose Can Be Saved in Three-Phase CT Urography? A Combination of Normal Dose Corticomedullary Phase With Low-Dose Unenhanced and Excretory Phases
Dahlman, P.^{1}; van der Molen, A.²; Raland, H.¹; Magnusson, A.¹* 1. *Department of Radiology, Uppsala University Hospital, Uppsala, Sweden*; 2. *Department of Radiology, Leiden University Medical Center, Leiden, Netherlands*

245. Evaluation of Response Criteria in Solid Tumors (RECIST) 1.1: Do New Guidelines Change Disease Status in Patients With Renal Cell Carcinoma?
Ziemlewicz, T.; Bashir, M.; Moshiri, S.; Jaffe, T.* *Duke University, Durham, NC*

246. How Much Radiation Dose is Given in CT Urography? A Multicenter Survey—Preliminary Results
Van Der Molen, A.^{1}; Otero-Garcia, M.²; Salvador-Izquierdo, R.³* 1. *Leiden University Medical Center, Leiden, Netherlands*; 2. *Complejo Hospitalario Universitario de Vigo (CHUVI), Vigo, Spain*; 3. *Hospital Clinic de Barcelona, Barcelona, Spain*

247. Effect of Intravenous Gadolinium-DTPA on Renal Diffusion Weighted Images
Sefidbakht, S.; Santa Maria, J.; Hom, S.; Quane, L.; Jalili, M.; Saremi, F.* *University of California Irvine, Orange, CA*

248. Efficacy of CT-Guided Cryoablation of Renal Tumors
Paspulati, R.; Wong, V.; Haaga, J.; Ponsky, L.* *University Hospital, Case Western Reserve University, Solon, OH*

249. CT-Guided Fine Needle Aspiration Biopsies of Renal Masses With the Use of Cytopathological Rapid On-Site Evaluation
Harri, P.; Lewis, M.; Mittal, P.; Ibraheem, O.; Bowen, M.; Torres, W.* *Emory University, Atlanta, GA*

250. CT Urography in the Diagnosis of Bladder Cancer in High-Risk Patients
Otero-Garcia, M.^{1}; Van der Molen, A.²* 1. *Complejo Hospitalario Universitario de Vigo (CHUVI), Vigo-Pontevedra, Spain*; 2. *Leiden University Medical Center, Leiden, New Caledonia*

2:00 pm-4:30 pm

Review Course: Ultrasound

Manchester Ballroom, Second Level

Obstetrics—*B. Hertzberg*
Gynecology—*O. Baltarowich*
Abdomen—*U. Hamper*
Small Parts—*D. Rubens*
Vascular—*L. Scouff*

SUBSPECIALTY TRACKS




Breast Imaging	page 57
Business and Practice Management	page 57
Cardiac Imaging	page 58
Chest/Pulmonary Imaging	page 59
Education and Competencies	page 60
Emergency Radiology	page 61
Gastrointestinal Imaging	page 62
Genitourinary Imaging	page 63
Musculoskeletal Imaging	page 64
Neuroradiology	page 66
Nuclear Medicine	page 67
Pediatric Imaging	page 68
Ultrasound	page 69
Vascular and Interventional Radiology	page 69

Your CME Resource



Earn 21.5 hours of CME credits



Categorical Course Syllabus

Members: **\$80**
Nonmembers: **\$215**

Earn 17.25 hours of CME credits



Categorical Course Syllabus

Members: **\$45**
Nonmembers: **\$173**

Earn 22 hours of CME credits



Categorical Course Syllabus

Members: **\$45**
Nonmembers: **\$220**

Visit the ARRS Booth #315 in the Exhibit Hall to Purchase Your Copies Today.

SUBSPECIALTY TRACKS: BREAST IMAGING



BREAST IMAGING

Who Should Attend: Radiologists, radiologists-in-training and other health professionals With an Interest in the application of the radiologic sciences to the detection and management of breast diseases.

Goals and Objectives: Upon completion of the breast imaging course track, the participant should be able to determine the appropriate use of computer-aided detection, core biopsy, sonography, MR as well as have a better understanding of the ethical and legal aspects of imaging of breast cancer. In addition, the participant should have gained proficiency in recognizing the imaging features and constructing an imaging differential diagnosis for various breast diseases.

Monday, May 3

7:00 am-8:00 am

Power Hour: Breast Imaging—*G. Newstead, moderator*

Randle B, Fourth Level

8:00 am-9:30 am

IC101. Breast Ultrasound: Basics Principles and Future—*S. Raza, M. Kettler*

Douglas C, Lobby Level

10:30 am-12:00 noon

IC106. Breast Nuclear Medicine: PEM and PET—*D. Mankoff, G. Mercier*

Douglas A, Lobby Level

1:00 pm-2:30 pm

IC112. Optimizing PET/CT Imaging Protocols, PET/CT for Breast Cancer and Dementia—*T. Wong, E. Akin, A. Siegel*

Elizabeth H, Second Level

1:00 pm-3:00 pm

SS3. Breast Imaging: MRI—Moderators: *D. Rausch, L. Salkowski*; Keynote: Breast MRI Controversies—*D. Ikeda*

Douglas B, Lobby Level

4:00 pm-5:30 pm

IC115. Basic Screening Principles—*D. Georgian-Smith*; Controversies on High-Risk Lesions at Core Biopsy: Radiology and Pathology Perspectives—*T. Lawton*

Elizabeth H, Second Level

Tuesday, May 4

8:00 am-9:30 am

IC202. Basic Principles of Breast Imaging: The Risks of Breast Density Challenging Cases: An Interactive Review—*J. Harvey, L. Bassett*

Douglas B, Lobby Level

10:00 am-12:00 noon

SS8. Breast Imaging: Novel Techniques—Moderators: *J. Leung, A. Nees*; Keynote: Advances in Multimodal Breast Imaging—*G. Newstead*

Elizabeth G, Second Level

1:00 pm-3:00 pm

SS12. Breast Imaging: Biopsy and Breast Imaging Outcomes—Moderators: *A. Campbell, T. Stephens*; Keynote: Imaging Guided Needle Biopsies of the Breast: A Moving Target—*V. Jackson*

Elizabeth H, Second Level

4:00 pm-5:30 pm

IC211. Breast MRI: Basic Clinical Principles and Navigating the New ACR Accreditation Breast MR Program—*C. Comstock, M. Boston*

Douglas A, Lobby Level

Wednesday, May 5

7:30 am-10:00 am

Review Course: Breast Imaging

Manchester Ballroom, Second Level

1:00 pm-2:30 pm

IC312. Digital Breast Tomosynthesis—*D. Gur, M. Zuley, J. Sumkin*

Elizabeth G, Second Level

4:00 pm-5:30 pm

IC316. Ethical and Medical-Legal Issues in Radiology—*P. Kornguth, L. Berlin*

Elizabeth H, Second Level

BUSINESS AND PRACTICE MANAGEMENT

Who Should Attend: Radiologists, radiologists-in-training and other health professionals With an Interest in the business and management of radiology practice.

Goals and Objectives: Upon completion of the business and practice management course track, the participant will be able to understand and respond to contemporary issues and challenges facing radiology, including but not limited to changes in reimbursement and payer regulations, medical liability, turf battles, patient surveys, physician productivity, ethics, and contemporary practice issues such as practical tips for optimizing the practice of radiology, including but not limited to the Introduction of new services such as cardiac CTA and MRI screening.

Sunday, May 2

1:30 pm-5:00 pm

Business and Practice Management Seminar

Elizabeth G, Second Level

Monday, May 3

8:00 am-9:30 am

IC102. Cardiac CTA: Setting up a Cardiac Service; Reimbursement Issues—*D. Dowe*; Technical Considerations and Principles of Cardiac CTA—*S. Abbara*; Protocols and Reconstructions—*U.J. Schoepf*

Elizabeth G, Second Level

IC104. Malpractice Issues in Radiology: Update 2010—*L. Berlin*

Douglas A, Lobby Level

SS1. Efficacy, Education and PACS: Safety and Communication—Moderators: *J. Eng, R. Agarwal*; Keynote: Improving Communication of Radiology Results—*C. Kahn*

Connaught, Third Level

9:30 am-10:30 am

Caldwell Lecture: Benjamin Chu, MD, MPH, President, Kaiser Permanente Southern California Region

Douglas B, Lobby Level

For a listing of abstracts included in the scientific sessions and power hours, please refer to the daily schedule. The categorical course schedule can be found on pages 11-12 and the case-based review schedule can be found on page 13.

SUBSPECIALTY TRACKS: CARDIAC IMAGING



10:30 am-12:00 noon

IC109. ABR Update—*G. Becker, J. Crowe, N.R. Dunnick, E. Kazerooni*

Elizabeth H, Second Level

SS2. Efficacy, Education and PACS: Policy and Operations—Moderators: *E. Fraile-Moreno, B. Richmond*; Keynote: Informatics for Operational Efficiency 2.0—*D. Channin*

Randle A, Fourth Level

1:00 pm-2:30 pm

IC113. Overutilization—*J. Thrall, P. Basu*

Elizabeth G, Second Level

Tuesday, May 4

10:30 am-12:00 noon

Categorical Course: Practical Approaches to Common Clinical Conditions: Efficient Imaging (PAC³E)—*Setting the PAC³E of Imaging*

Manchester Ballroom, Second Level

Wednesday, May 5

4:00 pm-5:30 pm

IC316. Ethical and Medical-Legal Issues in Radiology—*P. Kornguth, L. Berlin*

Elizabeth H, Second Level

Thursday, May 6

3:00 pm-4:30 pm

IC414. Medical Professionalism—*G. Butler*; Beyond Substance Abuse: Stress, Burnout, and Depression—*S. Brown* (2009 Berlin Scholar)

Randle A, Fourth Level

For a listing of abstracts included in the scientific sessions and power hours, please refer to the daily schedule. The categorical course schedule can be found on pages 11-12 and the case-based review schedule can be found on page 13.



CARDIAC IMAGING

Who Should Attend: Radiologists, radiologists-in-training and other health professionals With an Interest in the application of the radiologic sciences to the detection and management of diseases of the heart and great vessels.

Goals and Objectives: Upon completion of the cardiac imaging course track, the participant should be able to determine the appropriate use of CT and MR in the management of patients With heart disease. In addition, the participant should have gained proficiency in recognizing the imaging features and constructing an imaging differential diagnosis for various cardiovascular diseases.

Sunday, May 2

10:30 am-12:30 pm

Categorical Course: Practical Approaches to Common Clinical Conditions: Efficient Imaging (PAC³E) *Setting the PAC³E of Imaging*

Manchester Ballroom, Second Level

Monday, May 3

8:00 am-9:30 am

IC102. Cardiac CTA: Setting up a Cardiac Service; Reimbursement Issues—*D. Dowe*; Technical Considerations and Principles of Cardiac CTA—*S. Abbbara*; Protocols and Reconstructions—*U.J. Schoepf*

Elizabeth G, Second Level

10:30 am-12:00 noon

IC107. Cardiac CTA: Anatomy—*S. Patel*; Anomalies, Bypass Grafts and Stents—*G. Reddy*; Clinical Cases: Tips and Tricks—*S. Teague*

Douglas C, Lobby Level

1:00 pm-2:30 pm

IC111. Cardiac CTA: Assessment of Noncoronary Cardiac Disease—*G. Gladish*; Adult Congenital Heart Disease—*R. Gilkeson*; Chest Pain in the Emergency Department—*C. White*

Douglas C, Lobby Level

4:00 pm-5:30 pm

IC116. Cardiac MRI: The Basics—*M. Atalay*; Cardiomyopathies and Dysplasias—*J. Jedy*; Ischemic Heart Disease: Perfusion, Function, Viability—*M. Krishnam*

Douglas B, Lobby Level

Tuesday, May 4

10:00 am-12:00 noon

SS9. Cardiopulmonary Imaging—Moderators: *S. Patel, M. Atalay*; Keynote: Late Gadolinium Enhancement Cardiac MRI—*M. Atalay*

Elizabeth H, Second Level

1:00 pm-3:00 pm

SS13. Cardiopulmonary Imaging—Moderators: *R. Munden, M. Parker*; Keynote: CT Radiation Risks: What Patients Really Need to Know—*M. Parker*

Elizabeth G, Second Level

SUBSPECIALTY TRACKS: CHEST/PULMONARY IMAGING



4:00 pm-6:30 pm

Review Course: Cardiovascular Imaging

Manchester Ballroom, Second Level

Wednesday, May 5

7:00 am-8:00 am

Power Hour: Cardiopulmonary Imaging—*C. Meyer, moderator*

Randle B, Fourth Level

10:00 am-12:00 noon

SS17. Cardiopulmonary Imaging—Moderators: *B. Sundaram, M. Truong*;

Keynote: Update on Imaging of the Solitary Pulmonary Nodule—*M. Truong*

Elizabeth G, Second Level

CHEST/PULMONARY IMAGING

Who Should Attend: Radiologists, radiologists-in-training and other health professionals With an Interest in the application of the radiologic sciences to the evaluation and treatment of thoracic diseases.

Goals and Objectives: Upon completion of the chest/pulmonary imaging course track, the participant should be able to Incorporate the proper use of various imaging modalities in the diagnosis and treatment of adult and pediatric patients in both the emergency and nonemergency setting. In addition, the participant should have gained proficiency in recognizing the imaging features and constructing an imaging differential diagnosis for various thoracic diseases.

SUNDAY, MAY 2

8:00 am-10:00 am/1:30 pm-3:30 pm

Categorical Course: Practical Approaches to Common Clinical Conditions: Efficient Imaging (PAC³E) *Setting the PAC³E of Imaging*

Manchester Ballroom, Second Level

MONDAY, MAY 3

8:00 am-9:30 am

IC103. PET/CT for Solitary Pulmonary Nodule, Lung Cancer, and After Thermal Ablation—*S. Nayak, H. Agress, D. Yoo*

Elizabeth F, Second Level

10:30 am-12:00 noon

IC110. Pulmonary Interventions: AVMs and Bronchial Artery Embolization; Diagnosis—*A. Funaki*; Pulmonary Embolization—*C. Burke*; Bronchial Embolization—*B. Funaki*

Elizabeth G, Second Level

For a listing of abstracts included in the scientific sessions and power hours, please refer to the daily schedule. The categorical course schedule can be found on pages 11-12 and the case-based review schedule can be found on page 13.

TUESDAY, MAY 4

10:00 am-12:00 noon

SS9. Cardiopulmonary Imaging—Moderators: *S. Patel, M. Atalay*;
Keynote: Late Gadolinium Enhancement Cardiac MRI—*M. Atalay*

Elizabeth H, Second Level

1:00 pm-3:00 pm

SS13. Cardiopulmonary Imaging—Moderators: *R. Munden, M. Parker*;
Keynote: CT Radiation Risks: What Patients Really Need to Know—*M. Parker*

Elizabeth G, Second Level

Wednesday, May 5

7:00 am-8:00 am

Power Hour: Cardiopulmonary Imaging—*C. Meyer, moderator*

Randle B, Fourth Level

8:00 am-9:30 am

IC302. Radiographic and CT Imaging of Pulmonary Infections: TB/NTMB, Community-Acquired, Immunocompromised—*K. Soo Lee, J. Fishman, L. Ketaj, H.P. McAdams*

Douglas C, Lobby Level

10:00 am-12:00 noon

SS17. Cardiopulmonary Imaging—Moderators: *B. Sundaram, M. Truong*;
Keynote: Update on Imaging of the Solitary Pulmonary Nodule—*M. Truong*

Elizabeth G, Second Level

1:00 pm-2:30 pm

IC313. HRCT Imaging of Lung—*G. Abbott, A. Sharma, M. Gosselin*

Douglas C, Lobby Level

4:00 pm-5:30 pm

IC317. HRCT: Airway and Smoking-Related Lung Disease—*A. Bankier, C. Meyer, J. Kanne, E. Donnelly*

Douglas A, Lobby Level

Thursday, May 6

8:00 am-9:30 am

IC401. CTA of the Thorax: Pulmonary Thromboembolic Disease, Arterial and Venous Malformations, Acute Aortic Syndromes and Postoperative Evaluation of the Aorta—*L. Washington, S. Bhalla, C. Chiles, K. Birchard*

Douglas A, Lobby Level

IC404. Pediatric Large Airway Disease: State of the Art—*E. Lee*; Pediatric Interstitial Lung Disease: State of the Art—*P. Guillerman*; Congenital Lungs: Review—*C. Carrico*

Elizabeth G, Second Level

10:00 am-11:30 am

IC406. Hot Topics in Thoracic Imaging: Radiation Dose, CAD—SPN, PE, Decision Analysis, Dual Source, Dual Energy CT, Functional Imaging—*L. Hurwitz, H. MacMahon, J. Vlahos, J. Goldin*

Douglas C, Lobby Level

SUBSPECIALTY TRACKS: EDUCATION & COMPETENCIES



12:30 pm-2:00 pm

IC409. CT and PET/CT: SPN, Lung Cancer and Other Thoracic Malignancies—*J. Bruzzi, E. Rohren, J. Ko*

Douglas B, Lobby Level

3:00 pm-4:30 pm

IC413. Thoracic PET/CT: Interpretation Predicaments and Future Developments—*O. Mawlawi, J. Erasmus, M. Truong, T. Wong*

Elizabeth F, Second Level

IC415. Emergency Radiology: Current Concepts in Thoracic and Abdominal Trauma: MDCT of Thoracic Trauma—*R. Novelline*; MDCT of Splenic Trauma: New Concepts—*K. Shanmuganathan*; MDCT of Bowel and Mesenteric Injuries—*J. Soto*

Douglas C, Lobby Level

Friday, May 7

8:00 am-9:30 am

IC501. Radiographs and CT: Back to the Basics (chest imaging)—*J. Shephard, A. Rubinowitz, S. Copley, S. Rossi*

Douglas C, Lobby Level

10:30 am-1:00 pm

Review Course: Chest Imaging

Manchester Ballroom, Second Level



EDUCATION & COMPETENCIES

Who Should Attend: Radiologists, radiologists-in-training and other health professionals With an Interest in medical education and maintenance of certification.

Goals and Objectives: Upon completion of the education course track, participants should have a better understanding of adult learning principles and be able to Incorporate practical tips to create an effective learning environment. Participants will be able to write and edit multiple choice questions and develop self assessment modules. In addition, participants will learn how to implement practice programs that will allow them to meet their competency requirements as part of the maintenance of certification program.

Sunday, May 2

8:00 am-12:00 noon

Item-Writing Workshop

Randle A, Fourth Level

1:30 pm-5:00 pm

Education Seminar: Effective Feedback

Elizabeth H, Second Level

Monday, May 3

10:30 am-12:00 noon

IC109. ABR Update—*G. Becker, J. Crowe, N.R. Dunnick, E. Kazerooni*

Elizabeth H, Second Level

SS2. Efficacy, Education and PACS: Policy and Operations—Moderators: *E. Fraile-Moreno, B. Richmond*; Keynote: Informatics for Operational Efficiency 2.0—*D. Channin*

Randle A, Fourth Level

Wednesday, May 5

1:00 pm-2:30 pm

IC314. Radiation Safety (vascular and interventional radiology)—*B. Dixon, K. Ogden, R. Thornton*

Randle A, Fourth Level

4:00 pm-5:30 pm

IC316. Ethical and Medical-Legal Issues in Radiology—*P. Kornguth, L. Berlin*

Elizabeth H, Second Level

Thursday, May 6

3:00 pm-4:30 pm

IC414. Medical Professionalism—*G. Butler*; Beyond Substance Abuse: Stress, Burnout, and Depression—*S. Brown* (2009 Berlin Scholar)

Randle A, Fourth Level

SUBSPECIALTY TRACKS: EMERGENCY/GENERAL RADIOLOGY



Friday, May 7

8:00 am-9:30 am

IC502. Exposure to Low Dose Radiation from Medical Imaging—*R. Fazel*;
Measuring the Quality of Life Effects of Diagnostic Tests—*S. Swan*

Elizabeth H, Second Level

10:00 am-11:30 am

IC506. Contrast Materials—Critical Update: Contrast Induced
Nephropathy—*B. Herts*; Allergic Reactions to Contrast Material—*J. Ellis*;
Nephrogenic Systemic Fibrosis—*P. Kuo* (abdominal imaging)

Douglas A, Lobby Level

1:00 pm-2:30 pm

IC509. Radiation Issues Related to CT Utilization—*M. Parker*; Strategies to
Reduce CT Dose—*M. Gunn*

Douglas B, Lobby Level

EMERGENCY/GENERAL RADIOLOGY

Who Should Attend: Radiologists, radiologists-in-training and other health professionals With an Interest in the use of various imaging modalities to confidently diagnose and manage patients With traumatic and/or nontraumatic cardiovascular, abdominal, musculoskeletal, and head and neck emergencies.

Goals and Objectives: Upon completion of the emergency radiology course track, the participants should be able to optimize their protocols for appropriate and efficient management of patients With traumatic and/or nontraumatic cardiovascular, abdominal, musculoskeletal, and head and neck emergencies.

Sunday, May 2

4:00 pm-5:00 pm

Categorical Course: Practical Approaches to Common Clinical Conditions:
Efficient Imaging (PAC³E) *Setting the PAC³E of Imaging*

Manchester Ballroom, Second Level

Monday, May 3

8:30 am-9:30 am/11:00 am-12:00 noon/4:00 pm-5:00 pm

Categorical Course: Practical Approaches to Common Clinical Conditions:
Efficient Imaging (PAC³E)—*Setting the PAC³E of Imaging*

Manchester Ballroom, Second Level

For a listing of abstracts included in the scientific sessions and power hours, please refer to the daily schedule. The categorical course schedule can be found on pages 11-12 and the case-based review schedule can be found on page 13.

Tuesday, May 4

7:00 am-7:30 am

Categorical Course: Practical Approaches to Common Clinical Conditions:
Efficient Imaging (PAC³E)—*Setting the PAC³E of Imaging*

Manchester Ballroom, Second Level

1:00 pm-2:30 pm

IC208. Acute Bowel—Current Imaging: Bowel Obstruction—*W. Thompson*;
MDCT Techniques and Trauma—*R. Thoeni*; Small Bowel Ischemia and
Obstruction—*C. Menias*; Diverticulitis and Appendicitis—*E. Webb*

Douglas C, Lobby Level

Wednesday, May 5

4:00 pm-5:30 pm

IC320. Pediatric Abdominal Imaging: State of the Art—*R. Goodman*;
Intestinal Obstruction in Children: State of the Art—*L. Fenton*; Neonatal
Abdominal Emergencies: Review—*J. Reid*

Elizabeth G, Second Level

Thursday, May 6

7:00 am-8:00 am

Power Hour: Emergency/General Radiology—*D. Katz, moderator*

Randle B, Fourth Level

8:00 am-9:30 am

IC402. Emergency Radiology: CT Protocols and Techniques: Evolving
Concepts in MDCT Imaging of Abdominal Pain—*S. Anderson*; Imaging the
Obese Patient in the Emergency Department—*M. Gunn*; MDCT in the
Emergency Department: Update Your Protocols—*A. Sodickson*

Douglas C, Lobby Level

10:00 am-11:30 am

SS22. General/Emergency Radiology—Moderators: *K. Klein*; *M. Bruno*;
Keynote: CT Radiation Safety and the Modern Emergency Department—
M. Bruno

Douglas A, Lobby Level

12:30 pm-2:00 pm

IC410. Emergency Radiology: Simplifying the Diagnosis of Complex
Musculoskeletal Injuries: Simplifying Intra-Articular Calcaneus Fractures—
O.C. West; Less Common and Sometimes Confusing Injuries in and About
the Hip—*L. Rogers*; Simplifying Radiographic Indicators of Major
Ligamentous Injuries of the Knee—*J. Yu*

Douglas C, Lobby Level

3:00 pm-4:30 pm

IC415. Emergency Radiology: Current Concepts in Thoracic and Abdominal
Trauma: MDCT of Thoracic Trauma—*R. Novelline*; MDCT of Splenic Trauma:
New Concepts—*K. Shanmuganathan*; MDCT of Bowel and Mesenteric
Injuries—*J. Soto*

Douglas C, Lobby Level

SUBSPECIALTY TRACKS: GASTROINTESTINAL IMAGING



Friday, May 7

8:00 am-9:30 am

IC503. Emergency Radiology: Neuroradiology, Head and Neck Emergencies—Acute Head and Neck Infections—*W. Kubal*; MDCT of Cranio-Facial Trauma—*M. Bernstein*; Neck CTA in Trauma—*F. Munera*

Douglas A, Lobby Level

GASTROINTESTINAL IMAGING

Who Should Attend: Radiologists, radiologists-in-training and other health professionals With an Interest in the application of the radiologic sciences to the evaluation and treatment of diseases of the gastrointestinal system.

Goals and Objectives: Upon completion of the gastrointestinal imaging course track, the participant should be able to incorporate the proper use of CT, MR and PET/CT in the diagnosis and treatment of adult and pediatric patients With diseases of the liver, bowel, pancreas and colon. The participant should understand an organized approach to Interpreting studies for acute gastrointestinal disease, tumor screening, and tumor staging, and should have gained proficiency in recognizing the imaging features and constructing an imaging differential diagnosis for these entities.

Monday, May 3

1:00 pm-3:00 pm

SS4. Gastrointestinal Imaging: CT Radiation Dose—Moderators: *F. Coakley, R. Mezhich*; Keynote: CT Radiation Risk: A Phantom Menace—*R. Mezhich*; CT Radiation Risk: A Clear and Present Danger—*F. Coakley*

Douglas A, Lobby Level

1:00 pm-4:30 pm

Categorical Course: Practical Approaches to Common Clinical Conditions: Efficient Imaging (PAC³E)—*Setting the PAC³E of Imaging*

Manchester Ballroom, Second Level

4:00 pm-5:30 pm

IC114. Pancreatic Imaging: Practical Approach to the Cystic Lesion—*K. Mortelet*; Pitfalls in Pancreatic Imaging—*M. Federle*; Solid Pancreatic Neoplasms—*D. Morgan*

Douglas C, Lobby Level

Tuesday, May 4

7:00 am-8:00 am

Power Hour: Abdominal Imaging—*A. Qayyum, moderator*

Randle B, Fourth Level

7:00 am-10:30 am

Categorical Course: Practical Approaches to Common Clinical Conditions: Efficient Imaging (PAC³E)—*Setting the PAC³E of Imaging*

Manchester Ballroom, Second Level

For a listing of abstracts Included in the scientific sessions and power hours, please refer to the daily schedule. The categorical course schedule can be found on pages 11-12 and the case-based review schedule can be found on page 13.

8:00 am-9:30 am

IC201. Navigating CT and MRI of the Liver: MRI Technique and Diffuse Liver Disease—*J. Leyendecker*; Hepatocellular Tumors—*T. Desser*; Cholangiocarcinoma—*J.K. Han*

Douglas C, Lobby Level

10:00 am-12:00 noon

SS10. Gastrointestinal Imaging: Liver—Moderators: *A. Qayyum, K. Sandrasegaran*; Keynote: State-of-the-Art Imaging of Diffuse Liver Disease—*A. Qayyum*

Douglas B, Lobby Level

1:00 pm-3:00 pm

IC208. Acute Bowel—Current Imaging: Bowel Obstruction—*W. Thompson*; MDCT Techniques and Trauma—*R. Thoeni*; Small Bowel Ischemia and Obstruction—*C. Menias*; Diverticulitis and Appendicitis—*E. Webb*

Douglas C, Lobby Level

4:00 pm-6:00 pm

SS15. Gastrointestinal Imaging: Small and Large Bowel—Moderators: *C. Santillan, R. Aslam*; Keynote: MR and CT Enterography: Indications and Technical Considerations—*C. Santillan*

Elizabeth G, Second Level

Wednesday, May 5

8:00 am-9:30 am

IC301. CT Colonography—Technique, Interpretation and the Future: New Strategies for CTC Interpretation—*J. Yee*; Noncathartic CT Colonography—*M. Zalis*; State-of-the-Art CTC Technique—*D. Kim*; CTC Reimbursement and the Future—*J. Yee*

Douglas A, Lobby Level

10:00 am-12:00 noon

SS18. Gastrointestinal Imaging: Evaluation and Screening for Colorectal Cancer—Moderators: *L. Hinshaw, J. Yee*; Virtual Colonoscopy at the University of Wisconsin: How and Why—*L. Hinshaw*

Elizabeth H, Second Level

4:00 pm-5:30 pm

IC320. Pediatric Abdominal Imaging: State of the Art—*R. Goodman*; Intestinal Obstruction in Children: State of the Art—*L. Fenton*; Neonatal Abdominal Emergencies: Review—*J. Reid*

Elizabeth G, Second Level

Thursday, May 6

7:30 am-10:00 am

Review Course: Gastrointestinal Imaging

Manchester Ballroom, Second Level

8:00 am-9:30 am

IC402. Emergency Radiology: CT Protocols and Techniques: Evolving Concepts in MDCT Imaging of Abdominal Pain—*S. Anderson*; Imaging the Obese Patient in the Emergency Department—*M. Gunn*; MDCT in the Emergency Department: Update Your Protocols—*A. Sodickson*

Douglas C, Lobby Level

SUBSPECIALTY TRACKS: GENITOURINARY IMAGING



10:00 am-12:00 noon

SS23. Gastrointestinal Imaging: Pancreaticobiliary—Moderators: *J.K. Han, B. Yeh*; Keynotes: Contemporary Imaging of Cystic Pancreatic Lesions—*J.K. Han*; Imaging of Biliary Obstruction—*B. Yeh*

Elizabeth G, Second Level

12:30 pm-2:00 pm

IC408. Beyond the Visceral Organs—The Mesentery and Peritoneum: Peritoneal Spaces: Emphasis on Compartmentalization of the Perihepatic Space—*P. Min*; Vasculature and Improved Abdominopelvic Diagnosis—*B. Yeh*; Retroperitoneal Spaces—*J. Brink*

Douglas A, Lobby Level

IC412.* Contrast-Enhanced Ultrasound in Radiology—Where Are We in 2010: Physics and Safety of Bubbles, Instrumentation, Monitoring Angiogenesis, and Future Innovations—*P. Burns*; The Clinical Role for CEUS in Abdominal/Pelvic Imaging—*S. Wilson*

Elizabeth H, Second Level

3:00 pm-4:30 pm

IC415. Emergency Radiology: Current Concepts in Thoracic and Abdominal Trauma: MDCT of Thoracic Trauma—*R. Novelline*; MDCT of Splenic Trauma: New Concepts—*K. Shanmuganathan*; MDCT of Bowel and Mesenteric Injuries—*J. Soto*

Douglas C, Lobby Level

Friday, May 7

10:00 am-11:30 am

IC506. Contrast Materials—Critical Update: Contrast Induced Nephropathy—*B. Herts*; Allergic Reactions to Contrast Material—*J. Ellis*; Nephrogenic Systemic Fibrosis—*P. Kuo*

Douglas A, Lobby Level

For a listing of abstracts included in the scientific sessions and power hours, please refer to the daily schedule. The categorical course schedule can be found on pages 11-12 and the case-based review schedule can be found on page 13.



GENITOURINARY IMAGING

Who Should Attend: Radiologists, radiologists-in-training and other health professionals With an Interest in the application of the radiologic sciences to the detection and management of diseases affecting the genitourinary system.

Goals and Objectives: Upon completion of the genitourinary imaging course track, the participant should be able to apply current imaging techniques, including ultrasound, CT and MR imaging, to the diagnosis and treatment of diseases in the male and female pelvis. In addition, the participant should have gained proficiency in recognizing the imaging features and constructing an imaging differential diagnosis for various genitourinary diseases.

Monday, May 3

1:00 pm-4:30 pm

Categorical Course: Practical Approaches to Common Clinical Conditions: Efficient Imaging (PAC³E) *Setting the PAC³E of Imaging*

Manchester Ballroom, Second Level

Tuesday, May 4

7:00 am-8:00 am

Power Hour: Abdominal Imaging—*A. Qayyum, moderator*

Randle B, Fourth Level

7:00 am-10:30 am

Categorical Course: Practical Approaches to Common Clinical Conditions: Efficient Imaging (PAC³E) *Setting the PAC³E of Imaging*

Manchester Ballroom, Second Level

Wednesday, May 5

8:00 am-9:30 am

IC306. Aortic Stent Grafts: Imaging and Intervention—Thoracic Stent Grafts, Overview of Devices and Cases—*R. Hieb*; Planning Abdominal Aortic Grafts—*F. Facchini*; Secondary Interventions: When and How—*M. Neisen*

Elizabeth F, Second Level

1:00 pm-3:00 pm

IC311. Benign Diseases of the Female Pelvis: Imaging of Infertility: From HSG to MRI—*J. Fielding*; Urogynecology and Pelvic Floor Imaging—*A. Thurmond*; Problematic Early Pregnancies—*R. Goldstein*; The Cystic Ovarian Mass—*M. Patel*

Douglas A, Lobby Level

4:00 pm-6:00 pm

IC315. Renal Parenchyma, Vessels and Urothelium: Renal Parenchyma—*V. Dogra*; GU Vasculature—*M. Lockhart*; Urothelium—*E. Caoili*; Renal Neoplasms—*Z. Wang*

Douglas C, Lobby Level

* *Advanced Level Course*

SUBSPECIALTY TRACKS: MUSCULOSKELETAL IMAGING



4:00 pm-5:30 pm

IC320. Pediatric Abdominal Imaging: State of the Art—*R. Goodman*;
Intestinal Obstruction in Children: State of the Art—*L. Fenton*; Neonatal
Abdominal Emergencies: Review—*J. Reid*

Elizabeth G, Second Level

Thursday, May 6

8:00 am-9:30 am

IC402. Emergency Radiology: CT Protocols and Techniques: Evolving
Concepts in MDCT Imaging of Abdominal Pain—*S. Anderson*; Imaging the
Obese Patient in the Emergency Department—*M. Gunn*; MDCT in the
Emergency Department: Update Your Protocols—*A. Sodickson*

Douglas C, Lobby Level

12:30 pm-2:00 pm

IC408. Beyond the Visceral Organs—The Mesentery and Peritoneum:
Peritoneal Spaces: Emphasis on Compartmentalization of the Perihepatic
Space—*P. Min*; Vasculature and Improved Abdominopelvic Diagnosis—
B. Yeh; Retroperitoneal Spaces—*J. Brink*

Douglas A, Lobby Level

IC412.* Contrast-Enhanced Ultrasound in Radiology—Where Are We in
2010: Physics and Safety of Bubbles, Instrumentation, Monitoring
Angiogenesis, and Future Innovations—*P. Burns*; The Clinical Role for CEUS
in Abdominal/Pelvic Imaging—*S. Wilson*

Elizabeth H, Second Level

3:00 pm-4:30 pm

IC415. Emergency Radiology: Current Concepts in Thoracic and Abdominal
Trauma: MDCT of Thoracic Trauma—*R. Novelline*; MDCT of Splenic Trauma:
New Concepts—*K. Shanmuganathan*; MDCT of Bowel and Mesenteric
Injuries—*J. Soto*

Douglas C, Lobby Level

IC416. Renal Sonography: Renal Lesions Hiding in Plain Sight—
B. Hashimoto; Duplex and Color Doppler of the Kidneys—*S. Teefey*

Douglas A, Lobby Level

3:00 pm-5:00 pm

SS25. Genitourinary Imaging: Pelvis—Moderators: *D. Grand, A. Oto*;
Keynote: MR Imaging of Acute Abdominal Pain in Pregnant Patients—
A. Oto

Elizabeth G, Lobby Level

Friday, May 7

7:30 am-10:00 am

Review Course: Genitourinary Imaging

Manchester Ballroom, Second Level:

8:00 am-9:30 am

IC505. Gynecologic Ultrasound: Update on Ultrasound Evaluation of the
Endometrium—*U. Hamper*; A Practical Approach to Ultrasound Evaluation
of Pelvic Masses—*L. Scutt*

Douglas B, Lobby Level

* *Advanced Level Course*

10:00 am-11:30 am

IC506. Contrast Materials—Critical Update: Contrast Induced
Nephropathy—*B. Herts*; Allergic Reactions to Contrast Material—*J. Ellis*;
Nephrogenic Systemic Fibrosis—*P. Kuo*

Douglas A, Lobby Level

IC508. Pearls and Pitfalls in Obstetric Ultrasound: First Trimester—
T. Angtuaco; Second and Third Trimesters Part 1—*L. Romine*; Second and
Third Trimesters Part II—*D. Pretorius*

Douglas C, Lobby Level

1:00 pm-3:00 pm

SS28. Genitourinary Imaging: Renal/Adrenal—Moderators: *E. Remer*,
V. Dogra; Keynote: *Cystic Renal Masses: Beyond Benign Versus
Malignant*—*E. Remer*

Douglas D, Lobby Level

MUSCULOSKELETAL IMAGING

Who Should Attend: Radiologists, radiologists-in-training and other
health professionals With an Interest in the application of the radiologic
sciences to the detection and management of diseases affecting the mus-
culoskeletal system.

Goals and Objectives: Upon completion of the musculoskeletal imaging
course track, the participant should be able to determine and apply appro-
priate imaging methods, including ultrasound, MR and PET, to the diagno-
sis and treatment of diseases of the hip, spine, knee, shoulder, joints and
soft tissues. In addition, the participant should have gained proficiency in
recognizing the imaging features and constructing an imaging differential
diagnosis for various musculoskeletal diseases.

Sunday, May 2

5:30 pm-6:00 pm

Categorical Course: Practical Approaches to Common Clinical Conditions:
Efficient Imaging (PAC³E)—*Setting the PAC³E of Imaging*

Manchester Ballroom, Second Level

Monday, May 3

11:00 am-12:00 noon / 4:30 pm-6:10 pm

Categorical Course: Practical Approaches to Common Clinical Conditions:
Efficient Imaging (PAC³E)—*Setting the PAC³E of Imaging*

Manchester Ballroom, Second Level

4:00 pm-6:00 pm

SS6. Musculoskeletal Imaging: Upper and Lower Extremity: Diagnostic
Advances—Moderators: *C. Roberts, T. Pope*; Keynote: Total Knee
Arthroplasty Component Rotation: Importance and Easy Technique for
Measurement—*C. Roberts*

Douglas A, Lobby Level

*For a listing of abstracts included in the scientific sessions and power
hours, please refer to the daily schedule. The categorical course schedule
can be found on pages 11-12 and the case-based review schedule can be
found on page 13.*

SUBSPECIALTY TRACKS: MUSCULOSKELETAL IMAGING



Tuesday, May 4

8:00 am-9:30 am

IC203. Rotator Cuff of the Shoulder: Why, How and Where It Fails—*D. Resnick*

Douglas A, Lobby Level

10:00 am-11:30 am

IC206.* Lateral Elbow Injuries: MRI—*Z.S. Rosenberg*; Ligament and Other Tendon Injuries of the Elbow: MRI—*V. Khoury*; Ultrasound Evaluation—*J. Jacobson*

Douglas C, Lobby Level

1:00 pm-2:30 pm

IC209.* Hip Imaging and Sports Hernia—*W. Morrison, D. Blankenbaker, I. Omar*

Douglas A, Lobby Level

4:00 pm-5:30 pm

IC212. Lesions of the Jaw and Larynx—*R. Daffner, A. Lupetin*

Douglas B, Lobby Level

Wednesday, May 5

8:00 am-9:30 am

IC303. MR Imaging of the Knee—*M. Recht, C. Glaser*

Douglas B, Lobby Level

IC305. Upper Extremity Sports Injuries in Children: State of the Art—*J. Mackenzie*; Painful Topics in Pediatric Orthopedics: Review—*M. Dempsey—Robertson*; Pediatric Bone Lesions: Review—*P. Karakas*

Elizabeth H, Second Level

10:00 am-11:30 am

IC307. Arthritis: Basic and Advanced Imaging—*D. Flemming, M. Bruno, L. Bancroft*

Douglas C, Lobby Level

1:00 pm-3:00 pm

SS19. Musculoskeletal Imaging: Neoplastic, Metabolic and Spine Imaging—Moderators: *B. Sabb, S. Smith*; Keynote: Imaging of Neoplastic Disease and Mimickers—*S. Smith*

Elizabeth H, Second Level

4:00 pm-5:30 pm

IC318. Musculoskeletal Tumors and PET Imaging—*M. Murphey, J. Peterson*

Douglas B, Lobby Level

Thursday, May 6

7:00 am-8:00 am

Power Hour: Musculoskeletal Imaging—*L. Cerezal, N. Safadar*, moderators

Randle A, Fourth Level

8:00 am-9:30 am

IC403. Multimodality Imaging of the Shoulder—*K. Buckwalter, K. Schreibman*

Douglas B, Lobby Level

10:30 am-1:00 pm

Review Course: Musculoskeletal Imaging

Manchester Ballroom, Second Level

12:30 pm-2:00 pm

IC410. Emergency Radiology: Simplifying the Diagnosis of Complex Musculoskeletal Injuries: Simplifying Intra-Articular Calcaneus Fractures—*O.C. West*; Less Common and Sometimes Confusing Injuries in and About the Hip—*L. Rogers*; Simplifying Radiographic Indicators of Major Ligamentous Injuries of the Knee—*J. Yu*

Douglas C, Lobby Level

3:00 pm-5:00 pm

SS26. Musculoskeletal Imaging: Ultrasound and Interventions—Moderators: *W. Morrison, D. Blankenbaker*; Keynote: Musculoskeletal Ultrasound Interventions: Moving Beyond Ordinary—*D. Blankenbaker*

Douglas B, Lobby Level

Friday, May 7

10:00 am-12:00 noon

SS27. Musculoskeletal Imaging: Upper and Lower Extremity: MR and CT Advances—Moderators: *M. Robbin, A. Gentili*; Keynote: Technical Advances in Imaging of the Knee—*A. Gentili*

Elizabeth F, Lobby Level

* *Advanced Level Course*



SUBSPECIALTY TRACKS: NEURORADIOLOGY



NEURORADIOLOGY

Who Should Attend: Radiologists, radiologists-in-training and other health professionals With an Interest in the application of the radiologic sciences to the detection and management of diseases affecting the brain, head, neck, and/or spine in the adult and pediatric patient.

Goals and Objectives: Upon completion of the neuroradiology course track, participants should be able to determine and apply appropriate imaging techniques and recognize imaging features. In addition they should have gained proficiency in constructing an imaging differential diagnosis for various diseases and disorders of the brain, head, neck, and spine.

Sunday, May 2

4:00 pm-6:00 pm

Categorical Course: Practical Approaches to Common Clinical Conditions: Efficient Imaging (PAC³E)—*Setting the PAC³E of Imaging*
Manchester Ballroom, Second Level

Monday, May 3

7:30 am-12:00 noon

Categorical Course: Practical Approaches to Common Clinical Conditions: Efficient Imaging (PAC³E)—*Setting the PAC³E of Imaging*
Manchester Ballroom, Second Level

10:30 am-12:00 noon

IC108. PET/CT in Head and Neck Cancer—*R. Subramaniam, E. Rohren*
Douglas B, Lobby Level

1:00 pm-2:30 pm

IC112. Optimizing PET/CT Imaging Protocols, PET/CT for Breast Cancer and Dementia—*T. Wong, E. Akin, A. Siegel*
Elizabeth H, Second Level

Tuesday, May 4

8:00 am-9:30 am

IC204.* State of the Art Imaging of the Temporal Bone: Pre- and Postoperative Evaluation—*R. Harnsberger, T. Larson*
Elizabeth H, Second Level

10:00 am-11:30 am

IC207. Differential Diagnosis of Basal Ganglia Lesions—*M. Castillo, Z. Rumbolt*
Douglas A, Lobby Level

1:00 pm-2:30 pm

IC210. Glands of the Visceral Space: Thyroid and Parathyroid Imaging—*Y. Anzai, L. Loevner, D. Shatzkes*
Douglas B, Lobby Level

4:00 pm-5:30 pm

IC213.* Bars, Screws, Struts, Cages and Scars: A Review of the Postoperative Spine—*J. Ross, T. Naidich*
Douglas C, Lobby Level

Wednesday, May 5

8:00 am-9:30 am

IC304.* Cerebral Venous Imaging: Current Techniques and Diagnostic Pitfalls—*J. Leach, T. Abruzzo*
Elizabeth G, Second Level

10:00 am-11:30 am

IC308. You've Got a Lot of Nerve...Until You Don't! Perineural Tumor Spread and Patterns of Denervation—*L. Ginsberg, W. Smoker*
Douglas B, Lobby Level

IC309. Cranial Ultrasound: State of the Art—*L. Lowe*; Pediatric Spine Imaging: State of the Art—*N. Kadom*; Pediatric Leukodystrophies: Review—*I. Kim*
Douglas A, Lobby Level

1:00 pm-2:30 pm

SS20. Neuroradiology: Head and Neck—Moderators: *M. Michel, K. Salzman*; Keynote: Radiation Dose-Reduction in Head and Neck Imaging: Issues and Insights for Radiologists—*J. Hoang*
Randle B, Fourth Level

4:00 pm-5:30 pm

IC319.* Advanced Imaging Techniques for Head and Neck Disease—*S. Mukherji, A. Srinivasan*
Elizabeth F, Second Level

Thursday, May 6

8:00 am-9:30 am

SS21. Neuroradiology: Imaging Strategies and Techniques—Moderators: *D. Gandhi, M. Mullins*; Keynote: PET/CT and PET/MRI: Intracranial Applications of Metabolic Imaging—*R. Subramaniam*
Elizabeth F, Second Level

10:00 am-11:30 am

SS24. Neuroradiology: Imaging and Clinical Outcomes—Moderators: *D. Nguyen, P. Kranz*; Keynote: Advanced CT and MR Imaging of Acute Stroke Infarct Core and Ischemic Penumbra: Where Do We Stand?—*P. Schaefer*
Elizabeth F, Second Level

12:30 pm-2:00 pm

IC411.* NonInvasive Vascular Neuroimaging: Ultrasound, CT Angiography and MR Angiography—*J. Gemmete, D. Kim, B. Huang*
Elizabeth G, Second Level

2:30 pm-5:00 pm

Review Course: Neuroradiology
Manchester Ballroom, Second Level

* Advanced Level Course

SUBSPECIALTY TRACKS: NUCLEAR MEDICINE



Friday, May 7

7:00 am-8:00 am

Power Hour: Neuroradiology—*C. Glastonbury, moderator*
Randle B, Fourth Level

8:00 am-9:30 am

IC503. Emergency Radiology: Neuroradiology, Head and Neck Emergencies—Acute Head and Neck Infections—*W. Kubal*; MDCT of Cranio-Facial Trauma—*M. Bernstein*; Neck CTA in Trauma—*F. Munera*
Douglas A, Lobby Level

IC504.* A Basic Review of Brain Tumors and New Entities According to the WHO Classification—*K. Salzman, M. Omojola*
Elizabeth G, Second Level

10:00 am-11:30 am

IC507. Imaging of the Post-Treatment Neck With CT and MRI—*C. Glastonbury, D. Williams*
Elizabeth H, Second Level

1:00 pm-2:30 pm

IC510.* Imaging of Children and Adults With Epilepsy—*N. Salamon, R. Lee*
Douglas D, Lobby Level

NUCLEAR MEDICINE

Who Should Attend: Radiologists, radiologists-in-training and other health professionals With an Interest in the use of nuclear medicine and PET/CT for the assessment of various disorders and for the evaluation and staging of malignant neoplasms.

Goals and Objectives: Upon completion of the nuclear medicine course track, the participant should be able understand the role of PET/CT in a variety of malignancies (thoracic, gastrointestinal, musculoskeletal, breast, head and neck,) and dementia as well as learn new developments in PET/CT and how to optimize protocols. The participant will also learn about several nuclear medicine therapies which are used in clinical practice.

Monday, May 3

7:00 am-8:00 am

Power Hour: Nuclear Medicine—*E. Rohren, moderator*
Randle A, Fourth Level

8:00 am-9:30 am

IC103. PET/CT for Solitary Pulmonary Nodule, Lung Cancer, and After Thermal Ablation—*S. Nayak, H. Agress, D. Yoo*
Elizabeth F, Second Level

10:30 am-12:00 noon

IC106. Breast Nuclear Medicine: PEM and PET—*D. Mankoff, G. Mercier*
Douglas A, Lobby Level

IC108. PET/CT in Head and Neck Cancer—*R. Subramaniam, E. Rohren*
Douglas B, Lobby Level

1:00 pm-2:30 pm

IC112. Optimizing PET/CT Imaging Protocols, PET/CT for Breast Cancer and Dementia—*T. Wong, E. Akin, A. Siegel*
Elizabeth H, Second Level

4:00 pm-6:00 pm

SS7. Nuclear Medicine—Moderators: *D. Yoo, T. Wong*; Keynote: PET Response Criteria in Solid Tumors (PERCIST 1.0)—*H. Jacene*
Randle A, Fourth Level

Tuesday, May 4

8:00 am-9:30 am

IC205. Nuclear Medicine Therapies for Cancer: Radioimmunotherapy, Microspheres Therapy and Radioiodine Therapy—*A. Sheikh, H. Jacene, S. Goetze*
Elizabeth F, Second Level

1:00 pm-3:30 pm

Review Course: Nuclear Medicine
Manchester Ballroom, Second Level

Wednesday, May 5

4:00 pm-5:30 pm

IC318. Musculoskeletal Tumors and PET Imaging—*M. Murphey, J. Peterson*
Douglas B, Lobby Level

Thursday, May 6

12:30 pm-2:00 pm

IC409. CT and PET/CT: SPN, Lung Cancer and Other Thoracic Malignancies—*J. Bruzzi, E. Rohren, J. Ko*
Douglas B, Lobby Level

3:00 pm-4:30 pm

IC413. Thoracic PET-CT: Interpretation Predicaments and Future Developments—*O. Mawlawi, J. Erasmus, M. Truong, T. Wong*
Elizabeth F, Second Level

For a listing of abstracts included in the scientific sessions and power hours, please refer to the daily schedule. The categorical course schedule can be found on pages 11-12 and the case-based review schedule can be found on page 13.

SUBSPECIALTY TRACKS: PEDIATRIC IMAGING



PEDIATRIC IMAGING

Who Should Attend: Radiologists, radiologists-in-training and other health professionals With an Interest in the application of the radiologic sciences to the evaluation and treatment of diseases of Infants, children and adolescents.

Goals and Objectives: Upon completion of the pediatric imaging course track, the participant should be able to safely and effectively incorporate the use of various imaging modalities in the diagnosis and treatment of pediatric patients. In addition, the participant should have gained proficiency in recognizing the imaging features and constructing an imaging differential diagnosis for various diseases and disorders affecting the pediatric populations.

Sunday, May 2

2:30 pm-3:30 pm

Categorical Course: Practical Approaches to Common Clinical Conditions: Efficient Imaging (PAC³E)—*Setting the PAC³E of Imaging*
Manchester Ballroom, Second Level

Monday, May 3

5:30 pm-6:10 pm

Categorical Course: Practical Approaches to Common Clinical Conditions: Efficient Imaging (PAC³E)—*Setting the PAC³E of Imaging*
Manchester Ballroom, Second Level

Tuesday, May 4

7:00 am-10:30 am

Categorical Course: Practical Approaches to Common Clinical Conditions: Efficient Imaging (PAC³E)—*Setting the PAC³E of Imaging*
Manchester Ballroom, Second Level

4:00 pm-6:00 pm

SS16. Pediatric Imaging—Moderators: *E. Lee, T. Huisman*; Keynote: Advanced MRI of the Pediatric Brain: Why?—*T. Huisman*
Elizabeth H, Second Level

Wednesday, May 5

7:00 am-8:00 am

Power Hour: Pediatric Imaging—*T. Huisman, moderator*
Randle A, Fourth Level

8:00 am-9:30 am

IC305. Upper Extremity Sports Injuries in Children: State of the Art—*J. Mackenzie*; Painful Topics in Pediatric Orthopedics: Review—*M. Dempsey-Robertson*; Pediatric Bone Lesions: Review—*P. Karakas*
Elizabeth H, Second Level

10:00 am-11:30 am

IC309. Cranial Ultrasound: State of the Art—*L. Lowe*; Pediatric Spine Imaging: State of the Art—*N. Kadom*; Pediatric Leukodystrophies: Review—*I. Kim*
Douglas A, Lobby Level

1:00 pm-3:30 pm

Review Course: Pediatric Imaging
Manchester Ballroom, Second Level

4:00 pm-5:30 pm

IC320. Pediatric Abdominal Imaging: State of the Art—*R. Goodman*; Intestinal Obstruction in Children: State of the Art—*L. Fenton*; Neonatal Abdominal Emergencies: Review—*J. Reid*
Elizabeth G, Second Level

Thursday, May 6

8:00 am-9:30 am

IC404. Pediatric Large Airway Disease: State of the Art—*E. Lee*; Pediatric Interstitial Lung Disease: State of the Art—*P. Guillerman*; Congenital Lungs: Review—*C. Carrico*
Elizabeth G, Second Level

Friday, May 7

1:00 pm-2:30 pm

IC510. Imaging of Children and Adults With Epilepsy—*N. Salamon, R. Lee*
Elizabeth G, Second Level

For a listing of abstracts Included in the scientific sessions and power hours, please refer to the daily schedule. The categorical course schedule can be found on pages 11-12 and the case-based review schedule can be found on page 13.



SUBSPECIALTY TRACKS: ULTRASOUND



ULTRASOUND

Who Should Attend: Radiologists, radiologists-in-training and other health professionals With an Interest in the application of ultrasound to diagnose abdominal, vascular, obstetric, gynecologic, musculoskeletal, and neurological diseases and disorders in both the adult and pediatric patient.

Goals and Objectives: Upon completion of the ultrasound imaging course track, the participant should be able to Incorporate the proper use of ultrasound in the diagnosis and treatment of adult and pediatric patients With diseases or disorders in the pelvis, abdomen, head and neck, breast, musculoskeletal system and vascular system. In addition, the participant should have gained proficiency in recognizing the imaging features of ultrasound and constructing an imaging differential diagnosis for diseases effectively imaged by ultrasound.

Tuesday, May 4

10:00 am-11:30 am

IC206. Lateral Elbow Injuries: MRI—Z.S. Rosenberg; Ligament and Other Tendon Injuries of the Elbow: MRI—V. Khoury; Ultrasound Evaluation—J. Jacobson

Douglas C, Lobby Level

Thursday, May 6

12:30 pm-2:00 pm

IC412.* Contrast-Enhanced Ultrasound in Radiology—Where Are We in 2010: Physics and Safety of Bubbles, Instrumentation, Monitoring Angiogenesis, and Future Innovations—P. Burns; The Clinical Role for CEUS in Abdominal/Pelvic Imaging—S. Wilson

Elizabeth H, Second Level

3:00 pm-4:30 pm

IC416. Renal Sonography: Renal Lesions Hiding in Plain Sight—B. Hashimoto; Duplex and Color Doppler of the Kidneys—S. Teefey

Douglas A, Lobby Level

Friday, May 7

7:00 am-8:00 am

Power Hour: Ultrasound—M. Dighe, moderator

Randle A, Fourth Level

8:00 am-9:30 am

IC505. Gynecologic Ultrasound: Update on Ultrasound Evaluation of the Endometrium—U. Hamper; A Practical Approach to Ultrasound Evaluation of Pelvic Masses—L. Scoutt

Douglas B, Lobby Level

10:00 am-11:30 am

IC508. Pearls and Pitfalls in Obstetric Ultrasound: First Trimester—T. Angtuaco; Second and Third Trimesters Part I—L. Romine; Second and Third Trimesters Part II—D. Pretorius

Douglas C, Lobby Level

2:00 pm-4:30 pm

Review Course: Ultrasound

Manchester Ballroom, Second Level

VASCULAR AND INTERVENTIONAL RADIOLOGY

Who Should Attend: Radiologists, radiologists-in-training and other health professionals With an Interest in the application of the radiologic sciences to the evaluation of patients With vascular and nonvascular diseases amenable to treatment through Interventional radiology techniques and procedures.

Goals and Objectives: Upon completion of the vascular and Interventional radiology course track, the participant should be able to utilize currently available Interventional techniques, Including abscess drainage, ablation, embolization and pain management techniques, for both vascular and nonvascular Indications.

Sunday, May 2

12:10 pm-12:30 pm / 3:10 pm-3:30 pm / 4:30 pm-5:00 pm / 5:30 pm-6:00 pm

Categorical Course: Practical Approaches to Common Clinical Conditions: Efficient Imaging (PAC³E)—Setting the PAC³E of Imaging

Manchester Ballroom, Second Level

Monday, May 3

8:00 am-9:30 am

IC105. Thromboembolic Axis of Evil: DVT, PE and IVC Filters—T. Burdick, T. Kooy, L. Findeiss

Elizabeth H, Second Level

10:00 am-10:30 am

Categorical Course: Practical Approaches to Common Clinical Conditions: Efficient Imaging (PAC³E)—Setting the PAC³E of Imaging

Manchester Ballroom, Second Level

10:30 am-12:00 noon

IC110. Pulmonary Interventions: AVMs and Bronchial Artery Embolization; Diagnosis—A. Funaki; Pulmonary Embolization—C. Burke; Bronchial Embolization—B. Funaki

Elizabeth G, Second Level

1:00 pm-2:30 pm

SS5. Vascular and Interventional Radiology—Moderators: M.G. Knuttinen; T. Carrillo; Keynote: Endovascular Management of Massive Pulmonary Embolism—C. Owens

Randle A, Fourth Level

4:00 pm-5:30 pm

IC117. Interventional Radiology for the Diagnostic Radiologist—C. Ray, A. Nemcek, K. Kondo

Elizabeth G, Second Level

For a listing of abstracts Included in the scientific sessions and power hours, please refer to the daily schedule. The categorical course schedule can be found on pages 11-12 and the case-based review schedule can be found on page 13.

* Advanced Level Course

SUBSPECIALTY TRACKS: VASCULAR AND INTERVENTIONAL RADIOLOGY



Tuesday, May 4

7:00 am-8:00 am

Power Hour: Vascular and Interventional Radiology—*A. Nemcek, moderator*
Randle A, Fourth Level

10:00 am-11:30 am

SS11. Vascular and Interventional Radiology—Moderators: *J. Lorenz, T. Kinney*; Keynote: Hepatic Chemoembolization: Is it Time for a Paradigm Change?—*C. Ray*
Randle A, Fourth Level

1:00 pm-2:30 pm

SS14. Vascular and Interventional Radiology—Moderators: *S. Zangan, U. Pua*; Keynote: Minimally Invasive Management of Neuroendocrine Hepatic Metastases—*D. Madoff*
Randle A, Fourth Level

4:00 pm-5:30 pm

IC214. Management of Challenging Cases in Interventional Liver Oncology: A Case-Based Approach—*D. Madoff, R. Murthy, S. Rose*
Randle A, Fourth Level

Wednesday, May 5

8:00 am-9:30 am

IC304.* Cerebral Venous Imaging: Current Techniques and Diagnostic Pitfalls—*J. Leach, T. Abruzzo*
Elizabeth G, Second Level

IC306. Aortic Stent Grafts: Imaging and Intervention—Thoracic Stent Grafts, Overview of Devices and Cases—*R. Hieb*; Planning Abdominal Aortic Grafts—*F. Facchini*; Secondary Interventions: When and How—*M. Neisen*
Elizabeth F, Second Level

10:00 am-11:30 am

IC310. Vertebroplasty: The Beginner's Course—*S. Tutton, M. Davidian*
Randle A, Fourth Level

1:00 pm-2:30 pm

IC314. Radiation Safety (vascular and interventional radiology)—*B. Dixon, K. Ogden, R. Thornton*
Randle A, Fourth Level

4:00 pm-6:30 pm

Review Course: Vascular and Interventional Radiology
Manchester Ballroom, Second Level

Thursday, May 6

8:00 am-9:30 am

IC405. Pharmacology in Interventional Radiology: Sedation and Analgesia Primer, Anti-Coagulation and Anti-Platelet Therapy and Antibiotics, etc.—*H. Ferral, P. Gamboa, J. Lopera*
Elizabeth H, Second Level

12:30 pm-2:00 pm

IC411.* NonInvasive Vascular Neuroimaging: Ultrasound, CT Angiography and MR Angiography—*J. Gemmete, D. Kim, B. Huang*
Elizabeth G, Second Level

* Advanced Level Course



ELECTRONIC EXHIBITS



SUNDAY, MAY 2

1:00 pm–6:00 pm

Randle D/E, Fourth Level

MONDAY–THURSDAY, MAY 3-6

7:00 am–12:00 midnight

Randle D/E, Fourth Level

FRIDAY, MAY 7

7:00 am–1:00pm

Randle D/E, Fourth Level

EXHIBIT TOPICS:

Breast Imaging	pages 73-74
Cardiopulmonary Imaging	pages 75-77
Efficacy, Education, Administration and PACS	pages 78-79
General and Emergency Radiology	pages 80-82
Gastrointestinal/Liver/Biliary/Pancreas Imaging	pages 83-87
Genitourinary/OB/GYN Imaging	pages 88-91
Musculoskeletal Imaging	pages 92-95
Neuroradiology/Head and Neck	pages 96-100
Nuclear Medicine/Molecular Imaging	page 101
Pediatric Imaging	pages 102-103
Vascular and Interventional Radiology	pages 104-106

The abstracts included in the scientific sessions and power hours are available at www.ajronline



ARRS 2011 CHICAGO

ANNUAL MEETING ■ MAY 1-6

Call for Papers & Exhibits

Abstract topics include:

- Administration
- Breast Imaging
- Cardiopulmonary Imaging
- Education
- Efficacy
- Emergency Radiology
- Gastrointestinal Imaging
- Genitourinary Imaging
- Gynecologic Imaging
- Interventional Radiology
- Molecular Imaging
- Musculoskeletal Imaging
- Neuroradiology
- Nuclear Medicine
- Obstetric Imaging
- PACS
- Pediatric Radiology
- Physics
- Sonography
- Vascular Imaging

Abstract submission site: www.arrs.org

The abstract submission site opens August 2, 2010.

ELECTRONIC EXHIBITS: Breast



E001. Radiologic-Pathology Correlations in Breast Imaging: A Primer for Radiologists

Ojeda-Fournier, H.; Lai, L.; Bykowski, J.; Scuderi, R.; Olson, L. University of California San Diego, San Diego, CA

E002. Review of Various Breast Lesions Detected in Multidetector CT

Chang, Y.; Ahn, H.; Hwang, J.; Kwon, K.; Choi, D. Soonchunhyang University Hospital, Seoul, Korea

E003. The Many Faces of Papillary Lesions of the Breast

McArthur, T.; Umphrey, H.; Bernreuter, W.; Hogg, D. University of Alabama at Birmingham, Birmingham, AL

E004. The Many Faces of Invasive Ductile Carcinoma

Zarzour, J.; Umphrey, H. University of Alabama at Birmingham, Birmingham, AL

E005. Spectrum of Imaging Findings in the Silicone Injected Breast

Misra, M.; Leibman, A. Jacobi Medical Center, Bronx, NY

E006. Progressive Deforming Fat Necrosis of the Breast: A Multimodality Imaging Review with Pathologic Correlation

Woods, H.; Jesinger, R.^{1,2}; Lovell, D.¹; Braithwaite, A.¹; DeMartini, S.¹; Lee, V.¹ 1. David Grant USAF Medical Center, Travis AFB, CA; 2. Uniformed Services University of the Health Sciences, Bethesda, MD

E007. Looking Beyond the Cleavage: Manifestations of Systemic Disease in Breast Imaging

Kirwan R.¹; Yepes M.²; Kiszonas R.² 1. University of Miami/Jackson Memorial Hospital, Miami Beach, FL; 2. University of Miami, Miami, FL

E008. Rare Entities: Vascular Lesions of the Breast

Yitta, S.; Singer, C.; Heffernan, C.; Toth, H.; Mercado, C. NYU, New York, NY

E009. Review of Common Mammographic Artifacts on Both Digital and Analog Mammograms

Chatell, T.; Shah, B. Henry Ford Hospital, Grand Blanc, MI

E010. Appearances of Male Breast Carcinoma: Mammographic and Sonographic Correlates

Shah, C.; Pile-Spellman, E. NY Presbyterian Hospital, Columbia, New York, NY

E011. Pseudoangiomatous Stromal Hyperplasia (PASH): What the Radiologist Needs to Know

Trexler, N.; Umphrey, H. University of Alabama at Birmingham, Birmingham, AL

E012. Additional View: How and When to Use

Oh, Y.; Chung, S. Hallym University Medical Center, Seoul, Korea

E013. Pleomorphic Lobular Carcinoma In-situ and Pleomorphic Invasive Carcinoma: What Exactly are They and How Do We Find Them?

Lee, J.^{1,2}; Mercado, C.^{1,2}; Hernandez, O.^{1,2}; Moy, L.^{1,2}; Toth, H.^{1,2} 1. NYU School of Medicine, Scarsdale, NY; 2. NYU Cancer Institute, New York, NY

E014.* Radiologic Pathologic Correlation of Diseases Affecting the Pregnant and Lactating Breast

Joshi, S.; Marotti, J.; Dialani, V.; Mehta, T.; Slanetz, P. Beth Israel Deaconess Medical Center, Boston, MA

E015. Ductal Carcinoma in Situ of the Breasts Showing Unusual Imaging Findings

Park, Y.¹; Kim, S.¹; Park, J.¹; Lee, S.¹; Juhn, J.¹; Lee, J.²; Lee J.³ 1. Busan Paik Hospital, Inje University College of Medicine, Busan, Korea; 2. Dong-A University Medical Center, Busan, Korea; 3. Bongaeng Hospital, Busan, Korea

E016. WITHDRAWN

E017. Mammographic Asymmetries: Review of Terminology and Strategies for Increasing Cancer Detection

March, D.^{1,2}; Khadem, P.²; Crisi, G.²; Miller, V.^{1,2}; Rakita, D.^{1,2} 1. Radiology & Imaging, Inc., Northampton, MA; 2. Baystate Medical Center, Springfield, MA

E018. Imaging Findings of Inflammatory Fat Necrosis Following Breast Conservation Therapy and Radiation with Clinical and Pathologic Correlation

Zingula, S.; Glazebrook, K.; Reynolds, C.; Neal, L.; Summers, H.; Morton, M. Mayo Clinic, Rochester, MN

E019. Correlation of Tumor Receptors and Histologic Grade with Imaging Features of Infiltrating Ductal Breast Carcinoma: Can Imaging Predict Prognosis?

Lewis, M.; Irshad, A.; Leddy, R.; Hashmi, A.; Ackerman, S.; Pope, T.; Cluver, A. Medical University of South Carolina, Charleston, SC

E020. Breast MRI Findings Following Deep Inferior Epigastric Perforator Flap Reconstruction

Campbell, A.; Ackerman, S.; Cluver, A.; Irshad, A.; Pope, T. Medical University of South Carolina, Charleston, SC

E021.* Spectrum of MR Imaging Findings in the Post-Operative Breast

Ojeda-Fournier, H.; Brogoch, L.; Aiken, M. University of California San Diego, San Diego, CA

E022.* Breast Cancer in Women 35 Years and Younger: Spectrum of Clinical, Radiological, and Pathological Findings

Bickell K.¹; Kuo J.¹; Soetaert A.²; Larsen L.¹ 1. University of Southern California School of Medicine, La Canada, CA; 2. St. Luke's Cancer Institute Center for Breast Care, Kansas City, MO

E023.* Invasive Lobular Carcinoma: MRI Appearance with Histopathologic Correlation

Merchant, K.; Fundaro, G. Henry Ford Hospital, Troy, MI

E024.* Detection and Reporting of Extramammary Findings During Breast MRI

Ojeda-Fournier H.¹; Deshmukh M.¹; Hiller L.¹; Comstock C.¹; Mahoney M.²; Bykowski J.¹ 1. University of California San Diego, San Diego, CA; 2. University of Cincinnati, Cincinnati, OH

* offers CME credit

ELECTRONIC EXHIBITS: Breast



E025* Optimal Timing of Breast MRI Examinations for Premenopausal Women Who Do Not Have a Normal Menstrual Cycle

Ellis, R. Gundersen Lutheran Medical Center, La Crosse, WI

E026. Optimizing Breast MRI: Pitfalls, Errors and How to Avoid Them

Yepes, M.; Kizonas, R.; Infante, J. University of Miami, Pembroke Pines, FL

E027* Breast MRI: An Algorithm for Successful Cancer Diagnosis

Yepes, M.; Kizonas, R.; Infante, J. University of Miami, Pembroke Pines, FL

E028* Inflammatory Breast Carcinoma (IBC): Imaging Findings on Mammography, US, MRI, and PET/CT

Winston, E.; Le-Petross, H.; Cristofanilli, M.; Gong, Y.; Yang, W. M.D. Anderson Cancer Center, Houston, TX

E029* Optimizing 1.5T and 3.0T Contrast-Enhanced Dynamic Breast MRI in Your Practice

Lewis, M.; Moccaldi, M.; Mercado, C.; Lee, J.; Toth, H.; Moy, L. NYU Langone Medical Center, New York, NY

E030* Papillary Breast Carcinoma without Frank Invasion: Imaging Findings with Pathologic Correlation. Emphasis on MRI

Ecanow, J.; Newstead, G.; Mueller, J. University of Chicago, Chicago, IL

E031. MRI Findings of Pseudoangiomatous Stromal Hyperplasia (PASH) with Clinical and Pathologic Correlation

Glazebrook, K.; Jones, K.; Reynolds, C. Mayo Clinic, Rochester, MN

E032* Invasive Lobular Carcinoma of the Breast: Potentially Useful Imaging Findings for Differential Diagnosis

Boatsman, J.; Park, J.; Kim, J.; Yang, L.; Fajardo, L. University of Iowa Hospitals and Clinics, Iowa City, IA

E033. MRI Diffusion Characteristics of Benign Lumpectomy Scars

Hain, K.; Kelcz, F. University of Wisconsin, Madison, WI

E034. MDCT Angiography Application for Preoperative Planning in Patients Undergoing Breast Reconstruction

Saba, L.; Atzeni, M.; Ribuffo, D.; Mallarini, G. Azienda Ospedaliero Universitaria, Cagliari Sardegna, Italy

E035. Male Breast Cancer: Mammographic, Sonographic and PET CT Appearance with Histopathologic Correlation

Vance, L.; Merchant, K.; Mandava, S. Henry Ford Hospital, Troy, MI

E036. The Assessment of Breast Cancer Response and the Prediction of Pathologic Complete Response to Neoadjuvant Chemotherapy; Comparison of MRI and PET

Kim, S.¹; Moon, W.²; Kang, J.¹ 1. Seoul National University Hospital, Healthcare System Gangnam Center, Seoul, Korea; 2. Seoul National University Hospital, Seoul, Korea

E037. A Quality Review of the Timeliness of Breast Cancer Diagnosis and Treatment in an Integrated Breast Center

Ellis, R.; Landercasper, J.; Linebarger, J.; Mathiason, M.; Johnson, J.; Marcou, K.; De Maiffe, B.; Jago, G. Gundersen Lutheran Medical Center, La Crosse, WI

E038. Radiologic Features of Infection and Inflammatory Lesions in Breast: Imaging and Pathology Correlations

An, J.; Kang, J.; Woo, J. Eulji University, School of Medicine, Seoul, South Korea

E039* Fat Necrosis In Screening Mammography: A Sheep in Wolf's Clothing

Woytak, A. SUNY Upstate Medical University, University Hospital, East Syracuse, NY

E040. Extended Field of View in Breast Ultrasound: An Effective and Practical Tool for the Evaluation of Normal Anatomy, Benign and Malignant Pathology

Moncayo R.¹; Moncayo V.² 1. Ecomedica Diagnostic Ultrasound Center, Quito, Ecuador; 2. Emory University School of Medicine, Atlanta, GA

E041* Secretory Cancer in a Premenstrual Girl. Case Report and Literature Review.

Grover, R.; Cook, H.; Seely, J. University of Ottawa, Ottawa, Canada

E042. Typical and Atypical Imaging Appearance of Fibroadenoma: Multimodality Imaging

Abdel Razek, A. Mansoura University Hospital, Mansoura, Egypt

E043. Elastography 'Target Sign' as a Predictor of Benignity of Breast Ultrasound Lesions

Talley, M.; Sisney, G.; Salkowski, L.; Burnside, E.; Lindstrom, M. University of Wisconsin, Madison, WI

E044. Diagnostic Performance of Elastography in the Evaluation of Lesions Referred for Breast Biopsy. Combined Use of Color Elastogram and Strain Ratio Assessment

Kumm, T.¹; Chau, A.²; Szabunio, M.² 1. University of South Florida, Tampa, FL; 2. H. Lee Moffitt Cancer Center and Research Institute, Tampa, FL

E045. Utility of Diffusion Weighted Imaging in Differentiating Metastatic Versus Uninvolved Axillary Lymph Nodes

Net, J.; Kirwan, R.; Yepes, M.; Pattany, P. Jackson Memorial Hospital/ University of Miami, Miami Beach, FL

E046* Axillary and Intramammary Lymph Nodes Visualized on Mammography: Review of Suspicious Imaging Features and Avoidance of Pitfalls in Characterization

March, D.^{1,2}; Nguyen, C.²; Hadro, J.^{1,2}; Crisi, G.² 1. Radiology & Imaging, Inc., Springfield, MA; 2. Baystate Medical Center, Springfield, MA

* offers CME credit

ELECTRONIC EXHIBITS: Cardiopulmonary



E047* Post Therapeutic Imaging of Aortic Coarctation

Vummidi, D.; Mitsumori, L.; Kicska, G.; Reddy, G. University of Washington School of Medicine, Seattle, WA

E048. Pictorial Review of the Aorta Before, During, and After Repair

Ginat, D.; Bhatt, S.; Singh, M.; Dogra, V. University of Rochester, Rochester, NY

E049* Role of Diagnostic Imaging in Takayasu's Arteritis

Carrillo, M.; Felipe, T.; Paul, N.; Nguyen, E.; Summerfield, R. Toronto General Hospital, Toronto, Canada

E050. Embryology, Anatomy, Normal Variants, and Pathology of the Interatrial Septum

Rojas, C.; El-Sherief, A.; Chung, J.; Choy, G.; Medina-Zuluaga, H.; Abbara, S. Massachusetts General Hospital, Boston, MA

E051* Step-by-Step Guide on How to Obtain Standardized Cardiac Imaging Planes and What to Look for Once you Get There

El-Sherief, A.; Rojas, C.; Chung, J.; Choy, G.; Medina-Zuluaga, H.; Abbara, S. Massachusetts General Hospital, Boston, MA

E052. Echocardiography and MDCT, Complimentary Techniques

Rojas, C.; Medina-Zuluaga, H.; Chung, J.; Reingold, J.; El-Sherief, A.; Francis, S.; Abbara, S. Massachusetts General Hospital, Boston, MA

E053. Involvement of Heart and Pericardium by Secondary Malignancies—Rad Path Series at a Thoracic Oncology Center

Madan, R.; Buckley, O.; Padera, R.; Trotman-Dickenson, B.; Rybicki, F.; Hunsaker, A. Brigham & Women's Hospital, Boston, MA

E054. How to Perform a Cardiac CT: A Flowchart

Green, D.; Mitsumori, L.; Warren, W.; Shuman, W. University of Washington, Seattle, WA

E055* Lipomatous Metaplasia of the Myocardium: Multimodality Imaging of a Common Finding in the Chronic Phase of Myocardial Infarction

Farvid, A.; Talkin, B.; Young, A.; Hindoyan, A.; Shinbane, J.; Shriki, J. University of Southern California, Keck School of Medicine, Los Angeles, CA

E056. Congenital Anomalies of the Coronary Arteries

Talkin, B.; Ambruster, S.¹; Wilcox, A.¹; Baker, C.¹; Shinbane, J.¹; DeFrance, T.²; Shriki, J.¹ 1. University of Southern California, Keck School of Medicine, Los Angeles, CA; 2. University of California at San Francisco, San Francisco, CA

E057. Optimal Viewing Parameters for Myocardial Stress Perfusion CT

Techasith, T.¹; Ghoshhajra, B.¹; Drzezza, N.¹; Rogers, I.²; Medina-Zuluaga, H.¹; Blankstein, R.³; Maurovich-Horvat, P.¹; Cury, R.^{1,4} 1. Massachusetts General Hospital, Boston, MA; 2. Stanford University Hospital, Palo Alto, CA; 3. Brigham and Women's Hospital, Boston, MA; 4. Baptist Cardiac and Vascular Institute, Miami, FL

E058* Coronary Artery Bypass Graft Aneurysms and Pseudoaneurysms

Liu, H.; Ferguson, E. University of Texas at Houston, Houston, TX

E059* Cardiac MRI of the Fontan Procedure: A Review of MRI Appearance of Normal and Abnormal Findings and of Long Term Complications

Fredenburg, T.; Cohen, M.; Johnson, T. Indiana University, IN

E060* Imaging Ventricular Septal Defects In Adults: Pearls and Pitfalls

Newton, T.; Wong, K.; Paul, N.; Crean, A.; Nguyen, E. Toronto General Hospital, Toronto, Canada

E061* Imaging Manifestations of Pulmonary Arterial Hypertension: Moving Beyond the Pulmonary Artery

Brouha, S.; Peshock, R. University of Texas Southwestern Medical Center, San Diego, CA

E062* Myocardial BOLD Imaging: A New Frontier for Ischemic Heart Disease

Peter, S.; Beache, G. University of Louisville, Louisville, KY

E063* Advanced Sequences Used in Cardiac MRI—Review of Physics, Technique, Applications and Pitfalls

Rajiah, P.; Setser, R. Cleveland Clinic Foundation, Cleveland, OH

E064* Cardiovascular Imaging on 1.0T Open MRI: Practice, Pitfalls and Promise

Pantelic, M.; Poopat, C.; Song, T. Henry Ford Hospital, Detroit, MI

E065* Global and Regional Functional MR Imaging of Heart—Pictorial Review of Techniques and Pathological Patterns

Rajiah, P.; Setser, R.; Flamm, S. Cleveland Clinic Foundation, Cleveland, OH

E066* MRI in Congestive Cardiac Failure—A Pictorial Review

Rajiah, P. Cleveland Clinic Foundation, Cleveland, OH

E067* Imaging Following Vascular Surgeries in the Chest—A Pictorial Review

Rajiah, P.¹; Kanne, J.² 1. Cleveland Clinic Foundation, Cleveland, OH; 2. University of Wisconsin, Madison, WI

E068* MRI of Cardiac Shunts—Pictorial Review

Rajiah, P.¹; Kanne, J.² 1. Cleveland Clinic Foundation, Cleveland, OH; 2. University of Wisconsin, Madison, WI

E069* MRI Imaging of Atypical Cardiac Masses—A Pictorial Review

Rajiah, P.¹; Kanne, J.²; Flamm, S.¹ 1. Cleveland Clinic Foundation, Cleveland, OH; 2. University of Wisconsin, Madison, WI

E070* Role of MRI in the Evaluation of Pericardial Inflammation and Constriction—Pictorial Review

Rajiah, P.; Flamm, S. Cleveland Clinic Foundation, Cleveland, OH

E071* Role of MRI in the Evaluation of Myocardial Infarction—A Pictorial Review

Rajiah, P.; Flamm, S. Cleveland Clinic Foundation, Cleveland, OH

E072* MRI Primer of Congenital Heart Defect Repair

McGuire, M.^{1,2}; Rahmani, N.^{1,2}; Shankar, S.¹; Collins, L.¹ 1. Long Island Jewish Medical Center, New Hyde Park, NY; 2. Schneider Children's Hospital, New Hyde Park, NY

ELECTRONIC EXHIBITS: Cardiopulmonary



E073. Comparison of Pre- and Post-Contrast MRI Echoplanar Imaging Sequences in Evaluation of Aortic Regurgitation—A MRI Study with Echocardiographic Correlation

Rajiah, P.; Setser, R.; Flamm, S. Cleveland Clinic Foundation, Cleveland, OH

E074. Utility of Comprehensive, Low Dose Preoperative CT Evaluation of the Cardiac Surgery Patient

Delman, T.; Markowitz, A.; Sachs, P.; Aktay, R.; Shaffer, S.; Ciancibello, L.; Gilkeson, R. University Hospitals Case Medical Center, Cleveland, OH

E075* Pulmonary Valve Disease: Improved Diagnosis with Advanced CT and MRI Technology

Vogelius, E.; Gilkeson, R.; Sachs, P.; Markowitz, A.; Aktay, R. University Hospitals Case Medical Center, Cleveland, OH

E076. Incidental Extra-Coronary Cardiac Findings in Coronary CT Angiography (CCTA)—Looking Beyond the Coronaries

Aljizeeri, A.; Mumtaz, H.; Heilbron, B.; Taylor, C.; Ellis, J.; Leipsic, J. St. Paul's Hospital, Vancouver, Canada

E077. Dose Reduction Tools in Coronary CT: Opening New Horizons

Mumtaz, H.; Aljizeeri, A.; Heilbron, B.; Taylor, C.; Johnson, M.; Ellis, J.; Leipsic, J. St. Paul's Hospital, Vancouver, Canada

E078. The What, Why, and Where of Implantable Cardiac Devices

Wong, K.; Newton, T.; Nguyen, E.; Crean, A.; Nanthakumar, K.; Paul, N. University Health Network, Toronto, Canada

E079* Primary Tumors of the Chest Wall: An Imaging Guide

Mullan, C.; Madan, R.; Qian, X.; Trotman-Dickenson, B.; Hunsaker, A. Brigham & Women's Hospital, Boston, MA

E080. Solitary Fibrous Tumors of the Thorax and Abdomen—Experience at a Tertiary Oncology Center

Madan, R.; Mullan, C.; Buckley, O.; Qian, X.; Trotman-Dickenson, B.; Hunsaker, A. 1. Brigham & Women's Hospital, Boston, MA; 2. Beth Israel Deaconess Medical Center, Boston, MA

E081. Pitfalls of CTPA: A Case-Based Pictorial Essay

Michael, G.¹; Allmendinger, A.²; Perone, R.² 1. St. Vincents Medical Center, New York, NY; 2. St. Vincents Medical Center, New York, NY

E082* Imaging of Malignant Pleural Neoplasms

Souza, F.; O'regan, K.; Jagannathan, J.; Ramaiya, N.; Van Den Abbeele, A. Dana Farber Cancer Institute, Boston, MA

E083. Swine-Origin Influenza A (H1N1) Viral Infection: Radiographic and CT Findings

Ajlan, A.; Quiney, B.; Nicolaou, S.; Müller, N. University of British Columbia, Vancouver, Canada

E084. A Quantitative Comparison of Image Quality and Radiation Dose in Patients Undergoing CT Pulmonary Angiography with 120 kV and 100 kV

Fanous, R.; Paul, N.; Kashani, H.; Menezes, R. University of Toronto, Toronto, Canada

E085. Lung Bud Anomalies: Pictorial Essay

Franquet, T.¹; Abbott, G.²; Rosado de Christenson, M.³; Giménez, A.¹; Hidalgo, A.¹ 1. Hospital de Sant Pau, Barcelona, Spain; 2. Massachusetts General Hospital, Boston, MA; 3. St. Luke's Hospital of Kansas City, Kansas City, MO

E086. Emergent CT and Radiographic Thoracic Imaging Signs

Gabe, M.; Gerena, M.; Perone, R. St. Vincents Medical Center, New York, NY

E087* Tumors of the Trachea: From the Usual to the Unusual

Carrillo, M.; Patsios, D.; Summerfield, R.; Gordon, W.; Chung, T. Toronto General Hospital, Toronto, Canada

E088* Mesothelioma: Beyond the Pleura!

Madan, R.; Mullan, C.; Sugarbaker, D.; Chiriac, L.; Gill, R.; Jacobson, F.; Hunsaker, A. Brigham & Women's Hospital, Boston, MA

E089* Pulmonary Findings in Patients with Tuberos Sclerosis and Changes Following Treatment with Rapamycin

Hyun, C.; Ashwal, S.; Fisher, K. Loma Linda University Medical Center, Loma Linda, CA

E090. Evidence Based Approach to Imaging Evaluation of Pulmonary Embolism in Pregnancy: Safety and Utility of Current Modalities

Krishnamoorthy, A.; Thomas, S.; Vannier, M.; Pu, Y. University of Chicago Medical Center, Chicago, IL

E091. Don't Forget the Lateral! Lateral Chest X-Ray Anatomy and Physiology

Jethwa, S.¹; Loona, J.¹; Reede, D.¹; Martino, J.¹; Shah, R.² 1. Long Island College Hospital, Brooklyn, NJ; 2. North Shore/LIJ, Manhasset, NY

E092* Bronchopulmonary Malformations: A Pictorial Essay

Hwang, B.; Perone, R.; Gupta, S.; Berlin, F. New York Medical College at St. Vincent's Hospital and Medical Center of NY, New York, NY

E093* The Confessions of a Thoracic Misplaced Line: A Pictorial Essay

Hwang, B.; Perone, R.; Gupta, S. New York Medical College at St. Vincent's Hospital and Medical Center of NY, New York, NY

E094. Variant Origins of the Vertebral Artery—An Interactive Review

Kuriakose, J.; Gross, B.; Quint, D.; Kincaid, J.; Schafer, J.; Stojanovska, J. University of Michigan, Ann Arbor, MI

E095* Immediate CT Findings of Cryoablated Malignant Lung Nodules, < 2cm, Correlated with Extent of GGO and Necrosis

Ham, S. Korea University Anam Hospital, Seoul, Korea

E096* Assessment of Collateral Pathway Formation in Severe Occlusive Coronary Artery Atherosclerotic Disease Using Multidetector 64-Slice CT Coronary Angiography with Conventional Coronary Angiography Correlation

Chan, I.¹; Tapp, C.²; Elliot, T.²; Lydell, C.²; Hutchison, S.²; Merchant, N.² 1. University of Western Ontario (UWO), London, Canada; 2. University of Calgary, Calgary, Canada

ELECTRONIC EXHIBITS: Cardiopulmonary

E097* Role of CT Scan in Evaluation of Cardiovascular Surgeries-A Review

Rajiah, P.¹; Kanne, J.² 1. Cleveland Clinic Foundation, Cleveland, OH; 2. University of Wisconsin, Madison, WI

E098* Video-Assisted Thorascopic Surgery (VATS): What the Radiologist Needs to Know

Parghi, C.; Tu, R.; Daluvoy, S.; Akin, E. The George Washington University, Washington, DC

E099. Pulmonary Fungal Infections in Immunocompromised Patients: A Review of the Plain Film and MDCT Radiographic Findings

Gupta, S.; Hwang, B.; Perone, R. St. Vincent's Catholic Medical Center, New York, NY

E100* Pulmonary Metastases: Spectrum of High-Resolution CT Findings with Pathological Correlations

Furuya, K.¹; Yasumori, K.¹; Sakino, I.²; Takeo, S.¹; Momosaki, S.¹; Sakai, M.¹; Hiraka, K.¹; Muranaka, T.¹ 1. National Hospital Organization Kyushu Medical Center, Fukuoka, Japan; 2. Saiseikai Yahata General Hospital, Kitakyushu-City, Japan

E101. Radiological Spectrum of Adult Congenital Lung Disease

Vummid, D.; Pipavath, S.; Godwin, D.; Stern, E.; Kicska, G.; Swanson, J.; Reddy, G. University of Washington School of Medicine, Seattle, WA

E102. Deciphering the Idiopathic Interstitial Pneumonias: CT Imaging Features of IPF, NSIP, COP, AIP, RB-ILD, DIP, and LIP

Ferguson, E.¹; Berkowitz, E.² 1. The University of Texas at Houston Medical School, Houston, TX; 2. Emory University School of Medicine, Atlanta, GA

E103. An Interactive Flash-Based 3D Tutorial For Learning Segments of the Lungs and the Pulmonary Arterial System

Javan R.¹; Jeun B.²; Duszak R.^{1,3} 1. Baptist Memorial Hospital, Memphis, TN; 2. NYP Weill Cornell Medical Center, New York, NY; 3. Mid-South Imaging and Therapeutics, Memphis, TN

E104. Hypersensitivity Pneumonitis—A Pictorial Review

Summerfield, R.; Carrillo, M.; Alturkistany, S.; Torres, F.; Patsios, D. University Health Network, Toronto, Toronto, Canada

E105. WITHDRAWN

E106. Staging of Non-Small Cell Lung Cancer (NSCLC): Review of Modalities for Identification and Sampling of Mediastinal Lymph Nodes

Chung, J.; Lanuti, M.; El-Sherief, A.; Rojas, C.; Abbott, G.; Shepard, J. Massachusetts General Hospital, Boston, MA

E107* MRI of Pericardium and Pericardial Disease

Zarzhvesky, N.; Chughtai, K.; Frank, L.; Mueller, G.; Cronin, P.; Stojanovska, J. University of Michigan, Ann Arbor, MI

E108* Advanced MR Techniques in the Evaluation of Congenital Diseases of the Pulmonary Valve and Pulmonary Arteries

Detterich, J.¹; Farvid, A.²; Uzunyan, M.²; Shinbane, J.²; Baker, C.²; Wood J.¹; Shriki J.² 1. Children's Hospital of Los Angeles, Los Angeles, CA; 2. University of Southern California, Keck School of Medicine, Los Angeles, CA



* offers CME credit

ELECTRONIC EXHIBITS: Efficacy, Education, Administration & PACS



E109. The After Action Review (AAR): A Process Improvement Method to Promote Quality and Continuous Learning

McNamara, M.^{1,2} 1. Case Medical School MetroHealth Campus/Uniformed Services University of the Health Sciences, Cleveland, OH; 2. Uniformed Services University of the Health Sciences, Bethesda, MD

E110. A New Automated Three Dimensional (3D) Mapping and Labeling System for Routine Free Hand Ultrasound Examinations, Performance Evaluation in a Breast Phantom

Caluser, C.¹; Lum, B.²; Gheorghe, B.¹ 1. No Institutional Affiliation; 2. Little Company of Mary Hospital, Evergreen Park, IL

E111. How Well Do Radiologists Remember Test Images?

Haygood, T.¹; Galvan, E.²; Lano, E.¹; Ernst, R.¹; Viswanathan, C.¹; Rohren, E.¹; Devine, C.¹; Marom, E.¹ 1. MD Anderson Cancer Center, Houston, TX; 2. Yale University, New Haven, CT

E112. CTC Training for Radiology Residents

Friedman, A.¹; Lev-Toaff, A.² 1. University of Arizona, Tucson, AZ; 2. University of Pennsylvania School of Medicine, Philadelphia, PA

E113* Evaluation of Imaging Requests Placed by Emergency Medicine Residents, Using the American College of Radiology (ACR) Appropriateness Criteria

Logie, C.¹; Bond, M.²; Nagy, P.² 1. University of Maryland Medical Center, Baltimore, MD; 2. University of Maryland School of Medicine, Baltimore, MD

E114. Cross-Sectional Appearance of Paraphrenalia in the Abdomen and Pelvis

Gulati, A.; Kielar, A. The Ottawa Hospital, Ottawa, Canada

E115. Perfection of Roentgen's Imperfect Legacy—The Removal of the Penumbra Effect by a CAD Based on the De-Convolution Technique in Nine Case Studies of X-Ray, CT and MR

Chui, K.¹; Chui, S.²; Wojciechowski, A.³; Glinkowski, W.³; Stanfield D.¹ 1. Image Enhancement Technology Ltd, Uxbridge, Middlesex, UB10 8TD., United Kingdom; 2. Prince George Regional Hospital, Prince George, Canada; 3. Medical University of Warsaw, Warsaw, Poland

E116. Labeling of Contrast Agent Containers—A Potential Source of Confusion and Error

Cohen, M. Indiana University, Indianapolis, IN

E117. Current Compression Guidelines for the Practicing Radiologist

Ali, S.; Siegel, E. University of Maryland Medical Center, Pikesville, MD

E118. Outside the Box: Radiology and Embryology: New Techniques To Understand Disease and Diagnosis

Gerard, P.; Lefkowitz, Z.; Cooper, N.; Wu, J.; Moonthungal, S. Westchester Medical Center, New York, NY

E119. Radiological Signs of Weapons and Munitions—How Will Non-Combatants Recognize Them?

Maizlin, Z.¹; Kuruvilla, M.¹; Clement, J.²; Vos, P.²; Brown, J.² 1. McMaster University Medical Centre, Burlington, Canada; 2. St.Paul's Hospital, Vancouver, Canada

E120. Assessment of Radiology Residents Prior to Starting Independent Call

Patel, N.; Richer, E.; Naumann, M.; Del Gaizo, A.; Baumgarten, D.; Mullins, M. Emory School of Medicine, Atlanta, GA

E121. eLearning-Radiology.com: Quality Assurance of Radiology Education Material in the Internet

Talanow, R.^{1,2}; Grunewald, M.³; Ketelsen D.⁴ 1. The Cleveland Clinic, Cleveland, OH; 2. EduRad, Cleveland Heights, OH; 3. University of Erlangen/Nürnberg, Erlangen, Germany; 4. Eberhard-Karls-University Tuebingen, Tuebingen, Germany

E122. Prepared for Radiology Boards? A New Concept for Radiology Exam Preparation

Talanow, R.^{1,2} 1. The Cleveland Clinic, Cleveland, OH; 2. EduRad, Cleveland Heights, OH

E123. Understanding Radiology Through Its History: An Interactive Quiz

Shepherd, S.; Hoots, J.; Foster, S. Georgetown University Hospital, Washington, DC

E124. Academic Productivity Tracking in a Teaching Radiology Department: Are the Current Methods Sufficient?

Katur, A.¹; Holalkere, N.¹; Maietta, R.²; Shaffer, K.¹ 1. Boston Medical Center, Boston, MA; 2. No Institutional Affiliation

E125. Paper Writing for Trainees: Manuscript Preparation from Conception to Publication

Johnson, P.; Fishman, E. Johns Hopkins Hospital, Baltimore, MD

E126. Next Generation Digital Teaching Files: How to Create a Robust Teaching File System by Synergizing Free Web-Based Image Storage Services and Your Teaching File Software

Logie, C.; Siegel, E. University of Maryland Medical Center, Baltimore, United States

E127. Approaches to Increasing Awareness and Usage of the ACR Appropriateness Criteria Amongst our Referring Clinicians: How Can we Contribute?

Gupta, S.; Yeghiayan, P. St. Vincent's Catholic Medical Center, NY, New York, NY

E128. Teaching Common Plain Film Discrepancies to Residents: "Jeopardy" Game Show Format

Hammer, M.; Klein, K.; Jacobson, J. University of Michigan, Ann Arbor, MI

E129. The Educational and Career Impact of Using Medical Students for Triaging Off-Hour Diagnostic Imaging Requests at a Major Academic Medical Center

Kennedy, S.¹; Knibutat, D.²; DelBasso, S.³; Bokhari, S.³; Forman, H.³ 1. New York-Presbyterian Hospital-Weill Cornell Medical Center, New York, NY; 2. Yale-New Haven Hospital, New Haven, CT; 3. Yale University School of Medicine, New Haven, CT

E130* Simulation Training in Contrast Reaction Management

Costantino, D.; Patel, A. Hospital of the University of Pennsylvania, Philadelphia, PA

ELECTRONIC EXHIBITS: Efficacy, Education, Administration & PACS



E131. Resident Familiarity with the Politics of Medical Imaging and its Perceived Overutilization

Danaie, S.; Nicholas, K.; Domanski, M.; Tu, R. George Washington University Medical Center, Washington, DC

E132. A Web-Based, History/Indication Defined Program for Protocols MRI Exams

Baker, S.¹; Talanow, R.^{2,3} 1. The University of Iowa Hospitals and Clinics, Iowa City, IA; 2. The Cleveland Clinic, Cleveland, OH; 3. EduRad, Cleveland Heights, OH

E133. New Techniques And Applications in the Teaching of NRC Concepts For The Oral Radiology Board Examination

Gerard, P.¹; Lefkowitz, Z.¹; Patel, H.¹; Mozzor, M.¹; Patel, J.² 1. Westchester Medical Center, New York, NY; 2. University Kentucky College of Medicine, Lexington, KY

E134. Will It Open? Difficulties and Solutions in Accessing CD Based Diagnostic Images

Gerard, P.¹; Lefkowitz, Z.¹; Donahue, B.²; Reis, S.¹; Seiler, M.¹ 1. Westchester Medical Center, New York, NY; 2. Maimonides Medical Center, Brooklyn, NY

E135* 21st Century Downtime Processes for a Large Multispecialty Radiology Practice

Wood, C.; Williamson, S.; Riley, K. Mayo Clinic, Rochester, MN

E136* www.PubRad.org—PubMed for Radiology

Talanow, R.^{1,2}; Giesel, F.³ 1. The Cleveland Clinic, Cleveland, OH; 2. EduRad, Cleveland Heights, OH; 3. German Cancer Research Center (DKFZ) Heidelberg, Heidelberg, Germany

E137. Voice Controllable Digital Radiology: VCDR Cockpit Equipped with Eight Synchronizing Multimotors

Ukisu, R.; Koyama, K.; Yagi, S.; Fukushima, T.; Ohba, K.; Fujisawa, H.; Takenaka, H.; Kushihashi, T. Showa University Northern Yokohama Hospital, Yokohama, Japan

E138. Patient Safety in Radiology and Nuclear Medicine: Review of Current Concepts and New Strategies for Improvement in Daily Practice

Gerard, P.¹; Lefkowitz, Z.¹; Piechota, D.²; Hira, A.¹; Nilsen, E.¹; Lee, R.¹ 1. Westchester Medical Center, New York, NY; 2. Maimonides Medical Center, Brooklyn, NY

E139* Radiology of Pregnant and Lactating Patients: Evidence-Based Review of Imaging Issues and Recommendations

Wang, P.¹; Chong, S.¹; Knoepp, U.¹; Kielar, A.² 1. University of Michigan, Ann Arbor, MI; 2. The Ottawa Hospital, Ottawa, Canada

E140. The Joint Commission Patient Safety Goal 2: Improve Communication Among Caregivers—What the Radiologist Needs to Know

Gentili, A. University of California San Diego, San Diego, CA

E141. Residual Magnetism in MRI Suites after Quench and Controlled Rampdown of Superconducting Ultrahigh Field Magnets

Sammet, S.¹; Aguila, F.¹; Koch, R.^{1,2}; Knopp, M.¹ 1. The Ohio State University, Columbus, OH; 2. Brigham and Women's Hospital, Boston, MA

E142. Semiautomatic Audit of Documentation of Exposure Time for Procedures Using Fluoroscopy

Gentili, A. University of California San Diego, San Diego, CA

E143. Focused Professional Practice Evaluation (FPPE) and Ongoing Professional Practice Evaluation (OPPE): What the Radiologist Needs to Know

Gentili, A. University of California San Diego, San Diego, CA

E144. The Effect of Paper or Cloth Gowns on Total Skin Electron Irradiation Dose

Hopkins, S.; Steinman, J.; Wang, J. Roswell Park Cancer Institute, Buffalo, NY

E145. Optimizing Consistent CT Contrast Enhancement with Graphical Correlation of Contrast Injection Delivery

Shet, N.¹; Siegel, E.^{1,2} 1. University of Maryland Medical Center, Baltimore, MD; 2. Baltimore VA Medical Center, Baltimore, MD

E146* Partnering with Engineers: Techniques of Data Collection for Process Improvement in MR

Brandon, C.; Jacobson, J.; Fessell, D. University of Michigan, Ann Arbor, MI

E147. In the Dark of the Night: UCSF Experience Using NightHawk Radiology Service for Resident Backup

Panko, J. University of California San Diego, San Diego, CA

E148. Tools To Improve Communication In The Radiology Department: Daily Exercises and Practical Applications

Gerard, P.¹; Lefkowitz, Z.¹; Miller, C.²; Shah, J.¹; Moonthungal, S.³ 1. Westchester Medical Center, New York, NY; 2. Maimonides Medical Center, Brooklyn, NY; 3. Hackensack University Medical Center, Hackensack, NJ

E149. Analysis Of The Radiologist Report: A Historical Review, New Concepts, The Clinician Point Of View and Can We Improve?

Gerard, P.¹; Lefkowitz, Z.¹; Miller, C.²; Wu, J.¹; Dua, S.¹; Seiler, M.¹ 1. Westchester Medical Center, New York, NY; 2. Maimonides Medical Center, Brooklyn, NY

E150. RadLex for Dummies—A How-to Tutorial and Practical Example for Integrating RadLex for Individual Needs

Talanow, R.^{1,2} 1. The Cleveland Clinic, Cleveland, OH; 2. EduRad, Cleveland Heights, OH

E151* Correlation of Imaging Findings of the Spine with Clinical Syndromes via an Innovative, Interactive 3D Computer Application

Sher, A.; Vogelius, E.; Robbin, M. University Hospitals, Case Medical Center, Cleveland, OH

E152* Physician Documentation of Fluoroscopy Time in VCU Reports Correlates with Lower Fluoroscopy Times

Sammer, M.^{1,2}; Parisi, M.^{1,2}; Chapman, T.^{1,2} 1. Seattle Children's, Seattle, WA; 2. University of Washington, Seattle, WA

** offers CME credit*

ELECTRONIC EXHIBITS: General & Emergency Radiology



E153* The Triple Rule-Out CTA: Parameters, Protocols and Case Review

Aquino, M.; Nandalur, K. William Beaumont, Royal Oak, MI

E154. Multimodality Imaging of Erdheim-Chester Disease

Nguyen, B. Mayo Clinic, Scottsdale, AZ

E155* Opening Pandora's Box: Hope Remains for the Multidetector CT (MDCT) Evaluation of Small Bowel and Mesentery Injuries in Blunt Abdominal Trauma

Wells, S.; Chong, S.; Knoepp, U.; Mazza, M.; Al-Hawary, M. Michigan, Ann Arbor, MI

E156* Abdominal Plain Film Versus Multidetector CT in the Evaluation of Nonspecific Abdominal Pain in the Emergency Department: A Model for Evaluating Process, Cost and Effectiveness

Ptak, T.; Milne, L.; O'Brien, M. Massachusetts General Hospital, Needham, MA

E157. WITHDRAWN

E158* Use of CT Pulmonary Angiography in an Emergency Setting: Audit in the Townsville Hospital

Wilfred N.¹; Banks C.²; Lamont A.² 1. Princess Alexandra Hospital, Brisbane, Australia; 2. Townsville Hospital, Townsville, Australia

E159* "Taking My Breathe Away": MDCT in the Evaluation of Diaphragmatic Injuries

Garcia, L.; Nieves, D.; Gomez, A.; Sepulveda, J.; Rivera, G.; Lopez, Y.; Rivera, W. University of Puerto Rico, Medical Sciences Campus, San Juan, PR

E160* Hydatid Disease From Head To Toe MDCT Evaluation of Imaging Findings in Hydatid Disease—Both Uncomplicated and Complicated Cases

Kumar, V.; Pandhi, S.; Vaishnav, K.; Goswami, K.; Parida, S. Gujarat Cancer and Research Institute, Ahmedabad Gujarat, India

E161* "Putting Together the Jigsaw Puzzle": The Role of MDCT in the Characterization of Maxillary Bone Fractures

Nieves, D.; Garcia, L.; Vidal, J. University of Puerto Rico, Medical Sciences Campus, San Juan, PR

E162* "Broken Jaw": The Role of MDCT in the Evaluation of Mandibular Bone Fractures

Peguero, L.; Pabon, A.; Perez, V.; Santacana, G.; Vidal, J.; Garcia, L. University of Puerto Rico, Medical Sciences Campus, San Juan, PR

E163. Imaging of Non-Traumatic Abdominal Pain in the Emergency Department: Differential Diagnosis and Pictorial Essay of Usual and Unusual Causes

França, M.; Certo, M.; Ramos, A.; Pires, J.; Varzim, P. Centro Hospitalar do Porto, Maia, Portugal

E164* All Right Lower Quadrant Pain Is Not Appendicitis

Aggarwal, A.; Golan, S.; Rausch, D.; Simpson, W. Mount Sinai Medical Center, New York, NY

E165* Blunt Abdominothoracic Trauma—Case-Based Review

Chaudhary, H.; Calleros, J. Texas Tech University Health Science Center, El Paso, TX

E166* Extraluminal Gas in the Abdomen: Where is it? What Does it Mean?

França, M.; Certo, M.; Santos, P.; Maia, R.; Varzim, P. Centro Hospitalar do Porto, Maia, Portugal

E167* Imaging of Impacted Fish Bones in the Aerodigestive Tract: Pitfalls and Complications

Win, T.; Poh, A.; Chan, E. Changi General Hospital, Singapore, Singapore

E168* "Leaky Abdomen": Role of MDCT in the Evaluation of Traumatic Bowel and Mesenteric Injuries

Peguero, L.; Garcia, L.; Conde, Z.; Font, S.; Gomez, A.; Colon, E.; Ballester, G. University of Puerto Rico, Medical Sciences Campus, San Juan, PR

E169* Air Bubbles: Where and Why?

Baleato González S.¹; Garcia Figueiras R.²; Vilanova J.³; Barral Juez I.⁴; Villalba Martin C.²; Tardáguila F.¹ 1. POVISA, Vigo, Spain; 2. CHUS, Santiago De Compostela, Spain; 3. Clínica Girona-Hospital santa caterina, Girona, Spain; 4. CHOP, Pontevedra, Spain

E170* Imaging Patterns of Acute Intracranial Hemorrhage

Goud, A.¹; Goud, A.²; Nguyen, B.² 1. VA Boston, Boston, MA; 2. University of California Irvine, Orange, CA

E171* Cervical Spine On-Call: What Every Resident Needs to Know

Ali, S.; Awan, O. University of Maryland Medical Center, Pikesville, MD

E172* Anatomic Positioning System (APS): Accuracy of Localization of Mock Blast Fragments on CT in Three Dimensions

Shogan, P.¹; Fischer, T.²; Long J.¹; Frew M.¹; Bunger R.²; Folio L.²; Provenzale, J.³ 1. Walter Reed Army Medical Center, Washington, DC; 2. Uniformed Services University, Bethesda, MD; 3. Duke University Medical Center, Durham, NC

E173* Multimodality Pictorial Review Of Post-Transplant Lymphoproliferative Disorder: Spectrum Of Imaging Appearances from Head-to-Toe

Shah, C.; Bhanushali, A.; Newhouse, J.; Dsouza, B.; Ruzal-Shapiro, C. NY Presbyterian Hospital, Columbia, New York, NY

E174* Imaging of Lymphoma Cousins: Likes and Mimics

Hall, M.; Jagannathan, J.; Ramaiya, N.; Shinagare, A.; Van den Abbeele, A. Dana-Farber Cancer Institute, Boston, MA

E175. Overview of The Various Existing Radiological Tumor Assessment Criteria for Evaluating Tumor Response

Oliveira, G.¹; Bhargava, P.¹; Dubinsky, T.¹; Harisinghani, M.² 1. University of Washington, Seattle, WA; 2. Massachusetts General Hospital, Boston, MA

E176. How Your Clinical Report Answers the Hemato Oncologists Questions in Lymphoma Patients?

Oliveira, G.; Dubinsky, T.; Gopal, A. University of Washington, Seattle, WA

* offers CME credit

E177* What Has Changed Between Recist and Recist 1.1?

Oliveira, G.¹; Bhargava, P.¹; Dubinsky, T.¹; Harisinghani, M.² 1. University of Washington, Seattle, WA; 2. Massachusetts General Hospital, Boston, MA

E178* Mesenteric Injury in Blunt Trauma: What the Trauma Surgeon Needs to Know

Choudhary, S.; Philips, P.; Sunnapwar, A.; Patel, A. University of Texas Health Science Centre, San Antonio, TX

E179. Using Central Lines and Catheters for Power Injectors During CT Scans: What You Need to Know

Laxpati, M.; Jung, A.; Palmer, S.; Reddy, S.; Cheng, P.; Duddalwar, V. University of Southern California, Los Angeles, CA

E180* Recist 1.1: What is Different from Recist 1.0?

Braschi, M.¹; Ramaiya, N.²; Urban, T.¹; Kurra, V.¹; Harris, G.¹; Van den Abbeele, A.² 1. Massachusetts General Hospital, Watertown, MA; 2. Dana Farber Cancer Institute, Boston, MA

E181* Imaging Features of Solitary Fibrous Tumors

Ginat, D. University of Rochester, Rochester, NY

E182* The Evolving Face of 3D-Imaging as a Biomarker: Clinical Significance and Evidence-Based Support

Singh, A.; Sahani, D.; Cai, W.; Harmon, D.; Yoshida, H.; Uppot, R.; McGowan, J.; Harris, G. Massachusetts General Hospital, Boston, MA

E183. Lawsuits and Lines: Improving Recognition and Removing Retained Vascular Devices

Peters, G.; Whang, G.; Mogel, G.; Park, J.; Palmer, S. Keck School of Medicine, University of Southern California, Los Angeles, CA

E184. Ultrasound Imaging: A Dynamic Training Modality

Yilmaz, Z.; Klein, K.; Pandya, A.; Patterson, S. University of Michigan, Ann Arbor, MI

E185* Developing an Automated Process to Notify the Emergency Department of Significant Changes in On-Call Resident Interpretations Requiring Non-Urgent Follow-up

Itri, J.; Redfern, R.; Boedec, C.; Mercer, E.; Scanlon, M.; Datner, E. University of Pennsylvania Hospital, Philadelphia, PA

E186. WITHDRAWN**E187. The Inguinal Region; Hernias and Beyond**

O'Brien, J.; Grebenyuk, J.; Forster, B.; Andrews, G. UBC Hospital, Vancouver, Canada

E188* CT Artifacts in the Obese Patient

Gunn, M.; Kanal, K.; Stewart, B. University of Washington, Seattle, WA

E189. The Radiological Evaluation of "New Age Artifacts"

Gerard, P.; Lefkowitz, Z.; Nichols, R.; Chang, P. Westchester Medical Center, New York, NY

E190* Malpositioned Tubes and Lines in the Chest, Abdomen, and Pelvis: A Pictorial Review

Ginat, D.; Bashay, V.; Sidhu, R.; Wandtke, J. University of Rochester, Rochester, NY

E191* Fat Saturation Techniques: Physics and its Applications

Kanekar, S.; Sarwani, N.; Tappouni, R.; Walker, E. Penn State Milton S. Hershey Medical Center, Hershey, PA

E192* Role of Quality Improvement in Patient Satisfaction: Radiology Departmental Study

Ishak, C.; Kanth, N.; Lev, S.; Albanese, N.; Scarmato, V. Nassau University Medical Center, East Meadow, NY

E193* Infection Control in a Department of Radiology: Preparing for the Unknown!

Paul, N.; Nankooosingh, V.; Summerfield, R.; Maria, C.; Alturkistany, S.; Torres, F.; Patsios, D.; Roberts, H. University of Toronto, Toronto, Canada

E194* The Essentials of Ectopic Pregnancy: An On-Call Guide

Rausch, D.; Aggarwal, A.; Simpson, W. Mount Sinai Medical Center, New York, NY

E195* "Go With the Flow": The Role of MDCT Angiography in the Evaluation of Traumatic Peripheral Vascular Injuries

Nieves, D.; Garcia, L.; Badillo, K.; Vidal, J.; Gomez, A.; Rodriguez Adorno, D. University of Puerto Rico, Medical Sciences Campus, San Juan, PR

E196. Imaging of Air: How Did That Air Get There?

Kaushik, C.; Pandey, T.; Jumper, Z.; Viswamitra, S.; Jambhekar, K. University of Arkansas, Little Rock, AR

E197* CT of Acute Perianal Abscess and Infected Fistulae: A Pictorial Essay

Sondel, N.; Khati, N.; Zeman, R.; Hill, M. The George Washington University Hospital, Potomac, MD

E198* CT of the Skin

Katz, D.; Ganson, G.; Klein, M.; Mazzie, J. Winthrop-University Hospital, Mineola, NY

E199. Adaptive Statistical Iterative Reconstruction (ASIR) of Body CT Data Reduces Dose While Maintaining Image Quality

Kaplan, J.; Simpson, W.; Lee, K.; Tanenbaum, L. Mount Sinai Medical Center, New York, NY

E200* Spectrum of Craniocervical Junction Injuries

Punjwani, N.; Cheekatla, S. University of Texas at Houston, Sugar Land, TX

E201* Thoracic Spine Trauma: MDCT and MRI Correlation

Padua, S.; Garcia, L.; Badillo, K.; Vidal, J.; Gomez, A. University of Puerto Rico, Medical Sciences Campus, San Juan, PR

E202* "Taking a Chance": MDCT and MRI Correlation of Lumbar Spine Fractures

Garcia, L.; Badillo, K.; Vidal, J.; Gomez, A. University of Puerto Rico, Medical Sciences Campus, San Juan, PR

ELECTRONIC EXHIBITS: General & Emergency Radiology



E203. The Routine Use Of MRI in the Evaluation of Uncomplicated Ligamentous Injury in Conscious Post-Trauma Patients: Literature Review, Meta-Analysis and Decision Model

Ptak, T.; O'Brien, M. Massachusetts General Hospital, Needham, MA

E204* Emphysematous Infections of the Abdomen and Pelvis: A Comprehensive Review

Parizi, M.1; Ojili, V.1; Nagar, A.2; Chintapalli, K.1 1. University of Texas Health Science Center at San Antonio (UTHSCSA), San Antonio, TX; 2. Ohio State University Medical Center, Columbus, OH

E205* Imaging the Pregnant Woman for Non-Obstetric Reasons: What You Need to Know

Reddy, S.; Palmer, S.; Duddalwar, V.; Jung, A.; Nagata, K.; Inaba, K.; MacDonald, H.; Bright, A. LAC-USC Medical Center, La Canada, CA

E206* Pseudoaneurysms of the Chest, Abdomen, and Pelvis: Body Imagers Beware

Gordon, S.; Lobko, I.; Hoffman, J. Long Island Jewish Medical Center, Astoria, NY

E207. Clinical Mimickers of Lower Extremity Deep Venous Thrombosis: Ultrasound Diagnosis

Gunabushanam, G.; Krishnamoorthy, S.; Scoutt, L. Yale University School of Medicine, New Haven, CT

** offers CME credit*



E208* The Atypical Appendix

Javors, B.¹; Morehouse, H.¹; Merunka, V.²; Reddy, B.¹; Katz, D.³ 1. Bronx-Lebanon Hospital Center, Bronx, NY; 2. Beth Israel Medical Center, New York, NY; 3. Winthrop-University Hospital, Mineola, NY

E209* "Rule out Appendicitis": To Be or Not to Be

Virmani, V.¹; Papadatos, D.¹; Fasih, N.¹; Kielar, A.¹; Sethi, V.² 1. University of Ottawa, Ottawa, Canada; 2. Christian Medical College, Ludhiana, Ottawa, Canada

E210* Cholangiocarcinoma and Its Mimics

Torres, F.¹; Peng, L.¹; Hsu, J.¹; Menias, C.² 1. Kaiser Permanente LAMC, Los Angeles, CA; 2. Mallinckrodt Institute of Radiology, St. Louis, MO

E211* "Who is Choking Me?" Biliary Strictures—A Pictorial Review

Sonavane, S.; Kantawala, K.; Menias, C. Mallinckrodt Institute of Radiology, St. Louis, MO

E212* Uncommon Biliary Pathologies—A Multi-Modality Pictorial Essay

Sykes, J.; Bhatt, S.; Sidhu, R.; Dogra, V. University of Rochester, Rochester, NY

E213. Skeletons in the Corner: A Systematic Approach to the Evaluation of Body MRI in Order to Routinely Identify Bone, Soft Tissue and Spinal Abnormalities and Other Subtle Findings at the Edge of the Field of View

Adhya, S.; Ambruster, S.; White, E.; Wilcox, A.; Palmer, S. Keck School of Medicine, University of Southern California, Los Angeles, CA

E214* MDCT Evaluation of Acute Mesenteric Ischemia: An ABC's Approach

Schieda, N.; Papadatos, D.; Shabana, W. The University of Ottawa, The Ottawa Hospital, Ottawa, Canada

E215* Going, Going, Gone: Bowel Ischemia from Compromise to Necrosis

Mastropasqua, A.; Lynskey, G.; Szilagyi, S. Beth Israel Medical Center, New York, NY

E216. Diagnostic Performance of CT in Detection of Intestinal Ischemia Associated with Small Bowel Obstruction by Using Maximal Attenuation of Region-of-Interest

Kyung Mi, J.; Su Yeon, H.; Min Jeong, K.; Sung Hye, K.; Kwansoep, L.; Kwangseon, M. Hallym Sacred University, Anyang, Korea

E217. Oral Contrast Administration in Abdomen and Pelvis CT: Is it Essential?

Verma, R.; Bayanati, H.; Schwarz, B.; Shabana, W. The Ottawa Hospital, Ottawa, Canada

E218* MR Appearance of Normal Bowel and Bowel Pathology

Lee, H.¹; Kissin, I.¹; Prince, M.^{1,2} 1. Columbia University College of Physicians and Surgeons, New York, NY; 2. Weill Medical College of Cornell University, New York, NY

E219* Evaluation of Focal Small Bowel Pathologies with CT Entrography, Where Do We Stand?

Dykstra, J.; Sokhandon, F.; Shirkhoda, A. William Beaumont Hospital, Bloomfield Hills, MI

E220. Significant Extra Colonic Findings on CT Colonography: Incidence and Outcome of Patients

Alrujaib, M.; Ciarallo, A.; Giovanni, A.; Stein, I. McGill University, Montreal, Canada

E221. Is the Impact of Family History on CT Colonography Results and Optical Colonoscopy Referral Rates Overstated?

Hinshaw, L.; Kim, D.; Kehoe, P.; Pickhardt, P. University of Wisconsin School of Medicine and Public Health, Madison, WI

E222. Accuracy and Time-Efficiency of 3D CT Colonography of Pig Phantoms: Conventional 3D Versus New Panoramic 3D Interpretation

Choi, J.¹; Kim, S.²; Choi, B.²; Han, J.²; Kim, S.²; Park, H.²; Lee, J.²; Lee, J.² 1. National Cancer Center, Goyang-si, South Korea; 2. Seoul National University Hospital, Seoul, Korea

E223. Contrast Enemas: High-Yield Techniques and Top Diagnoses

Coquia, S.; Bau, J.; Peterson, C.; Hartman, D. Penn State Hershey Medical Center, Hershey, PA

E224. Intussusception From the Cradle to the Grave

Kim, Y.¹; Cho, O.²; Jeong, W.¹; Kim, E.¹; Lee, S.³ 1. Hanyang University Kuri Hospital, Kuri city, Kyunggido, Korea; 2. Hanyang University Hospital, Seoul, Korea; 3. Korea University Guro Hospital, Seoul, Korea

E225. 3T Dynamic Contrast MRI in a Phase II Trial of a Multi-targeted Receptor Tyrosine Kinase Inhibitor in Relapsed and Refractory Gastroesophageal Cancers

Sammet, S.; Clark, D.; Bhinder, A.; Tahiri, S.; Bekaii-Saab, T.; Knopp, M. Ohio State University, Columbus, OH

E226. Gallbladder Carcinoma: Spectrum of Imaging Findings and Mimics

Volpacchio, M.^{1,2}; Santamarina, M.³; Lopez, Mora J.¹; Franco, V.¹; Quipildor, M.²; Lell, A.²; Montes, F.¹ 1. Centro de Diagnóstico Dr Enrique Rossi, Buenos Aires, Argentina; 2. Hospital de Clínicas Jose de San Martín, Buenos Aires, Argentina; 3. Hospital Almirante Nef, Viña del Mar, Chile

E227. The Dropped Gallstone, the Protean Imaging Manifestations of an Overlooked Entity

Wood, C.; Nikolaidis, P.; Taffel, M. Northwestern University, Chicago, IL

E228. Differentiating Between Chronic and Acute Cholecystitis by Ultrasound

Danaie, S.; Nicholas, K.; Hill, M.; Zeman, R. George Washington University Medical Center, Washington, DC

E229* Intestinal Lipomatosis: A Multimodality Imaging Review of Lipomatous Polyposis and Epiploic Lipomatosis with Radiologic-Pathological Correlation

Gould, C.¹; Lattin, G.^{2,3}; Lewis, R.^{1,2}; Tan, J.⁴ 1. National Naval Medical Center, Bethesda, MD; 2. Armed Forces Institute of Pathology, Washington, DC; 3. Uniformed Services University of the Health Sciences, Bethesda, MD; 4. 48th Medical Group, RAF Lakenheath, United Kingdom

E230. WITHDRAWN

* offers CME credit

ELECTRONIC EXHIBITS: GI, Liver, Biliary & Pancreas



E231* MDCT Features of Gastroduodenal Cystic Lesions: Endoscopic and Pathologic Correlation

Kim, H.; Lim, J.; Lee, D.; Ko, Y. Kyung Hee University Medical Center, Seoul, Korea

E232* Gastric Emphysema: Causes, Clinical Implications, and CT Findings

Johnson, P.; Horton, K.; Fishman, E.; Scott, W. Johns Hopkins Hospital, Baltimore, MD

E233* Primary Colorectal Lymphomas: What Radiologist Should Know

Sunnapwar A.1; Katre, R.1; Choudhary, S.1; Prasad, S.1; Nagar, A.2 1. UTHSCSA, San Antonio, TX; 2. OSU, Columbus, OH

E234* Recognition of Chemotherapy Related Changes in the Abdomen and Pelvis: Imaging and Perspectives!

Lall, C.1; Lamba, R.2; Trilikis, G.1; Helmy, M.3; Saremi, F.3; Cohen, A.3; Verma, S.4; Wolbrink, D.1 1. Indiana University School of Medicine, Indianapolis, IN; 2. University of California, Davis, Davis, CA; 3. University of California, Irvine, Orange, CA; 4. University of Cincinnati Medical Center, Cincinnati, OH

E235* Hypervascular Gastric Masses: MDCT Protocol Optimization, Postprocessing Techniques, and Interpretative Pitfalls

Johnson, P.; Horton, K.; Fishman, E. Johns Hopkins Hospital, Baltimore, MD

E236. Pictorial Review of Gastric Cancer with Rad-Path Correlation

Lance, V.; Lee, E.; Kee, S.; Loh, C. UCLA Medical Center, Los Angeles, CA

E237* Hypotonic CT Duodenography: A Pictorial Essay

Bayanati, H.; Mojtabaie, P.; Tao, H. University of Ottawa, Ottawa, Canada

E238* Imaging of Abdominal Inflammatory Myofibroblastic Tumor with Pathologic Correlation

Reiter, M.1,2; Lewis, R.1,2; Lattin, G.1 1. Armed Forces Institute of Pathology, Washington, DC; 2. National Naval Medical Center, Bethesda, MD

E239. Laparoscopic Port Complications: Cruising Issues; An Imaging Perspective!

Lall, C.1; Verma, S.2; Lamba, R.3; Saremi, F.4; Helmy, M.4; Sandrasegaran, K.1; Trilikis, G.1; Wolbrink, D.1 1. Indiana University School of Medicine, Carmel, IN; 2. University of Cincinnati Medical Center, Cincinnati, OH; 3. University of California, Davis, Davis, CA; 4. University of California, Irvine, Orange, CA

E240* Genetic Conditions Associated with Gastrointestinal Neoplasms: A Review of the Spectrum of Findings on CT

Earhart, C.; Ricker, C.; Tang, S.; Abboud, G.; El-Khoueiry, A.; Iqbal, S.; Lenz, H.; Shriki, J. University of Southern California, Keck School of Medicine, Los Angeles, CA

E241. Common Radiographic Signs in Abdominal Plain Film Imaging

Menon, S.1; Loree, R.1; Ortiz-Romero, S.1; Szilagy, S.1; Yim, A.1; Frager, D.2; Cooke, K.2 1. Beth Israel Medical Center, New York, NY; 2. St. Luke's Roosevelt Hospital, New York, NY

E242. Non-Meckelian Intestinal Diverticulosis and its Complications: A Multimodality Imaging Review with Pathologic Correlation

Walker, D.1; Lattin, G.2,3; Jesinger, R.1,3; Tubay, M.1,4; Lewis, R.2; Dalal, K.1; Scherre, M.1; Grider, D.1 1. David Grant USAF Medical Center, Travis AFB, CA; 2. Armed Forces Institute of Pathology, Washington, DC; 3. Uniformed Services University of the Health Sciences, Bethesda, MD; 4. University of Utah Health Care, Salt Lake City, UT

E243. Twists and Turns in the Abdomen: A Pictorial Review of Solid Organ, Hollow Viscus, and Abdominal Fat Torsions with Pathologic Correlation

Timpone, V.1; Lattin, G.2,3; Jesinger, R.1,3; Lewis, R.2; Tubay, M.1,4; Azuar, K.1; DeMartini, S.1; Scherrer, M.1 1. David Grant USAF Medical Center, Travis AFB, CA; 2. Armed Forces Institute of Pathology, Washington, DC; 3. Uniformed Services University of the Health Sciences, Bethesda, MD; 4. University of Utah Health Care, Salt Lake City, UT

E244. Guide to Hollow Viscera Surgical Procedures

Roberts, A.; Fanous, R.; Jaffer, N.; McLeod, R.; Chawla, T.; Au, F.; Ghai, S. University of Toronto, Toronto, Canada

E245. WITHDRAWN

E246. Three Phase Swallow Study: Description of Normal Anatomy and Spectrum of Pathology Using Video Format

Washnik, A.; Al-hawary, M.; Kaza, R.; Liu, P.; Cohan, R.; Sonda, P. University of Michigan, Ann Arbor, MI

E247* Bariatric Procedures: Multi-Modality Approach Demonstrating Normal Post-Op Appearance, Common Complications and Challenging Cases

Bau, J.; Peterson, C.; Hal, H. Penn State Hershey Medical Center, Hershey, PA

E248. Recurrence Patterns of Gastrointestinal Tumors

Oliphant, M. Wake Forest University, Winston Salem, NC

E249. Imaging of Metastatic Neuroendocrine Tumors (NET)

Shore, K.; Jagannathan, J.; Ramaiya, N.; Shinagare, A.; Van den Abbeele, A. Dana Farber Cancer Institute, Boston, MA

E250. The Role of PET and Combination PET/CT in the Evaluation of Patients with Inflammatory Bowel Disease

Halpenny, D.1; Burke, J.2; O'Connell, M.3 1. Adelaide and Meath Hospitals Incorporating the National Childrens Hospital, Dublin 24, Ireland; 2. St. Colmcille's Hospital, Loughlinstown, Dublin, Ireland; 3. Mater Hospital, Dublin, Ireland

E251. Complications of Lower Abdominal Surgery: What Went Wrong? An Interactive Teaching File

Hartman, D.; Dulka, S.; Showalter, M.; Swehla, B. MS Hershey Medical Center, Hershey, PA

E252. Potentiality of MR in the Mesorectal Fascia Assessment

Saba, L.; Fantola, G.; Casula, F.; Mallarini, G. Azienda Ospedaliero Universitaria, Cagliari Sardegna, Italy

E253. CT Enterography in Patients with Crohn Disease: Pearls and Pitfalls

Torrazo, H.; Costa, C. Hospital de Braga, Braga, Portugal

E254. Evaluation of Biphasic Sixty-four Row MDCT with Mesenteric CT Angiography in the Detection of Acute Mesenteric Ischemia

Vivian, M.; Kirkpatrick, I.; Kroeker, M.; Henderson, B. University of Manitoba, Winnipeg, Canada

E255* Spectrum of Malignant Hepatic Neoplasms in Pediatric Population—MDCT Evaluation

Kumar, V.; Pandhi, S.; Vaishnav, K.; Goswami, K.; Sethi, S. Gujarat Cancer and Research Institute, Ahmedabad Gujarat, India

E256* Unusual Primary Hepatic Masses

Madrazo, B.¹; Casillas, J.¹; Dreizin, D.¹; Amendola, M.²; Akhter, N.¹; Castillo, R.¹ 1. University of Miami Miller School of Medicine, Miami, FL; 2. No Institutional Affiliation

E257. Usefulness of Liver Perfusion CT in the Evaluation of Portal Hypertension: Comparison with Hepatic Venous Pressure Gradient and Wedge Hepatic Venous Pressure Measured by Hepatic Vein Catheterization

Chung, D. St. Mary's Hospital, Catholic University of Korea, Seoul, South Korea

E258. Characterization of Benign and Malignant Hepatic Lesions Using Gadoxetate Disodium Enhanced MRI

Haddad, F.; Hill, M.; Zeman, R. George Washington University Hospital, Washington, DC

E259. Save the Liver Transplant: A Radiology Resident's On-Call Guide

Rausch, D.; Simpson, W. The Mount Sinai Medical Center, New York, NY

E260. Interactive Flash-Based 3D Tutorial of the Liver Segmental and Vascular Anatomy

Javan, R.; Duszak, R. Baptist Memorial Hospital, Memphis, TN

E261. Acute Hepatic Failure: It's Varied Imaging Appearance with Pathological Correlation and Comparison to Chronic Liver Failure

Romero, M.¹; Fong, T.¹; Palmer, S.¹; Ihde, L.¹; Kosco, A.²; Lin, L.² 1. Keck School of Medicine, University of Southern California, Los Angeles, CA; 2. Kaiser Permanente, Los Angeles Medical Center, Los Angeles, CA

E262. Early Experiences Utilizing Gadoxetate Disodium in the Evaluation of Hepatic and Biliary Lesions

Tingle, E.; Glastad, K. Baylor University Medical Center, Dallas, TX

E263* Liver Transplant and Beyond: MR Imaging Findings

Khatri, G.; Miller, F. Northwestern University Feinberg School of Medicine, Chicago, IL

E264. Introduction to the One and Only Hepatocyte Specific, FDA Approved MRI Contrast Agent—Gadoxetate Disodium

Jacob, R.; Chimpiri, A.; Keller, R. Oklahoma University Health Sciences Center, Oklahoma City, OK

E265* Uncommon Benign Liver Tumors and Pseudotumors: Cross-Sectional Imaging Spectrum

Shanbhogue, A.¹; Zaheer, A.²; Katabathina, V.¹; Sandrasegaran, K.³; Takahashi, N.⁴; Prasad, S.¹ 1. University of Texas Health Science Center at San Antonio, San Antonio, TX; 2. The Johns Hopkins Hospital, Baltimore, MD; 3. Indiana Institute for Biomedical Imaging Sciences, Indianapolis, IN; 4. Mayo Clinic, Rochester, MN

E266* Gadopentate Dimeglumine and Gadoxetate Disodium: Delayed Imaging in Liver MR

Boriskin, H.¹; Villani, R.¹; Hines, J.^{1,2}; Grimaldi, G.¹; Ben-Levi, E.¹; Friedman, B.^{1,2}; Burge, A.¹ 1. North Shore University Hospital, Manhasset, NY; 2. Long Island Jewish Medical Center, New Hyde Park, NY

E267. Hepatocyte-Specific MR Contrast Agent: Improved Lesion Characterization with Gd-EOB-DTPA

Puryzko, A.; Remer, E.; Veniero, J. Cleveland Clinic Foundation, Cleveland, OH

E268. Beyond ADC: Diffusion-Weighted MR Imaging of Small Liver Lesions

Johnson, P.; Jurasic, M.; Bridges, M. Mayo Clinic, Jacksonville, FL

E269* The Many Faces of Focal Nodular Hyperplasia with Gd-EOB-DTPA at 3T MRI

Sosnowski, R.; Mwangi, I.; Sirlin, C. UCSD, San Diego, CA

E270* A Pictorial Review of Fat-Containing Liver Abnormalities

Heaslip, I.; Hegarty, C.; Gibney, R.; Malone, D.; Skehan, S.; Heffernan, E. St. Vincent's University Hospital, Dublin 4, Ireland

E271. Intrahepatic Periportal Enhancement on Hepatobiliary Phase Images of Gd-EOB-DTPA Enhanced MRI: Imaging Findings and the Prevalence in Various Hepatobiliary Diseases

Kobayashi, S.; Matsui, O.; Gabata, T.; Koda, W.; Minami, T.; Ryu, Y.; Kozaka, K. Kanazawa University, Kanazawa, Japan

E272. In-vivo and Ex-vivo MR Imaging of Excised Human Livers and Histological Correlation on Treated Hepatocellular Carcinomas

Yoon, J.^{1,2}; Mwangi, I.¹; Eachmad, E.¹; Claude, S.¹; Peterson, M.¹ 1. University of California San Diego, UCSD Medical Center, Hillcrest, San Diego, CA; 2. Busan Paik Hospital, Inje University College of Medicine, Busan, Korea

E273. Imaging Characteristics of Gadoxetate Disodium Injection in Human Liver: How much Delayed Imaging is Sufficient?

Chow, D.; Margolis, D.; Schwoppe, R.; Lu, D.; Raman, S. University of California, Los Angeles, Los Angeles, CA

E274. Association of Hepatic Hemangiomas with Giant Hemangioma: Prevalence and Clinical Relevance

Jhaveri, K.¹; Paraskevi, V.¹; Shah, S.²; Haider, M.¹; Ayyapan, A.¹; Khalili, K.¹ 1. University of Toronto, Toronto, Canada; 2. Cleveland Clinic, Cleveland, OH

E275. Unusual Presentations of Hepatocellular Carcinoma—A Review

Bhargava, P.¹; Oliveira, G.²; Vaidya, S.²; Yeh, M.²; Dighe, M.² 1. University of Washington & VA Puget Sound Health Care System, Seattle, WA; 2. University of Washington, Seattle, WA

* offers CME credit

ELECTRONIC EXHIBITS: GI, Liver, Biliary & Pancreas



E276. Parasitic Disease of the Liver: A Review of the Spectrum of Disease and Appearance

Ihde, L.¹; Earhart, C.¹; Abboud, G.¹; Sadeghi, A.¹; Buxbaum, J.¹; Grant, E.¹; Duddalwar, V.²; Klipfel, N.¹ 1. University of Southern California, Keck School of Medicine, Los Angeles, CA; 2. USC Norris Cancer Hospital, Los Angeles, CA

E277. The Role of Ultrasound Fusion Imaging in Abdominal Interventions

Tchelepi, H. Wake Forest University School of Medicine, Winston Salem, NC

E278. Intraoperative US of the Liver in Primary and Secondary Malignant Liver Neoplasms: Comparison to State-of-the-Art Preoperative Imaging

Wagnetz, U.¹; Wei, A.²; Massey, C.³; Atri, M.¹; Metser, U.¹ 1. Radiology, Toronto, Canada; 2. Surgery, Toronto, Canada; 3. Biostatistician, Toronto, Canada

E279. Portacaval Lymphadenopathy: Should it be a Cause for Concern in the Absence of Visible Hepatobiliary, Pancreatic and Gastric Pathology?

Iyer, V.; Borczuk, D.; Hahn, P.; Mueller, P.; Harisinghani, M. Massachusetts General Hospital, Boston, MA

E280. Cisterna Chyli in Patients with Malignancy—Influence of Cardiovascular Disease on the Prevalence and Size of the Cisterna

Feuerlein, S.; Stolz, J.; Muhe, R.; Brambs, H.; Pauls, S. University of Ulm, Ulm, Germany

E281* Intraabdominal Fibromatosis: Imaging Spectrum with Pathologic Correlation

Ritchie, B.^{1,2}; Lewis, R.^{1,2}; Lattin, G.¹ 1. Armed Forces Institute of Pathology, Bethesda, MD; 2. National Naval Medical Center, Bethesda, MD

E282. The Rocky Mesentery: Imaging Spectrum of Calcified Mesenteric Disorders

Shanhogue, A.¹; Ojili, V.¹; Shanhogue, D.¹; Nagar, A.²; Fasih, N.³; Prasad, S.¹ 1. University of Texas Health Science Center at San Antonio, San Antonio, TX; 2. Ohio State University Medical Center, Columbus, OH; 3. The Ottawa Hospital, Ottawa, Canada

E283. CT Manifestations of Abdominal Tuberculosis

Lee, W.¹; Duddalwar, V.²; Stella, D.³; Dagia, C.⁴; Hennessy, O.¹; Chang, S.⁵ 1. St. Vincent's Hospital, Caulfield North VIC, Australia; 2. USC/Norris Comprehensive Cancer Center, Los Angeles, CA; 3. Royal Melbourne Hospital, Parkville, Australia; 4. Royal Children's Hospital, Parkville, Australia; 5. Vancouver General Hospital, Vancouver, Canada

E284. Extranodal Abdominopelvic Lymphoma: A Grand Tour of Lymphoma of the Solid Organs

Panko, J.¹; Aganovich, L.²; Hughes, Cassidy F.²; Chan, M.¹ 1. University of California-San Diego, San Diego, CA; 2. VA San Diego Medical Center, San Diego, CA

E285. Spontaneous Hemorrhage Complicating Tumors in the Abdomen: CT Spectrum

Lamba, R.¹; Sandhu, P.¹; Lall, C.² 1. University of California, Davis, Sacramento, CA; 2. Indiana University, Indianapolis, IN

E286. Extra-Adrenal Myelolipoma: A Series of 28 Cases from the AFIP

Reaven, R.¹; Manning, M.¹; Craig, W.²; Woodward, P.³ 1. University of Maryland, Baltimore, MD; 2. AFIP, Washington, DC; 3. University of Utah, Salt Lake City, UT

E287* Hepatobiliary and Pancreatic MRI: Specific Questions a Hepatobiliary Surgeon Will Ask a Radiologist

Sebastian, S.¹; Muchantef, K.²; Cornfeld, D.²; Salem, R.²; Krishnamoorthy, S.² 1. University of Mississippi Medical Center, Jackson, MS; 2. Yale University, New Haven, CT

E288* Carcinoma of Unknown Primary (CUP): A Need for a Practical Diagnostic Algorithm

Chintapalli, K.; Lalwani, N.; Prasad, S. UTHSCSA, San Antonio, TX

E289. Comprehensive Analysis of Interpretive Errors in Abdominal Imaging and the Lessons that Can be Learned

Brinkman, M.; Pozniak, M.; Hinshaw, L. University of Wisconsin School of Medicine and Public Health, Madison, WI

E290. Solid Pancreatic Neoplasms and Pseudotumors: Cross-Sectional Imaging Spectrum of the 'Unusual Suspects'

Ojili, V.¹; Parizi, M.¹; Nagar, A.²; Prasad, S.¹; Chintapalli, K.¹ 1. University of Texas Health Science Center at San Antonio, San Antonio, TX; 2. Ohio State University Medical Center, Columbus, OH

E291. Imaging of Acute and Chronic Pancreatitis and its Complications

Goud, N.; Goud, A.; Malguria, N.; Jati, A. Boston VA Medical Center, Boston, MA

E292. Imaging Features of Pancreatic Neuroendocrine Tumors (PNETs) and Their Metastases on Portal Venous Phase CT—Our Experience

Katkar, A.¹; Souza, F.²; Fennessy, F.²; Donald, D.² 1. UIHC, Iowa City, IA; 2. DFCI, Boston, MA

E293. Pancreatic Neoplasms: It's All in the "Family"

Capps, E.; Sharma, P.; Wong, W.; Ford, K. Baylor University Medical Center, Dallas, TX

E294. Pancreatic Surgery for the Radiologist 2009: An Illustrated Review of Classic and Newer Surgical Techniques for Pancreatic Tumor Resection

Corl, F.; Johnson, P.; Fishman, E. Johns Hopkins Hospital, Baltimore, MD

E295* Atypical Variants of Serous Cystadenomas—A Comprehensive Review of MRI Features

Patel, B.; Kalb, B.; Sarmiento, J.; Adsay, N.; Martin, D. Emory University School of Medicine, Atlanta, GA

E296* MRI of Cystic Pancreatic Lesions: Radiologic Pathologic Correlation with Management

Muchantef, K.¹; Sebastian, S.²; Cornfeld, D.¹; Jain, D.¹; Krishnamoorthy, S.¹ 1. Yale University, New Haven, CT; 2. University of Mississippi Medical Center, Jackson, MS

ELECTRONIC EXHIBITS: GI, Liver, Biliary & Pancreas



E297* MRI of the Pancreas: An Electronic Atlas of Pancreatic Masses with Surgical Path Correlation

Garon, B.; Ihde, I.; Patel, H.; Chan, R.; Fleming, M.; Martin, S.; Palmer, S. University of Southern California, Los Angeles, CA

E298. Role of MRI in Evaluating Pancreatitis with Emphasis on MRCP

Katre, R.; Sunnapwar, A.; Choudhary, S.; Shanbhogue, A.; Prasad, S.; Chintapalli, K. UTHSCSA, San Antonio, TX

E299. Secretin Enhanced MRCP: Technique, Quantification And Role In Diagnosing Pancreatic Pathologies

Sanyal, R.; Herts, B.; Veniero, J. Cleveland Clinic, Cleveland, OH

E300* Imaging in Pancreatic Surgery: An Electronic Atlas of Postsurgical Anatomy and Common Complications

Salibian, R.; Patel, H.; Duddalwar, V.; Garon, B.; Palmer, S. Keck School of Medicine-University of Southern California, Los Angeles, CA

E301. MRI Pattern in Autoimmune Pancreatitis Including Manganese Enhancement

Feuerlein, S.; Juchems, M.; Brambs, H.; Ernst, A. University of Ulm, Ulm, Germany

E302. Effect of Intramuscular Butylscopolamine Administration in the Reduction of Peristaltic Artifacts in Secretin-Enhanced MR Cholangiopancreatography

Restaino, G.; Rosa, M.; Missere, M.; Occhionero, M.; Barrassi, M.; Costanzo, S.; Sallustio, G. Catholic University of Sacred Heart, Campobasso, Italy

E303* Non-Carcinomatous Neoplasms of the Pancreas: A Pictorial Review

Bayanati, H.; Vakili, M.; Papadatos, D. University of Ottawa, Ottawa, Canada

E304* Various Complications of Acute Pancreatitis: Understanding the MDCT Findings and Their Pathophysiology

Kim, K.; Cho, S.; Jeon, Y.; Lee, K. Inha University Hospital, Incheon, Korea

E305. What is the Destiny of Acute Pancreatitis?: Evaluation of Prognostic Factors Determined by Initial CT Features

Kim, J.; Cho, S.; Jeon, Y.; Lee, K. Inha University Hospital, Incheon, Korea

E306. Complications of Pancreatic Transplantation: Review of Anatomy and Selected Imaging Features

Mehandru, S.; Nakamoto, D.; Azar, N. University Hospitals Case Medical Center, Cleveland Heights, OH

E307. A Pictorial Review of Abdominopelvic Fatty Lesions

Dease, K.; Ferretti, J.; Zhou, D. Nassau University Medical Center, Wantagh, NY

E308. Encapsulating Peritoneal Sclerosis—Imaging Findings Behind an Underrecognized Complication of Long-term Peritoneal Dialysis

Cameron, S.; Gayomali, C.; Hansson, J.; Finkelstein, F.; Protopoulos, Z. Hospital of St. Raphael, New Haven, CT

E309. Retained Surgical Sponge (Gossypiboma): Spectrum of Imaging Findings in the Acute and Chronic Phase

Hammer, M.; Al-Hawary, M.; Kaza, R.; Dillman, J.; Platt, J. University of Michigan, Ann Arbor, MI

E310. Evaluation of Perianal Fistulas with MRI

Szilagyí, S.; Mastropasqua, A.; Kagen, A. Beth Israel Medical Center, New York, NY

E311. Double Contrast MRI in Pre-Operative Evaluation of Rectal Cancer: Use of Aqueous Jelly as Rectal Contrast Agent

Fasih, N.1; Shanbhogue, K.2; Walsh, C.1; Fraser-Hill, M.1 1. The Ottawa Hospital, Ottawa, Canada; 2. UTHSCSA, San Antonio, TX

E312* 3 Tesla MR Locoregional Staging of Rectal Cancer: A Surgical and Radiation Oncology Perspective

Knechtges, P.; Budovec, J.; Kosinski, L.; Kelly, T.; Anderson, J.; Ludwig, K. Medical College of Wisconsin, Milwaukee, WI

E313. MRI of the Rectum Using 3D Fast Spin-Echo Extended Echo-Train Acquisition (XETA): Preliminary Result

Park, H.; Kim, Y.; Hwang, D.; Jung, E.; Jung, S.; Jeon, H. Konkuk University School of Medicine, Seoul, Korea

E314* Primary Tumors of Retroperitoneum

Jati, A.; Malguria, N.; Diaz, L.; Arndt, W. VA Boston Healthcare Systems, Chestnut Hill, MA

E315. Rats Do Not Develop Nephrogenic Systemic Fibrosis After Intraperitoneal Administration of Gadolinium Bound Contrast Agents

Langer, R.1; Lorke, D.1; Neidl, van Gorkom K.1; Petroianu, G.1; Azimullah, S.1; Nurulain, S.1; Speck, U.2 1. FMHS UAEU, Al Ain, UAE; 2. Charite, Berlin, Germany

E316* The Forgotten Organ; Spectrum of Focal Lesions in the Spleen: Value of Cross-Sectional Imaging in Diagnosis with Emphasis on MRI

Fasih, N.; Walsh, C.; Kielar, A.; Ryan, J.; McInnes, M.; Macdonald, B. The Ottawa Hospital, Ottawa, Canada

** offers CME credit*



ELECTRONIC EXHIBITS: GU/OB/GYN



E317* Imaging of Adrenal Masses: A Pictorial Review

Dighe, M.¹; Bhargava, P.²; Oliveira, G.¹; Bush, W.¹; Vaidya, S.² 1. University of Washington, Seattle, WA; 2. University of Washington & VA Puget Sound Health Care System, Seattle, WA

E318* MRI and the Pregnant Patient: A Complete Guide to Evaluating the Pregnant Patient Presenting with Clinically Suspected Appendicitis

Earhart, C.; Hawari, A.; Barra, Q.; Whang, G.; Romero, M.; Palmer, S. Keck School of Medicine, University of Southern California, San Gabriel, CA

E319. MRI of Pelvic Endometriosis: Effect of Reader's Experience on Accuracy and Interobserver Variability

Missere, M.; Restaino, G.; Maselli, G.; Carone, V.; Ferrandina, G.; Sallustio, G. Catholic University of Sacred Heart, Campobasso, Italy

E320. Assessment of Tumoral Angiogenesis in Endometrial Carcinoma With Dynamic-Contrast-Enhanced MRI: A Prospective Study

Restaino, G.; Barrassi, M.; Missere, M.; Carbone, A.; Ferrandina, G.; Sallustio, G. Catholic University of Sacred Heart, Campobasso, Italy

E321. Developing a Normogram of the Cerebellar Vermis Utilizing 3D Ultrasound and Image Postprocessing

Guttmann, A.; Dighe, M.; Mitsumori, L.; Hardikar, S. University of Washington, Seattle, WA

E322* Nephron Sparing Surgery: Complications and Peri-Operative Pitfalls on CT and MR

Arnold, R.; Myers, D. Henry Ford Hospital, Detroit, MI

E323. Mixed Epithelial and Stromal Tumor of the Kidney (MEST): A Complex Diagnosis Made Simpler Using Radiologic-Pathologic Correlation with Special Focus on Multidetector CT with 3D Mapping

Chu, L.; Hruban, R.; Horton, K.; Fishman, E. Johns Hopkins University, Baltimore, MD

E324* Fat Containing Renal Cell Carcinoma: Spectrum of Imaging Findings and Differentiation from Fat-Containing Benign Renal Lesions

Wasnik, A.; Kaza, R.; Cohan, R.; Al-Hawary, M.; Francis, I. University of Michigan, Ann Arbor, MI

E325. Papillary Renal Cell Carcinoma: Unique Imaging Features Confirmed on 15 Pathology Proven CT Cases

Panchal, V.¹; Panko, J.¹; Aganovic, L.²; Hughes Cassidy, F.² 1. University of California-San Diego, San Diego, CA; 2. VA San Diego Medical Center, San Diego, CA

E326. WITHDRAWN

E327. Serum Creatinine Monitoring After Administering Intravenous Contrast in Diabetics on Metformin with Normal Kidney Function

Ishak, C.; Kanth, N.; Dease, K.; DeCosta, S.; Nourollahzadeh, E.; Rai, S.; Ajaimy, M.; Scarmato, V. Nassau University Medical Center, East Meadow, NY

E328. MRI of Cystic Renal Lesions in the Adult: Radiologic Pathologic Correlation

Muchantef, K.¹; Sebastian, S.²; Cornfeld, D.¹; Krishnamoorthy, S.¹ 1. Yale University, New Haven, CT; 2. University of Mississippi Medical Center, Jackson, MS

E329. Diffusion Weighted MRI in the Assessment of Tumor Response to Novel Targeted Therapies in Metastatic Renal Cell Carcinoma

Bharwani, N.; Miquel, M.; Sahdev, A.; Powles, T.; Reznak, R.; Rockall, A. Barts & The London NHS Trust, London, United Kingdom

E330* Clear Cell Renal Cell Carcinoma: Multidetector CT and MRI Appearances

Patnana, M.; Vikram, R.; Ng, C.; Sandler, C. University of Texas MD Anderson Cancer Center, Houston, TX

E331. The Fate of Small Renal Masses, Less Than 1 cm

Lang, E.^{1,2}; Hanano, A.¹; Emery, K.¹; Thomas, R.³; Myers, L.³; Rudman, E.¹; Jaworsky, J.¹; Macchia, R.¹ 1. SUNY Downstate Medical Center, Brooklyn, NY; 2. Johns Hopkins Bayview Medical Center, Baltimore, MD; 3. Tulane Health Science Center, New Orleans, LA

E332. Subtype Differentiation of Small Renal Cell Carcinomas on Biphasic MDCT: Measurement of Degree and Heterogeneity of Enhancement

Cho, J.; Kim, S. Seoul National University Hospital, Seoul, Korea

E333. Imaging Findings of Renal Toxicity in Patients with Chronic Lithium Use

Karaosmanoglu, A.; Arellano, R.; Mueller, P. Massachusetts General Hospital, Boston, MA

E334. Preoperative CT Factors That May Correlate with the Degree of Renal Impairment After Partial Nephrectomy

Jeun, B.; Shih, G.; Shehorn, D.; Ng, C.; Wang, G.; Scherr, D.; Auh, Y. Weill Cornell Medical Center, New York, NY

E335* Use of Multimodality 3D Imaging to Demonstrate Complex Nodal Drainage Pathways in Common Pelvic Malignancies

Oliveira, G.¹; Dubinsky, T.¹; Dighe, M.¹; Warren, W.¹; Mitsumori, L.¹; Harisinghani, M.² 1. University of Washington, Seattle, WA; 2. Massachusetts General Hospital, Boston, MA

E336* An Atlas of Nodal Pathways of Metastatic Gynecological Cancers

Islam, T.^{1,2}; Hahn, P.²; Lee, S.²; Harisinghani, M.^{1,2} 1. Center for Molecular Imaging Research, Boston, MA; 2. Massachusetts General Hospital, Harvard Medical School, Boston, MA

E337* Placenta Accreta: How to Study it by Using MR

Saba, L.; Guerriero, S.; Sulcis, R.; Ajossa, S.; Melis, G.; Mallarini, G. Azienda Ospedaliero Universitaria, Cagliari Sardegna, Italy

E338* MR Imaging of Ectopic Pregnancy: Imaging Features and Incremental Value to Ultrasound

Koroglu, M.¹; Kayhan, A.²; Orin, S.²; Ernst, R.³; Yacoub, J.²; Oto, A.² 1. Suleyman Demirel University, Isparta, Turkey; 2. University of Chicago, Chicago, IL; 3. MD Anderson, Houston, TX

ELECTRONIC EXHIBITS: GU/OB/GYN



E339. Diagnostic Pitfall: Enhancement of Organizing Hematoma on MRI

Blumenthal, B.; Hines, J.; Friedman, B. Long Island Jewish Medical Center, New Hyde Park, NY

E340* Fetal Cardiac Anomalies—Recent Advances in Ultrasonographic Evaluation: A Pictorial Review with Pathological Correlation

Rajiah, P.¹; Mak, C.²; Dubinsky, T.²; Dighe, M.² 1. Cleveland Clinic Foundation, Cleveland, OHs; 2. University of Washington, Seattle, WA

E341. Ovarian Vein Thrombosis: CT Identification, Associated Findings, and Clinical Evaluation and Management

Luongo, J.¹; Saxon, P.¹; Yam, B.¹; Covarrubias, D.²; Merunka, V.³; Ortiz, A.¹; Katz, D.¹ 1. Winthrop-University Hospital, Mineola, NY; 2. Long Island College Hospital, Brooklyn, NY; 3. Beth Israel Medical Center, New York, NY

E342* Metastatic Ovarian Neoplasms: A Case-Based Review of Imaging Findings

Bayanati, H.; Grover, R.; Chaudhary, H.; Shabana, W. University of Ottawa, Ottawa, Canada

E343* Adnexal Torsion: Diagnostic Imaging Features on CT and MRI with Pathologic Correlation

Duigenan, S.; Lee, S. Oliva, E. Massachusetts General Hospital, Boston, MA

E344* Imaging Features of Ovarian Cystic Lesions with Emphasis on Differential Diagnosis

Park, S.; Lee, Y.; Song, M.; Moon, M.; Cho, H.; Lee, M. Cheil General Hospital and Women's Healthcare Center, Kwandong University College of Medicine, Seoul, Korea

E345* MR Imaging Findings to Make it Difficult to Discriminate Between Benign and Malignant Adnexal Masses

Rha, S.; Shin, Y.; Oh, S.; Jung, S.; Kim, Y.; Byun, J. Seoul St. Marys' Hospital, The Catholic University of Korea, Seoul, Korea

E346. Ovarian Metastasis in Endometrial Carcinoma: Incidence and Imaging Findings with CT and MR in a Referral Center for Gynaecological Oncology

Restaino, G.; Missere, M.; Occhionero, M.; Guerriero, M.; Ferrandina, G.; Sallustio, G. Catholic University of Sacred Heart, Campobasso, Italy

E347* Hemorrhagic Ovarian Cysts, Endometriomas, and Cystic Teratomas: Keys to Diagnosis and Management of These Common "Complex" Ovarian Cysts

Shah-Patel, L.; Patel, M. Mayo Clinic, Phoenix, AZ

E348. Deep Infiltrating Endometriosis: CT Imaging Evaluation

Jung, S.; Kim, Y.; Park, H.; Jeon, H. Konkuk University Medical Center, Konkuk University School of Medicine, Seoul, Korea

E349* Differential Diagnosis of Complicated or Complex Gynecologic Diseases and Gynecologic Disease Mimicking Nongynecologic Diseases in Reproductive-Aged Female Patients with Pelvic or Lower Abdominal Pain

Namkung, S.; Nam, K.; Lee, J.; Jung, H.; Hwang, I.; Hong, M.; Kim, H.; Choi, Y. Hallym University Hospital, Chuncheon, Gangwon-do, Korea

* offers CME credit

E350* Pearls and Pitfalls in MR Imaging of the Female Pelvis

Lai, L.; Malhotra, R.; Brown, M. University of California, San Diego, La Jolla, CA

E351* Cystic Lesions in Female Pelvis: Approach on MR Imaging

Gill, G.; Sidhu, R.; Bhatt, S.; Dogra, V. University of Rochester, Rochester, NY

E352* MR Imaging of Pelvic Floor Dysfunction: A Practical Diagnostic Approach

Ram, R.; Jambhekar, K.; Donepudi, S.; Shaikh, R.; Pandey, T. University of Arkansas for Medical Sciences, Little Rock, AR

E353. In the Zone: MRI of the Uterus and Cervix Using Zonal Anatomy to Identify Pathology

Jurasic, M.; Bridges, M. Mayo Clinic Jacksonville, Jacksonville, FL

E354* The MRI Appearances of Pelvic Endometriosis: A Pictorial Review with Laparoscopic Correlation

Yang, N.¹; Esler, S.² 1. St. Michael's Hospital, Toronto, Canada; 2. Austin Health, Melbourne, Australia

E355* How Can Things Go So Wrong? MR Imaging of Penile Prostheses, Their Complications, and Their Malfunctions

Jurasic, M.; Bridges, M. Mayo Clinic Jacksonville, Jacksonville, FL

E356. Female Infertility Assessment: The Role of MR-HSG Compared to Traditional HSG

Iorio, N.; Macioce, A.; Matarazzo, I.; Vitale, V.; David, V. AO Sant'Andrea-Sapienza Università di Roma, Rome, Italy

E357* Permanent Contraceptive Devices in the Female Pelvis on Multimodality Imaging: Confirming Correct Location and Diagnosing the Complications

Ebuoma, L.; Lee, S.; Oliva, E. Massachusetts General Hospital, Boston, MA

E358* Which Pre- and Post-Surgical MR Finding the Surgeons Want to Know When Evaluating Patients with Pelvic Floor Dysfunction?

Oliveira, G.; Cuevas, C.; Bhargava, P.; Fialkow, M.; Dubinsky, T.; Dighe, M. University of Washington, Seattle, WA

E359* The Nuts and Bolts of Nodal Staging in Primary Prostate Cancer

Islam, T.^{1,2}; Hahn, P.²; Tabatabaei, S.²; Harisinghani, M.^{1,2} 1. Center for Molecular Imaging Research, Boston, MA; 2. Massachusetts General Hospital, Harvard Medical School, Boston, MA

E360* MRI of the Prostate: Techniques, Applications and Limitations

Mallikarjunappa, M.; Lee, J.; Kolokythas, O.; Dighe, M.; Warren, B.; Dubinsky, T. University of Washington, Seattle, WA

E361* MRI of Treated Prostate Cancer

Vargas, H.; Wassberg, C.; Akin, O.; Hricak, H. Memorial Sloan-Kettering Cancer Center, New York, NY

E362* Expected and Unexpected Findings After Prostatectomy: 3T MRI with Surface and Endorectal Coil

Taneja, R.; Lee, J.; Kolokythas, O.; Dighe, M.; Dubinsky, T. University of Washington, Seattle, WA

E363.* A Practical Approach in Detection of Local Recurrence of Prostate Cancer in the Prostatectomy Bed: Use of Slope Images
Boonsirikamchai, P.; Jackson, E.; Kuban, D.; Kaur, H.; Hou, P.; Choi, H. The University of Texas M. D. Anderson Cancer Center, Houston, TX

E364. Comparison of a 32 Channel Coil and a 6 Channel Coil for MRI of the Prostate at 3T
Sammot, S.; Wei, W.; Reiss, B.; Liang, J.; Jia, G.; Aguila, F.; Choi, S.; Knopp, M. The Ohio State University, Columbus, OH

E365.* Testicular Involvement in Lymphoma and Leukemia: Clinical and Radiological Review
Nasseri, F.¹; Eftekhari, F.² 1. Baylor College of Medicine, Houston, TX; 2. University of Texas M. D. Anderson Cancer Center, Houston, TX

E366. A to Z of Extragonadal Germ Cell Tumors
Shinagare, A.; Jagannathan, J.; Ramaiya, N.; Shore, K.; Hall, M.; Van den Abbeele, A. Dana Farber Cancer Institute, Boston, MA

E367. Segmental Testicular Infarction
Saxon, P.¹; Katz, D.¹; Luongo, J.¹; Badler, R.¹; Ramas, C.¹; Tublin, M.²; Desser, T.¹ 1. Winthrop University Hospital, Woodbury, NY; 2. University of Pittsburgh School of Medicine, Pittsburgh, PA

E368.* Imaging Features of Benign Solid Testicular Lesions
Park, S.^{1,2}; Lee, W.²; Lee, J.² 1. Cheil General Hospital and Women's Healthcare Center, Kwandong University College of Medicine, Seoul, Korea; 2. Ulsan University Hospital, University of Ulsan, Ulsan, Korea

E369. Transitional Cell Carcinoma of the Upper Urinary Tract and its Mimics: CT Urogram with Multiplanar Reconstruction
Jati, A.; Manuel, D.; Arndt, W. VA Boston Healthcare System, Chestnut Hill, MA

E370.* Radiological Imaging of Urinary Diversions
Sidhu, R.; Bhatt, S.; Marshall, J.; Cardin, A.; Dogra, V. University of Rochester, Rochester, NY

E371. Imaging Features of the Fat-Containing Lesions in Genitourinary System
Park, S.^{1,2}; Moon, M.¹; Kim, J.²; Cho, K.² 1. Cheil General Hospital and Women's Healthcare Center, Kwandong University College of Medicine, Seoul, Korea; 2. Asan Medical Center, University of Ulsan, Seoul, Korea

E372.* CT Urography of Benign and Malignant Conditions of The Upper Urinary Tract System, A Radiologic-Pathologic Correlation
Fish, E.; Sokhandon, F.; Jafri, S. William Beaumont Hospital, Bloomfield Hills, MI

E373.* GU Findings in AIDS: The Changing Face of a Forgotten Pandemic
Amendola, M.¹; Madrazo, B.²; Alfaro, K.²; Casillas, J.²; Ramchandani, P.³; Jafri, S.⁴ 1. No Institutional Affiliation; 2. University of Miami Miller School of Medicine, Miami, FL; 3. University of Pennsylvania Medical Center, Philadelphia, PA; 4. William Beaumont Hospital, Bloomfield Hills, MI

E374.* Acquired Ureteral Obstruction—Causes, Management Principles, and Imaging Pre-and Post-Intervention
Sommerville, B.; Heldmann, M.; Walker, P.; Black, G.; Sangster, G.; Elmajian, D. Louisiana State University Health Sciences Center, Shreveport, LA

E375. Penile Pathology: Can Cross-Sectional Imaging Play a Role?
Henderson, B.; Heldmann, M.; Sangster, G.; Elmajian, D.; Dudley, B.; Moore, S.; Ryder, S. LSUHSC-Shreveport, Shreveport, LA

E376.* Uterine Fibroid Embolization: A Comprehensive Review of the Radiological Diagnosis, Anatomy and Treatment of Leiomyoma
Poon, K.; Lee, E.; Loh, C.; Kee, S.; Hoffman, C. UCLA Medical Center, Los Angeles, CA

E377.* MR Imaging of Cervical Carcinoma
Law, Y.; Cheah, F. Singapore General Hospital, Singapore, Singapore

E378.* Uterine Myometrial Masses
Ahuja, F.; MacDonald, D. The Ottawa Hospital, Ottawa, Canada

E379.* Imaging of Various Vaginal and Vulva Lesions: Focused on MR Imaging
Rha, S.; Oh, S.; Shin, Y.; Jung, S.; Kim, Y.; Byun, J. Seoul St. Mary's Hospital, The Catholic University of Korea, Seoul, Korea

E380.* MRI Imaging of Mullerian Duct Anomalies and Correlative Findings in Other Imaging Modalities Such as Ultrasound and Hysterosalpingograms
Patel, P.; Bhatt, S.; Dogra, V.; Sidhu, R.; Reddy, S. University of Rochester Medical Center, Rochester, NY

E381. The Role of MRI in Assessing the Risk of Obstetrical and Gynecological Complications of Mullerian Duct Abnormalities
Patel, P.; Bhatt, S.; Dogra, V.; Sidhu, R.; Reddy, S. University of Rochester Medical Center, Rochester, NY

E382.* State of Art Imaging Approach to Gestational Trophoblastic Disease with Special Emphasis on the Role of MRI
Khalatbari, K.; Lee, J.; Kolokythas, O.; Dighe, M.; Dubinsky, T. University of Washington, Seattle, WA

E383.* Imaging Features of Atypical Fibroids
Narayanan, P.¹; Munneke, G.² 1. Chelsea and Westminster Hospital, London, United Kingdom; 2. St. George's Hospital, London, United Kingdom

E384. The Diffusion Weighted Properties of Uterine Fibroids
Jenkins, S.; Yang, N.; Colak, E.; Prabhudesai, V.; Kirpalani, A. St. Michael's Hospital, Toronto, Canada

E385. Benign Uterine Smooth Muscle Tumors with Unusual Growth Patterns: Benign Metastasizing, Intravenous, Disseminated Intraperitoneal, Retroperitoneal, and Cotyledonoid Leiomyomas
Demos, T.¹; Posniak, H.¹; Pierce, K.¹; Potkul, R.¹; Joseph, N.² 1. Loyola University Medical Center, Maywood, IL; 2. University of Chicago Hospitals, Chicago, IL

ELECTRONIC EXHIBITS: GU/OB/GYN

E386. Hysterosalpingography: Tips for Both Performance and Interpretation

Kim, A.; Bennett, G.; Albert, R.; Giovanniello, G. NYU Langone Medical Center, Oakland Gardens, NY

E387. Multimodality Imaging Findings of IUDs and the Essure Permanent Birth Control (PBC) Device

Parghi, C.; Khati, N. The George Washington University, Washington, DC

E388. Diagnosis of Uterine Scar Dehiscence and Its Clinical Relevance

Palacios-Jaraquemada, J.¹; Bruno, C.¹; Fiorillo, A.²; Hamer, J.³; Carrascosa, P.⁴ 1. Fundación Científica del Sur, Buenos Aires, Argentina; 2. CEMIC, Buenos Aires, Argentina; 3. Cegyr, Buenos Aires, Argentina; 4. Diagnóstico Maipú, Vicente López, Argentina

E389. Elevated Alpha Feto Protein (AFP) Level in Pregnancy—Etiology and Imaging Appearances

Dighe, M.¹; Bhargava, P.²; Fligner, C.¹; Mitsumori, L.¹ 1. University of Washington, Seattle, WA; 2. University of Washington & VA Puget Sound Health Care System, Seattle, WA

E390. Placental Abruption

Woytak, A. SUNY Upstate Medical University, University Hospital, East Syracuse, NY

E391. Spectrum of Subtle Sonographic Features of Uterine Adenomyosis

Pandya, A.; Caoili, E.; Wasnik, A.; Weadock, W. University of Michigan, Ann Arbor, MI

E392* Imaging the Endometrium: Pearls and Pitfalls

Sunnappwar, A.; Katre, R.; Choudhary, S. UTHSCSA, San Antonio, TX

** offers CME credit*



ELECTRONIC EXHIBITS: Musculoskeletal



E393. "Not Just Any Tom, Dick or Harry": Anomalous Muscles of the Ankle, How to Recognize Them on MR Imaging and Their Clinical Relevance

Clemenshaw, M.; Bui-Mansfield, L.; O'Brien, S. Brooke Army Medical Center, San Antonio, TX

E394.* Clinical Correlation and MRI of the Ankle

Mazzie, J.1; Chang, W.2; Smith, S.3; Scalcone, L.1; Youn, T.1; Klein, M.1; Luchs, J.1; Katz, D.1 1. Winthrop University Hospital, Mineola, NY; 2. No Institutional Affiliation; 3. Brigham and Women, Boston, MA

E395. Cry "Ankle": A Review of Ankle Fractures with Plain Film and MDCT Correlations

Garcia, L.; Alvarado, E.; Quinonez, G.; Rivera, R.; Badillo, K.; Vidal, J.; Gomez, A. University of Puerto Rico, Medical Sciences Campus, San Juan, PR

E396.* Ankle Fracture Classification: A Case-Based Review Focused On Lauge-Hansen Classification and Ankle Stability

Tice, J.1; Walker, E.1,2; Bernard, S.1 1. Penn State Hershey Medical Center, Hummelstown, PA; 2. Uniformed Services University of the Health Sciences, Bethesda, MD

E397. Well-Turned Ankles: Radiology of Ankle Arthroplasty

Khorashadi, L.; Ha, A.; Chew, F. University of Washington, Seattle, WA

E398. The Sacroiliac Joint—A Window to Arthropathy: A Multimodality Imaging Review of Sacroiliac Joint Disease with Emphasis on Differential Diagnosis

Baril, R.1; Lichtenberger, J.1; Southam, S.1; Jesinger, R.1; Tall, M.2 1. David Grant Medical Center, Travis AFB, CA; 2. Wilford Hall Medical Center, Lackland AFB, TX

E399.* Thumbs Up: The Radiologic Guide to the Universe of 1st CMC Joint Arthroplasty

Khorashadi, L.; Ha, A.; Chew, F. University of Washington, Seattle, WA

E400.* Bone Death—Yesterday's Specters Today!

Gharbaoui, L.; Chandrasekhar, A. The University of Texas Medical School at Houston, Houston, TX

E401. Spine MR Imaging of Spine Marrow: Age Related Changes and Pathology

Hanrahan, C.; Ellchuk, T.; Shah, L. University of Utah, Salt Lake City, UT

E402.* The Spectrum of Irradiated Bone Marrow on MRI

Bean, G.; Singh, R.; Kumar, R.; Madewell, J. MD Anderson Cancer Center, Houston, TX

E403. Bone Marrow Alteration in Patients with Type 1 Gaucher Disease on Enzyme Replacement Therapy

Lerner, D.; Simpson, W.; Hermann, G.; Balwani, M. Mount Sinai Medical Center, New York, NY

E404. Recognition, Assessment and Treatment of Non-Union Following Surgical Fixation of Fractures: Emphasis on 3D CT

Calisir, C.; Fishman, E.; Carrino, J.; Fayad, L. Johns Hopkins, Baltimore, MD

E405. CT Appearances of Bone Lesions in POEMS Syndrome

Frohnert, P.; Glazebrook, K.; Dispenzieri, A. Mayo Clinic, Rochester, MN

E406. Tumors and Tumor-Like Conditions at the Surface of Bones

Diaz, L.1; Goud, A.1; Roermer, F.2; Arndt, W.1; Guermazi, A.2 1. Boston VA Health Care System, Jamaica Plain, MA; 2. Boston University Medical Center, Boston, MA

E407.* The Incidental Calcified or Ossified Body: Where is it and What Does it Mean?

Pai, R.; Doshi, S.; Yadavalli, S.; Koshy, P. William Beaumont Hospital, Birmingham, MI

E408. A Pictorial Review of Lesions of the Clavicle

Spanos, G.; White, E.; Matcuk, G.; Patel, D.; Masih, S.; Learch, T.; Hawari, A.; Forrester, D. USC, Los Angeles, CA

E409. Arthrography: A Video Tutorial for the Visual Learner

Perrich, K.; Sharma, V.; Richardson, M. University of Washington, Seattle, WA

E410. Nerve Sheath Tumors: Classic Imaging Findings, Differentiating Features, and Potential Pitfalls

Earhart, C.; Patel, D.; Ihde, L.; Matcuk, G.; White, E. LAC+USC, Los Angeles, CA

E411. MRI of Cartilaginous Bone Tumors

Cerniglia, C.; Weiss, S. University of Massachusetts Amherst Memorial Medical Center, Worcester, MA

E412. Not Everything That's Hot on a Bone Scan is Malignant: A Pictorial Review of Benign Causes of Increased Isotope Uptake

Moran, D.; O'Neill, A.; Heffernan, E.; Skehan, S. St. Vincent's University Hospital, Dublin 4, Ireland

E413. Soft Tissue Calcification: Recognizing Friend from Foe

Lim, R.1; Schneider, R.2; Hwang, S.1; Hameed, M.1 1. Memorial Sloan-Kettering Cancer Center, New York, NY; 2. Hospital for Special Surgery, New York, NY

E414.* Lesions of Cartilage Origin Arising from Surface of Bone—Differential Diagnosis and Pathologic Correlation

Moorthy, M.; Mooney, S.; Dieudonne, G.; Seo, G.; Monu, J. University of Rochester, Rochester, NY

E415.* New and Improved: Orthopedic Hardware for the 21st Century

Petscavage, J.; Khorashadi, L.; Perrich, K.; Ha, A. Chew, F. University of Washington, Seattle, WA

E416.* Malignant Tumors of the Chest Wall: A Pictorial Review of Radiological Findings

O'Regan, K.1; Souza, F.2; Jagannathan, J.2; Ramaiya, N.2; Van den Abbeele, A.2 1. Dana Farber Cancer Institute, Boston, MA; 2. Dana Farber Cancer Institute, Boston, MA

E417. Beyond Lateral Epicondylitis: Recognizing Common Mimickers, Expanding the Differential Diagnosis, and Avoiding Pitfalls in the Evaluation of Lateral Elbow Pain

Kotnis, N.; Chiavaras, M.; Harish, S. St. Joseph's Healthcare McMaster University, Hamilton, Canada

E418. MR Arthrography of the Elbow: Current Concepts in Technique and Interpretation

Casey, D.; Johnston, S.; Serou, M.; Neitzschman, H. Tulane University Health Sciences Center, New Orleans, LA

E419. MR Imaging in the Shoulder and Elbow of Professional Baseball Players

Chun, T.; Lee, K. Eulji University, Daejeon, Korea

E420. Unhinged: The Radiology of Elbow Arthroplasty

Petsavage, J.; Ha, A.; Chew, F. University of Washington, Seattle, WA

E421. Patterns of Elbow Injury in Childhood

Walker, B.; Cesarz, M.; Monu, J.; Singh, D.; Seo, G. University of Rochester, Rochester, NY

E422. Ultrasound and MR of the Elbow—Common Pathology

Craig, J.; van Holsbeeck, M.; Bouffard, J. Henry Ford Hospital, Ann Arbor, MI

E423. Imaging Features of Common and Uncommon Pediatric Skeletal Dysplasias

Jiang, J.; Boiteau, G. Allegheny General Hospital, Pittsburgh, PA

E424. Lisfranc Joint Injury: What Does Volumetric CT Add To Detection, Characterization and Treatment Planning?

Kalia, V. Johns Hopkins, Baltimore, MD

E425. Demystifying Mid-Foot Fractures: Interactive 3D CT Review

Sharma, V.; Ha, A.; Richardson, M.; Chew, F. University of Washington, Seattle, WA

E426* Tarsal Coalition Demystified: Novel MRI Findings and Newly Recognized Associations with Tarsal Coalition Complex

Hwang, J.; Platnick, J.; Lester, N.; Lempert, L.; Jbara, M. Staten Island University Hospital, Brooklyn, NY

E427. Cuboid Fractures: A Review of Clinical Presentations, Multimodality Diagnosis, and Treatment Outcomes

Buse, G.¹; Jesinger, R.^{1,2}; Southam, S.¹; Braza, R.¹; Puckett, A.¹ 1. David Grant USAF Medical Center, Travis AFB, CA; 2. Uniformed Services University of the Health Sciences, Bethesda, MD

E428* That Sinking Feeling: A Radiographic Approach to Acquired Adult Flat Foot

Brown, C.; Ha, A.; Chew, F. University of Washington, Seattle, WA

E429* Handy Imaging Guide to Musculoskeletal Hand Pathology

Choi, E.¹; Choi, K.^{1,2}; Masih, S.^{1,2} 1. Ronald Reagan UCLA Medical Center, Los Angeles, CA; 2. West Los Angeles Veterans Administration, Los Angeles, CA

E430. 3-Tesla MRI of the Intrinsic Muscles of the Hand and Wrist: A Didactic Review of Their Anatomy, Functions and Related Pathologies

Pierre-Jerome, C.; Moncayo, V.; Terk, M. Emory University School of Medicine, Atlanta, GA

E431. The Radiologist's Guide to Lytic Lesions of the Hands and Feet

Grant, M.; Patel, S.; Parasu, N.; Jurriaans, E.; Finlay, K. McMaster University, Hamilton, Canada

E432. The Effect of Rotation Angle on the Measurement of BMD in the Forearm

Han, M.¹; Kwon, S.²; Juhng, S.³; Yang, S.⁴ 1. Chungnam National University Hospital, Daejeon, Korea 2. Chungnam National University College of Medicine, Daejeon, Korea 3. Wonkwang University Hospital, Iksan, Korea; 4. Eulji University Hospital, Daejeon, Korea

E433. Garden Variety 3D Femoral Neck Fractures: Garden Classification System

Yost, A.; Gridley, D. Maricopa Medical Center, Phoenix, AZ

E434. Intra-Articular Hip Injection: Pain Relief Correlated with Radiological Severity of Osteoarthritis

Alizadeh, A.; Klein, D.; Epstein, N.; Rodriguez, J. Lenox Hill Hospital, New York, NY

E435* Femoroacetabular Impingement: A Resident-Oriented Review

Duffy, P.; Cameron, S.; Zucconi, W.; Dinauer, P. Hospital of St. Raphael, New Haven, CT

E436* A Multi-Modality Approach to the Imaging of the Complications of a Hip Arthroplasty with Emphasis on Clinical and Radiologic Aspects

Gupta, S.¹; Diwan, A.¹; Yang, J.¹; McLaughlin, V.¹; Love, C.¹; Vrahas, M.² 1. St. Vincent's Catholic Medical Center, New York, NY; 2. Massachusetts General Hospital, Boston, MA

E437. Temporomandibular Joint: MRI Anatomy and Pathology

Gaillard, F.¹; Bhuta, S.² 1. Radiopaedia.org, Melbourne, Australia; 2. Gold Coast Hospital, Gold Coast, Australia

E438. Distal Femur Resection with Modular Endoprosthetic Reconstruction: Indications and Imaging Findings

Chakarun, C.¹; White, E.¹; Menendez, L.¹; Brien, E.²; Matcuk, G.¹; Patel, D.¹; Learch, T.² 1. University of Southern California, Los Angeles, CA; 2. Cedars-Sinai Medical Center, Los Angeles, CA

E439* Can MRI Predict the Progression of Osteochondral Lesion in the Pediatric Knee?

Maizlin, Z.¹; Ghandehari, H.¹; Algowizai, N.¹; Kuruvilla, M.¹; Missiuna, P.¹; Peterson, D.¹; Clement, J.² 1. McMaster University Medical Centre, Burlington, Canada; 2. St. Paul's Hospital, Vancouver, Canada

E440* Practical MR Evaluation of Knee Cartilage: Normal, Abnormal, and Why it Matters

Forney, M.; Robbins, M.; Winalski, C.; Subhas, N.; Parker, R.; Tyson, S. Cleveland Clinic Foundation, Mayfield Heights, OH

E441* AM or PL: Comprehensive Review of Functional Anatomy, MRI Appearance and Surgical Reconstruction of Normal and Injured Double Bundle ACL

Punjwani, N.; Kumaravel, M. University of Texas at Houston, Sugar Land, TX

* offers CME credit

ELECTRONIC EXHIBITS: Musculoskeletal



E442. MR Imaging Atlas of Anatomic Variants of the Knee

Shah, N.¹; Carter, K.² 1. Brigham and Women's Hospital, Natick, MA; 2. Pontiac Osteopathic Hospital, Pontiac, MI

E443. Use of the V Sign in the Diagnosis of Bucket Handle Meniscal Tear of the Knee

Rao, N.^{1,2}; Patel, Y.³; Chen, Q.²; Owen, J.²; Eisemon, E.²; Fogel, J.⁴; Beltran, J.² 1. Brigham and Women's Hospital, Boston, MA; 2. Maimonides Medical Center, Brooklyn, NY; 3. Jamaica Hospital Medical Center, Jamaica, NY; 4. Brooklyn College of the City University of New York, Brooklyn, NY

E444. Distended Gastrocnemius Bursae: Clinical Significance and Associated Findings on MRI

Moore, A.^{1,2}; Dahl, A.^{1,2}; Moore, T.^{1,2} 1. University of Nebraska Medical Center, Omaha, NE; 2. Nebraska Health Imaging, Omaha, NE

E445. Posterior Root of Lateral Meniscus: Anatomic Review Using 3T-MR

Park, J.¹; Park, S.²; Jin, W.²; Ryu, K.¹ 1. Kyung Hee University Medical Center, Seoul, Korea; 2. East-West Neo Medical Center, College of Medicine, Kyung Hee University, Seoul, Korea

E446. Occult Fracture in Traumatic Knee with Suprapatellar Effusion on Plain Radiograph

Kanth, N.; Ishak, C.; Ferretti, J.; Cardoza, S.; Rehmani, R. Nassau University Medical Center, East Meadow, NY

E447. Bursae of the Knee: Normal Anatomy, Complications and Mimics

Negahban, A.; Matcuk, G.; White, E.; Patel, D.; Forrester, D.; Masih, S.; Zand, T.; Tsai, J. LAC+USC Medical Center, Los Angeles, CA

E448. Ultrasound of the Knee—Normal Anatomy and Common Pathology

Craig, J.; van Holsbeeck, M.; Bouffard, J. Henry Ford Hospital, Ann Arbor, MI

E449. Imaging Features of Glomus Tumors

Laundre, B.; Glazebrook, K.; Schiefer, T.; Inwards, C. Mayo Clinic, Rochester, MN

E450* Imaging Review of Synovial Disorders

Shah, N.¹; Carter, K.² 1. Brigham and Women's Hospital, Natick, MA; 2. Pontiac Osteopathic Hospital, Pontiac, MI

E451. Quantifying Power Doppler Ultrasound Using ImageJ 3D Color Inspector/Color Histogram

Cossi, A.; Cheng, J.; Holalkere, N.; Katur, A.; Rana, A.; Tornetta, P. Boston Medical Center, Boston, MA

E452. Subtrochanteric Femoral Fractures in Patients on Long-term Alendronate Therapy: Imaging Features

Chan, S.¹; Rosenberg, Z.²; Chan, K.²; Capecci, C.² 1. Zwanger-Pesiri, Lindenhurst, NY; 2. NYU, New York, NY

E453* MR Neurography Evaluation of Peripheral Nerve Surgery

Chhabra, A.; Wang, K.; Williams, E.; Carrino, J.; Thawait, S. Johns Hopkins University, Ellicott City, MD

E454. MR Neurography and Surgical Correlation of Tunnels

Chhabra, A.; Subhawong, T.; Williams, E.; Carrino, J.; Thawait, S. Johns Hopkins University, Ellicott City, MD

E455* MRI of Upper Extremity Peripherical Neuropathy

Rao, D.; Rao, D.; Diaz, L. Boston VA healthcare, Boston, MA

E456* Role of ADC Mapping in Evaluation of Leukemic Infiltration of Vertebrae with Post Chemotherapy and / or Post Radiotherapy Marrow Changes

Shah, S.; Parekh, K.; Vadvala, H.; Rajpura, H.; Sethi, S.; Goswami, K. Gujarat Cancer & Research Institute, Ahmedabad, India

E457. Liposarcoma: Where is the Fat?

O'Regan, K.; Souza, F.; Jagannathan, J.; Ramaiya, N.; Van den Abbeele, A. Dana Farber Cancer Institute, Boston, MA

E458. Anterior Pelvic and Abdominal Sources of Groin Pain: How Anatomy Predisposes to Injury as Demonstrated by MSKUS and MR Evaluation

Brandon, C.; Jacobson, J.; Fessell, D.; Girish, G.; Morag, Y.; Jamadar, D.; Dong, Q.; Jiang, Y. University of Michigan, Ann Arbor, MI

E459* The Sacrum and Sacral Plexus: A Multimodality Overview of Pathologic Entities and Associated Neuromuscular Disorders

Apgar, J.¹; Wissman, R.¹; Gorman, D.¹; Towbin, A.² 1. University of Cincinnati, Cincinnati, OH; 2. Cincinnati Children's Hospital Medical Center, Cincinnati, OH

E460* Imaging of Sacroiliac Joint Pathology

Chow, K.; Lal, M.; Modarresi, S.; Masih, S. Veterans Administration Greater Los Angeles, Los Angeles, CA

E461* Acromioclavicular Separations

Merunka, V.; Viets, R.; Lynskey, G. Beth Israel Medical Center, New York, NY

E462. Shoulder Ultrasound Tutorial: How to Perform a Scan, Review of Normal Imaging, and Abnormal Findings

Robbins, M.; Subhas, N.; Winalski, C.; Schils, J.; Forney, M.; McNulty, D.; Tyson, S. Cleveland Clinic, Mayfield Heights, OH

E463. Abnormal Sonographic Findings of Asymptomatic Shoulder Scans

Girish, G.; De Gama Lobo, I.; Boon, T.; Robertson, B.; Morag, Y.; Fessell, D.; David, J.; Miller, B. University of Michigan, Ann Arbor, MI

E464* A Pictorial Review of Soft Tissue Calcifications

Khan, M.^{1,2}; Terk, M.² 1. University of California at San Diego, San Diego, CA; 2. Emory University, Atlanta, GA

E465* Metabolic Imaging Of Musculoskeletal Pathology with MR Spectroscopy: How Far Have We Come?

Fayad, L.; Wang, X.; Machado, A.; Barker, P. Johns Hopkins, Baltimore, MD

ELECTRONIC EXHIBITS: Musculoskeletal



E466. Patterns of MRI Findings in Various Skeletal Muscle Disorders

Theodorou, D.; Theodorou, S.; Kakitsubata, Y. University of California, San Diego, CA, San Diego, CA

E467. Imaging of Deep Fibromatoses

Manzella, A.; Borba Filho, P.; Albuquerque, E.; Zelaquett, C.; Bezerra, E.; Costa, H.; Fonseca, C.; Souza, M. Hospital das Clinicas da Universidade Federal de Pernambuco, Recife, Brazil

E468* Review of Intra-Articular Lesions

Powell, A.¹; Song, A.²; Walker, E.^{1,3}; Murphey, M.^{2,3} 1. Milton S. Hershey Medical Center, Hershey, PA; 2. Armed Forces Institute of Pathology, Washington, DC; 3. Uniformed Services University of the Health Sciences, Bethesda, MD

E469. MRI Evaluation of Tumor and Tumor-like Conditions of Skeletal Muscle

Motamedi, D.¹; Modarresi, S.²; Chow, K.² 1. Cedars-Sinai Medical Center, Santa Monica, CA; 2. West Los Angeles VA/UCLA Medical Center, Los Angeles, CA

E470* MRI of the Musculocutaneous Flap: Description of the Normal, the Suspicious and the Abnormal

Moncayo, V.; Pierre-Jerome, C.; Monson, D.; Terk, M. Emory University School of Medicine, Atlanta, GA

E471. MRI Appearance in Two Cases of Angiomatoid Fibrous Histiocytoma: An Exceedingly Rare Entity with Interesting Findings!

Ajlan, A.¹; Sayegh, K.²; Powell, T.²; Nahal, A.² 1. University of British Columbia, Vancouver, Canada; 2. McGill University Health Centre, Montreal, Canada

E472. Imaging Findings of Intravascular Papillary Endothelial Hyperplasia Presenting in Extremities: Correlation with Pathologic Findings

Lee, S.; Choo, H.; Park, Y.; Park, J. Inje University Busan Paik Hospital, Busan, South Korea

E473. Specific Imaging Features of Benign Soft Tissue Tumors and Tumor-Like Conditions: A Pictorial Review

Bridges, S.; Garcia, G.; Loreda, R.; Rahal, A.; Williams, R. The University of Texas Health Science Center at San Antonio, San Antonio, TX

E474* Imaging of Musculoskeletal Complications of Thermal Burns

Raikhlin, A.; Christakis, M. University of Toronto, Toronto, Canada

E475. Musculoskeletal Soft Tissue Masses: A Review of Sonographic, MR and Pathologic Features

Backer, M.; Patel, B.; Larrison, M. University of Alabama at Birmingham, Birmingham, AL

E476. Preoperative Sonographic Localization of Foreign Bodies with Postoperative Pathologic Correlation

Scalcione, L.; Klein, M.; Teplitz, G.; Luchs, J. Winthrop-University Hospital, Mineola, NY

E477. Approach to the Acute Spine in The Multi-Trauma Patient: A Primer for the Body Imager

Rehmani, R.¹; Lev, S.^{1,2} 1. Nassau University Medical Center, East Meadow, NY; 2. North Shore/LIJ, Manhasset, NY

E478. Diagnostic Approach to Disc Space Destruction

Gatewood, J. University of Kansas, Kansas City, KS

E479. A Practical MRI Grading System for Lumbar Foraminal Stenosis

Lee, S.¹; Lee, J.²; Kang, H.²; Yeom, J.²; Kim, Y.³; Cho, O.³ 1. Korea University Guro Hospital, Seoul; 2. Seoul National University Bundang Hospital, Seongnam-si, Gyeonggi-do, Korea; 3. Hanyang University College of Medicine, Kuri City, Kyunggi-do, Korea

E480* Complications of Spinal Fixation Hardware—A Pictorial Review

Katzen, J.; Chadez, T.; Brindle, K. George Washington University, Bethesda, MD

E481. Abnormalities and Variants of the Proximal and Distal Biceps Brachii Tendons

Elliott, A.; Yadavalli, S. William Beaumont Hospital, Royal Oak, MI

E482* Interactive 3D CT Models for Teaching Anatomy and Pathology in Common Hand and Wrist Trauma

Grauke, L.; Richardson, M. University of Washington, Seattle, WA

E483* The Guyon's Canal in Perspectives: 3-Tesla MRI Review of the Normal Anatomy, the Anatomical Variations and the Guyon's Canal Syndrome

Pierre-Jerome, C.; Moncayo, V.; Terk, M. Emory University School of Medicine, Atlanta, GA

E484. Comparison of Diagnostic Accuracy Between Dynamic Cine-Arthrography and Wrist MRI with or without Intra-Articular Contrast Injection in the Diagnosis of Intrinsic Ligament Tear or TFCC Tear, Based on Arthroscopic Findings of the Wrist

Kim, B.¹; Lee, G.¹; Park, J.¹; Cha, S.¹; Lee, K.¹; Hong, S.²; Kang, C.³; Lee, S.² 1. Korea University Ansan Hospital, Korea University College of Medicine, Gyeonggi-do, Korea; 2. Korea University Guro Hospital, Korea University College of Medicine, Seoul, Korea; 3. Korea University Anam Hospital, Korea University College of Medicine, Seoul, Korea

E485. Efficacy of High Resolution CT for Detection of Early Healing in Scaphoid Fractures

Choudur, H.; Di Ianni, M.; Guram, K.; Zarinehbafe, S.; Parasu, N. McMaster University, Hamilton, Canada

E486. Fractures in the Distal Radius—Relating Radiologic Assessment to Management

Hubeny, C.; Hedegard, W.; Mooney, S.; Dieudonne, G.; Seo, G.; Monu, J. University of Rochester, Rochester, NY

* offers CME credit

ELECTRONIC EXHIBITS: Neuroradiology/Head & Neck



E487* Diagnostic Cerebral Angiography—Indications, Technical Details with Hands on Approach, and Recognition of Complications
Srinivasan, A.; Mohan, S.; Hoeffner, E.; Mukherji, S. University of Michigan Health System, Canton, MI

E488. Comparison Between CT Angiography (3D-CTA) and Digital Subtraction Angiography (DSA) in Follow up of Post Clipped Cerebral Aneurysms
Richard, K.; Chakraborty, S.; Santos, M.; Glikstein, R. University of Ottawa, Faculty of Medicine, Ottawa, Canada

E489. Time of Flight MR Angiography of Micro Aneurysms at 7T
*Sammet, S.¹; Schmalbrock, P.¹; Bourekas, E.¹; Heverhagen, J.²; Knopp, M.¹
1. The Ohio State University, Columbus, OH; 2. Philipps Universität, Marburg, Germany*

E490* Normal Anatomy and Pathological Conditions of the Pineal Region: CT and MR Imaging
Gustas, C.; Vijay, K.; Agarwal, A.; Thamburaj, K. Penn State Hershey Medical Center, Hershey, PA

E491. Imaging Findings and Differential Diagnosis of Primary CNS Lymphoma in the Immunocompetent Versus the Immunocompromised Patient
O'Mahony, D.; Knox, M.; Wilson, G.; McDermott, R. St. James's Hospital, Dublin, Ireland

E492. Evaluation of Extracranial-Intracranial Bypass: Utility of CT Angiogram and CT Perfusion with Acetazolamide Challenge
*Vagal, A.¹; Leach, J.^{1,2}; Strunk, R.¹; Zuccarello, M.¹
1. University Hospital, Cincinnati, OH; 2. Cincinnati Childrens Hospital Medical Center, Cincinnati, OH*

E493. Accuracy of CT Cerebral Perfusion Imaging in Demonstrating Ischemia: A Correlation of the Size of Ischemic Lesions on CT Perfusion Compared to Diffusion Weighted Imaging
Ho, C.; Hussain, S.; Alam, T. Indiana University, Indianapolis, IN

E494. Safety of Gadobenate Dimeglumine for Contrast-Enhanced MR Imaging of the CNS in Intraindividual Crossover Studies
Kuhn, M. University of Illinois College of Medicine, Peoria, IL

E495* What Do You Do About that Pesky Corpus Callosal Lesion? A Systematic Approach
Bodiwala, R.; Bonfante-Mejia, E. University of Texas HSC at Houston, Houston, TX

E496. Brain Herniation
*Shogan, P.¹; Peterson, M.¹; Petermann, G.²; Smith, A.^{3,4}; Smirniotopoulos, J.^{3,4}
1. Walter Reed Army Medical Center, Washington, DC; 2. Marshfield Clinic, Marshfield, WI; 3. Uniformed Services University, Bethesda, MD; 4. Armed Forces Institute of Pathology, Washington, DC*

E497* Pathophysiology and Corresponding Imaging Changes in Stroke
Kanekar, S.; Roller, R.; Showalter, M. Penn State Milton Hershey Medical Center, Hershey, PA

E498. Differentiation of Non-Neoplastic Diseases from Neoplastic Lesions Based on Advanced Imaging Techniques
Tamrazi, B.; Mangla, R.; Kolar, B.; Almast, J.; Ekholm, S. University of Rochester Strong Memorial Hospital, Rochester, NY

E499* Radiology of Ataxia
Kanekar, S. Penn State Milton S. Hershey Medical Center, Hershey, PA

E500* White Matter Disease (WMD)
Roller, R.; Showalter, M.; Kanekar, S. Penn State Milton S. Hershey Medical Center, Hershey, PA

E501* Altered Mental Status in the Emergency Department: Looking Beyond the Obvious
Agarwal, A.; Nguyen, D.; Thamburaj, K.; Ouyang, T. Penn State Hershey Medical Center, Hershey, PA

E502* Imaging of the Meninges: Intracranial and Spinal
Wolin, E.; Vijay, K.; Agarwal, A.; Nguyen, D. Penn State Hershey Medical Center, Hershey, PA

E503* Headache Imaging: Is it Hypo or Hyper?
Grover, R.; Chakraborty, S.; Torres, C. University of Ottawa, Ottawa, Canada

E504* Imaging of the Cavernous Sinus: Normal Anatomy and Pathology
Wolin, E.; Agarwal, A.; Ouyang, T.; Thamburaj, K. Penn State Hershey Medical Center, Hershey, PA

E505* CT and MR Imaging of the Corpus Callosum: A Pictorial Essay
Allmendinger, A.; Krauthamer, A.; Morgan, J.; Matthews, J.; Spektor, V.; Destian, S. St. Vincent's Catholic Medical Center, New York, NY

E506* Neurofibromatosis 1 and 2 Revisited: A Comprehensive Yet Concise Imaging Overview of the Dominant Imaging Findings of NF-1 and 2 as Demonstrated by a 10 Year Collection of Cases
Gupta, N.; Gupta, J.; Palacios, E.; Rodgers, B. Tulane University of New Orleans, New Orleans, LA

E507* Cavernous Sinus: Review of Anatomy and Differential Diagnosis
Vanka, J.; Angtuaco, E.; Raghu, R.; Shah, C.; Kumar, M.; Kaushik, C.; Yousaf, M.; Vanhemert, R. UAMS, Little Rock, AR

E508* Pictorial Review of Jugular Foramen Lesions
Vanka, J.; Ramakrishniah, R.; Angtuaco, E.; Donepudi, S.; Shah, C. UAMS, Little Rock, AR

E509* Radiation Necrosis: When to Suspect and How to Diagnose by Imaging
Borghei, P.; Patel, B.; Palmer, C.; Curé, J.; Shah, R. University of Alabama at Birmingham, Birmingham, AL

E510. Look Beyond the Enhancing Margins: Significance of Peritumoral Region in Differentiation of Mass Lesions of the Brain
Mangla, R.; Ekholm, S.; Gill, G. University of Rochester, Rochester, NY

E511. Advanced Imaging in Follow-Up of Brain Tumors
Mangla, R.; Ekholm, S.; Almast, J. University of Rochester, Rochester, NY

E512.* Pitfalls and Artifacts in Dynamic Susceptibility Contrast MR Perfusion of Brain

Mangla, R.; Ekholm, S. University of Rochester, Rochester, NY

E513. Meningioma: Spectrum of Imaging Findings at Multi-Imaging Modalities

Abdel Razeq, A.¹; Castillo, M.² 1. Mansoura University Hospital, Mansoura, Egypt; 2. University of North Carolina, Chapel Hill, NC

E514.* Dural Sinus Thrombosis: Spectrum of Imaging Findings

Abdel Razeq A.¹; Castillo, M.² 1. Mansoura University Hospital, Mansoura, Egypt; 2. University of North Carolina, Chapel Hill, NC

E515.* Imaging Spectrum and Etiology of Cortical Laminar Necrosis

Shepherd, S.; Hoots, J.; Makariou, E. Georgetown University Hospital, Washington, DC

E516. Functional and Dysfunctional Anatomy of the Uncinate Fasciculus and Regional White Matter Pathways

Singh, S.; Mark, L.; Ulmer, J.; Guleria, S.; Gaggl, W.; Virshni, K.; Rohatgi, S.; Klein, A. Medical College of Wisconsin, Wauwatosa, WI

E517. Functional and Dysfunctional Anatomy of the Anterior Cingulum

Virshni, K.; Mark, L.; Ulmer, J.; Klein, A.; Guleria, S.; Rohatgi, S.; Gaggl, W.; Singh, S. Medical College of Wisconsin, Wauwatosa, WI

E518. Functional and Dysfunctional Anatomy of the Posterior Cingulum

Rohatgi, S.; Ulmer, J.; Mark, L.; Klein, A.; Virshni, K.; Singh, S.; Gaggl, W.; Guleria, S. Medical College of Wisconsin, Wauwatosa, WI

E519. Translating Diffusion Tensor Imaging for Presurgical Mapping

Ulmer, J.; Klein, A.; Mark, L.; Gaggl, W.; Virshni, K.; Guleria, S.; Singh, S.; Rohatgi, S. Medical College of Wisconsin, Wauwatosa, WI

E520. MR Imaging of Primary Central Nervous System Lymphomas (PCNSL)

Rashidi, F.; Nguyen, T.; Chakraborty, S.; Santos, M. University of Ottawa, Ottawa, Canada

E521. Characterizing "In-Situ Thrombus" in Intracranial Vasculature with Susceptibility Weighted Imaging (SWI)

Bhuta, S.; Wijedeera, R.; Hsu, C.; Kwan, G. Gold Coast Hospital, Gold Coast, QLD, Australia

E522. CNS Presentations of Leukemia as Primary Disease—A Scientific Exhibit of the Disease, its Complications and Infection

Vadvala, H.; Parekh, K.; Shah, S.; Rajpura, H.; Parida, S.; Goswami, K. Gujarat Cancer & Research Institute, Ahmedabad, India

E523. Schistosomiasis Mansoni as a Cause of Hypertensive Basal Ganglia

Manzella, A.; Borba-Filho, P.; Brandt, C.; Fonte, K. Hospital das Clinicas da Universidade Federal de Pernambuco, Recife, Brazil

E524. Enhancement-Perfusion Mismatch is Useful in Differentiation of Primary CNS Lymphomas From Other Enhancing Malignant Tumors of the Brain

Mangla, R.; Germin, B.; Ekholm, S. University of Rochester, Rochester, NY

E525.* What You Need to Know about MR Neuroimaging at 1.5T and 3T

Tanenbaum, L. Mt. Sinai School of Medicine, New York, NY

E526. Salvage Outcomes for Pituitary Adenomas Using Fractionated Stereotactic Radiosurgery: Cyberknife

Eaton, M.; Kovacs, M.; Zada, G.; Apuzzo, M.; Pagnini, P. University of Southern California + LAC, Los Angeles, CA

E527. The Correlation Between Carotid Siphon Calcification and Small-Vessel Infarction

Hong, N.; Seo, H.; Lee, Y.; Cha, S. Korea University Hospital, Ansan, South Korea

E528.* An Image-Based Approach to MR Artifacts in Neuroradiology

Morelli, J.¹; Runge, V.¹; Ai, F.²; Vu, L.¹; Nitz, W.³; Schmeets, S.³; Garg, V.¹; Desai, S.¹ 1. Scott and White Memorial Hospital and Clinic, Temple, TX; 2. Tongji Medical College of Huazhong University, WuHan, Hubei, China; 3. Siemens AG, Erlangen, Germany

E529. Correlation of PET Hypo-and Hypermetabolism with Surgical Outcome in Refractory Epilepsy

Talanow, R.; Wu, G. The Cleveland Clinic, Cleveland, OH

E530.* Cavernous Sinus Pathology: Characteristic Findings and Clinically Relevant Differential Diagnoses

Butani, D.¹; Gill, G.¹; Bhatt, A.¹; Dhillon, G.¹; Hung, J.²; Almast, J.¹ 1. University of Rochester Medical Center, Rochester, NY; 2. St Joseph Hospital, Ann Arbor, MI

E531.* I Spy Trouble: MDCT for the Evaluation of Acute Eye Pain in the Emergency Room

Downey, R.¹; Wesolowski, J.¹; Chan, R.²; Shtein, R.¹; Chong, S.¹ 1. University of Michigan, Ann Arbor, MI; 2. Weill Cornell Medical College, New York, NY

E532.* Anatomical Study of the Aortic Arch Great Vessels and Vertebral Arteries: Variations, Incidences and Their Correlations

Bergen, D.¹; Heran, M.¹; Fu, W.² 1. University of British Columbia, Vancouver, Canada; 2. University of Calgary, Calgary, Canada

E533.* Important and Potentially Dangerous ICA/ECA Communications: An Anatomic Review

Lee, B.¹; Whitehead, M.² 1. University of Virginia, Charlottesville, VA; 2. UCSD, San Diego, CA

E534.* Interactive Atlas of CT Anatomy of the Skull Base

Fakhfakh, K.¹; Ben Mahfoudh, K.¹; Guermazi, Y.¹; Haddar, S.¹; Mnif, Z.²; Mnif, J.¹ 1. CHU Habib Bourguiba, Sfax, Tunisia; 2. Chu Hedi Chaker, Sfax, Tunisia

E535.* Neurogenic Thoracic Outlet Syndrome—A Review of CT and MRI Findings

Iqbal, S.; Donahue, D.; Mehndiratta, A.; Torriani, M.; Gupta, R. Massachusetts General Hospital, Boston, MA

* offers CME credit

ELECTRONIC EXHIBITS: Neuroradiology/Head & Neck



E536. Imaging of the Neck Nodes; What is More Important Than Size?

Agarwal, A.; Sabat, S.; Ouyang, T.; Thamburaj, K. Penn State Hershey Medical Center, Hershey, PA

E537. Seeing is Believing: Orbital Emergencies on CT and Their Mimics

Winestone, M.; Lynskey, G.; Viets, R. Beth Israel Medical Center, New York, NY

E538* Pediatric Pop-Eye

Mathew, N.; Wu, L.; Nguyen, V. Long Island Jewish Medical Center, New Hyde Park, NY

E539* Role of 3D CT in the Evaluation of Craniosynostosis

Buckler, M.; Wu, L.; Nguyen, V. Long Island Jewish Medical Center, New Hyde Park, NY

E540* Congenital Hearing Loss

Wu, L.; Nguyen, V. Long Island Jewish Medical Center, New Hyde Park, NY

E541* Choked into Stroke: Anomalous Insertion of the Vertebral Artery into the Transverse Foramen

Lynskey, G.; Viets, R. Beth Israel Medical Center, New York, NY

E542. WITHDRAWN

E543. Imaging and Pathologic Features of Primary Intraosseous Meningioma

Hussain, S.; Hattab, E.; Mosier, K.; Douglas-Akinwande, A. Indiana University School of Medicine, Indianapolis, IN

E544* Imaging the Pharyngeal Mucosal Space: The Aerodigestive Front Line

Kaur, H.¹; Katzen, J.¹; Parghi, C.¹; Tu, R.^{1,2}; Jones, R.¹ 1. George Washington University, Washington, DC; 2. Progressive Radiology, Washington, DC

E545. Differential Diagnosis of Sinonasal Masses and Mass-like Lesions

Schemmel, D.; Borghei, P.; Chapman, P.; Shah, R. University of Alabama at Birmingham, Birmingham, AL

E546. What's in a Name? Eponyms in Head and Neck Radiology

Spanos, G.; Go, J. USC, Los Angeles, CA

E547. Carotid Sheath/Space: Normal Anatomy and Pathology

Bangiyev, L.¹; Hyoung, O.¹; Reede, D.¹; Smoker, W.²; Holliday, R.³; Gentry, L.⁴ 1. Long Island College Hospital, Brooklyn, NY; 2. University of Iowa Hospitals and Clinics, Iowa City, IA; 3. The New York Eye and Ear Infirmary, New York, NY; 4. University of Wisconsin Hospital and Clinics, Madison, WI

E548. Neurocytomas: The Good, the Bad, and the Ugly

Hobbs, S.¹; Goldstein, S.¹; Smith, A.^{2,3} 1. University of Kentucky, Lexington, KY; 2. Uniformed Services University, Bethesda, MD; 3. Armed Forces Institute of Pathology, Washington, DC

E549. The Clivus: from Embryology and Anatomy to Pathology

Dhillon, G.; Gill, G.; Kolar, B.; Almast, J. University of Rochester, Rochester, NY

E550. Skull Base Lesions—A Review of Imaging Characteristics and Normal Anatomy

Stewart, B.¹; Rebello, R.²; Kennedy, S.¹ 1. McMaster University, Hamilton, Canada; 2. St. Joseph's Hospital, Hamilton, Canada

E551. Rare Neoplasms of Maxilla—CT and MRI Evaluation

Pandhi, S.; Vaishnav, K.; Kumar, V.; Goswami, K.; Rathi, Y. Gujarat Cancer and Research Institute Ahmedabad Gujarat India, Ahmedabad, India

E552. Multiple Imaging Manifestations of the "Great Mimic" Neurosarcoidosis

Casey, D.; Palacios, E. Tulane University Health Sciences Center, New Orleans, LA

E553. Inner Ear Pathology: A Comprehensive Imaging Overview of Pathological Processes Affecting the Bony and Membranous Labyrinth

Gupta, N.; Gupta, J.; Palacios, E.; Rodgers, B. Tulane University of New Orleans, New Orleans, LA

E554. MRI Spectrum of Developmental Anomalies of Hypothalamic Pituitary Axis

Singh, P.; Giragani, S.; Khandelwal, N.; Gupta, V. PGIMER, Chandigarh-23, India

E555* Trouble at the Intersection: Pathologies of the Cavernous Sinus

Borghei, P.; Schemmel, D.; Roberson, G.; Shah, R. University of Alabama at Birmingham, Birmingham, AL

E556. Peripheral Facial Nerve Palsy: A Spectrum of Imaging Findings

Tan, J.; Mafee, M. University of California, San Diego, San Diego, CA

E557* Imaging of the Cranial Nerves: Structure, Function and Pathology

Maloney, J.¹; Poon, C.^{2,3}; Parkhurst, R.¹; Kier, E.³ 1. SUNY Upstate Medical University, Syracuse, NY; 2. University of Chicago, Chicago, IL; 3. Yale University School of Medicine, New Haven, CT

E558. 3T Dynamic Contrast Enhanced MRI and PET/CT of Metastatic Medullary Thyroid Carcinoma

Sammet, S.; Griffin, R.; Liang, J.; Yang, X.; Zhang, J.; Hall, N.; Shah, M.; Knopp, M. The Ohio State University, Columbus, OH

E559. Role of Diffusion Weighted MR Imaging in Differentiation of Masticator Space Infection from Tumor

Abdel Razek, A. Mansoura University Hospital, Mansoura, Egypt

E560* Pterygopalatine Fossa; An Important Intersection

Sathyakumar, V.; Angtuaco, E.; Ramakrishnaiah, R.; Kaushik, C.; Kumar, M.; Yousaf, M.; Shah, C. University of Arkansas for Medical Sciences, Little Rock, AR

E561* Radiological Anatomy of the Central Skull Base: A Systematic and Optimized Approach

Grover, R.; Dos Santos, M. University of Ottawa, Ottawa, Canada

* offers CME credit

E562* Navigating Around the Globe: A Location Based Algorithmic Approach to the World of Orbital Trauma

Gluck, G.; Lev, S. Nassau University Medical Center, East Meadow, NY

E563. Spectrum of Complications of Temporal Bone Fractures

Krauthamer, A.; Gerena, M.; Morgan, J.; Destian, S. New York Medical College at St. Vincent's Hospital, New York, NY

E564* Review of the Imaging Findings of Incidental Calvarial and Facial Bone Lesions

Krauthamer, A.; Morgan, J.; Allmendinger, A.; Spektor, V.; Destian, S. New York Medical College at St. Vincent's Hospital, New York, NY

E565* Cerebrospinal Fluid Leaks: Work Up and Diagnostic Imaging In 2009

Casey, D.; Rodgers, B.; Palacios, E.; Friedlander, P. Tulane University, New Orleans, LA

E566. Orthopantomogram Findings to Differentiate Early Malignant Erosion of Mandible from Root Resorption in Case of Carcinoma of Buccal Mucosa

Parekh, K.; Vadvala, H.; Rajpura, H.; Shah, S.; Rathi, Y.; Goswami, K. Gujarat Cancer & Research Institute, Ahmedabad, India

E567. Keeping an Eye on Orbital and Ocular Injuries

Carr, R.1; Couch, S.2; Dalley, R.1; Beauchamp, N.1 1. University of Washington, Seattle, WA; 2. Mayo Clinic, Rochester, MN

E568. Calcified Orbital and Ocular Lesions: An Approach to Diagnosis

Carr, R.1; Couch, S.2; Dalley, R.1; Beauchamp, N.1 1. University of Washington, Seattle, WA; 2. Mayo Clinic, Rochester, MN

E569. Limited Views of the Orbits to Screen for Metallic Foreign Bodies Prior to MR Imaging

Berner, M.; Kier, R.; Muro, G.; Graf, D. Bridgeport Hospital, Bridgeport, CT

E570* Carotid Artery Doppler Ultrasound: Pearls and Pitfalls with Multimodality Comparative Imaging

Ginat, D.; Sidhu, R.; Bhatt, S.; Dogra, V. University of Rochester, Rochester, NY

E571* Multimodality Approach to Imaging of Parathyroid Adenomas

Lee, W.1; Farrell, S.1; Temple, F.1; Harding, J.1; Hennessy, O.1; Hoang, J.2 1. St. Vincent's Hospital, Fitzroy, Australia; 2. Duke University Medical Center, Durham, NC

E572. Fine Needle Aspiration of Thyroid Nodules: Can False Negative Rates be Reduced?

Ginat, D.; Voci, S.; Rubens, D. University of Rochester, Rochester, NY

E573. Recurrence in the Thyroidectomy Bed: Sonographic Findings

Kamaya, A.; Gross, M.; Jeffrey, B. Stanford University, Stanford, CA

E574. Sonographic Differentiation of Benign and Malignant Thyroid Nodules: Prospective Study

Kim, D.; Lee, Y.; Sin In, H.; Jeong, H.; Eun, C. Busan Paik Hospital, Inje University School of Medicine, Busan, Korea

E575* Bisphosphonate-Associated Osteonecrosis of the Jaws

Godoy, L.; Sartim, R.; Almeida, F.; Sênedá, L.; Cerri, G.; Gebrim, E. Hospital Sírio Libanês, Sao Paulo, Brazil

E576. Comparison of 3T Diffusion Weighted MRI and 18F-fluoro-2-deoxyglucose PET/ CT in Cervical Lymphadenopathy of Patients With Nasopharyngeal Carcinoma

Anthony, M.; Zhang, Z.; Feng, S.; Yau, K.; Khong, P.; Mak, H. University of Hong Kong, Hong Kong, Hong Kong

E577. Distinguishing Intrathyroid Parathyroid Pathology from Thyroid Nodules

Heller, M.; Tublin, M. University of Pittsburgh, Pittsburgh, PA

E578* Imaging of the Clivus: Normal, Abnormal and as a Marker of Underlying Systemic Disease

Vijay, K.; Moore, G.; Agarwal, A.; Nguyen, D. Penn State Hershey Medical Center, Hershey, PA

E579. Loss of Vision: Imaging of the Visual Pathway, from the Retina to the Visual Cortex

Agarwal, A.; Ouyang, T.; Sabat, S.; Nguyen, D. Penn State Hershey Medical Center, Hershey, PA

E580. Nasopharyngeal Squamous Cell Carcinoma (NPSCCa): What Radiologists Should Know?

Ukisu, R.; Yagi, S.; Koyama, K.; Oba, K.; Fukushima, T.; Fujisawa, H.; Takenaka, H.; Kushihashi, T. Showa University Northern Yokohama Hospital, Yokohama, Japan

E581* Thyroid Gland Metastases: Overview of Imaging Findings with Pathological Correlation

Iyer, V.; Lubitz, C.; Stephen, A.; Hahn, P.; Harisinghani, M. Massachusetts General Hospital, Boston, MA

E582* A Systematic Review of the Normal Vascular Anatomy of Spinal Cord with Clinical Applications

Mohan, S.1; Parmar, H.1; Srinivasan, A.1; Gandhi, D.2; Mukherji, S.1 1. University of Michigan Health System, Ann Arbor, MI; 2. The Johns Hopkins Hospital, Baltimore, MD

E583. Pictorial Review of Imaging Characteristics of Intradural Spinal Tumors

Jabehdar Maralani, P.; Chakraborty, S. University of Ottawa, Ottawa, Canada

E584* Spinal Angiogram—Vascular Anatomy, Indications, Technical Details and Management of Complications

Mohan, S.; Srinivasan, A.; Chaudhary, N.; Pandey, A.; Thompson, B.; Gemmete, J. University of Michigan Health System, Canton, MI

E585. Style and Content of CT and MRI Spine Reports: Radiologist and Clinician Preferences

Ghali Eskander, M.; Leung, A.; Lee, D. The University of Western Ontario, London, Canada

E586* CT-Guided Cervical Nerve Root Blocks: Tips, Traps and Contrast Utilization

Apostol, M.; Kranz, P.; Gray, L.; Taylor, J.; Lascola, C.; Kilani, R.; Hoang, J. Duke University, Wake Forest, NC

ELECTRONIC EXHIBITS: Neuroradiology/Head & Neck



E587. Radiologic-Pathologic Correlation of Pediatric Intramedullary and Extramedullary Intradural Spinal Neoplasms: A Pictorial Review

Soderlund, K.1; Smith, A.2,3; Rushing, E.2; Smirniotopoulos, J.3 1. National Naval Medical Center, Bethesda, Bethesda, MD; 2. Armed Forces Institute of Pathology, Washington, DC; 3. Uniformed Services University, Bethesda, MD

E588* CTA Evaluation of Collateral Pathways in Carotid Occlusive Disease

Shah, L.; Kieper, K. University of Utah, Salt Lake City, UT

E589. Assessment of Automated Bone Removal for CT Angiography of the Skull Base Comparing Sequential Single Energy CT with Simultaneous Dual Energy Extraction Techniques: Differences in Radiation Dose and Postprocessing Results

Blackham, K.; Ciancibello, L.; Gilkeson, R.; Tarr, R.; Hsu, D. University Hosp of Cleveland Case Medical Center, Cleveland, OH

E590* Multidetector CT Evaluation of Carotid Atherosclerotic Disease: Spectrum of Vulnerability

Antypas, E.; Nandalur, K. William Beaumont, Royal Oak, MI

* offers CME credit



E591. HIDA Scan: Thinking Outside the Biliary Tree: Unexpected Findings on Cholescintigraphy

Masuda, E.; Dalal, I. Henry Ford Hospital, Detroit, MI

E592.* Osseus Pathology of the Lower Extremity in Children: Tc99m Bone Scan Findings with Emphasis on Correlative Imaging

Trout, A.; Brown, R.; Jacobson, J.; Lahti, L. University of Michigan Health System, Ann Arbor, MI

E593. Detection of Recurrent Gliomas Treated with Surgery and Radiation Therapy Using Alpha-[11C]methyl-L-tryptophan (AMT) and 18F-fluorodeoxyglucose (FDG) Positron Emission Tomography

Bahl, G.¹; Barger, G.²; Mittal, S.²; Chakraborty, P.²; Kupsky, W.²; Juhasz, C.²
1. Wayne State University/Detroit Medical Center, Madison Heights, MI; 2. Wayne State University, Detroit, MI

E594. PET Findings in Amyotrophic Lateral Sclerosis with Cognitive Impairment

Talanow, R.; Wu, G.; Pioro, E. The Cleveland Clinic, Cleveland, OH

E595.* Is a 18-FDG PET/CT Superior to Tc-99m MDP Bone Scan with SPECT in the Initial Staging of Skeletal Metastases in Advanced Breast Cancer?

Sacks, A.; Subramaniam, R.; Gordon, R.; Mercier, G.; Ozonoff, A.; Hayim, M. Boston University Medical Center, Boston, MA

E596. Thymic Abnormalities on FDG PET/CT: Pictorial Essay

Merkulov, A.; Sadowski, S.; Ghesani, N. UMDNJ-NJMS, Secaucus, NJ

E597. Therapy Options For Hyperthyroid Patients: A Guide For The Practicing General Radiologist

Rodgers, B.; Gupta, J. Tulane University, New Orleans, LA

E598. 18F-FLT PET/CT: Early Predictive Imaging Biomarker for Therapy Response

Surasi, D.¹; Subramaniam, R.¹; Chapman, M.¹; Davison, J.¹; Peller, P.²; Mercier, G.¹
1. Boston Medical Center, Boston, MA; 2. Mayo Clinic, Rochester, MN

E599. Improving Informed Consent for Radioactive I-131 Treatment

Epling, J.; Veselicky, K. West Virginia University, Morgantown, WV

E600.* Pictorial Review of Nuclear Arthrography with Correlation to Surgical Findings

Espinosa, L.; Danielsky, P.; Sabb, B.; Blaha, J.; Brown, R.; Frey, K. University of Michigan, Ann Arbor, MI

E601. The Good, the Bad, and the Ugly: A Case Review of Pulmonary Nodule Evaluation with PET/CT

Arani, K.¹; Nandalur, K.^{1,2}; Wong, C.¹
1. William Beaumont Hospital, Royal Oak, MI; 2. WBH, Royal oak, MI

E602. FDG PET/CT in the Primary Staging Evaluation of Adenocarcinoma of Lung

Talanow, R.; Shrikanthan, S.; Mohammed, T. The Cleveland Clinic, Cleveland, OH

E603. The Value of FDG-PET/CT in the Management of HIV-Related Malignancies

Davison, J.; Cooley, T.; Subramaniam, R. Boston University School of Medicine, Boston, MA

E604.* The Role of FDG PET/CT Scan in the Evaluation of Extranodal Lymphoma

Khayyat, N.^{1,2}; Tarabishi, A.^{1,2}; Joyrich, R.^{1,2}
1. Wayne State University, Detroit, MI; 2. Detroit Medical Center, Detroit, MI

E605.* Common Artifacts in Breast Lymphoscintigraphy: Diagnosis, Prevention and a Pictorial Review

Khot, R.; Rehm, P. University of Virginia, Charlottesville, VA

E606. FDG-PET/CT in the Assessment of Unknown Primary Tumor Presenting with Lymphadenopathy

Rajebi, M.^{1,2}; Wells, K.²; Fu, Y.²
1. SUNY Upstate Medical University, Syracuse, NY; 2. University of Tennessee Medical Center, Knoxville, TN

E607.* PET/CT of the Lymphoma: Imaging Findings According to Histological Subtypes

Yang, S.¹; Kim, D.¹; Lee, Y.¹; Chun, T.¹; Kim, K.¹; Han, H.¹; Yoo, H.¹; Hwang, C.²
1. Eulji University Hospital, Daejeon, South Korea; 2. Konyang University Hospital, Daejeon, South Korea

E608. Outside The Box: Utilizing Balloon Models as a New Technique to Teach Concepts of Nuclear Cardiology

Gerard, P.; Lefkowitz, Z.; Duarte, M. Westchester Medical Center, New York, NY

E609.* What Kind of Scan Is It? New Techniques In Teaching Residents The Recognition of Whole Body Nuclear Scans

Gerard, P.¹; Lefkowitz, Z.¹; Wu, J.¹; Dua, S.¹; Moonthungal, S.²
1. Westchester Medical Center, New York, NY; 2. Hackensack University Medical Center, Hackensack, NJ

E610.* E-NUCS: Online Evaluation and Skills Development in Nuclear Medicine with a Focus on Hybrid Modalities Such as PET/CT and SPECT/CT

Talanow, R.^{1,2}; Grunewald, M.³; Kuwert, T.³
1. The Cleveland Clinic, Cleveland, OH; 2. EduRad, Cleveland Heights, OH; 3. University of Erlangen/Nürnberg, Erlangen, Germany

E611.* Crucial FDG Avid Non-Malignant Findings on PET/CT: Avoiding Misdiagnoses

Nekhline, M.; Masuda, E.; Dalal, I. Henry Ford Hospital, Detroit, MI

E612.* Complex Regional Pain Syndrome

Verzosa, S. Beth Israel Medical Center, New York, NY

E613. Comparison of Tc-99m Sestamibi and Tc-99m Tetrofosmin for Preoperative Localization in Primary Hyperparathyroidism

Talanow, R.; Neumann, D. The Cleveland Clinic, Cleveland, OH

E614. Extramedullary Disease of Multiple Myeloma: Multi-Modality Imaging with Emphasis on MR and PET/CT

Nguyen, B.; Ram, P.; Roarke, M. Mayo Clinic, Scottsdale, AZ

E615. Out of the Box: The Unique Role of PET/CT in the Diagnosis and Management of Unusual Male Malignancies

Gerard, P.¹; Lefkowitz, Z.¹; Butler, J.²; Huang, J.²; Nichols, R.¹; Chang, P.¹
1. Westchester Medical Center, New York, NY; 2. Maimonides Medical Center, Brooklyn, NY

ELECTRONIC EXHIBITS: Pediatric Imaging



E616* Pediatric Bladder Masses and Their Mimics: A Multimodality Pictorial Review

Friedkin, A.; Chow, J.; Taylor, G. *Children's Hospital Boston, Boston, MA*

E617* Pediatric Stress Fractures: An Interactive Case Series with Emphasis on MRI and Radiologic Correlation

Vogelius, E.; Yarmohammadi, H.; Robbin, M.; Young, P. *UH Case Medical Center, Cleveland, OH*

E618* Pediatric Osteomyelitis: An Interactive Case Series with Emphasis on MRI and Radiologic Correlation

Yarmohammadi, H.; Vogelius, E.; Robbin, M.; Young, P. *UH Case Medical Center, Cleveland, OH*

E619* Imaging of Absent Septum Pellucidum on Prenatal Ultrasound: Correlation with Prenatal MRI

Chaturvedi, A.; Chaturvedi, A.; Dighe, M.; Ishak, G.; Dubinsky, T. *University of Washington, Seattle, WA*

E620* MR Imaging of Cerebellar Malformations

Abdel Razek, A.¹; Castillo, M.² 1. *Mansoura University Hospital, Mansoura, Egypt*; 2. *University of North Carolina, Chapel Hill, NC*

E621. Imaging Seizures in Pediatric Patients

Abdel Razek, A.¹; Castillo, M.² 1. *Mansoura University Hospital, Mansoura, Egypt*; 2. *University of North Carolina, Chapel Hill, NC*

E622* Head Sonography Self-Assessment Module: Review of Normal Anatomy with Emphasis on Pitfalls and Variants

Dean, J.^{1,2}; Sessions, J.^{1,2}; North, K.^{1,3}; Lowe, L.^{1,3} 1. *University of Missouri-Kansas City, Kansas City, MO*; 2. *St. Lukes Hospital of Kansas City, Kansas City, MO*; 3. *Children's Mercy Hospitals and Clinics, Kansas City, MO*

E623* Neonatal Cranial Sonography: A Pictorial Review

Nevile, S.; Shang, S.; Rotem, E.; Kazmmi, K. *Drexel/Hahnemann University Hospital, Philadelphia, PA*

E624. Utility of Sonography in Evaluation and Treatment of Pediatric Breast Infections

Kwok, L.; Katzman, M.; Leibman, A. *Albert Einstein College of Medicine-Jacobi Medical Center, Bronx, NY*

E625* Cardiac MRI of Transposition of the Great Vessels: A Review of MRI Appearance of Normal and Abnormal, Pre-and Post-Operative Findings and of Long Term Complications

Cohen, M.; Johnson, T. *Indiana University, Indianapolis, IN*

E626. Effectiveness of Standardized Color-Coding of Anatomical Structures in 3D Reconstructions of Congenital Heart Diseases Using CCTA

Ralhan, T.; Richardson, R.; Gurevich, M.; Diab, K.; Alboliras, E. *St. Joseph Hospital, Phoenix, Phoenix, AZ*

E627* A Different Side of Kids—Resident Difficulties and Solutions for Interpreting the Lateral Pediatric Radiograph

Abramson, L.; Lynskey, G.; Viets, R. *Beth Israel Medical Center, New York, NY*

E628. Spectrum of Air in the Wrong Places: From Pneumomediastinum to NEC

Jung, A.; Oh, Y.; Choi, S.; Yoon, S.; Woo, J.; Kim, H.; Yang, I.; Chung, S. *Kangnam Sacred Heart Hospital, Seoul, Korea*

E629. Congenital Foot Abnormalities: Plain Film Findings Made Simple

Hwang, B.¹; Gupta, S.¹; Saddler, M.¹; Siegel, S.²; Morgan, J.¹ 1. *New York Medical College at St. Vincent's Hospital and Medical Center of NY, New York, NY*; 2. *VA Medica Center East Orange, East Orange, NJ*

E630. Gastrointestinal Stromal Tumors

Beteselassie, N.¹; Ali, S.¹; Rivard, D.^{1,2} 1. *University of Missouri in Kansas City, Kansas City, MO*; 2. *Children's Mercy Hospitals and Clinics, Kansas City, MO*

E631. Occipital Sutures Revisited: Role of 3D MDCT Scan in Differentiating Fracture from Sutures

Adapa, P.; Moore, G.; Choudhary, A.; Jha, B.; Boal, D. *Penn State Hershey Medical Center, Hershey, PA*

E632. Unexpected MRI Findings in Suspected Legg-Calvé-Perthes Disease in Children with Negative or Equivocal Radiographs

Lobert, P.; Dillman, J.; Hernandez, R. *University of Michigan, Ann Arbor, MI*

E633. Review of Pediatric Liver Masses

Gordon, S.; Choi-Rosen, J. *Long Island Jewish Medical Center, Astoria, NY*

E634* Multimodality Imaging of Pediatric Liver Tumors

Shah, C.; Malkerker, D.; Spottswood, S.; Singh, S. *Vanderbilt University Medical Center, Nashville, TN*

E635. MR Imaging of Typical and Atypical Focal Nodular Hyperplasia in Treated Pediatric Oncologic Patients

Shaylor, S.; Do, R.; Abramson, S.; Price, A.; Wexler, L.; Kramer, K.; Shia, J.; Schwartz, L. *Memorial Sloan Kettering Cancer Center, New York, NY*

E636. Cat Scratch Disease: An Interactive Review of Typical and Atypical Imaging Manifestations in the Pediatric Population

Patel, S.; Lowe, L.; Leonard, P.; North, K.; Dettloff, K. *University of Missouri-Kansas City, Kansas City, MO*

E637. Tuberos Sclerosis—The Role of the Radiologist

O'Driscoll, D. *St. James Hospital, Dublin, Ireland*

E638* Normal and Pathologic Fetal Respiratory Tract Analysis Using MRI

Saba, L.; Angiolucci, M.; Sulcis, R.; Melis, G.; Mallarini, G. *Azienda Ospedaliero Universitaria, Cagliari Sardegna, Italy*

E639. Evaluation of Current CT Protocols with Goal of Minimizing Radiation Exposure in Pediatric Patients

Park, J.; Garelick, I.; Gesner, L. *St. Barnabas Medical Center, Livingston, NJ*

E640. Utility of FDG PET/CT in Pediatric Lymphomas

Talanow, R.; Karakas, P.; Shrikanthan, S. *The Cleveland Clinic, Cleveland, OH*

ELECTRONIC EXHIBITS: Pediatric Imaging

E641* Help Me! Somebody Hurt Me: A Pictorial Quiz of Nonaccidental Trauma

Wu, L.; Choi-Rosen, J. Long Island Jewish Medical Center, New Hyde Park, NY

E642. Evaluation of Pediatric CT Doses and Protocols

Gonzalez, E.; Beasley, C.; Firestone, K.; John, S.; Wagner, L. University of Texas at Houston, Houston, TX

E643* Gynecologic Masses in Pediatric and Adolescent: Tumors and Tumor Mimics

Nasseri, F.¹; Eftekhari, F.² 1. Baylor College of Medicine, Houston, TX; 2. University of Texas M. D. Anderson Cancer Center, Houston, TX

E644* Ovarian Torsion in Children and Young Girls: A Pictorial Review

Sonavane, S.; Kantawala, K.; Khanna, G. Mallinckrodt Institute of Radiology, St. Louis, MO

E645* Demystifying Skeletal Dysplasias: Skull and Craniocervical Junction

Foster, S.^{1,2}; Parnell, S.^{1,2}; Chew, F.² 1. Seattle Children's Hospital, Seattle, WA; 2. University of Washington, Seattle, WA

E646* Pictorial Review of Pediatric Scrotal Disorders

Goldberg, J.; Wind, E.; Thomas, A.; Choi-Rosen, J. Long Island Jewish Medical Center, New Hyde Park, NY

E647. Inferior Vena Cava Anomalies: CT, MR, and US with Clinical and Pathological Correlation, in the Setting of Wilm's Tumor and Tumor Thrombus Involvement

Park, B.^{1,2}; Chow, J.¹; Johnson, C.¹; Shamberger, R.¹; Vargas, S.¹; Jacobs, C.³; Prabhu, S.¹ 1. Children's Hospital Boston, Harvard, Cambridge, MA; 2. Mount Auburn Hospital, Cambridge, MA; 3. Beth Israel Deaconess Medical Center, Boston, MA

E648* "Puff of Smoke": Review of the Pathophysiology, Clinical and Radiological Manifestations, and Treatment Options of Moyamoya

Penarozza, S.; Boe, J.; Thai, T.; Maqbool, F. University of Oklahoma Health Sciences Center, Oklahoma City, OK

E649* Vascular Anomalies in Children: Update and Review of Classification

Abedin, S.¹; Marchant, T.²; Bailey, L.²; Scherbel, A.³; Fullingim, J.^{4,5}; Lowe L.^{1,5} 1. University of Missouri-Kansas City, Kansas City, MO; 2. Kansas City University of Medicine and Biosciences, Kansas City, MO; 3. Idaho State University, Radiographic Science, Rexburg, ID; 4. Oklahoma State University Medical Center, Tulsa, OK; 5. Children's Mercy Hospital and Clinics, Kansas City, MO

* offers CME credit



ELECTRONIC EXHIBITS: Vascular/Interventional



E650. CT Imaging of Thoracic Aortic Pathology and CT Follow-Up Imaging Status-Post Endograft Repair

Patel, A.; Hameed, T.; Rydberg, J.; Sandrasegaran, K.; Lall, C. *Indiana University School of Medicine, Indianapolis, IN*

E651. Nontraumatic Thoracic Aortic Pseudoaneurysms: CT Angiography and 3D Imaging Features of a Rarely Encountered Lesion

Farooqui, S.; Fishman, E. *Johns Hopkins University, Baltimore, MD*

E652. Prospective ECG Triggered 64 Slice CTA of the Thoraco-Abdominal Aorta

Mitsumori, L.; Green, D.; Warren, B.; Gunn, M.; Kolokythas, O.; Dubinsky, T.; Reddy, G.; Shuman, W. *University of Washington, Seattle, WA*

E653. Cervical Doppler Waveforms: What Should Every Radiologist Recognize?

Frias Vilaca, A.; Reis, A.; Pinto, J. *Hospital de São Sebastião, Santa Maria Da Feira, Portugal*

E654. Pulmonary Angiography: A Review of the Procedure and its Role in the 21st Century

Kwok, K.; Wiggins, E. *Monmouth Medical Center, Long Branch, NJ*

E655* Estimated Effective Dose of CT-Guided Thoracic Procedures

Foltz, G.; Maymani, H.; Yu, H.; Ogden, K.; Molina, P.; Birchard, K.; Dixon, R. *University of North Carolina, Carrboro, NC*

E656* Incidence and Clinical Outcome of Acute Ischemic Cholecystitis After Transarterial Chemoembolization (TACE) of Hepatocellular Carcinoma

Wagnetz, U.¹; Jaskolka, J.¹; Yang, P.²; Jhaveri, K.¹ 1. *Radiology, Toronto, Canada*; 2. *No Institutional Affiliation*

E657. Complications of Percutaneous Gastrostomy, Gastrojejunostomy and Jejunostomy: A Pictorial Review

Martin, C.; Mojibian, H.; Reiner, E.; Gunabushanam, G. *Yale University School of Medicine, New Haven, CT*

E658. Skull Views for Cerebral Angiography Foster Visualization

Taheri, M.; Cohen, W.; Ghodke, B.; Hallam, D.; Tozer, K. *University of Washington, Seattle, WA*

E659. Irreversible Electroporation: Emerging Technology Beyond Radiofrequency and Cryoablation

Mirza, S.¹; Adler, G.¹; Solomon, S.² 1. *New York-Presbyterian Hospital/Weill Cornell Medical Center, New York, NY*; 2. *Memorial Sloan Kettering Cancer Center, New York, NY*

E660* Polyarteritis Nodosa—An Educational Review

O'Driscoll, D. *St. James Hospital, Dublin, Ireland*

E661* Interventional Radiology Management of Renal Injuries in Complex Patients

Oppenheimer, J.¹; Lee, J.²; Kondo, K.²; Ray, C.² 1. *Northwestern University, Chicago, IL*; 2. *University of Colorado Denver, Aurora, CO*

E662* Percutaneous CT and US Guided Radiofrequency Ablation of Renal Tumors Adjacent to the Collecting System: Efficacy of Chilled Water Perfusion in Mitigating Thermal Injury

McClure, T.; Raman, S. *University of California-Los Angeles, Los Angeles, CA*

E663* Fluoroscopic Guided Removal of Renal Transplant Ureteral Stents: Technique of Choice

Shamimi-Noori, S.; Ramchandani, P.; Naji, A. *University of Pennsylvania, Philadelphia, PA*

E664. Preoperative Evaluation of Vascularized Fibular Grafts

Menon, S.; Loree, R.; Silberzweig, J. *Beth Israel, New York, NY*

E665. Imaging Evaluation and Vascular Interventions in the Inframalleolar Arterial Vasculature—The Evolving Frontier

Suri, R.; Garg, D.; Albayati, A.; Lopera, J.; Kroma, G. *UTHSCSA, San Antonio, TX*

E666. A Pictorial Review of Deep Venous Thromboses and the Endovascular Management

Wilner, A.; Wiggins, E. *Monmouth Medical Center, Long Branch, NJ*

E667. Evaluation of the Liver after Radiofrequency Ablation: Expected Post-Ablation Evolution and Complications

Patel, T.; Patel, T. *New York Presbyterian Hospital, Cornell, New York, NY*

E668. Measurement of Intrahepatic Pressure During Radiofrequency Ablation in Vivo Porcine Liver

Kawamoto, C.; Yamauchi, A.; Kaneko, K.; Miyagi, N.; Yakabi, K. *Saitama Medical Center, Saitama Medical University, Kawagoe, Japan*

E669* Solid Visceral Injuries: Imaging and Intervention

Backer, M.; Kapoor, B.; Oser, R.; Lockhart, M. *University of Alabama at Birmingham, Birmingham, AL*

E670. Complications of Transcatheter Arterial Chemoembolization (TACE): An Imaging Review with Clinical Integration

Lichtenberger, J.; Gover, D.; Jesinger, R. *David Grant Medical Center, Travis AFB, CA*

E671* Can Adrenalin Modulated Chemoembolization (TACE) Improve Tumor-Tissue Ratio of Chemotherapeutic Agent and Improve Tumor Ablation?

Lang, E.^{1,2}; Rudman, E.¹; Jaworsky, J.¹; Hanano, A.¹; Slakey, D.³ 1. *SUNY Downstate Medical Center, Brooklyn, NY*; 2. *Johns Hopkins Bayview Medical Center, Baltimore, MD*; 3. *Tulane University, New Orleans, LA*

E672. TIPS: The Covered Stent

Patel, T.; Funaki, B. *University of Chicago, Chicago, IL*

E673. Semiautomated Angle Selection Devices for Interventional Procedures

Mansouri, B.¹; Kapoor, A.¹; Li, M.¹; Guion, P.¹; Beck, A.¹; Saxena, V.¹; Sharma, K.^{1,2}; Wood, B.¹ 1. *National Institutes of Health, National Cancer Institute, Bethesda, MD*; 2. *Georgetown University Hospital, Washington, DC*

ELECTRONIC EXHIBITS: Vascular/Interventional



E674. Transjugular Liver Biopsy of Liver Transplant Patients: Anatomic Variants and Complications

Hockett, M.; Lee, E.; Loh, C.; McWilliams, J.; Kee, S. UCLA Medical Center, Los Angeles, CA

E675. Osler Weber Rendu: Diagnosis and Management

Gupta, J.; Gupta, N.; Palacios, E.; Blank, B.; Rodgers, B.; Schuber, S. Tulane University of New Orleans, New Orleans, LA

E676. Pulmonary Arteriovenous Malformations: Imaging and Intervention

Kapoor, B.; White, J.; Medsing, A.; Saddekni, S.; Underwood, E. University of Alabama at Birmingham, Birmingham, AL

E677* Planting the Seeds of Success: A Series of Imaging-Guided Fiducial Marker Placements for Directing Robotic Radiosurgery

Patel, A.¹; Lord, B.²; Lall, C.¹; Sandrasegaran, K.¹; Hameed, T.¹; Tann, M.¹; Berry, W.¹; Kohli, M.¹ 1. Indiana University School of Medicine, Indianapolis, IN; 2. Central Indiana Cancer Center/CyberKnife of Indianapolis, Indianapolis, IN

E678. Diagnosis and Management of Mesenteric Ischemia: An Update

Patel, B.; Kapoor, B.; Lockhart, M. UAB, Birmingham, AL

E679. CT Guided Percutaneous Biopsy of Abdominal and Pelvic Lesions—Techniques, Tips and Tricks

Sainani, N.; Gervais, D.; Mueller, P.; Arellano, R. Massachusetts General Hospital, Boston, MA

E680* Review of the Literatures of Vena Cava Anomalies: What Radiologist Should Know

Yagi, S.; Ukisu, R.; Koyama, K.; Oba, K.; Fukushima, T.; Fujisawa, H.; Takenaka, H.; Kushihashi, T. Showa University Northern Yokohama Hospital, Yokohama, Japan

E681. Hands On, Hands Off: The Delicate Balance of Teaching Residents to Perform Procedures

Patel, A.; Lall, C.; Sandrasegaran, K.; Hameed, T.; Tann, M.; Berry, W.; Kohli, M.; Majidi, S. Indiana University School of Medicine, Indianapolis, IN

E682. Optimizing Arteriovenous Fistula Maturation

Hall, A.¹; Zangan, S.¹; Falk, A.² 1. University of Chicago, Chicago, IL; 2. No Institutional Affiliation

E683. Pelvic Trauma: Diagnostic Imaging to Interventional Procedures

Chiou, M.; Lee, E.; McWilliams, J.; Loh, C.; Kee, S. UCLA Medical Center, Los Angeles, CA

E684. Embolic Protection Devices—An Update: Device Characteristics, Risks Versus Benefits, and Evidence-Based Review of Efficacy in the Non-Coronary Arterial System

Suri, R.; Albayati, A.; Garg, D.; Lopera, J.; Kroma, G. UTHSCSA, San Antonio, TX

E685. Endovascular Treatment of Arterial Injuries from Attempted Central Venous Catheter Placements: State of The Art

Hill, J.; Ray, C.; Morrow, J.; Gupta, R. University of Colorado, Denver, CO

E686. Dual-Wire Focused-Force Dilatation Balloon for Peripheral Lower Limb Angioplasty: Initial Experience

Teh, H.; Dubey, N.; Clarke, M.; Peh, W. Alexandra Hospital, Singapore, Singapore

E687* Potential Interactions Between Radio Contrast Media and Antibiotics and Their Possible Impact on Discography—An In Vitro Study

Langer, R.; Neidl v Gorkom, K.; Usmani, A.; Lorke, D.; Petroianu, G.; Banyias, M.; Azimullah, S.; Nurulain, S. FMHS UAE University, Al Ain, UAE

E688. Common Procedures in Nonvascular Genitourinary Interventional Radiology. How We Do It?

Karaosmanoglu, A.; Arellano, R.; Mueller, P. Massachusetts General Hospital, Boston, MA

E689. Catheter-Directed Thrombolysis and Thrombectomy of Acute Renal Vein Thrombosis: A Case Series

Mahne, A. Main Line Health-Bryn Mawr Hospital, Havertown, PA

E690. Using Ultrasound in Performing Image-Guided Interventions on Malfunctioning Arteriovenous Hemodialysis Shunts

Viets, R.; Patel, R. Beth Israel Medical Center, New York, NY

E691. Envascular Embolization of Visceral Artery Pseudoaneurysms

Lien, K.; Fatade, F.; Axelrod, D. Stony Brook University Medical Center, Stony Brook, NY

E692* Endovascular Management of Vascular Complications in Liver and Renal Transplants

Weisman, N.; Hawari, A.; Park, J. University of Southern California, Los Angeles, CA

E693. Anatomical Variants of the Inferior Vena Cava and its Clinical Implications for Filter Placement

Gunabushanam, G.; Martin, C.; Mojibian, H.; Reiner, E.; Pollak, J. Yale University School of Medicine, New Haven, CT

E694* Transhepatic and Translumbar Central Venous Catheters—A Reappraisal

Tisnado, J.¹; Komorowski, D.¹; Sydnor, M.¹; Tisnado, J.^{1,2}; Fox, W.¹ 1. MCV Hospitals / VCU Medical Center, Richmond, VA; 2. Hartford Hospital-Radiology, Hartford, CT

E695* The Role of Interventional Radiology in Venous Blood Sampling Revisited

Tisnado, J.¹; Amendola, M.^{1,2}; Tisnado, J.^{1,3}; Sydnor, M.¹; Komorowski, D.¹; Daniels, A.¹ 1. MCV Hospitals / VCU Medical Center, Richmond, VA; 2. Univ of Miami Leonard M. Miller SOM, Miami, FL; 3. Hartford Hospital-Radiology, Hartford, CT

* offers CME credit

ELECTRONIC EXHIBITS: Vascular/Interventional

**2010
ARRS**
ANNUAL MEETING
SAN DIEGO • MAY 2-7

E696* Central Venous Access in Children. A Comprehensive Review

Tisnado, J.¹; Tisnado, J.^{1,2}; Sydnor, M.¹; Komorowski, D.¹ 1. MCV Hospitals / VCU Medical Center, Richmond, VA; 2. Hartford Hospital-Radiology, Hartford, CT

E697. Klippel-Trenaunay Syndrome: Spectrum of Imaging Findings

Abdel Razek, A. Mansoura University Hospital, Mansoura, Egypt

E698* Angio CT Preoperative Evaluation for Anterolateral Thigh Flap Harvesting

Saba, L.; Atzeni, M.; Ribuffo, D.; Mallarini, G. Azienda Ospedaliero Universitaria, Cagliari Sardegna, Italy

E699. Multimodality Imaging of Renal Vascular Diseases: A Review of Invasive and Non-Invasive Techniques

To, T.; Han, S.; Clavijo, L.; Weaver, F.; Shriki, J. University of Southern California, Keck School of Medicine, Los Angeles, CA

E700* Superior and Inferior Mesentery Artery Aneurysms and Pseudoaneurysms—Radiologic Diagnosis and Management

Tisnado, J.; Prasad, U.; Sydnor, M.; Komorowski, D. MCV Hospitals / VCU Medical Center, Richmond, VA

E701. Vascular Ultrasound Interpretation: A Pictorial Collection of Tricky Cases

Rehmani, R.^{1,2}; Scarmato, V.^{1,2}; Pellerito, J.¹ 1. North Shore University Hospital, Manhasset, NY; 2. Nassau University Medical Center, East Meadow, NY

E702. Design of a Fiber Optic Ultraviolet Device for Treatment of Central Line Infections

Lin, R.¹ 1. No Institutional Affiliation

* offers CME credit



ARRS THANKS ITS CORPORATE PARTNERS AND CORPORATE SPONSORS

Corporate Partners:

GE Healthcare

Siemens Healthcare

Toshiba America Medical Systems, Inc.

Corporate Sponsors:

Agfa HealthCare

Bracco Diagnostics, Inc.

Calgary Scientific

Fujifilm Medical Systems

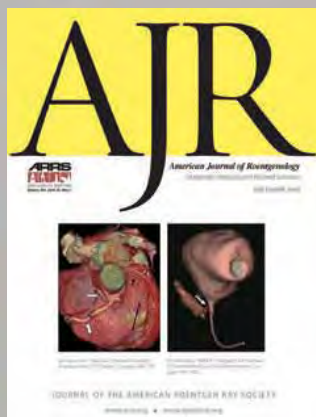Thieme Publishers

Third Eye Teleradiology

Quality Education From A Trusted Source For Radiologic Technologists

CERT is online Continuing Education for Radiologic Technologists that is:

- Cutting Edge
- Cost Effective
- Convenient Everyday



Adapted from selected *American Journal of Roentgenology* content by and for radiologic technologists, CERT offers ARRT Category A credit in the topic areas needed most, including CT, mammography, and MRI.

Available for radiologic technologists through ARRS membership or by subscription, lessons are available online 24/7 from the convenience of home or office—no costly travel or time away from the practice required.

CERT is practical, timely, and important—from a source you know and trust.



This is a great product to keep our radiologic technologists up-to-date in this fast-paced and ever-changing field of radiology.

— Bernard F. King, MD
Chair, Department of Radiology
Mayo Clinic, Rochester, MN

From Science to Practice, Quality Care for Your Patients

For more information visit www.arrs.org.

COMMERCIAL EXHIBITORS



American Board of Radiology

Booth: 202
5441 East Williams Boulevard, Suite 200
Tucson, AZ 85711
Phone: 520-790-2900
Fax: 520-790-3200
www.theabr.org

The mission of The American Board of Radiology is to serve the public and the medical profession by certifying that its diplomates have acquired, demonstrated, and maintained a requisite standard of knowledge, skill and understanding essential to the practice of radiology, radiation oncology and radiologic physics.



American College of Radiology

Booth: 314
1891 Preston White Drive
Reston, VA 20191
Phone: 703-648-8900
Toll free: 800-227-5463
www.acr.org

Founded in 1923, the American College of Radiology (ACR) celebrates its 87th anniversary this year as the foremost organization representing the interests of the nation's diagnostic radiologists, radiation oncologists, interventional radiologists, nuclear medicine physicians, medical physicists, and allied health professionals.

Through its core pillars of education, advocacy, quality and safety, and clinical research, the ACR serves patients and society by advancing the science of radiology, improving the quality of patient care, positively affecting the socioeconomics of the practice of radiology, providing continuing education opportunities for radiologists, and conducting clinical research for the future of radiology.

American Roentgen Ray Society



American Roentgen Ray Society

Booth Number: 315
1891 Preston White Drive
Reston, VA 20191
Phone: 800-347-7748
Fax: 703-264-2093
www.arrs.org

The American Roentgen Ray Society is an international membership organization of physicians and scientists in radiology and related fields. Founded in 1900, the ARRS mission is to improve the practice of radiology and increase the impact of radiologists on patient care by promoting the creation, exchange, dissemination and implementation of clinical information. In support of its objectives, the society publishes a monthly peer-reviewed journal, the *American Journal of Roentgenology* and produces a variety of educational products for the radiology community. Information on the benefits of membership, the *American Journal of Roentgenology* and other products and services can be obtained from staff members in the booth.



Amirsys, Inc.

Booth: 409
Carolyn S. Blevins
Manager of Marketing and Sales
2180 South 1300 East, Suite 405
Salt Lake City, UT 84106
Phone: 949-348-2208
Fax: 949-348-2236
Cell: 949-632-7898
E-mail: cblevins@amirsys.com
www.amirsys.com; www.statdx.com

STATdx® Diagnostic Decision Support system provides point-of-care reference support to the practicing radiologist. STATdx Diagnosis, Imaging Anatomy, and Expert Differential Diagnosis modules comprise the core, expert-Based content of STATdx. STATdx® Premier™ includes new features such as RADtools™, Procedures, RADsearch, Live References and Compare Anywhere. STATdx Premier may be integrated to provide seamless access.

COMMERCIAL EXHIBITORS



AprioMed

Apriomed, Inc.

Booth: 508
2 Palmer Drive, Suite 1A
Londonderry, NH 03053
Phone: 603-421-0875
Fax: 866-239-1797
www.apriomed.com

AprioMed develops and sells single use innovative products such as Bonoptoy, the coaxial bone biopsy needle system, SeeStar, the CT Guiding Device and Spirotome, the coaxial soft tissue biopsy needle system, that all aid the radiologist when performing percutaneous interventions, primarily in conjunction with CT scanning or CT fluoroscopy imaging procedures. The products are designed to increase precision and accuracy and to support the physician in reducing patient discomfort during interventions.



Aris Teleradiology

Booth: 208
5655 Hudson Drive, Suite 210
Hudson, OH 44236
Phone: 330-655-3800
Fax: 330-655-3828
www.aristeleradiology.com

Aris Teleradiology is a nationally recognized radiology services company that offers solutions to radiologists. Aris provides preliminary and final reads 24/7/365, tele-locums, subspecialty reads and on-site coverage in some cases. We have over 60 radiologists with subspecialty expertise including body imaging, neurology, musculoskeletal, CTA, breast MRI, PET/CT and tele-mammography.



Bard Biopsy Systems

A Business Unit of Bard Peripheral Vascular, Inc.

Booth: 300
1415 West 3rd Street
Tempe, AZ 85281
Phone: 480-894-9515
Toll Free: 800-321-4254
Fax: 480-966-7062
www.bardbiopsy.com

Bard is the world leader in biopsy innovations. Bard's newest innovation, the Finesse™ Ultra Breast Biopsy System, is the only self-contained, vacuum-assisted, ultrasound-guided breast biopsy system with SIMS Technology. Bard's Vacora® Breast vacuum-assisted breast biopsy system obtains large, high-quality, contiguous tissue samples under ultrasound, stereotactic x-ray and MR image guidance. The new UltraClip® Dual Trigger Breast Tissue Marker is simple to operate and provides exceptional control. Bard also offers localization wires, as well as core needle biopsy systems for lung, liver, breast and prostate biopsies.



Bassett Healthcare Network Bassett Medical Center

Bassett Medical Center

Booth: 200
Colleen Donnelly
One Atwell Road
Cooperstown, NY 13326
Phone: 607-547-6982
E-mail: colleen.donnelly@bassett.org
www.bassett.org

Bassett, a growing multi-specialty group in central New York state, is actively seeking board certified/board eligible radiologists. Interested candidates should be able to perform all basic modalities, angiography not required. Cooperstown, NY, is a beautiful, historic village located on Otsego Lake, with year round cultural and recreational activities. Cooperstown is a safe family-oriented community with excellent schools.

For information, contact Colleen Donnelly at (607) 547-6982 or email colleen.donnelly@bassett.org.

COMMERCIAL EXHIBITORS



Bayer HealthCare
Pharmaceuticals

Bayer HealthCare Pharmaceuticals

Booth: 201
6 West Belt
Wayne, NJ 07470
Phone: 973-694-4100
www.bayerus.com

Bayer HealthCare Pharmaceuticals is the U.S.-Based pharmaceuticals unit of Bayer HealthCare, a global, innovative leader in the healthcare and medical products industry. We aim to discover and manufacture products that improve human health worldwide by diagnosing, preventing and treating diseases in Women's Healthcare, Diagnostic Imaging, Specialized Therapeutics, Hematology, Cardiology and Oncology.

Bracco Imaging S.p.A.



Booth: 401
Holly Polo
107 College Road East
Princeton, NJ 08540
Phone: 609-514-2200
Toll Free: 1-800-631-5245
Fax: 609-514-2514
<http://usa.braccoimaging.com/>

Bracco Imaging S.p.A., a world leader in the diagnostic imaging business, develops, manufactures and markets diagnostic imaging agents and solutions that meet medical needs and facilitate clinical solutions. Headquartered in Milan, Italy, Bracco Imaging operates in over 80 markets worldwide. Bracco Diagnostics Inc. is the U.S. subsidiary of Bracco Imaging.



DR Systems, Inc.

Booth: 217
10140 Mesa Rim Road
San Diego, CA 92121
Phone: 858-625-3344
Fax: 858-625-3335
E-mail: drsystems@dominator.com
www.dominator.com

DR Systems offers the Unity™ RIS/CVIS/PACS enterprise medical image and information management system for hospitals and imaging centers. The Unity platform encompasses the entire imaging workflow process in one unified system—from Web scheduling to registration, to PACS, reporting, tracking, peer review, management reporting, and regulatory compliance.



EagleEye Radiology, Inc.

Booth: 506
12100 Sunrise Valley Drive, Suite 290-B
Reston, VA 20191
Phone: 703-652-1200
E-mail: info@eerad.com
www.eerad.com

Incorporated in 2005 by a group of military-trained radiologists, EagleEye Radiology, Inc. is a premier, total radiology solutions provider. Our clients rely on us for seamless daytime, after-hours, onsite, and subspecialty coverage. We are committed to helping health care facilities capture, maintain, and grow their radiology service offerings.

COMMERCIAL EXHIBITORS



ELSEVIER

Elsevier-Mosby / Saunders

Booth: 415
1600 JFK Boulevard, Suite 1800
Philadelphia, PA 19103
Phone: 215-239-3490
Fax: 215-239-3494
www.elsevierhealth.com

Saunders, Mosby, Churchill Livingstone, Butterworth Heimemann, and Hanley-Belfus, premier worldwide health science publishing company, under the umbrella of Elsevier, Inc., presents our latest titles in Radiology. Visit and browse through our complete selection of publications including books, periodicals, and online solutions. Elsevier...building insights, breaking boundaries!



**Ethicon
Endo-Surgery**

PART OF THE JOHNSON & JOHNSON FAMILY OF COMPANIES

Ethicon Endo-Surgery, Inc.

Booth: 307
4545 Creek Road
Cincinnati, OH 45242
Phone: 513-337-7000
Toll Free: 1-800-USE-ENDO
www.eesedu.com

Ethicon Endo-Surgery, a Johnson & Johnson company, develops and markets advanced medical devices for minimally invasive and open surgical procedures, focusing on procedure-enabling devices for the interventional diagnosis and treatment of conditions in general and bariatric surgery, gastrointestinal health, gynecology and surgical oncology. More information at www.ethiconendo.com.



imagination at work

GE Healthcare

Booth: 301
Craig Small
Senior Brand Manager
101 Carnegie Center
Princeton, NJ 08540
Phone: 609-514-6379
E-mail: Craig.Small@ge.com
www.gehealthcare.com

GE is making a new commitment to health. Healthymagination will change the way we approach healthcare, with more than 100 innovations all focused on addressing three critical needs: lowering costs, touching more lives and improving quality.

HOLOGIC™

The Women's Health Company

Hologic, Inc.

Booth: 406
35 Crosby Drive
Bedford, MA 01730
Phone: 781-999-7300
E-mail: womenshealth@hologic.com
www.hologic.com

Visit Hologic to learn more about the industry's most sophisticated digital mammography system, Selenia® Dimensions®2D. The Selenia Dimensions 2D full-field digital mammography system offers a flexible platform that can be configured for 3D breast imaging when and if breast tomosynthesis is approved by the FDA. Learn more at www.hologic.com.

COMMERCIAL EXHIBITORS



iCRco, Inc.

Booth: 509
Seyhan Gulen
Marketing Director
2580 West 237th Street
Torrance, CA 90505
Phone: 310-921-9559
Fax: 310-921-2559
E-mail: sgulen@icrcompany.com
www.icrcompany.com

iCRco, Inc., Based in Torrance, CA, is an established, privately-held, global leader in providing innovative digital x-ray imaging solutions, including a complete suite of x-ray imaging hardware, PACS, imaging software and integrated solutions for the medical, chiropractic, dental, veterinary and non-destructive testing markets. These revolutionary products enable iCRco customers to experience the true low cost of ownership of digital x-ray imaging.



Lippincott Williams & Wilkins

Booth: 400
530 Walnut Street
Philadelphia, PA 19106
www.lww.com

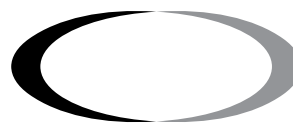Lippincott Williams & Wilkins publishes medical books, journals, and software.



McKesson Corp.

Booth: 407
1145 Sanctuary Parkway, Suite 200
Alpharetta, GA 30004
Phone: 866-217-4184
E-mail: radiologyinfo@mckesson.com
www.mckesson.com/radiologyservices

McKesson's Revenue Management Solutions, with the largest radiology client base, makes us uniquely qualified to take your financial performance to the next level. As experts in billing and practice management, McKesson can guide you through the complexities of reimbursement and help you capture more of what you earn.



MEDICAL DOCTOR
ASSOCIATES

THE QUALITY LEADER IN MEDICAL STAFFING

Medical Doctor Associates

Booth: 302
Niki Nichols—Vice President of Radiology
145 Technology Parkway, NW
Norcross, GA 30092
Toll Free: 800-780-3500 x 2476
www.mdainc.com

Medical Doctor Associates is the quality leader in healthcare staffing. MDA is the only multi-specialty locum tenens organization that offers Occurrence Form Insurance to doctors who contract with us. MDA pays competitive fees every two weeks and now offers direct deposit.



MEDRAD, Inc.

Booth: 502
One Medrad Drive
Indianola, PA 15051
Phone: 412-767-2400
Fax: 412-767-2596
www.medrad.com

MEDRAD, Inc. develops, markets and services medical devices used to diagnose and treat disease. Its product offerings include fluid injection systems for radiology and cardiology, endovascular devices for the safe treatment of cardiovascular disease, magnetic resonance-compatible accessories and equipment services. The company's world headquarters is near Pittsburgh, Pennsylvania, in the United States. MEDRAD is a business of Bayer Medical Care. More company information is available at www.medrad.com.

COMMERCIAL EXHIBITORS



Physicians Business Network

Booth: 505
David Gaston
Director of Business Development
10950 Grandview, Suite 200
Overland Park, Kansas 66210
Phone: 800-288-4901
Fax: 913-381-3454
www.pbnmed.com

Physicians Business Network (PBN), a proven leader in helping physicians optimize their practice's financial performance, specializes in billing, follow-up, contract negotiation, coding, practice audits, training, credentialing, accounting and consulting services. Clients rely on PBN to help them navigate complex payer reimbursement rules. Call 800-288-4901 for additional information. It's Proof... Not Promises.



SenorX

Booth: 206
3 Morgan
Irvine, CA 92618
Phone: 949-362-4800
Toll Free: 877-210-1300
Fax: 949-362-3519
E-mail: customerservice@senorx.com
www.senorx.com

SenorX (NASDAQ: SENO) develops, manufactures and sells minimally invasive medical devices used by breast care specialists for the diagnosis and treatment of breast cancer, including the advanced technology EnCor® vacuum-assisted breast biopsy system and Contura® Multi-Lumen Balloon (MLB) for APBI providing optimal treatment for more patients.
www.senorx.com, 877-210-1300, customerservice@senorx.com.



Sheridan Radiology Services

Booth: 500
1616 North Harrison Parkway, #200
Sunrise, FL 33323
Phone: 800-816-6791
E-mail: radiology@sheridanhealthcare.com
www.sheridanhealthcare.com

Established in 1953, Sheridan provides radiology practice management services, with 60 radiologists in 20 facilities and growing. We are a leader in cutting edge technology with expertise in all modalities. We offer daytime, weekend and after hour coverage; U.S. Based 24/7 teleradiology. Visit us or contact (800) 816-6791, radiology@sheridanhealthcare.com, www.sheridanhealthcare.com

SIEMENS

Siemens Healthcare

Booth: 306
51 Valley Stream Parkway
Malvern, PA 19355
Phone: 888-826-9702
www.siemens.com/healthcare

Siemens Healthcare is one of the world's largest suppliers in medical imaging, laboratory diagnostics, medical information technology and hearing aids. Siemens offers products and solutions for the entire range of patient care from a single source—from prevention and early detection to diagnosis, and on to treatment and aftercare.
www.siemens.com/healthcare

COMMERCIAL EXHIBITORS



Sunset Radiology, Inc.

Booth: 519
2301 Rosencrans Avenue, Suite 4150
El Segundo, CA 90245
Phone: 310-706-4440
Fax: 310-706-4441
www.sunsetradiology.com

Sunset Radiology, Inc.—Nighthawks— Teleradiology

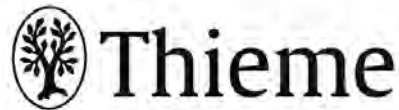
- Radiologist owned and operated & 100% USA Based
- Board certified, years of hospital Based experience
- Joint Commission accredited; secure, HIPAA compliant
- Fast turnaround; competitively priced; highly accurate
- Preliminary or final reads; coverage 24/7/365



TeraRecon, Inc.

Booth: 207
2955 Campus Drive, Suite 325
San Mateo, CA 94403
Phone: 650-372-1100
Fax: 650-372-1101
Web: www.terarecon.com

TeraRecon, Inc. is a leader in advanced image processing and 3D visualization techniques providing systems and solutions for medical and other visualization applications Based on its unique and patented image processing technologies.



Thieme Publishers

Booth: 511
333 Seventh Avenue
New York, NY 10001
Phone: 800-782-3488
Fax: 212-947-0108
www.thieme.com

Thieme is an award-winning international medical and science publisher serving health professionals and students for more than 100 years. Thieme promotes the latest advancements in clinical practice, publishes the latest research findings, advocates medical education and is known for the high quality and didactic nature of its books, journals, and electronic products.



Third Eye Teleradiology, Inc

Booth: 513
2800 Regatta Avenue
Miami Beach, FL 33140
Toll free: 877-225-3EYE (3393)
E-mail: Info@tetradiology.com
www.tetradiology.com

Third Eye Teleradiology, Inc ("TET"): Fellowship trained, academic radiologists delivering subspecialty specific diagnostic imaging reports and consultations. TET emphasizes client satisfaction with the highest quality service, easy implementation and the most advanced imaging techniques, including 3D and virtual.

We create customized coverage solutions, providing subspecialty daily, overflow and vacation coverage.

COMMERCIAL EXHIBITORS



TOSHIBA

Leading Innovation >>>

Toshiba America Medical Systems, Inc.

Booth: 514
2441 Michelle Drive
Tustin, CA 92780
Phone: 800-421-1968
www.medical.toshiba.com

An innovator in medical imaging technology, Toshiba America Medical Systems markets, sells, distributes and services diagnostic imaging systems throughout the U.S. Toshiba is committed to providing customers with the patient-focused technology and optimum system performance needed to succeed in today's healthcare marketplace.



COMPREHENSIVE SUB-SPECIALTY TELERADIOLOGY SERVICES

U.S. Radiology On-Call

Booth: 309
2461 Santa Monica Boulevard, Suite 108
Santa Monica, CA 90404
Phone: 866-487-7621
Fax: 310-388-3029
www.usroc.com

We are a fully US-Based Joint Commission accredited subspecialty teleradiology service providing the highest quality of 24/7/365 coverage available. We service all size imaging facilities from large level one trauma centers to solo rural practices nationwide. We will customize an affordable HL-7 compliant coverage solution for your practice with services including nighthawk, evening overflow, mammography, and final report coverage in all disciplines of radiology. Our service will allow you to reduce your overall expenses while continuing to provide the highest quality work to your referring physicians in the demanding and increasingly 24/7 medical environment of today.



Vital Images, Inc.

Booth: 503
5850 Opus Parkway, Suite 300
Minnetonka, MN 55343
Phone: 952-487-9500
www.vitalimages.com

Vital Images, headquartered in Minneapolis, is a leading provider of enterprise-wide advanced visualization software solutions. The company's technology gives radiologists, cardiologists, oncologists and other medical specialists' time-saving productivity and communications tools that can be accessed throughout the enterprise and via the Web for use in the day-to-day practice of medicine.



Whitaker Medical, LLC

Booth: 215
1200 Enclave Parkway, Suite 200
Houston, TX 77077
Toll free: 800-444-5628
Phone: 281-870-1000
Fax: 866-513-0183
www.whitakermedical.com

Our company provides staffing solutions to a large variety of healthcare organizations seeking locum tenens professionals in anesthesiology, radiology, pharmacy, primary care and all subspecialties. We also provide permanent and government contract positions in all medical specialties.

OFFICERS AND COMMITTEES



The background of the slide is a photograph of a tropical beach at sunset. A single palm tree stands on the right side, its silhouette dark against the bright, orange, and yellow sky. The ocean waves are visible in the foreground, and the horizon line is low. The overall mood is warm and serene.

THE ARRS THANKS ITS 2010 ANNUAL MEETING FACULTY AND VOLUNTEERS

**The Success of
the Meeting
is the Result of
Your Efforts!**

OFFICERS AND COMMITTEES



OFFICERS 2009-2010

President

Ella A. Kazerooni, MD2009-2010

President-Elect

Joseph K.T. Lee, MD2009-2010

Vice President

James A. Brink, MD2009-2010

Secretary

Melissa Rosado de Christenson, MD2008-2013

Treasurer

Howard P. Forman, MD2005-2010

EXECUTIVE COUNCIL 2009-2010

Ella A. Kazerooni, MD, President2009-2010
 Joseph K.T. Lee, MD, President-Elect2009-2010
 James A. Brink, MD, Vice-President2009-2010
 Melissa Rosado de Christenson, MD, Secretary2008-2013
 Howard P. Forman, MD, Treasurer2005-2010
 John K. Crowe, MD, 2008-2009 Past President2009-2010
 Philip Costello, MD, Chair, Corporate Relations Committee.2009-2014
 Norman J. Beauchamp, MD, Chair, Education/CME Committee .2009-2010
 Howard P. Forman, MD, Chair, Finance and Budget Committee .2005-2010
 Mauricio Castillo, MD, Chair, Instructional Courses Committee. .2008-2013
 Bernard F. King, MD, Chair, Membership Committee2007-2012
 Jonathan S. Lewin, MD, Chair, Program Committee.2006-2011
 Charles E. Kahn, Jr., MD, Chair, Publication Committee.2006-2011
 Lawrence P. Davis, MD, Chair, ACR Commission on Education. .2009-2010
 John A. Patti, MD, Vice-Chair, ACR Board of Chancellors2009-2010
 James H. Thrall, MD, Chairman, ACR Board of Chancellors. . . .2009-2010
 John K. Crowe, MD, Chair, The Roentgen Fund Board of Trustees2009-2010

COMMITTEES

Corporate Relations Committee

Norman J. Beauchamp, MD.2008-2011
 Mauricio Castillo, MD2008-2013
 Anton N. Hasso, MD.2008-2011
 Jonathan S. Lewin, MD2006-2011
 Frank J. Rybicki, MD, PhD.2008-2011
 Philip Costello, MD, Chair.2009-2014

Education/CME Committee

Thomas H. Berquist, MD2008-2011
 Mauricio Castillo, MD2008-2013
 Elliot K. Fishman, MD2007-2010
 Eugene D. Frank, MA, RTR, FASRT2008-2011
 Charles E. Kahn, Jr., MD.2006-2011
 Joseph K.T. Lee, MD2008-2009
 Jonathan S. Lewin, MD2006-2011
 Angelisa M. Paladin, MD2009-2012

Gary J. Whitman, MD2009-2012
 Beverly P. Wood, MD2009-2012
 Jannette Collins, MD, Associate Chair2007-2010
 Norman J. Beauchamp, MD, Chair2009-2010

Executive Committee of the Executive Council

James A. Brink, MD2009-2010
 Howard P. Forman, MD2009-2010
 Joseph K.T. Lee, MD2009-2010
 Melissa Rosado de Christenson, MD2009-2010
 Ella A. Kazerooni, MD, Chair2009-2010

Finance and Budget Committee

James A. Brink, MD2009-2010
 Ella A. Kazerooni, MD2009-2010
 Joseph K.T. Lee, MD2009-2010
 Melissa Rosado de Christenson, MD2009-2010
 Howard P. Forman, MD, Chair2005-2010

Gold Medal Nominating Committee

John K. Crowe, MD2009-2010
 Melissa Rosado de Christenson, MD2009-2010
 Robert J. Stanley, MD2009-2010
 Joseph K.T. Lee, MD, Chair2009-2010

Instructional Courses Committee

Teresita L. Angtuaco, MD2008-2012
 Laura W. Bancroft, MD2008-2011
 Jonathan W. Berlin, MD2009-2010
 Jeremy J. Erasmus, MD2008-2012
 Brian S. Funaki, MD2008-2012
 Dianne Georgian-Smith, MD2008-2010
 Richard B. Gunderman, MD, PhD.2009-2010
 Michelle A. Michel, MD2008-2010
 Janet R. Reid, MD2008-2010
 Jorge A. Soto, MD2009-2012
 Charles S. White, MD2008-2010
 Benjamin Yeh, MD.2008-2010
 Don C. Yoo, MD2008-2010
 Joseph Yu, MD.2008-2010
 Marilyn J. Siegel, MD, Associate Chair2008-2013
 Mauricio Castillo, MD, Chair2008-2013

Membership Committee

Mostafa Atri, MD2008-2011
 Eugene D. Frank, MA, RTR, FASRT2007-2010
 Justin A. Frederick, MD2007-2010
 Jorge A. Soto, MD2008-2011
 Hans Van Heesewijk, MD2005-2010
 Darcy Wolfman, MD.2008-2011
 Bernard F. King, MD, Chair2007-2012

Nominating Committee

James A. Brink, MD2009-2010
 Joseph K.T. Lee, MD2009-2010
 John K. Crowe, MD, Chair.2009-2010

OFFICERS AND COMMITTEES



Program Committee

Deborah A. Baumgarten, MD, MPH	.2008-2011
Norman J. Beauchamp, MD	.2009-2010
Thomas H. Berquist, MD	.2008-2011
James A. Brink, MD	.2009-2010
Mauricio Castillo, MD	.2008-2013
Valerie P. Jackson, MD	.2009-2012
Joseph K.T. Lee, MD	.2008-2010
Jessica W.T. Leung, MD	.2007-2010
Kenneth C. Wang, MD, PhD	.2007-2010
Elmar M. Merkle, MD, Associate Chair	.2009-2012
Jonathan S. Lewin, MD, Chair	.2006-2011

Publication Committee

Jonathan W. Berlin, MD	.2006-2011
Ruth C. Carlos, MD	.2009-2014
Jonathan H. Chung, MD	.2009-2010
Mannudeep K. Kalra, MD	.2008-2013
Scott A. Koss, MD	.2006-2010
Charles E. Kahn, Jr., MD, Chair	.2006-2011

The Roentgen Fund Board of Trustees

James A. Brink, MD	.2009-2012
M. Paul Capp, MD	.2008-2011
William J. Casarella, MD	.2008-2011
Ella A. Kazerooni, MD	.2007-2010
Joseph K.T. Lee, MD	.2008-2011
Neil H. Messinger, MD	.2008-2011
John P. Tampas, MD	.2007-2010
Jerome F. Wiot	.2008-2011
John K. Crowe, MD, Chair	.2009-2010

Editor-In-Chief

Thomas H. Berquist, MD, (<i>American Journal of Roentgenology</i>)	.2008-2013
--	------------

Historian

Raymond A. Gagliardi, MD	.2005-2010
--------------------------	------------

SUBCOMMITTEES

CME Review Subcommittee

Michelle S. Barr, MD	.2007-2010
Sanjeev Bhalla, MD	.2007-2010
David A. Bluemke, MD, PhD	.2008-2011
Christine B. Chung, MD	.2007-2010
Vikram Dogra, MD	.2007-2010
Thomas R. Goodman, MD	.2008-2011
Howard J. Harvin, MD	.2007-2010
Hyun S. Kim, MD	.2007-2010
Mark A. Kliewer, MD	.2008-2011
Mark J. Kransdorf, MD	.2008-2011
Huong T. Le-Petross, MD	.2008-2011
Jessica W.T. Leung, MD	.2008-2011
Laurie A. Loevner, MD	.2008-2011
David C. Madoff, MD	.2007-2010
Alexis V. Nees, MD	.2008-2011
Harriet J. Paltiel, MD	.2007-2010
Mark S. Parker, MD	.2007-2010
Mahesh R. Patel, MD	.2007-2010

Smita Patel, MD	.2007-2010
Janet R. Reid, MD	.2007-2010
Michael L. Richardson, MD	.2007-2010
Melissa Rosado de Christenson, MD	.2007-2010
Frank J. Rybicki, MD, PhD	.2007-2010
Carl M. Sandler, MD	.2009-2012
Stuart G. Silverman, MD	.2008-2011
Raymond Thornton, MD	.2008-2011
Don C. Yoo, MD	.2007-2010
Gary J. Whitman, MD, Chair	.2008-2011

CME Outcomes Subcommittee

James C. Anderson, MD	.2007-2011
Angelisa M. Paladin, MD	.2007-2011
Michael L. Richardson, MD	.2008-2011
Kitt Shaffer, MD, PhD	.2007-2011
Rathan Subramaniam, MD	.2009-2012
Beverly P. Wood, MD, Chair	.2009-2014

Education Evaluation Subcommittee

Jocelyn D. Chertoff, MD, Chair	.2010-2013
--------------------------------	------------

Abdominal

Harpreet K. Pannu, MD	.2007-2010
William J. Weadock, MD	.2007-2010

Body Imaging

Mark C. De Lano, MD	.2008-2011
Howard J. Harvin, MD	.2008-2011
Ania Kielar, MD	.2008-2011
Charles R. Luttenton, MD	.2008-2011

Breast

Sandra R. Bates, MD	.2008-2011
Alexis V. Nees, MD	.2008-2011
Kitt Shaffer, MD, PhD	.2007-2010
Tanya W. Stephens, MD	.2008-2011

Cardiovascular

Ronald L. Korn, MD	.2008-2011
Kitt Shaffer, MD, PhD	.2007-2010

Chest

Smita Patel, MD	.2008-2011
-----------------	------------

Emergency

Estelle Cooke-Sampson, MD	.2007-2010
Joel Gross, MD	.2007-2010
Robert A. Novelline, MD	.2007-2010

GI/GU

Abraham Dachman, MD	.2008-2011
N. Reed Dunnick, MD	.2007-2010

Medical/Legal Risk Management

Stephen M. Brown, MD	.2008-2011
Annemarie Relyea-Chew, JD, MS, MAT	.2008-2011
Kitt Shaffer, MD, PhD	.2007-2010

OFFICERS AND COMMITTEES



Musculoskeletal

Thomas H. Berquist, MD2008-2011
Gandikota Girish, MBBS, FRCS, FRCR2008-2011
Jon A. Jacobson, MD2007-2010
Ashok K. Nath, MD2007-2010
Catherine C. Roberts, MD2009-2012
Joseph Yu, MD2008-2011

Neuroradiology

Mark E. Mullins, MD2007-2010
Vaishali V. Phalke, MD2008-2011

Nuclear Medicine

Philip O. Alderson, MD2007-2010
Antoine Leblond, MD2008-2011

Pediatrics

Edward Y. Lee, MD, MPH2008-2011
Raymond W. Sze, MD2008-2011

Ultrasound

Manjiri Dighe, MD2008-2011
Barbara S. Hertzberg, MD2008-2011

Maintenance of Certification Subcommittee

Teresita L. Angtuaco, MD2008-2011
Stephen R. Baker, MD2007-2010
Stephen Chan, MD2008-2011
Felix S. Chew, MD2007-2010
Brian S. Funaki, MD2007-2010
Jeffrey P. Kanne, MD2009-2012
Aine Kelly, MD2008-2011
Katherine A. Klein, MD2008-2011
Darlene Metter, MD2008-2011
Amit Pandya, MD, RDMS, RVT, RDCS2009-2012
Karen G. Ordovas, MD2009-2012
Sidney P. Regalado, MD2008-2011
Frank J. Rybicki, MD, PhD2010-2013
Pamela W. Schaefer, MD2008-2011
Michael, J. Tuite, MD2007-2010
Beverly P. Wood, MD2007-2010
Jannette Collins, MD, Chair2007-2010

Regional Courses Subcommittee

James A. Brink, MD2009-2012
Michael P. Federle, MD2009-2012
Clyde A. Helms, MD2009-2012
Karen M. Horton, MD2009-2012
R. Brooke Jeffrey, Jr., MD2009-2012
Robert A. Novelline, MD2009-2012
Jeffrey C. Weinreb, MD2009-2012
Elliot K. Fishman, MD, Chair2009-2012

Research Subcommittee

Elizabeth S. Burnside, MD2005-2010
Edwin F. Donnelly, MD2009-2012
Jonathan Kruskal, MD, PhD2005-2010
Edward Y. Lee, MD, PhD2009-2012

Nabile M. Safdar, MD2009-2012
Pina C. Sanelli, MD2009-2012
Stefan Tigges, MD2005-2010
Ruth C. Carlos, MD, Chair2009-2012

Review Course Subcommittee

Gerald F. Abbott, MD2008-2011
James C. Anderson, MD2008-2010
Sanjeev Bhalla, MD2009-2011
Donna G. Blankenbaker, MD2009-2012
Barbara S. Hertzberg, MD2009-2012
Lisa H. Lowe, MD2008-2010
Michelle A. Michel, MD2008-2010
Christine M. Peterson, MD2009-2012
Lonie R. Salkowski, MD2008-2011
Cynthia Santillan, MD2009-2012
Don C. Yoo, MD2008-2010
Steven M. Zangan, MD2009-2012
Deborah A. Baumgarten, MD, MPH Chair2009-2012

Scientific Program Subcommittee

Jonathan S. Lewin, MD, Chair2006-2011
--	------------

Breast

Amy S. Campbell, MD2009-2012
Christopher E. Comstock, MD2009-2012
Valerie P. Jackson, MD2009-2012
Alexis V. Nees, MD2009-2012
Gillian Newstead, MD2009-2012
Brandi T. Nicholson, MD2007-2010
Ruby E. Obaldo-Meierotto, MD2009-2012
Stephanie Patterson, MD2008-2011
Dana R. Rausch, MD2009-2012
Lonie R. Salkowski, MD2008-2011
Tanya W. Stephens, MD2008-2011
Jessica W.T. Leung, MD, Chair2007-2010

Cardiopulmonary

Suhny Abbara, MD2009-2012
Michael K. Atalay, MD, PhD2009-2012
Katherine Birchard, MD2008-2011
Daniel T. Boll, MD2009-2012
Vincent B. Ho, MD, MBA2009-2012
Jill E. Jacobs, MD2009-2012
Saurabh Jha, MBBS2009-2012
Aine Kelly, MD2009-2012
Michael T. Lu, AB2009-2012
Rachna Madan, MD2009-2012
Santiago Martinez-Jimenez, MD2007-2010
Reginald F. Munden, MD2009-2012
Mark S. Parker, MD2007-2010
Nova C. Patel, MD2009-2012
U. Joseph Schoepf, MD2009-2012
Baskaran Sundaram, MD2007-2010
Pamela K. Woodard, MD2009-2012
Smita Patel, MD, Chair2007-2010

OFFICERS AND COMMITTEES



Efficacy/Education/Administration

Hani H. Abujudeh, MD, MBA2008-2011
Rajan Agarwal, MD, MBA2009-2012
Vikram Dogra, MD2008-2011
Donna Magid, MD2009-2012
John Eng, MD, Chair2008-2011

General Radiology/Emergency Radiology

Michael A. Bruno, MD2009-2012
Jenny K. Hoang, MBBS, FRANZCR2009-2013
Thorsten R. Fleiter, MD2007-2010
Diego B. Nunez, Jr., MD2009-2012
Amit Pandya, MD, RDMS, RVT, RDCS2007-2010
Stefan Puig, MD2009-2012
Tina S. Sanghvi, MD2009-2012
Katherine A. Klein, MD, Chair2007-2010

GI/Liver/Biliary/Pancreas

Dina F. Caroline, MD2007-2010
Abraham Dachman, MD2007-2010
Louis Hinshaw, MD2008-2011
Jennifer Y. Hsu, MD2009-2012
Tracy A. Jaffee, MD2009-2012
Ihab R. Kamel, MD, PhD2008-2011
Douglas S. Katz, MD2009-2012
Orpheus Kolokythas, MD2007-2010
Wendy B. Landman, MD2009-2012
Elmar M. Merkle, MD2009-2012
Dean Nakamoto, MD2009-2012
Maryam Rezvani, MD2009-2012
Cynthia Santillan, MD2007-2010
Claude B. Sirlin, MD2009-2012
Rafel Tappouni, MD2008-2011
Sharlene A. Teefey, MD2009-2012
Courtney Woodfield, MD2008-2011
Fergus V. Coakley, MB, Bch, Chair2007-2010

GU/Ob/Gyn

Robert M. Abbott, MD2008-2011
Kelli Jo Andresen, MD2008-2011
David Grand, MD2009-2012
Matthew S. Hartman, MD2008-2011
Akira Kawashima, MD2009-2012
Christine O. Menias, MD2008-2011
Aytekin Oto, MD2009-2012
Srinivasa R. Prasad, MD2008-2011
Maheen Rajput, MD2009-2012
Parvati Ramchandani, MD2008-2011
Erick M. Remer, MD2009-2012
Miriam Romero, MD2009-2012
Elizabeth A. Sadowski, MD2008-2011
Mitchell E. Tublin, MD2009-2012
Paula Yeghiayan, MD2009-2012

Musculoskeletal

Donna G. Blankenbaker, MD2007-2010
Christine B. Chung, MD2009-2012
Mary K. Drake, MD2009-2012
Amilcare Gentili, MD2009-2012
Stephen F. Hatem, MD2008-2011
Viviane Khoury, MD, FRCPC2009-2012
William B. Morrison, MD2007-2010
John M. Payan, MD2009-2012
Joshua M. Polster, MD2009-2012
Thomas L. Pope, Jr., MD2007-2010
Mark R. Robbin, MD2009-2012
Catherine C. Roberts, MD2009-2012
Brian J. Sabb, DO2009-2012
Ken L. Schreiber, MD, PhD2007-2010
Stacy E. Smith, MD2007-2010
Hilary R. Umans, MD2008-2011
James N. Wise, MD2009-2012
Laura M. Fayad, MD, Chair2007-2010

Neuro/Head and Neck

Kristine Blackham, MD2009-2012
Ari M. Blitz, MD2009-2012
Dheeraj Gandhi, MD2009-2012
Christine M. Glastonbury, MD2007-2010
Sung E. Logerfo, MD2009-2012
Michelle A. Michel, MD2009-2012
Mark E. Mullins, MD2009-2012
Dan T.D. Nguyen, MD2007-2010
Matthew F. Omojola, MB, BS2009-2012
Puneet Pawha, MD2008-2011
Colin Shiu-On Poon, MD, PhD2009-2012
Karen L. Salzman, MD2009-2012
Pamela W. Schaefer, MD2009-2012
Rathan Subramaniam, MD2009-2012
Achala A. Vagal, MD2009-2012
Ay-Ming Wang, MD2009-2012
Elizabeth Yutan, MD2008-2011
Christopher D. Lascola, MD, PhD, Chair2007-2010

Nuclear Medicine/Molecular Imaging

Steven Yoon-Ho Cho, MD2009-2012
Indu Doddamane, MD2009-2012
Ghassen El-Haddad, MD2009-2012
Heather A. Jacene, MD2009-2012
Robert C. Murphy, MD, PhD2009-2012
Don C. Yoo, MD2009-2012
Terence Z. Wong, MD, PhD, Chair2007-2010

PACS/Computers

Krishna Juluru, MD2009-2012
Daniel Rubin, MD, MS2009-2012
William J. Weadock, MD2008-2011
Richard Wiggins, MD2009-2012
Bradford J. Richmond, MD, Chair2007-2010

OFFICERS AND COMMITTEES



Pediatrics

Ana M. Gaca, MD2007-2010
Boaz Karmazyn, MD.2008-2011
Edward Y. Lee, MD2009-2012
Sudha P. Singh, MBBS.2007-2010
Aylin Tekes, MD2009-2012
Thierry A.G.M. Huisman, MD, Chair2008-2011

Vascular/Interventional

Aravind Arepally, MD2007-2010
Alexander Ding, MD, MS2009-2012
Martha-Gracia Knuttinen, MD, PhD2008-2011
Jonathan Lorenz, MD2009-2012
David C. Madoff, MD2009-2012
Uei Pua, MBBS.2009-2012
Charles E. Ray, Jr., MD2009-2012
Anthony Ryan, MB, ChB.2009-2012
Charles Owens, MD, Chair2007-2010

AD HOC COMMITTEES

GoldMiner Advisory

Michael A. Bruno, MD.2008-2010
Susanna I. Lee, MD2008-2010
Michael L. Richardson, MD2008-2011
Daniel Rubin, MD, MS.2008-2011
Charles E. Kahn, Jr., MD, Chair2008-2011

International Relations

Norman J. Beauchamp, MD.2007-2010
Mauricio Castillo, MD2007-2010
John K. Crowe, MD2007-2010
Charles E. Kahn, Jr., MD.2007-2010
Ella A. Kazerooni, MD.2007-2010
Bernard F. King, MD.2007-2010
James A. Brink, MD, Chair2007-2010

Senior Radiologist Section

B. G. Brogdon, MD2008-2011
M. Paul Capp, MD.2006-2011
William J. Casarella, MD2007-2010
John M. Dennis, MD.2006-2011
Raymond A. Gagliardi, MD2006-2011
Ted F. Leigh, MD.2006-2011
Andrew K. Poznanski, MD2007-2010
Lee F. Rogers, MD2007-2010
Kay H. Vydareny, MD2008-2011
Jerome F. Wiot, MD2006-2011
John P. Tampas, MD, Chair2006-2011

REPRESENTATIVES TO OTHER ORGANIZATIONS

Academy of Radiology Research

Ella A. Kazerooni, MD2008-2011
Joseph K.T. Lee, MD.2008-2011

American Board of Radiology

Valerie P. Jackson, MD.2005-2010
Matthew Mauro, MD2006-2010
Janet L. Strife, MD2007-2010

American College of Radiology Board of Chancellors

Jonathan S. Lewin, MD2008-2011
---------------------------------	------------

American College of Radiology Council

Anton N. Hasso, MD, Councilor.2008-2011
Philip Cascade, MD, Alternate Councilor2009-2011

American College of Radiology Intersociety Committee

Joseph K.T. Lee, MD2009-2010
Melissa Rosado de Christenson, MD2009-2010

American College of Radiology Foundation International Outreach

Mauricio Castillo.2010-2014
----------------------------	------------

American Medical Association—CPT Advisory Committee

Mark D. Alson, MD2007-2010
-----------------------------	------------

American Medical Association House of Delegates

William W. Horsley, MD Alternate Delegate2009-2011
Robert D. Steele, Jr., MD, Delegate2009-2011

Conjoint Committee for Radiology at the AFIP

Melissa Rosado de Christenson, MD2008-2011
---	------------

National Council for Radiation Protection and Measurements

James A. Brink, MD2008-2011
------------------------------	------------

GE Healthcare

The best ideas are yours.

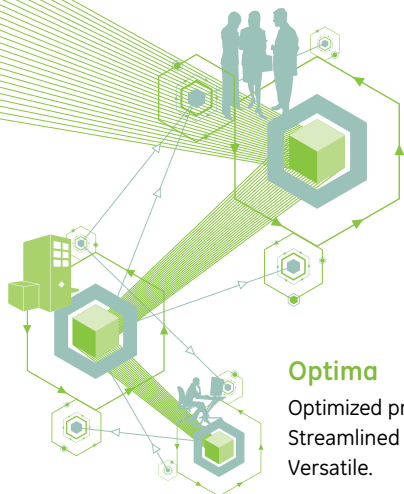
You know what you need better than anyone. Guided by your voice, we're making it easier for you to find the right technology and care for your patients. That's why we've introduced three platforms to help you find the solution you need: Optima™, Brivo™ and Discovery™.

So keep sharing your ideas — and we'll keep listening.
Healthcare Re-imagined.

Continue the conversation at www.gehealthcare.com/you

Discovery

Breakthrough technology.
Advanced applications.
Competitive edge.



Optima

Optimized productivity.
Streamlined workflow.
Versatile.

Brivo

Essential functionality.
Intuitive design.
Operational ease.



imagination at work