

Provided for non-commercial research and education use.  
Not for reproduction, distribution or commercial use.



This article appeared in a journal published by Elsevier. The attached copy is furnished to the author for internal non-commercial research and education use, including for instruction at the authors institution and sharing with colleagues.

Other uses, including reproduction and distribution, or selling or licensing copies, or posting to personal, institutional or third party websites are prohibited.

In most cases authors are permitted to post their version of the article (e.g. in Word or Tex form) to their personal website or institutional repository. Authors requiring further information regarding Elsevier's archiving and manuscript policies are encouraged to visit:

<http://www.elsevier.com/authorsrights>



From the Society for Vascular Surgery

# Surgical conversion with graft salvage as a definitive treatment for persistent type II endoleak causing sac enlargement

Nicola Mangialardi, MD,<sup>a</sup> Sonia Ronchey, MD, PhD,<sup>a</sup> Matteo Orrico, MD,<sup>a,b</sup> Eugenia Serrao, MD,<sup>a</sup> Vittorio Alberti, MD,<sup>a</sup> Stefano Fazzini, MD, PhD,<sup>a</sup> Felice Pecoraro, MD, PhD,<sup>c</sup> and Carlo Setacci, MD,<sup>b</sup>  
*Rome, Siena, and Palermo, Italy*

**Objective:** The goal of this study was to present open surgical conversion with graft salvage or “semiconversion” as a definitive and safe treatment for untreatable and persistent type II endoleaks causing sac enlargement after endovascular aneurysm repair.

**Methods:** Between January 2001 and December 2014, 25 of 1623 endovascular aortic repair (EVAR) patients were selected as candidates for open semiconversion. The indication was persistent type II endoleak in 13 patients (12 of whom received previous attempts of embolization), type I and II endoleak in 2 patients, and sac growth without imaging evidence of endoleak in the other 10. After the infrarenal aorta was prepared (via a retroperitoneal access, whenever possible), the technique consisted of performing a banding of the neck with Teflon (DuPont, Wilmington, Del), a sacotomy to remove the thrombus or the hygroma, or both, and then suturing all of the feeding vessels that were found. Proximal and distal fenestrations were performed to avoid sac repressurization.

**Results:** The semiconversion was performed after a mean of 74 months after the initial EVAR. The mean aneurysm size at the time of the EVAR was 6.0 cm (range, 5.0-9.5 cm), and the mean aneurysm size at the time of the semiconversion was 7.7 cm (range, 5.5-11.5 cm). The overall aneurysm size increase was 38%, and the average growth rate was 8.2% per year. One patient had a stable aneurysm size but was treated because of an emergency condition. Technical success was 100%, with resolution of the endoleak and no perioperative deaths. Four cardiac deaths were registered at 12, 26, 30, and 60 months (mean follow-up, 42 months; range, 1-80 months).

**Conclusions:** Graft salvage appears to be a valid option compared with open repair when considering treatment of persistent type II endoleak. This case series shows that semiconversion is a safe and effective treatment for otherwise untreatable type II endoleak. (J Vasc Surg 2015;62:1437-41.)

As endovascular aortic repair (EVAR) has been introduced, a decreasing rate of total aneurysm-related deaths has been reported, with EVAR becoming more and more adopted in comparison to open repair.<sup>1,2</sup> Some concerns remain regarding the durability of the materials,<sup>3</sup> because the rate of reintervention reported in literature reaches 35%.<sup>4-6</sup> Despite this, within 5 years, the percentage of patients with abdominal aortic aneurysm undergoing EVAR in the United States increased from 39% to 72%, and the

number of patients undergoing open repair declined dramatically.<sup>7,8</sup> Any type of endoleak accounts for 83% of the indications for reintervention. Furthermore, 65% of reinterventions are caused by persistent type II endoleak,<sup>8</sup> which is one of the most frequent complications of EVAR, with an incidence of 10% to 30%.<sup>1-3</sup>

However, given the consistent percentage of stable or regressive type II endoleak, the need for treatment remains controversial.<sup>4,6,9</sup> According to the European Collaborators on Stent-Graft Techniques for Abdominal Aortic Aneurysm Repair (EUROSTAR) database, most type II endoleaks will thrombose spontaneously and have a benign course.<sup>8</sup> Treatment is considered only for large, high-flow endoleaks or in case of aneurysmal growth.<sup>7</sup> The first step is usually embolization, which can be performed via several access points and will cause the resolution of 80% of the endoleaks. Laparoscopic ligation of the feeding vessels has also been described.<sup>10,11</sup> When the endoleak persists and the sac enlarges, despite these procedures, surgical conversion is advised.<sup>12</sup> Nevertheless, complete graft removal carries a high mortality risk.<sup>13</sup> A less aggressive option is surgical conversion with endograft salvage. This technique was first reported by Hinchliffe et al<sup>14</sup> in 2002, and has since been sporadically reported in case reports and small series.<sup>15,16</sup>

From the Vascular Surgery Department, San Filippo Neri Hospital, Rome<sup>a</sup>; the Vascular Surgery Department, Policlinico Santa Maria alle Scotte, Siena<sup>b</sup>; and the Vascular Surgery Unit, AOUP “P. Giaccone,” University of Palermo, Palermo.<sup>c</sup>

Author conflict of interest: none.

Presented at the International Fast Talk at the 2015 Vascular Annual Meeting of the Society for Vascular Surgery, Chicago, Ill, June 17-20, 2015.

Correspondence: Matteo Orrico, MD, Vascular Surgery Department, San Filippo Neri Hospital, Via Martinotti 20, 00135 Rome, Italy (e-mail: [dr.orrico.matteo@gmail.com](mailto:dr.orrico.matteo@gmail.com)).

The editors and reviewers of this article have no relevant financial relationships to disclose per the JVS policy that requires reviewers to decline review of any manuscript for which they may have a conflict of interest.

0741-5214

Copyright © 2015 by the Society for Vascular Surgery. Published by Elsevier Inc.

<http://dx.doi.org/10.1016/j.jvs.2015.07.075>

The aim of this study was to describe the open conversion with graft salvage technique, or “semiconversion,” and to present the mid- and long-term results of our 25 cases.

## METHODS

This study conforms with the Declaration of Helsinki. Informed consent was collected from every patient.

**Patient selection.** Between January 2001 and January 2015, 1623 EVAR procedures were performed at our institution. Data were prospectively collected in a database and retrospectively reviewed. The follow-up method after EVAR consisted of serial duplex ultrasound (DUS) imaging, abdominal X-ray imaging, and routine physical examinations at 1, 3, 6, and 12 months and yearly thereafter. A contrast computed tomography (CT) scan was performed whenever there was evidence of an endoleak or in case of aneurysmal sac increase at the DUS examinations and whenever a patient presented with symptoms that could be related to the aneurysm. If sac growth was detected, than the follow-up was intensified by performing a DUS examination every 6 months, accompanied by contrast CT scan examination at the first 6-month control and whenever evidence showed further increasing diameter.

The resolution of the type II endoleak was defined by its disappearance at the DUS or, in cases of prior sac increase or treated patients, or both, at the CT scan control. CT scans were retrospectively reviewed, and measurements were done twice by the principal investigator and once by another observer to ensure acceptable intraobserver and interobserver variability.

The selection of the patients suitable for semiconversion is summarized in Fig 1. We registered a 13% incidence of persistent at type II endoleak at 1 year. Of those, 17% (2% of the total) were accompanied by aneurysmal sac growth with a maximum diameter >5 cm and were treated by our group by embolizations through several access points: 35 transarterial, 12 translumb, and 7 transcaval. These were assessed every 6 months thereafter with contrast CTs. Two or more procedures were performed in 15 patients. Of the persistent and growing type II endoleaks, 28 (78%) were solved  $\leq$ 1 year by endovascular means. However, eight persisted >1 year after the diagnosis of type II endoleak, showing aortic growth, and underwent semiconversion. Semiconversion was also performed in four patients with type II endoleaks who had undergone endovascular embolization attempts in other centers that had failed.

A patient with a stable type II endoleak was also treated by semiconversion when he presented at our emergency department, after 85 months of being lost at follow-up, with abdominal pain and CT signs of an aortoenteric fistula. We treated this patient by semiconversion because he was considered too fragile for a more aggressive removal of the graft. He was 80 years old and with severe chronic obstructive pulmonary disease and coronary artery disease. A surgical repair of the fistula (débridement and primary closure) and semiconversion were concurrently performed by multidisciplinary surgical team.

Two patients with associated type I and II endoleaks were also treated by semiconversion. Other 10 patients underwent semiconversion because of sac enlargement, without any evidence of endoleak on the imaging. These last 13 patients did not undergo any kind of endovascular treatment.

**Technique.** At the beginning of our experience, we performed the intervention with a median laparotomy, but then, from December 2007, we preferred, when feasible, a less aggressive standard retroperitoneal approach through the 11th intercostal space, without rib resection or reflection of the left kidney, so that 12 semiconversions were performed via a standard retroperitoneal access.

Once the infrarenal aorta was prepared, we performed preventive banding and reshaping of the neck with a Teflon (DuPont, Wilmington, Del) band and consolidated the graft to the aortic neck with four or five stitches binding together the Teflon, the aortic wall, and the endograft. The aim of banding and suturing was to prevent neck evolution, graft migration, and loss of sealing that potentially could come from traction applied during the intervention.

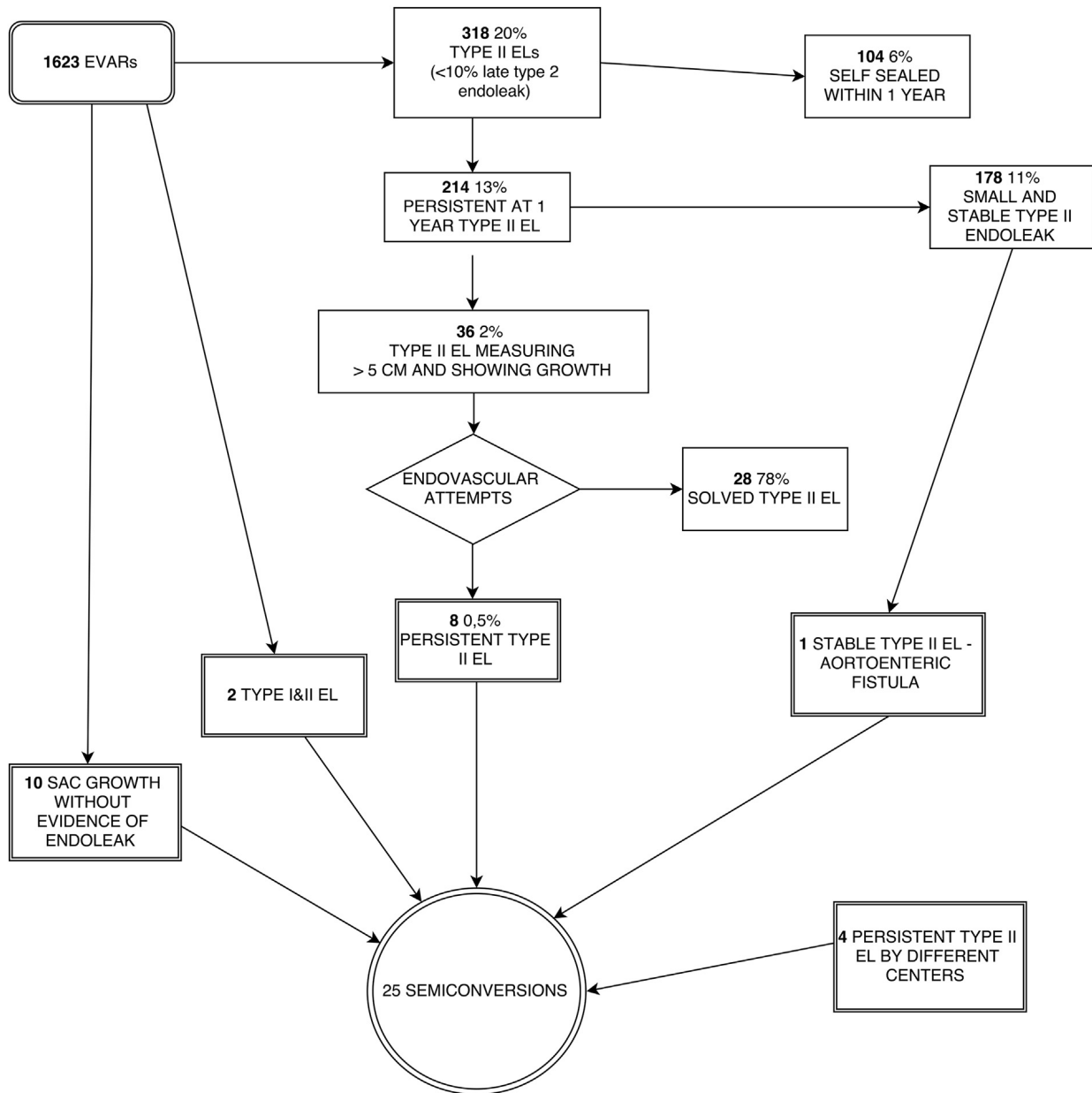
This step requires a minimal mobilization of the neck, because we gain the posterior space by digitoclasy. The Teflon banding of the neck is in our daily open repair practice. Despite the periaortic inflammation, this step was always relatively easy, probably because in our experience, the neck was always not significantly involved in the inflammation process. After the proximal neck was secured, the sac was opened longitudinally, and the thrombus or hygromas, or both, was removed (Fig 2). We then sutured all of the identified feeding vessels that were found and also in instances of sac growth without imaging evidence of type II endoleak. The sac was finally sutured leaving some fenestrations to avoid repressurization with the consequent risk of expansion and rupture. We always put a drain in the sac and another in the retroperitoneal space to drain the chyle coming from the inflamed periaortic tissue and for early detection of a secondary hemorrhage. The drains are kept in place from 1 to 3 days and until only traces of chyle are present.

We monitored the resolution of the leak by the same algorithm used to follow-up EVAR patients plus a contrast CT scan control at 30 days after the semiconversion.

## RESULTS

We treated 25 patients by partial conversion. The mean age was 76.1 years. Associated comorbidities included hypertension in 21 patients (84%), diabetes mellitus in 6 (24%), chronic obstructive pulmonary disease in 5 (20%), coronary artery disease in 11 (44%), chronic renal failure in 6 (24%), and dyslipidemia in 7 (28%). According to the American Society of Anesthesiologists (ASA) Physical Status Classification, 17 patients were at ASA 3, 3 were at ASA 2, and 5 were at ASA 4. The ASA classification is reported as stated at the time of the semiconversion.

The stent grafts originally implanted were Excluder (W. L. Gore and Associates, Flagstaff Ariz) in 17 patients (68%), Zenith (Cook Inc, Bloomington, Ind) in 3 (12%),



**Fig 1.** Flow chart shows the selection of the population eligible for semiconversion. *EL*, Endoleak; *EVAR*, endovascular aortic repair.

Endurant (Medtronic, Sunnyvale, Calif.) in 1 (4%), Talent (Medtronic) in 2 (8%) and Vanguard (Boston Scientific/Scimed, Natick, Mass) in 2 (8%).

The procedure was done at an average of 73.52 months (range 13-120 months) after the initial EVAR. The mean aneurysm size at the time of EVAR was 5.8 cm (range, 5.0-9.5 cm), and the mean aneurysm size at the time of semiconversion was 7.7 cm (range, 5.5-11.5 cm).

Only the patient with the aortoenteric fistula had stable aneurysm size (80 mm) after 85 months of follow-up. He did not receive the preventive banding of the infrarenal neck because of the high risk of infection of the Teflon felt.

The overall medium aneurysm size increase was of 38%, and 39% if not excluding the patient with stable aneurysm size. The mean rate of increase was 8.2% per year, but this was not constant. A comparison of the 10 patients with sac growth, without imaging evidence of type II endoleak, showed a trend of more growth, faster, and over a similar time period than the 13 type II endoleaks we observed. Of the 13 evident type II endoleaks, only the patient with the aortoenteric fistula did not undergo an endovascular attempt due to his clinical condition. The 10 patients with sac growth without imaging evidence of type II endoleak and the two patients with associated type I and II

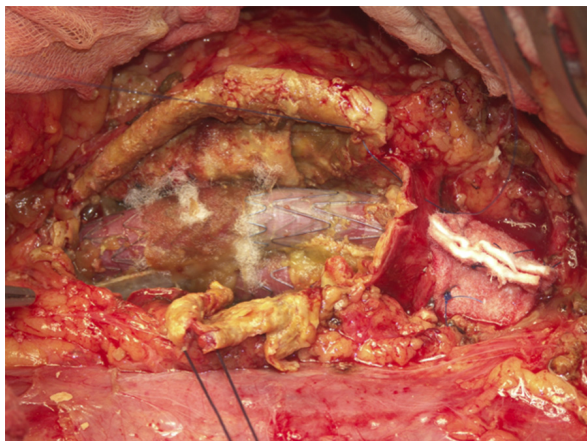


Fig 2. Proximal banding of the neck and sacotomy.

endoleaks did not undergo any other treatment but the semiconversion. We were able to preserve the graft in all cases.

Twelve semiconversions were performed via a retroperitoneal access starting by 2007; from then, this approach was preferred whenever possible. The mean operation length was 3.9 hours, and the mean blood loss was 356 mL.

Blood transfusion was necessary only in the patient with the aortoenteric fistula. He received 2 units of blood before and 1 unit during the intervention.

The mean hospital stay was 9.8 days. In-hospital morbidity was 4% due to one pulmonary infection, which was resolved  $\leq 30$  days. The mean follow-up after partial conversion was 35.3 months (range, 1-70 months).

We recorded no procedure-related deaths. Four cardiac deaths occurred at 12, 26, 30, and 60 months (mean follow-up, 42 months; range, 1-80 months). All patients showed complete resolution of the leak at the DUS examination and at the 30-day contrast CT scan control. No patients showed recurrence of sac growth during the follow-up.

## DISCUSSION

Type II endoleak management is one of the most controversial aspects of short-term and long-term follow-up after EVAR.<sup>9,17,18</sup> Even when feeding patent vessels are not clearly present, but when there is evidence of sac enlargement, authors have shown concern about the risk of rupture and the evolution of sac dimensions.

Many techniques have been proposed to solve an evolutive endoleak, including endovascular techniques (embolizations for instance), open repair, and laparoscopic strategies.<sup>10,18,19</sup>

For only 78% of the 36 patients who underwent endovascular treatment for type II endoleak of our original population, the treatment was eventually effective. These data are congruent with data from the literature.<sup>12,18</sup>

It is evident that the surgical strategy is considered as the last resource because these patients, already borderline

for open surgery at the time of EVAR, usually become more fragile during the time between the prior EVAR and the semiconversion. In our experience, this time was  $>6$  years. The danger is even higher when complete graft removal is proposed. This has been shown by some studies that have compared small subgroups of open conversion with and without graft salvage.<sup>20</sup>

Several authors<sup>16</sup> have shown that graft salvage seems to be a valid option compared with graft removal, because in some comparative series, the mortality ranges from 1% to 4% when removing the graft and is 0% when performing sacotomy with graft salvage.<sup>20</sup> This is, as far as we know, the largest case series of semiconversions in the literature. This technique, which was described first by Hinchliffe et al<sup>14</sup> in 2002, permits resolution of the endoleak in most cases by suturing the feeding vessel, and clamping of the aorta is not necessary. Several small case series were presented after the first publication describing some technical variations.<sup>12</sup>

Some authors<sup>12,21,22</sup> underlined the concept of being as least invasive as possible by performing a short incision on the sac and not manipulating the landing zone. We do not completely agree on this subject; we believe it is worth performing a good sacotomy for the purpose of searching for as many patent vessels with back bleeding as possible. Furthermore, the preventive banding and suturing of the infrarenal neck, which obviously implies a certain manipulation of the landing zone, if performed effectively, is the fundamental maneuver to assure the stability of the graft and permanently avoid its migration after a long time.

The laparoscopic approach has also been described as useful in these instances, but we believe that a surgical approach such as the one we described is more applicable because it is in the toolbox of all vascular surgeons, and if performed as we have described, should be considered not strictly an invasive approach. In all cases, we found a clear source of the sac enlargement, and we fixed it using our technique.

We believe that the main indication to semiconversion should be any kind of sac growth post-EVAR, only after a minimum of one failed endovascular embolization procedure (where failed means continued sac enlargement during the follow-up) and when any other embolization attempts are feasible. We think that is inconvenient, for a treatment of a growing sac, to realize more than three failed embolization procedures.

We included in this series also a semiconversion performed as an emergency concurrently with the repair of an aortoenteric fistula. We decided to treat this patient by semiconversion because he was judged as being too fragile for a more aggressive approach. After the surgical repair of the fistula, a semiconversion was performed to treat the leak. The patient was then prescribed lifelong antibiotic therapy. He is still alive and in good condition after 12 months of follow-up. During our follow-up, we never observed the persistence of type II endoleak and sac growth.

The long follow-up that we have for some of these patients (>6 years), together with the absence of adverse outcomes, shows that this is a safe and effective “last-resource” technique to treat sac enlargement after EVAR for persistent type II endoleaks causing sac enlargement, even for those patients who have been considered unfit for open surgery.

## CONCLUSIONS

Graft salvage appears to be a valid option compared with open repair when considering treatment of persistent type II endoleak. The results of this case series show that this is a safe and effective treatment for endotherapy-resistant type II endoleak causing sac enlargement.

## AUTHOR CONTRIBUTIONS

Conception and design: NM, SR, MO, ES

Analysis and interpretation: MO

Data collection: MO, VA, SF

Writing the article: MO

Critical revision of the article: NM, SR, ES, FP, CS

Final approval of the article: NM, SR, ES

Statistical analysis: MO

Obtained funding: Not applicable

Overall responsibility: NM

## REFERENCES

- Giles KA, Pomposelli F, Hamdan A, Wyers M, Jhaveri A, Schermerhorn ML. Decrease in total aneurysm-related deaths in the era of endovascular aneurysm repair. *J Vasc Surg* 2009;49:543-50.
- Egorova N, Giacobelli J, Greco G, Gelijns A, Kent CK, McKinsey JF. National outcomes for the treatment of ruptured abdominal aortic aneurysm: comparison of open versus endovascular repairs. *J Vasc Surg* 2008;48:1092-100.
- Lifetime Registry of EVAR Publications Committee. Lifeline Registry of Endovascular Aneurysm Repair: long-term primary outcome measures. *J Vasc Surg* 2005;42:1-10.
- Nabi D, Murphy EH, Pak J, Zarins CK. Open surgical repair after failed endovascular aneurysm repair: is endograft removal necessary? *J Vasc Surg* 2009;50:714.e21.
- EVAR trial participants. Endovascular aneurysm repair and outcome in patients unfit for open repair of abdominal aortic aneurysm (EVAR trial 2): randomised controlled trial. *Lancet* 2005;365:2187-92.
- Prinssen M, Verhoeven EL, Buth J, Cuypers PW, van Sambeek MR, Balm R, et al; Dutch Randomized Endovascular Aneurysm Management (DREAM) Trial Group. A randomized trial comparing conventional and endovascular repair of abdominal aortic aneurysms. *N Engl J Med* 2004;351:1607-18.
- Gloviczki P, Huang Y, Oderich GS, Duncan AA, Kalra M, Fleming M, et al. Clinical presentation, comorbidities, and age but not female gender predict survival after endovascular repair of abdominal aortic aneurysm. *J Vasc Surg* 2015;61:853-61.e2.
- Schanzer A, Messina L. Two decades of endovascular abdominal aortic aneurysm repair: enormous progress with serious lessons learned. *J Am Heart Assoc* 2012;1:e000075.
- Jones JE, Atkins MD, Brewster DC, Chung TK, Kwolek CJ, LaMuraglia GM. Persistent type 2 endoleak after endovascular repair of abdominal aortic aneurysm is associated with adverse late outcomes. *J Vasc Surg* 2007;46:1-8.
- Zou J, Sun Y, Yang H, Ma H, Jiang J, Jiao Y, et al. Laparoscopic ligation of inferior mesenteric artery and internal iliac artery for the treatment of symptomatic type II endoleak after endovascular aneurysm repair. *Int Surg* 2014;99:681-3.
- Feezor RJ, Nelson PR, Lee WA, Zingarelli W, Cendan JC. Laparoscopic repair of a type II endoleak. *J Laparoendosc Adv Surg Tech* 2006;16:267-70.
- Ferrari M, Sardella S, Berchiolli R, Adami D, Vignali C, Napoli V, et al. Surgical treatment of persistent type 2 endoleaks, with increase of the aneurysm sac: indications and technical notes. *Eur J Vasc Endovasc Surg* 2005;29:43-6.
- Kouvelos G, Koutsoumpelis A, Lazaris A, Matsagkas M. Late open conversion after failed endovascular aortic aneurysm repair. *J Vasc Surg* 2015;61:1350-6.
- Hinchliffe RJ, Singh-Ranger R, Whitaker SC, Hopkinson BR. Type II endoleak: transperitoneal sacotomy and ligation of side branch endoleaks responsible for sac expansion. *J Endovasc Ther* 2002;9:539-42.
- Bang SH, Park JB, Chee HK, Kim JS, Jang IS. Surgical experience of persistent type 2 endoleaks with aneurysmal sac enlargement after endovascular aneurysm repair. *Korean J Thorac Cardiovasc Surg* 2014;47:167-70.
- Gossetti B, Faccenna F, Castiglione A, Felli MM, Venosi S, Gattuso R. Persistent type II endoleak: two cases of successful sacotomy. *Ann Vasc Surg* 2013;27:240.e9-e11.
- Kray J, Kirk S, Franko J, Chew DK. Role of type II endoleak in sac regression after endovascular repair of infrarenal abdominal aortic aneurysms. *J Vasc Surg* 2015;61:869-74.
- Avgerinos ED, Chaer RA, Makaroun MS. Type II endoleaks. *J Vasc Surg* 2014;60:1386-91.
- Burbelko M, Kalinowski M, Heverhagen JT, Piechowiak E, Kiessling A, Figiel J, et al. Prevention of type II endoleak using the AMPLATZER Vascular Plug before endovascular aneurysm repair. *Eur J Vasc Endovasc Surg* 2014;47:28-36.
- Chaar I, Eid R, Park T, Rhee R, Abu-Hamad G, Tzeng E, et al. Delayed open conversions after endovascular abdominal aortic aneurysm repair. *J Vasc Surg* 2012;55:1562-9.
- Kolvenbach R, Pinter L, Raghunandan M, Cheshire N, Ramadan H, Dion YM. Laparoscopic remodeling of abdominal aortic aneurysms after endovascular exclusion: technical description. *J Vasc Surg* 2002;36:1267-70.
- White JV. Regarding “Laparoscopic remodelling of abdominal aortic aneurysms after endovascular exclusion: a technical description”. *J Vasc Surg* 2002;36:1271-3.

Submitted May 7, 2015; accepted Jul 15, 2015.