

Provided for non-commercial research and education use.
Not for reproduction, distribution or commercial use.



This article appeared in a journal published by Elsevier. The attached copy is furnished to the author for internal non-commercial research and education use, including for instruction at the authors institution and sharing with colleagues.

Other uses, including reproduction and distribution, or selling or licensing copies, or posting to personal, institutional or third party websites are prohibited.

In most cases authors are permitted to post their version of the article (e.g. in Word or Tex form) to their personal website or institutional repository. Authors requiring further information regarding Elsevier's archiving and manuscript policies are encouraged to visit:

<http://www.elsevier.com/authorsrights>



Early endovascular aneurysm repair after percutaneous coronary interventions

Felice Pecoraro, MD,^{a,b} Markus Wilhelm, MD,^a Angela R. Kaufmann, MD,^a Dominique Bettex, MD,^c Willibald Maier, MD,^d Dieter Mayer, MD,^a Frank J. Veith, MD,^c and Mario Lachat, MD,^a *Zurich, Switzerland; Palermo, Italy; and New York, NY*

Objective: The objective of this study was to report long-term results of early endovascular aortic aneurysm repair after percutaneous coronary intervention (PCI).

Methods: This was a retrospective analysis of all patients presenting with abdominal aortic aneurysm and coronary artery disease treated during the same hospitalization by endovascular aortic aneurysm repair performed soon after PCI. Primary outcomes were perioperative mortality, perioperative complications, survival after treatment, and freedom from reintervention.

Results: A total of 20 patients were included, and all completed both procedures. No deaths or abdominal aortic aneurysm ruptures occurred between the PCI and the aortic intervention. Perioperative mortality was 5% as one patient died of mesenteric ischemia after endovascular aneurysm repair. Major cardiovascular vascular complications occurred in four patients (20%) and included non-ST-segment elevation myocardial infarction (one) and access vessel complication (three). Mean follow-up was 94 (range, 1-164; standard deviation, 47) months. Estimated survival at 1 year, 2 years, 5 years, and 10 years was 90%, 90%, 90%, and 60%, respectively. A reoperation was required in six patients. Estimated freedom from reintervention at 1 year, 2 years, 5 years, and 10 years was 83%, 83%, 78%, and 72%, respectively.

Conclusions: Our study indicates that early endovascular aneurysm repair performed within a week after PCI may be a reasonable approach in patients with large or symptomatic aneurysms. (*J Vasc Surg* 2015;61:1146-50.)

Abdominal aortic aneurysm (AAA) has a high incidence globally.¹ Since the introduction of endovascular aneurysm repair (EVAR) by Volodos² and Parodi,³ this technique became the first option in AAA treatment. Compared with open surgery, this less invasive approach has shown better short-term results and similar long-term results.⁴ Although endovascular treatment significantly reduces perioperative complications, myocardial infarction is still the most frequent cause of death after aortic aneurysm treatment.⁵ The same trend is observed in the long-term period, with a fourfold risk increase of myocardial infarction in patients suffering cardiac symptoms preoperatively.^{6,7} In these patients, coronary artery disease (CAD) treatment before aortic aneurysm repair is advocated to reduce myocardial mortality. Both coronary artery bypass grafting (CABG) and percutaneous coronary intervention (PCI) are reported to be effective in reducing early and

late aneurysm-related mortality.^{8,9} Results with combined PCI and early EVAR are missing. Herein we report our experience with early EVAR after PCI in patients with AAA and CAD with long-term follow-up.

METHODS

All patients treated by early EVAR after PCI between January 1997 and December 2005 at the Clinic for Cardiovascular Surgery and the Clinic for Cardiology of Zurich were evaluated. Informed consent for the procedure itself and for the anonymous data collection and analysis was obtained from all patients. The Institutional Review Board approved the retrospective study.

An early EVAR procedure after PCI was indicated when a patient selected for EVAR was preventively treated by PCI for coronary disease during the same hospitalization. By definition, at least a significant coronary artery stenosis requiring PCI intervention was present in all patients. A coronary artery stenosis >70% was considered angiographically significant. Both EVAR and PCI were performed according to a board including vascular specialists, cardiologists, and anesthesiologists.^{10,11} Patients' data collection was performed prospectively within the in-house clinical information systems (KISIM 4.91; CISTEC AG, Zurich, Switzerland; and Dendrite Clinical Systems, Oxfordshire, UK). Follow-up data were obtained as "first intention" through the clinical information system; phone interviews were used when follow-up data were missing. Data were analyzed in January 2014. Primary end points were perioperative mortality, perioperative complications, survival after treatment, and freedom from reintervention. Perioperative outcomes were

From the Clinic for Cardiovascular Surgery,^a Division of Cardiovascular Anesthesia,^c and Department of Cardiology,^d University Hospital Zurich, Zurich; the Vascular Surgery Unit, University of Palermo, AOUP "P. Giaccone," Palermo^b; and The Cleveland Clinic and New York University Medical Center, New York.^c

Author conflict of interest: none.

Reprint requests: Felice Pecoraro, MD, Vascular Surgery Unit, University of Palermo, AOUP "P. Giaccone," Via L. Giuffrè, 90100 Palermo, Italy (e-mail: felicepecoraro@libero.it or felice.pecoraro@unipa.it).

The editors and reviewers of this article have no relevant financial relationships to disclose per the JVS policy that requires reviewers to decline review of any manuscript for which they may have a conflict of interest.

0741-5214

Copyright © 2015 by the Society for Vascular Surgery. Published by Elsevier Inc.

<http://dx.doi.org/10.1016/j.jvs.2014.12.044>

Table. Patients' associated comorbidities

	No. (%)
Hypertension	16 (80)
Diabetes mellitus	4 (20)
Smoking	16 (80)
Lipid disorders	15 (75)
BMI >25	13 (60)
COPD	7 (35)
CKD	2 (10)
CVD	2 (10)
Previous MI	10 (50)
Double MI	1 (5)
Valvular/rhythm heart disease	2 (10)

BMI, Body mass index; *COPD*, chronic obstructive pulmonary disease; *CKD*, chronic kidney disease; *CVD*, cerebrovascular disease; *MI*, myocardial infarction.

defined as events occurring within 30 days. Demographic and preoperative risk factors were also collected and analyzed. History of CAD included typical symptoms, previous myocardial infarction, and clinical studies.¹² Angina pectoris and dyspnea were classified according to the criteria of the Canadian Cardiovascular Society (CCS)¹³ and the New York Heart Association (NYHA).¹⁴ Peripheral artery disease was defined according to Rutherford classification.¹⁵ Perioperative complications were divided into aneurysm related, heart related, and lung related. Aneurysm-related complications included abdominal bleeding, ileus, peritonitis, intestinal ischemia, abdominal compartment syndrome, and type I and III endoleaks after EVAR treatment. Heart-related complications included new perioperative myocardial infarction, new cardiac arrhythmias, cardiac tamponade, and congestive heart failure after PCI treatment. Lung-related complications included pneumonia, pleural effusion (>500 mL), pneumothorax requiring treatment, acute respiratory distress syndrome, and respiratory insufficiency. Cerebral complications such as cerebrovascular insult (CVI) and peripheral nerve lesions were also registered. Statistical analysis was performed with SPSS 16.0 (SPSS Inc, Chicago, Ill). Range and standard deviation (SD) are reported for parametric data; absolute value and percentage are reported for nonparametric data. Mean follow-up of the included patients was 94 (range, 1-164; SD, 47) months.

RESULTS

In the study period, 20 consecutive patients were treated intentionally by early EVAR after PCI. All were treated during the same hospitalization and represent the study cohort. Mean age was 75.5 (range, 59-89; SD, 8) years, and all were male; associated comorbidities are reported in the Table. Mean aneurysm diameter was 61.3 (range, 30-100; SD, 15) mm. In addition to the AAA, two patients (10%) presented with a thoracic aortic aneurysm. In three cases (15%), the AAA was symptomatic with no rupture signs.

In all cases, thoracoabdominal computed tomography angiography was used to evaluate the aortic aneurysm;

coronary angiography evaluated for CAD, and echocardiography evaluated for heart functionality. One-vessel CAD was present in five patients (25%), two-vessel disease in eight patients (40%), and three-vessel disease in seven patients (35%). Fifteen patients (75%) had an ejection fraction >55%, four (20%) between 55% and 35%, and one <35%. Eleven patients (55%) were asymptomatic according to the NYHA criteria; seven (35%) were classified in NYHA II and two (10%) in NYHA III. Seventeen patients (85%) were asymptomatic according to the CCS criteria; the remaining three patients (15%) were classified in CCS II. Six patients (30%) had no peripheral artery disease symptoms; six patients (30%) were classified as Rutherford I, three patients (15%) as Rutherford II, and five patients (25%) as Rutherford III. Of the 42 diseased coronary vessels, 27 (64%) were revascularized. In 16 patients (80%), coronary artery revascularization was performed with stent (drug-eluting stent, 6; bare-metal stent, 10) placement, whereas in four patients (20%), PCI consisted of simple balloon angioplasty. The remaining 15 coronary vessels (36%) were untreated for a nonsignificant stenosis (50%-70% stenosis) in 12 or because the coronary artery was considered irrelevant in 3. The right femoral artery was employed as the PCI access site in 17 cases (85%), the left femoral artery in the remaining 3 (15%). After PCI, all patients were treated with a dual antiplatelet regimen consisting of acetylsalicylic acid (100 mg/d) in all cases plus ticlopidine (250 mg/d) or clopidogrel (75 mg/d). The dual antiplatelet treatment was not interrupted for the EVAR procedure. Mean interval from PCI to EVAR was 2.5 (range, 0.1-7.0; SD, 2.7) days. EVAR was performed with a commercially available bifurcated stent graft in all cases. Excluder (Gore, Flagstaff, Ariz) was used in 10 cases (50%); Vanguard (Boston Scientific, Natick, Mass), in 6 cases (30%); Zenith (Cook Inc, Bloomington, Ind), in 2 cases (10%); Endologix (Endologix, Phoenix, Ariz), in 1 case (5%); and a hybrid device (Zenith body and Excluder limbs), in the remaining case (5%). Infrarenal fixation devices (Excluder, Endologix) were used when the proximal neck was >2 to 2.5 cm in length; transrenal fixation devices (Zenith, Vanguard) were used in shorter necks. Mean proximal neck length was 2.2 (SD, 0.4) cm. In all cases, the device's main body (trunk) was introduced through a surgical arterial exposure (16 femoral arteries and 4 external iliac arteries [EIAs]). In 12 cases, the previous PCI access was surgically exposed to deliver the device's main body; in 4 cases, the femoral PCI access site was not appropriate for the EVAR sheath size and therefore the homolateral EIA was used; in the remaining 4 cases, the contralateral femoral artery was used. The contralateral stent graft limb was introduced through a percutaneous femoral access in 17 cases, the EIA in 2 cases, and a femoral cutdown in the remaining case.

Local anesthesia was employed in all PCI (100%) and in 17 (85%) EVAR procedures. No conversion from local to general anesthesia was registered. The mean volume of contrast material used for the EVAR and PCI procedures was 124 (SD, 65) mL and 196 (SD, 76) mL, respectively.

Mean in-hospital length of stay was 7 (range, 4-20; SD, 9) days.

All patients completed PCI and early EVAR procedures with no AAA rupture or death in the interval between the two procedures. One patient (5%) died after the early EVAR procedure. This patient had a history of myocardial infarction, CVI, and dialysis for chronic renal failure. He suffered postoperatively of intestinal ischemia. Ten perioperative complications occurred, including major adverse cardiovascular complications in four patients (25%). Heart-related complications included an acute non-ST-segment elevation myocardial infarction after coronary restenosis. In this case, initially treated with simple balloon angioplasty, repeated balloon PCI was successful. Lung-related complications were registered in two patients presenting with a pneumothorax and a pleural effusion, respectively. Aneurysm-related complications were registered in two patients presenting with an ileus. A type I endoleak was registered in three cases. Two patients had temporary deterioration of renal function, and one of these required two sessions of hemodialysis. No significant difference was observed in total contrast medium volume in patients developing transient renal function impairment ($P = .08$). Three patients (15%) developed acute limb ischemia. Of these, two patients had a PCI and EVAR access on the same femoral artery. In the remaining case, a femoral cut-down was performed after PCI access. No CVIs were registered. Estimated survival at 1 year, 2 years, 5 years, and 10 years was 90%, 90%, 90%, and 60%, respectively (Fig 1).

Overall, nine patients died during the follow-up. One patient died perioperatively; the second died at postoperative day 45 of global respiratory insufficiency and septic shock. These two patients were excluded from the freedom from reintervention end point. In the remaining 18 patients, a reoperation was required in 6 (33%). One patient underwent repeated PCI for coronary artery stenosis. In three patients, a type I endoleak was managed endovascularly with proximal cuff extensions. The remaining two reoperations were performed to treat patients presenting with acute limb ischemia and consisted of femoral artery thromboendarterectomy with polytetrafluoroethylene patch in one case and lower limb peripheral bypass in the remaining case. The third acute limb ischemia was managed conservatively. Estimated freedom from reintervention at 1 year, 2 years, 5 years, and 10 years was 83%, 83%, 78%, and 72%, respectively (Fig 2).

DISCUSSION

CAD is frequent in AAA patients,^{16,17} and it represents the main cause of death after AAA repair.^{5,18-20} The American College of Cardiology and the American Heart Association of the American College of Physicians recommend, for patients with unstable cardiac symptoms or advanced CAD, coronary revascularization through CABG or PCI.²¹ To reduce cardiac mortality during or after AAA repair,⁶ a preventive coronary revascularization may be advocated.^{22,23} Obviously, patients with large or enlarging AAAs and patients with symptomatic AAAs should be

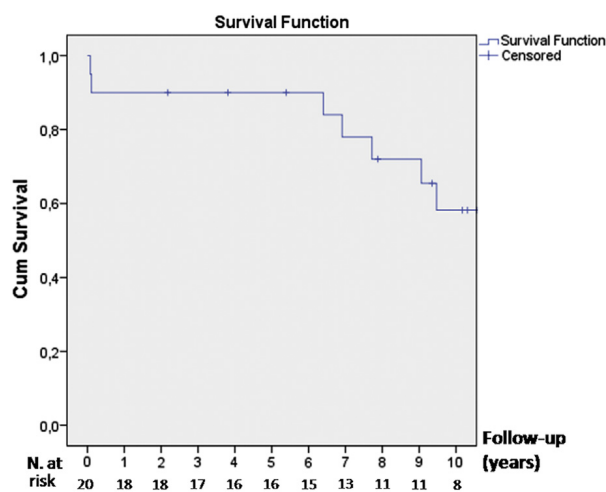


Fig 1. Cumulative survival. Standard error exceeds 10% at 7 years.

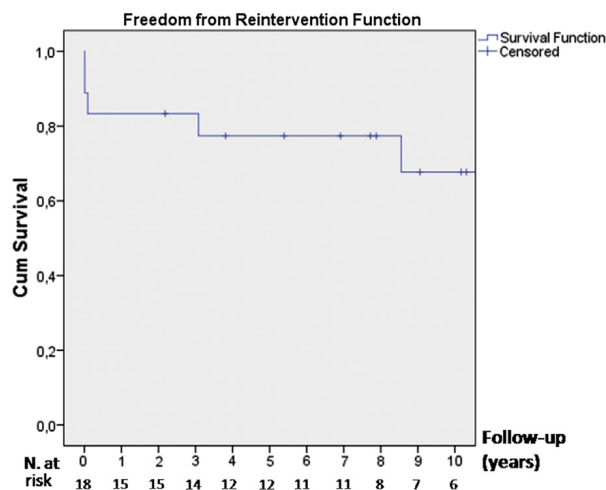


Fig 2. Cumulative freedom from reintervention. Standard error exceeds 10% at 3 years.

treated without much delay with graft replacement or EVAR. In such clinical situations, the management of CAD may be problematic. CABG and open AAA repair performed as a combined procedure efficiently treat both pathologic processes but have shown good results only in a few centers.^{24,25} Combined CABG and EVAR could represent a better solution, but so far there are no data to prove this. Thus, in most centers, a staged approach is used.²² PCI and EVAR have been shown to be less invasive and safer than the respective open repairs; thus, their combination could be more appropriate.^{5,20,26} A strong argument in favor of PCI in patients with AAA is related to the use of local anesthesia. In fact, general anesthesia (with intubation and muscle relaxation) may be involved in AAA rupture because of pressure modification in thoracic and abdominal compartments.^{27,28} However, when coronary revascularization has been performed with

PCI, the Society for Vascular Surgery practice guidelines suggest postponing elective AAA repair to reduce the risk of coronary thrombosis.²⁹ Delay between both procedures should be 4 weeks after simple balloon angioplasty but may last for 1 year when drug-eluting stents have been used.³⁰ During the interval between coronary and aortic procedures, patients are exposed to a higher AAA rupture risk,²² probably related to the inflammatory response after heart revascularization.²⁴ AAA rupture has been reported after 1 week from heart treatment; thus, to decrease AAA rupture risk, a reduction of the interval time (<2 weeks) has been proposed.²²

So far, there is no experience or evidence on how to proceed when EVAR is performed after PCI and what the results are. In our patients, the early EVAR treatment performed at a mean time interval of 2.5 (range, 0.1-7.0; SD, 2.7) days after PCI was shown to be safe. The durability of these combined, less invasive procedures may be an issue as, in both EVAR and PCI, reinterventions seem to be more frequent. EVAR has been related to a higher incidence of reoperations in the long term compared with open AAA repair.^{4,31-33} A similar trend has been reported with PCI in comparison to CABG, independently of the type of coronary stent used.²⁶ In this series, one patient required repeated PCI and three patients required an additional procedure to treat type I endoleak during the follow-up. However, in all four patients, these complications were managed endovascularly. Endoleak incidence (six patients; 30.0%) seems to be high, but it has to be underlined that the follow-up period extends for 8 years, with only three patients who required a reintervention for type I endoleak. Finally, this experience includes our EVAR learning curve, especially in short necks, and some old devices, such as the Vanguard, showed a high rate of material failure, especially on the proximal fixation segment. Peripheral vascular complications during follow-up occurred in 15% (3 of 20) of the patients, and in all these cases it concerned the femoral artery that was used twice as an access site for PCI and EVAR intervention. Thus, it should be recommended to use alternative PCI access (radial or brachial artery) when an early EVAR is planned.

The potential drawbacks of combined early EVAR after PCI may be related to (1) the repeated use of contrast medium within a short time that could increase risk of renal dysfunction, (2) the need to perform EVAR under dual antiplatelet therapy after PCI with a potential increased risk of bleeding, and (3) the close time of two distinct surgical stresses with a potential increase for mortality and morbidity outcomes.

Simultaneous transcatheter aortic heart valve replacement and PCI as single-stage procedures have been shown to improve outcomes of patients presenting with CAD.³⁴ Thus, in the area of hybrid operating rooms with high-end fluoroscopy, the questions arise if coronary and aortic procedures may be done simultaneously and if this would reduce coronary stent thrombosis, perioperative myocardial infarction rate, and death. This will have to be addressed by specific study.

The retrospective analysis and the small patient cohort with no comparative group represent clear limitations of the study. Because of our positive experience, since 1997 all patients presenting with a similar clinical situation and clear indications for both procedures were treated with early EVAR after PCI, and therefore we cannot build up a consistent control group. Another important limitation is that in our experience with early EVAR after PCI, we cannot answer consistently if the risk of coronary artery thrombosis may be higher after the use of drug-eluting stents than after bare-metal stents or simple balloon angioplasty, as our groups are too small. However, this first report on EVAR performed early after PCI may be considered background for further comparative studies.

CONCLUSIONS

To date, there are no data reporting on early or long-term outcomes in patients treated with early EVAR after PCI. Our study indicates that early EVAR after PCI within 7 days may be a reasonable strategy to reduce cardiac events and AAA rupture, especially in patients with large or symptomatic aneurysms. EVAR can be safely performed under dual antiplatelet therapy after PCI. This experience justifies reconsidering the general policy of postponing EVAR for a long time when coronary angioplasty with drug-eluting stents has been performed.

AUTHOR CONTRIBUTIONS

Conception and design: MW, ML

Analysis and interpretation: FP, MW, AK, DB, WM, DM, FV, ML

Data collection: MW, AK

Writing the article: FP, MW, FV, ML

Critical revision of the article: FP, MW, AK, DB, WM, DM, FV, ML

Final approval of the article: FP, MW, AK, DB, WM, DM, FV, ML

Statistical analysis: FP

Obtained funding: Not applicable

Overall responsibility: FP

REFERENCES

1. Stather PW, Sidloff DA, Rhema IA, Choke E, Bown MJ, Sayers RD. A review of current reporting of abdominal aortic aneurysm mortality and prevalence in the literature. *Eur J Vasc Endovasc Surg* 2014;47:240-2.
2. Volodos NL, Shekhanin VE, Karpovich IP, Troian VI, Gur'ev IuA. [A self-fixing synthetic blood vessel endoprosthesis]. *Vestn Khir Im I I Grek* 1986;137:123-5.
3. Parodi JC, Palmaz JC, Barone HD. Transfemoral intraluminal graft implantation for abdominal aortic aneurysms. *Ann Vasc Surg* 1991;5:491-9.
4. United Kingdom EVAR Trial Investigators, Greenhalgh RM, Brown LC, Powell JT, Thompson SG, Epstein D, Sculpher MT. Endovascular versus open repair of abdominal aortic aneurysm. *N Engl J Med* 2010;362:1863-71.
5. Paravastu SC, Jayarajasingam R, Cottam R, Palfreyman SJ, Michaels JA, Thomas SM. Endovascular repair of abdominal aortic aneurysm. *Cochrane Database Syst Rev* 2014;1:CD004178.

6. Hollier LH, Plate G, O'Brien PC, Kazmier FJ, Glowiczki P, Pairolero PC, et al. Late survival after abdominal aortic aneurysm repair: influence of coronary artery disease. *J Vasc Surg* 1984;1:290-9.
7. Lo Sapio P, Chechi T, Gensini GF, Troisi N, Pratesi C, Chiti E, et al. Impact of two different cardiac work-up strategies in patients undergoing abdominal aortic aneurysm repair. *Int J Cardiol* 2014;175:e1-3.
8. Reul GJ Jr, Cooley DA, Duncan JM, Frazier OH, Ott DA, Livesay JJ, et al. The effect of coronary bypass on the outcome of peripheral vascular operations in 1093 patients. *J Vasc Surg* 1986;3:788-98.
9. Foster ED, Davis KB, Carpenter JA, Abele S, Fray D. Risk of noncardiac operation in patients with defined coronary disease: the Coronary Artery Surgery Study (CASS) registry experience. *Ann Thorac Surg* 1986;41:42-50.
10. Brewster DC, Cronenwett JL, Hallett JW Jr, Johnston KW, Krupski WC, Matsumura JS, et al. Guidelines for the treatment of abdominal aortic aneurysms. Report of a subcommittee of the Joint Council of the American Association for Vascular Surgery and Society for Vascular Surgery. *J Vasc Surg* 2003;37:1106-17.
11. Ryan TJ, Bauman WB, Kennedy JW, Kereiakes DJ, King SB 3rd, McCallister BD, et al. Guidelines for percutaneous transluminal coronary angioplasty. A report of the American Heart Association/American College of Cardiology Task Force on Assessment of Diagnostic and Therapeutic Cardiovascular Procedures (Committee on Percutaneous Transluminal Coronary Angioplasty). *Circulation* 1993;88:2987-3007.
12. Bonaca MP, Wiviott SD, Braunwald E, Murphy SA, Ruff CT, Antman EM, et al. American College of Cardiology/American Heart Association/European Society of Cardiology/World Heart Federation universal definition of myocardial infarction classification system and the risk of cardiovascular death: observations from the TRITON-TIMI 38 trial (Trial to Assess Improvement in Therapeutic Outcomes by Optimizing Platelet Inhibition With Prasugrel-Thrombolysis in Myocardial Infarction 38). *Circulation* 2012;125:577-83.
13. Campeau L. Grading of angina pectoris [letter]. *Circulation* 1976;54:522-3.
14. The Criteria Committee of the New York Heart Association. Nomenclature and criteria for diagnosis of diseases of the heart and great vessels. 9th ed. Boston: Little, Brown; 1994. p. 253-6.
15. Rutherford RB, Baker JD, Ernst C, Johnston KW, Porter JM, Ahn S, et al. Recommended standards for reports dealing with lower extremity ischemia: revised version. *J Vasc Surg* 1997;26:517-38.
16. Bayazit M, Gol MK, Battaloglu B, Tokmakoglu H, Tasdemir O, Bayazit K. Routine coronary arteriography before abdominal aortic aneurysm repair. *Am J Surg* 1995;170:246-50.
17. Hertzner NR. Basic data concerning associated coronary disease in peripheral vascular patients. *Ann Vasc Surg* 1987;1:616-20.
18. Hertzner NR. Fatal myocardial infarction following abdominal aortic aneurysm resection. Three hundred forty-three patients followed 6-11 years postoperatively. *Ann Surg* 1980;192:667-73.
19. Galland RB. Mortality following elective infrarenal aortic reconstruction: a Joint Vascular Research Group study. *Br J Surg* 1998;85:633-6.
20. Rose J, Evans C, Barleben A, Bandyk D, Wilson SE, Chang DC, et al. Comparative safety of endovascular aortic aneurysm repair over open repair using patient safety indicators during adoption. *JAMA Surg* 2014;149:926-32.
21. Eagle KA, Berger PB, Calkins H, Chaitman BR, Ewy GA, Fleischmann KE, et al. ACC/AHA Guideline Update for Perioperative Cardiovascular Evaluation for Noncardiac Surgery—Executive Summary. A report of the American College of Cardiology/American Heart Association Task Force on Practice Guidelines (Committee to Update the 1996 Guidelines on Perioperative Cardiovascular Evaluation for Noncardiac Surgery). *Anesth Analg* 2002;94:1052-64.
22. Blackburne LH, Tribble CG, Langenburg SE, Mauney MC, Buchanan SA, Sinclair KN, et al. Optimal timing of abdominal aortic aneurysm repair after coronary artery revascularization. *Ann Surg* 1994;219:693-6; discussion: 696-8.
23. Autschbach R, Falk V, Walther T, Vettelschoss M, Diegeler A, Dalichau H, et al. Simultaneous coronary bypass and abdominal aortic surgery in patients with severe coronary disease—indication and results. *Eur J Cardiothorac Surg* 1995;9:678-83; discussion: 683-4.
24. Ohuchi H, Kato M, Asano H, Tanabe H, Ogiwara M, Imanaka K, et al. Combined coronary artery bypass grafting and abdominal aortic aneurysm repair. *Asian Cardiovasc Thorac Ann* 2003;11:233-6.
25. King RC, Parrino PE, Hurst JL, Shockey KS, Tribble CG, Kron IL. Simultaneous coronary artery bypass grafting and abdominal aneurysm repair decreases stay and costs. *Ann Thorac Surg* 1998;66:1273-6.
26. Bravata DM, Gienger AL, McDonald KM, Sundaram V, Perez MV, Varghese R, et al. Systematic review: the comparative effectiveness of percutaneous coronary interventions and coronary artery bypass graft surgery. *Ann Intern Med* 2007;147:703-16.
27. Mayer D, Pfammatter T, Rancic Z, Hechelhammer L, Wilhelm M, Veith FJ, et al. 10 years of emergency endovascular aneurysm repair for ruptured abdominal aortoiliac aneurysms: lessons learned. *Ann Surg* 2009;249:510-5.
28. Bakker EJ, van de Luijngaarden KM, van Lier F, Valentijn TM, Hoeks SE, Klimek M, et al. General anaesthesia is associated with adverse cardiac outcome after endovascular aneurysm repair. *Eur J Vasc Endovasc Surg* 2012;44:121-5.
29. Chaikof EL, Brewster DC, Dalman RL, Makaroun MS, Illig KA, Sicard GA, et al. The care of patients with an abdominal aortic aneurysm: the Society for Vascular Surgery practice guidelines. *J Vasc Surg* 2009;50:S2-49.
30. Schouten O, Sillesen H, Poldermans D. European Society of Cardiology. New guidelines from the European Society of Cardiology for perioperative cardiac care: a summary of implications for elective vascular surgery patients. *Eur J Vasc Endovasc Surg* 2010;39:1-4.
31. Prinssen M, Verhoeven EL, Buth J, Cuypers PW, van Sambeek MR, Balm R, et al. A randomized trial comparing conventional and endovascular repair of abdominal aortic aneurysms. *N Engl J Med* 2004;351:1607-18.
32. Lovegrove RE, Javid M, Magee TR, Galland RB. A meta-analysis of 21,178 patients undergoing open or endovascular repair of abdominal aortic aneurysm. *Br J Surg* 2008;95:677-84.
33. Takagi H, Umemoto T. A meta-analysis of randomized and risk-adjusted observational studies of endovascular versus open repair for ruptured abdominal aortic aneurysm. *Vasc Endovascular Surg* 2011;45:717-9.
34. Abdel-Wahab M, Mostafa AE, Geist V, Stocker B, Gordian K, Merten C, et al. Comparison of outcomes in patients having isolated transcatheter aortic valve implantation versus combined with preprocedural percutaneous coronary intervention. *Am J Cardiol* 2012;109:581-6.

Submitted Aug 19, 2014; accepted Dec 13, 2014.