



Deep seroma after incisional hernia repair

Case reports and review of the literature



Ann. Ital. Chir.

Published online (EP) 12 May 2015

pii: S2239253X15022938

www.annitalchir.com

Giuseppe Salamone, Leo Licari, Antonino Agrusa, Giorgio Romano, Gianfranco Cocorullo, Gaspare Gulotta.

Department of Surgical, Oncological and Oral Sciences University of Palermo.
General Surgery and Emergency Policlinico Universitario "P. Giaccone", Palermo, Italy

Deep seroma after incisional hernia repair. Case report and review of the literature

AIM: Wound-related complications are common after incisional hernia repair with mesh; seroma formation is the most frequent problem. The formation of a deep seroma has been rarely reported in the literature.

MATERIAL OF STUDY: In one year, September 2012-2013, 136 patients underwent surgery for incisional hernia repair, both elective and urgent. **Results:** The following complications were observed: one dislocation of polypropylene prosthesis, a massive relapsed seroma and two deep seromas described in this article. A 63- years-old female underwent open incisional hernia repair with an intraperitoneal PTFE patch. She developed recurrent seroma under the mesh drained percutaneously, and finally the prosthesis was removed. A 72- years-old male underwent open incisional hernia repair with an intraperitoneal PTFE patch. After several months the patient had seroma infection. The prosthesis was then removed.

CONCLUSIONS: Seroma is a wellknown complication of postoperative ventral hernia repair, especially where prosthetic mesh is used. The formation of a deep seroma is rare. Only few works mention this complication in literature. In the development of these chronic seromas a role may be played by a long-term inflammatory reaction, more pronounced with polypropylene and polyester meshes than with ePTFE. A conservative follow up of the seromas is recommended because drainage can introduce infection. In cases where the seroma causes discomfort or is infected then drainage is necessary. From experience at our institution we suggest that patients with the deep subtype of mesh-associated seromas may require closer clinical follow up. When possible, we recommend attempting the drainage of the liquid, eventually followed by microbiological examination.

KEY WORDS: Deepseroma, Incisional hernia, Intraperitoneal mesh

Introduction

Wound-related complications are common after incisional hernia repair with mesh; among them the seroma formation is the most frequent problem. When mesh is

used for repair of larger and more complex incisional hernias, the risk of seroma formation increases and appears in 30-50% of cases¹. The formation of a deep seroma has been rarely reported in the literature. Scott *et al.* reported two cases², Heniford *et al.* reported a frequency of 0,36% (3/819 patients) of long-term fluid collection develop under the mesh³. Tsereteli *et al.* reported 7 cases (of 442 patients in 5 years) with persistent seroma posterior to the mesh⁴. The different biomaterials used to construct commonly used prosthetic mesh influence the permeability to fluid and affect seroma formation rates. Previously reported rates of seroma occurrence with different types of mesh range from 4% to 8% with polypropylene grafts and 5% to 15% with polytetrafluorethylene (PTFE) grafts^{5,6}.

Pervenuto in Redazione Aprile 2014. Accettato per la pubblicazione Marzo 2015.

Correspondence to: Giuseppe Salamone MD, Department of Surgical Oncological and Oral Sciences, University of Palermo, General Surgery and Emergency, Policlinico Universitario "P. Giaccone", Via Liborio Giuffrè 5, 90127 Palermo, Italy (e-mail: giuseppe.salamone@unipa.it)

Susmallian et al. evaluated the true incidence of seroma formation after laparoscopic repair of incisional hernia with PTFE patch; in 20 patients seroma was diagnosed clinically in only 35% of cases, while ultrasound examination revealed the presence of seroma in 100% of patients⁷. The extent of seroma formation is also known to vary between subjects despite the use of identical mesh materials and surgical technique. In some patients only a small amount of fluid is found using ultrasonography, others suffer from a large volume of seroma fluid that has to be aspirated or treated during operation⁸. In most instances, these seromas resolve either spontaneously or with the insertion of drains or serial percutaneous aspirations. The best way to recognize and differentiate postoperative fluid collection from hernia recurrence seems to be a computed tomography (CT) scan of the abdomen and its wall⁹. CT is a useful imaging tool in patients with repair of incisional ventral hernia, showing the correct site of the mesh, subclinical fluid collections in the abdominal wall and recurrent hernia¹⁰.

Material and Methods

In one year, from September 2012 to September 2013, 136 patients underwent surgery for incisional hernia repair, of which 106 midline (78%) and 30 lateral (22%), both elective and urgent. 19% of those with median line were treated with direct suture, 22% treated with polypropylene sublay and for the remaining 57% the intraperitoneal mesh was used (40% polyester with a three dimensional weave material, 10% PTFE, 7% other dual-meshes). Finally in 2 patients a biological mesh and syntheticbioabsorbable mesh (for tissue reinforcement) was used.

10% of those with lateral surgical treatment direct suture was used (size less than 3 cm), 36.7% were treated with polypropylene sublay and for the remaining 53.3% an intraperitoneal mesh was used (20% polyester with a three dimensional weave material, 23.3% PTFE, 10% other dual-meshes).

Intraperitoneal meshes were fixed along the circumference, with cautious hemostasis, resection of the hernia sac, placement of suction drain in the subcutaneous tissue (removed on day 3 post-operative) and application of pressure dressing(removed in 7th post-operative day). The following complications were observed: in a patient with liver disease HBV related and post-operative paralytic ileus; the dislocation of the prosthesis (polypropylene) and subsequent incisional hernia recurrence; in a patient with chronic heart failure a massive seroma relapsed, twice drained percutaneously (biological prosthesis); two deep seromas, the only complications that required removal of the prosthesis, described in more detail in the sections below.

CASE HISTORY 1

A 63-years-old female with a medical history of diabetes mellitus type II, ulcerative colitis and hypertension, underwent at the age of 60 open right nephrectomy for a voluminous cyst. In October 2012 she underwent open incisional hernia repair. The hernia was repaired with an intraperitoneal PTFE patch. Five months after surgery, she developed a seroma, without infection, and abdominal pain, localized in the left side of the abdomen. An abdominal CT revealed a large, well-defined intra-abdominal fluid collection (23x11x25 cm) under the mesh (Figs. 1, 2, 3). A percutaneous closed suction aspiration

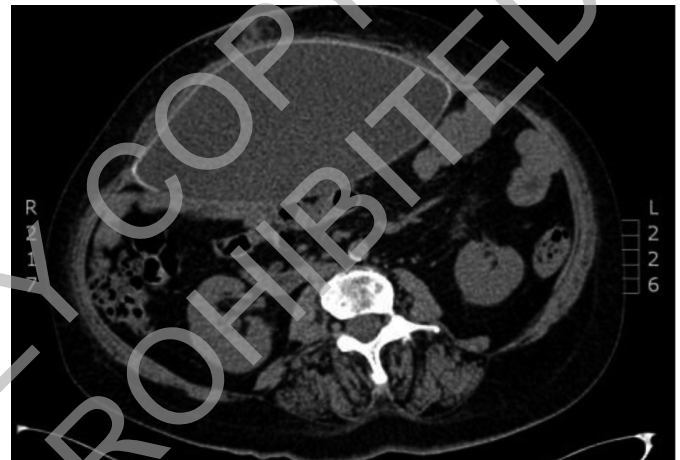

Fig. 1: Case 1: intra-abdominal fluid collection under the mesh.

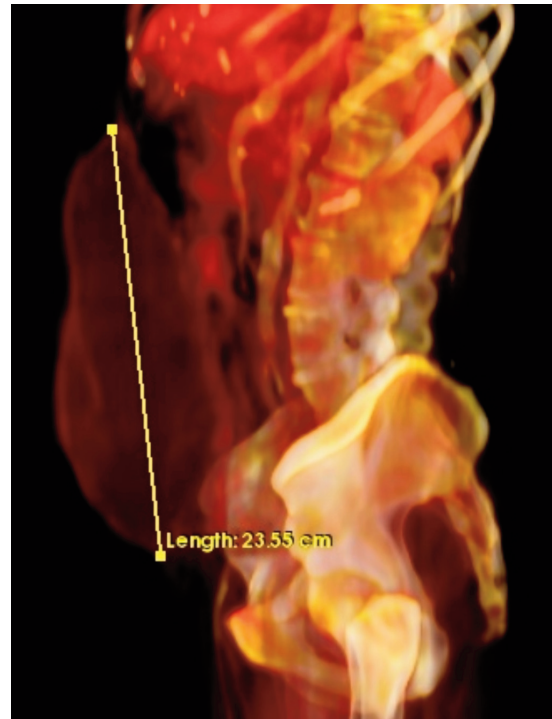


Fig 2: Case 1 3D. Reconstruction with OsiriX Imaging Software Lateral view.

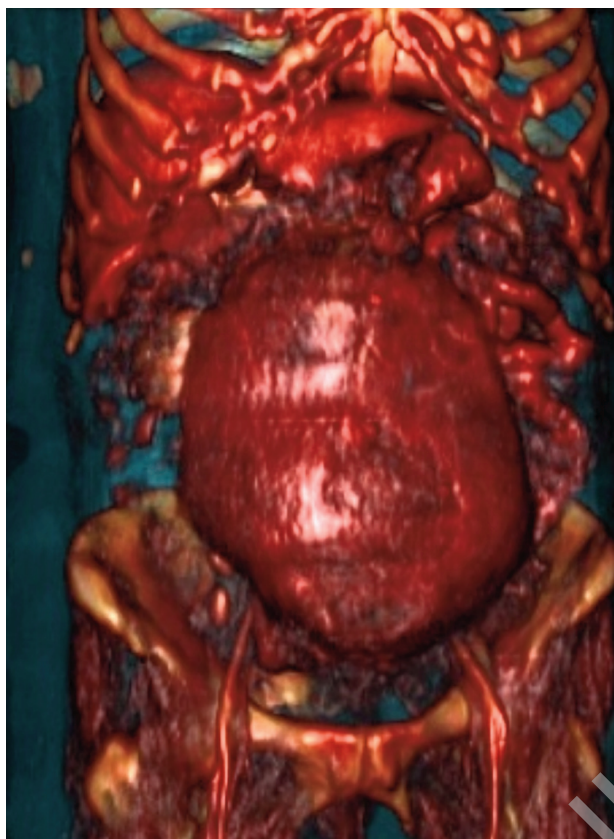


Fig. 3: Case 1 3D. Reconstruction with OsiriX Imaging Software Front view.

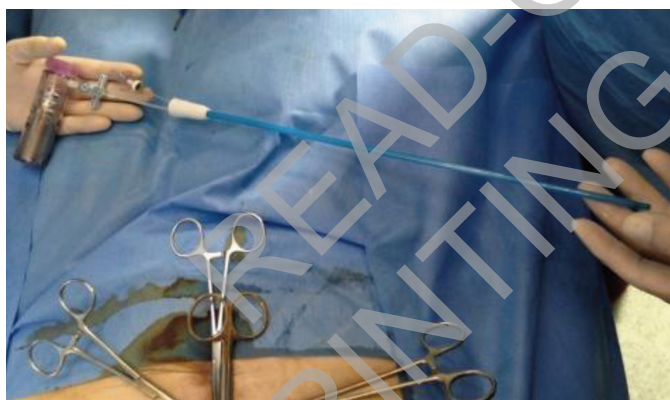

Fig. 4: Case 1: percutaneous drainage with instillation of fibrin glue.

was subsequently performed. After four months the seroma recurred (20 x 10 x 24) and it was treated with percutaneous drainage (Fig. 4) with instillation of fibrin glue as a sclerosant. Despite these attempts, 3 months later, a large seroma recurred. The patient was then hospitalized; abdominal CT was performed revealing the seroma under the mesh (18 x 8 x 24 cm). The patient underwent surgery, the prosthesis was removed and 2 L of serous material was aspirated (Fig. 5), partly taken for microbiological examination. The posterior wall of sero-

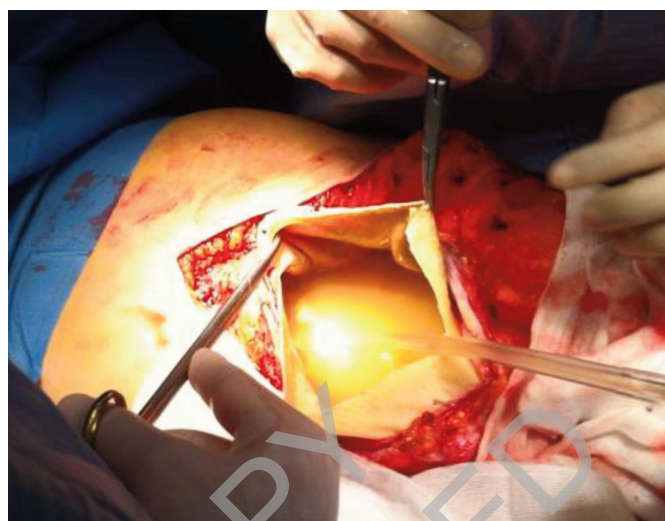


Fig. 5: Case 1: serous material under the mesh.

ma cavity consisted of thick granulation tissue that separated the mesh and underlying fluid from the abdominal contents. This made it possible to repair the abdominal wall without the use of a mesh, in doubt of infection. The microbiological examination came back negative, highlighting the absence of infection. The patient had no postoperative complications and complete remission of the painful symptoms.

CASE HISTORY 2

A 72-years-old male with a medical history of hypertension, chronic obstructive pulmonary disease, underwent at the age of 66 abdominal aortic aneurysm. At the age of 70 underwent open incisional hernia repair

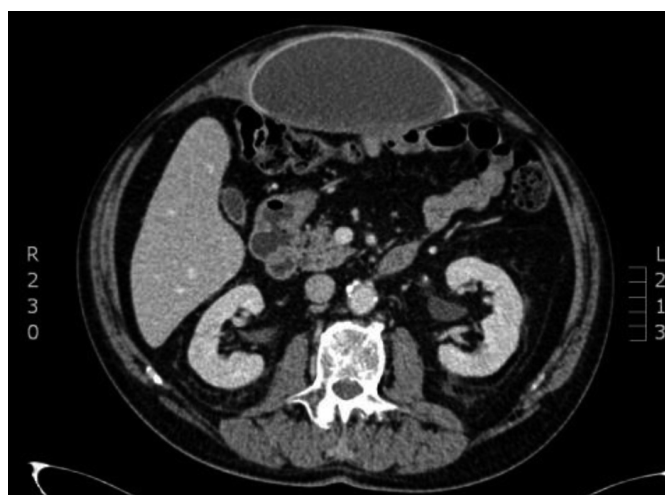

Fig. 6: Case 2: intra-abdominal fluid collection under the mesh.

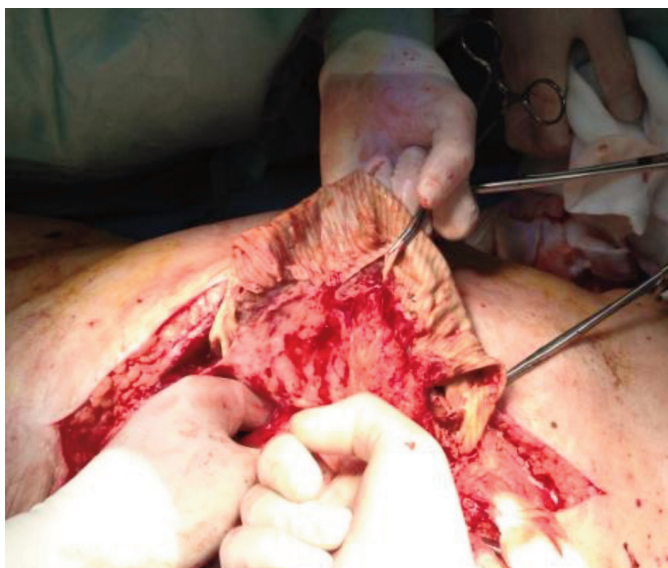

Fig. 7: Case 2: the removal of infected mesh.

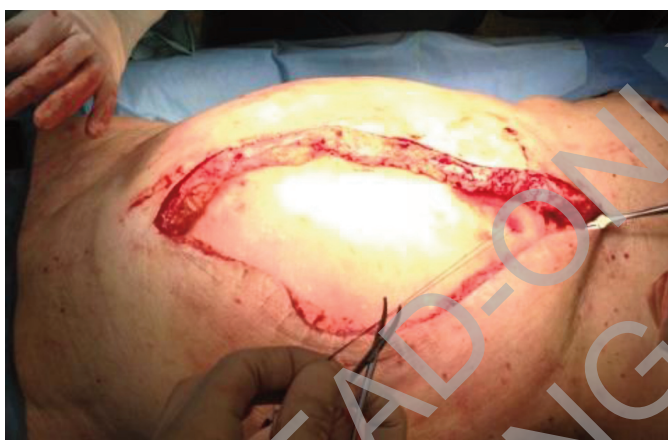

Fig. 8: Case 2: use of synthetic bioabsorbable mesh onlay.

with an intraperitoneal PTFE patch, followed by cauterization and partial excision of the hernia sac. After two months the partial wound dehiscence was treated surgically. After 2 years recurrent incisional hernia and deep seroma was observed (17x14x6 cm) (Fig. 6), without symptoms. After 6 months, the patient developed cutaneous fistula with consequent infection of seroma. The prosthesis was then removed, and the recurrent incisional hernia repaired with the components separation technique and a synthetic bioabsorbable mesh onlay (Figs. 7, 8).

Results and Conclusions

Seroma is a well-known complication of postoperative ventral hernia repair, especially where prosthetic mesh is

used. An exact etiology for seroma formation is not clear, but an immediate local inflammatory response to the presence of mesh is thought to be a culprit, such as an abnormal disposition of reticulin fibres¹¹. Commonly applied mesh materials are made from expanded PTFE or polypropylene. Both materials may cause a variety of tissue reactions leading to postoperative cytokine release, fever or a persistent formation of seroma¹². The extent of seroma formation varies between subjects despite the use of identical mesh materials and surgical technique. Although in some patients only a small amount of fluid is found using ultrasonography, others suffer from a large volume of seroma fluid that has to be aspirated or treated during operation. The latter occurs during the immediate postoperative period and usually resolves with or without drainage within 4-6 weeks. A conservative follow up of the seromas is recommended because drainage can introduce infection. In cases where the seroma causes discomfort or is infected then drainage is necessary¹³.

The formation of a deep seroma is rare. In literature, only few works mention this complication. Scott P.D. reports two cases, Heniford observed 3 cases out of 850 patients (0,3%)³. The largest number of cases reported was by Tsereteli Z with, a group of 6 patients out of 442 (1,3%), this study proposes a treatment algorithm for seroma deep persistent, which takes into account, among the various consequential options, drainage of the fluid collection and the removal of the mesh.

We report two cases out of 136 patients (1,4%). The development of these chronic seromas may involve other mechanisms other than the ones described in the previous studies because long-term inflammatory reaction is more pronounced with polypropylene and polyester meshes than with ePTFE¹⁴. Our patients, as also described by Tsereteli, have developed an extensive peel or rind that separated the mesh and underlying fluid from the abdominal contents, which allowed, once removed the mesh, to repair the wall only with suture. Cauterization of the hernia sac and the application of a central full-thickness suture to reduce the dead space between the hernia sac and the patch significantly decrease the incidence of seroma, hematoma, and infection.

From experience at our institution we suggest that patients with the deep subtype of mesh-associated seromas may require closer clinical follow up. When possible, we recommend attempting the drainage of the liquid, eventually followed by microbiological examination. Finally, as also suggested by Tsereteli's algorithm, we recommend the removal the prosthetic mesh after the first seroma occurrence.

Riassunto

La formazione di sieromi a seguito di correzione chirurgica di laparoceli con mesh è una evenienza frequen-

te oramai non più considerata una vera e propria complicanza. Il “Deep Seroma” rappresenta invece un raro riscontro, come peraltro confermato dai rari casi riportati in letteratura, che talvolta può raggiungere grandi dimensioni e, se complicati da infezione, possono avere una percentuale elevata di mortalità. In un anno, nel nostro istituto 136 pazienti sono stati sottoposti ad intervento chirurgico di plastica della parete addominale per laparocele con posizionamento di protesi: tra le complicanze osservate desideriamo segnalare due rari casi di deep seroma. In entrambi i casi la protesi utilizzata è stata in PTFE al di sotto della quale, sul versante viscerale, si sono formati due voluminosi deep seromas. L'esordio dei due casi è stato differente: sintomatico il primo senza sequele infettive, mentre il secondo, asintomatico ma con l'evidenza di fistola cutanea e successiva infezione del sieroma. Importante la diagnosi precoce che deriva da un stretto follow-up dei pazienti operati, che può essere agevolmente sospettata con una ETG e perfezionata con TC addome ed ricostruzione 3D della lesione che eseguito in uno dei due casi ha permesso una valutazione anatomica più precisa.

References

1. Berger D, Bientzle M, Muller A: *Postoperative complications after laparoscopic incisional hernia repair. Incidence Treatment.* Surg Endosc, 2002; 16 (12):1720-723.
2. Scott PD, Harold KL, Craft RO, Roberts CC: *Postoperative seroma deep to mesh after laparoscopic ventral hernia repair. Computed tomography appearance and implications for treatment.* Rad Case Rep 2008
3. Heniford BT, Park A, Ramshaw BJ, Voeller G: *Laparoscopic repair of ventral hernias. Nine years' experience with 850 consecutive hernias.* Ann Surg, 2003; 238(3):391-99.
4. Tsereteli Z, Ramshaw B, Ramaswamy A: *Chronic posterior seroma with neoperitoneum following laparoscopic ventral hernia repair: Treatment algorithm.* Hernia, 2008; 12(4):363-66.
5. Turkcapar AG, Yerdel MA, Aydinuraz K, Bayar S, Kuterdem E: *Repair of midline incisional hernias using polypropylene grafts.* Surg Today, 1998; 8(1):59-63.
6. Chrysos E, Athanasakis E, Saridaki Z, et al.: *Surgical repair of incisional ventral hernias: Tensionfree technique using prosthetic materials (expanded polytetrafluoroethylene Gore-Tex Dual Mesh).* Am Surg, 2000; 66(7):679-82.
7. Susmallian S, Gewurtz G, Ezri T, Charuzi I: *Seroma after laparoscopic repair of hernia with PTFE patch: Is it really a complication?* Hernia, 2001; 5(3):139-41.
8. Schachtrupp A, Klinge U, Junge K, et al.: *Individual inflammatory response of human blood monocytes to mesh biomaterials.* Br J Surg, 2003; 90(1):114-20.
9. Dukhno O, Pinsk I, Hertzano Y, Levy I, Ovnat A: *An unusual presentation of a huge seroma following ventral hernia repair.* Surg Pract, 2005.
10. Gossios K, Zikou A, Vazakas P, Passas G, Glantzouni A, Glantzounis G, Kontogiannis D, Tsimoyiannis E: *Value of CT after laparoscopic repair of postsurgical ventral hernia.* Abdom Imaging, 2003; 28(1):99-102.
11. Salamone G, Licari L, Atzeni J, Tutino R, Gulotta G: *Histologic considerations about a rare case of recurrent incisional hernia on McBurney incision.* Ann Ital Chir, 2014; 85 (ePub).
12. Schachtrupp A, Klinge U, Junge K, et al.: *Individual inflammatory response of human blood monocytes to mesh biomaterials.* BJS, 2003; 90(1):114-20.
13. Gutierrez DIP, Vargas RJ, Dieguez Garcia JA: *The value of CT diagnosis of hernia recurrence after prosthetic repair of ventral incisional hernias.* Eur Radiol, 2001; 11(7):1161-164.
14. Klinge U, Klosterhalfen B, Muller M, Schumpelick V: *Foreign body reaction to meshes used for the repair of abdominal wall hernias.* Eur J Surg, 1999; 165(7):665-73.