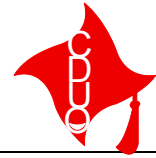


XXI CONGRESSO NAZIONALE

Odontoiatria Traslazionale

(Roma, 10-12 Aprile 2014)



Collegio dei Docenti Universitari
di discipline Odontostomatologiche

ORTOGNATODONZIA

INDICE >>>

TREATMENT OF CLASS I MALOCCLUSION WITH FRANKEL APPLIANCE

F. Frezza¹, A. Padovano di Leva¹, G. Campisi², M. Dioguardi¹, G. La Torretta¹, V. Panzarella²,
G. Montaruli¹, D. Ciavarella¹

*1*Department of Clinical and Experimental Medicine, Faculty of Medicine, School of Dentistry, University of Foggia, Foggia, Italy

*2*Department of Oral Sciences, Section of Oral Medicine, University of Palermo, Palermo, Italy

Aim. The aim of this paper is to evaluate the effect of the Frankel in child with class I malocclusion, maxillary and mandibular contraction, and anterior teeth crowding.

Materials and methods. 5 patients with a class I division I malocclusion, maxillary and mandibular contraction and anterior crowding was enrolled in the present study. All patients presented with a stage CS2, CS3 or CS4. Patients with CS5 were not enrolled in the study. Before wearing the Frankel, on each patient head radiographs were taken in lateral plane with the head fixed in a cephalostat with a film-focus distance of 4 m and a midsagittal-to-film distance of 0,1 m. Cephalometric analysis and casts analysis was performed before phase 1 treatment (T1), and immediately following phase 2 treatment (T2). In addition to standard cephalometric evaluation, another analysis, based on the distance of the basion, A and B to the T line, was done. Patients were instructed to wear the Frankel for 16 hours per day, during the night and afternoon, removing it only to eat and brush. Active treatment lasted 24 months for all patients. A statistical analysis of cephalometric and casts values before and after treatment was done.

Results. After 24 months of treatment the cephalometric effects observed were: an increase of the anterior facial height (mean 3,8 mm), an increase of the distance of the basion to the T line (mean 3,6 mm), a incisors tip control (upper incisors mean 0°, lower incisors - 3,2°) and a sagittal maxillary growth control (the mean distance of A to T line was 0°, the mean distance of B to T line was of - 2,2 mm). On cast authors observed an expansion of the upper and lower arches (anterior upper arch expansion mean 2 mm, posterior upper arch expansion mean 2,5 mm; lower arch mean 1 mm) with anterior crowding resolution and incisors sagittal control.

Conclusions. Authors evaluated that Frankel had a great repeat to control jaw growth, an increase of maxillary and mandibular expansion, an increase of the anterior facial height with a good control of incisors inclination.