

Liver hydatidosis: reasoned indications of surgical treatment. Comparison between conservative and radical techniques

Retrospective study



Ann. Ital. Chir., 2014 85: 422-430
pii: S0003469X14022337

Giuseppe Salamone, Roberta Tutino, Jenny Atzeni, Leo Licari, Nicola Falco,
Giuseppina Orlando, Gaspare Gulotta

Department of Surgical, Oncological and Oral Science, University of Palermo, Medical School, General Surgery and Emergency, Policlinico "Paolo Giaccone", Palermo, Italy.

Liver hydatidosis: reasoned indications of surgical treatment. Comparison between conservative and radical techniques. Retrospective study

Liver hydatidosis is a focal benign parasitic disease that still cause high rate of morbidity particularly in the Mediterranean area. A retrospective study comparing conservative and radical techniques in a General and Urgent Surgery operative unit was carried out in order to find signs of its surgical treatment.

A total of 50 patients, 24 men and 26 women, who experienced a surgical treatment from 2000 to 2011, participated, and through the Fisher's Exact Test characteristics of the cysts, post-operative complications and relapse were compared. As a result, 29 patients undertook conservative surgery, while 21 radical surgery.

There was a relationship between characteristics of the cysts and the technique chosen, ($p < 0.001$). Likewise, whenever the diameter was smaller than 10cm or localized in the left lobe a radical technique was used. Conversely, a conservative technique was used when the diameter was bigger than 10 cm or they were localized in the right lobe or complicated by intra-biliary or intra-peritoneal rupture as well as in contiguity with major vascular and biliary structures. In this regard, while the post-operative morbidity was related to the conservative techniques ($p < 0.004$), the relapses tended to not be related to any techniques in our case ($p < 0.14$).

In conclusion, in a non hepato-bilio-pancreatic center a radical surgery including liver resection is suggested for left lobe's cysts, while a conservative technique tends to be more effective for right lobe's cysts mainly if complex. Consequently, patients with complicated presentation could explain why conservative treatment causes higher rate of morbidity.

KEY WORDS: Liver hydatidosis, Parasitic diseases

Introduction

Liver hydatidosis is a focal benign parasitic disease caused by the embryonic form of *metacestodes E. Granulosus*. Interestingly, hydatid being considered a benign pathology tends to be characterized by a controversy due to

those complications coming from its growth and progression. The compressive phenomena and the rupture which cause anaphylactic shock which is difficult to manage can be an example. In addition, it is a health problem impacting also on farming and trade^{1,2}. It does not surprise that this parasitic disease is one of the most widespread especially in the Mediterranean area. In this regard, in Italy the disease is endemic with a higher prevalence in the southern regions. Sicily, for instance, due to its territorial features, counts a prevalence of 57.6% in sheep, 11-67% in cattle, 5.6-19% in sheepdogs and 2.3%^{1,2} in humans^{3,4}. Notably, the disease expanded dramatically in humans from 1.99% to 2.30% between 1980-'84 and 1989-'91 respectively (a particular thanks to unpublished data prepared by Prof.

Pervenuto in Redazione Gennaio 2014. Accettato per la pubblicazione Aprile 2014

Correspondence to: Dr. Roberta Tutino, via Roccaforte 147, 90011 Bagheria (PA) (e-mail: la.tutino@gmail.com)

G. Garippa). Despite the fact that cysts' prevalence and fertility rates are lower than in the past⁴ this health problem still has a strong importance and high incidence in the region^{5,6}.

The reason of this study resides on the importance and incidence that this disease has in Sicily. Its aim is to provide patients with a combination of safety and resolution through assessing various techniques of surgery. Despite numerous therapeutic approaches have been developed, including medical therapy, PAIR, endoscopic, surgery, radio ablation⁷⁻¹⁴, surgery tends to be the most effective treatment^{8,15}. Furthermore, it is the most in use with also complicated cysts, voluminous cysts with inside- daughter cysts, only localized superficial cysts, infected cysts, cysts in communication with the biliary tree or compressing adjacent vital organs^{10,16-19}. However, different surgical treatments are adopted according to the disease, patient and surgeon. Surgical techniques are divided into two main groups: conservatives and radicals.

In general, post-operative mortality ranges from 0% to 8%, and this is related to the presence of complicated cysts. Patients being operated for hepatic hydatid disease have usually a prolonged hospital stay as morbidity is not underestimated. Several factors may influence significantly the occurrence of complications. A cyst more than 10 cm in diameter containing purulent bile and biliary fistulas, located near the dome liver or in areas where it is difficult to inspect, can be the case. Recurrence are likely possible and variable with a percentage between 2% and 10%, after open interventions. Additionally, this may occur even after 10-15 years and it might be caused by unrecognized cysts not treated at the time of the surgery; sub-locations from the presence of exophytic daughter cysts after conservative treatment; hydatid spillage of not sterile liquid.

The dual function of General and Urgent Surgery Operative Unit enabled the team to accommodate patients with hydatid disease, but with different clinical presentations. The study started with the analysis of different aspects and possible evolution of the disease at the expense of the liver. It then moved to analyze those clinical histories of patients who undertook hepatic hydatid disease surgery from 2000 to 2011 from the school of Palermo assessing those proposals through international scientific literature.

Method

A retrospective study was carried out through the analysis of patients operated for hepatic hydatid disease in the General and Urgent Surgery O.U. of the Policlinic "Paolo Giaccone" in Palermo from 2000 to 2011. The study aimed to confirm if there was correlation between the chosen technique with the patient, the complication rate and the recurrence of the disease. Patients diagnosed with

questionable imaging techniques, not confirmed by laboratory data and showing negative pathology were excluded from the study.

Demographic data, clinical presentation, location and characteristics of the cyst, data on hospital stay, post-operative complications and follow-up were collected and analyzed using frequencies and percentages and processed using the Fisher Exact Test. Demographic data taken into account were parameters in strict dependence with the infestation of the parasite such as sex, age, profession, if patients come from small towns. The input mode and hospital response to the disease were examined through the analysis of admission to emergency or elective, start symptoms and specifically assessing the occurrence of pain, fever, jaundice, itching.

The investigation of characteristics of cyst was based on data supplied by diagnostic imaging by ultrasound and CT. We analyzed their size, location, presence of multiple cysts and their stage according to Garbhi and WHO's classification^{20,21}. Firstly, cysts were classified into 2 categories according to their dimension, > of 10 cm and ≤ of 10 cm. The different segmental locations were classified into three groups: left lobe-segments V and VI - segments VII-VIII-I, considering a possible uniformity of treatment for distal, front or back location^{22,23}. The number of cysts in the organ was another parameter considered which enables lobectomy rather than individual cysts treatments in case of multiple cysts within the same lobe, in particular the left lobe. Secondly, patients' cysts were divided in stage according to the WHO classification, providing useful information about the state of disease activity and the presence of complicated cysts. This gave also further knowledge about the inflammatory or fibrotic substrate and the malleability of the residual cavity after excision.

Another parameter regarded the presence of cysts complicated by rupture into the biliary tract or peritoneum, as well as the presence of cysts with compressive effects on adjacent structures and/or their relationships of proximity to major vascular and bile structures. These two categories of treatments were sometimes associated with cholecystectomy or ERCP to facilitate the resolution of any notices bile or just the coexistence of gallstone disease, and assessed with affixing drainage pipes free, NBD and Kehr drainage tubes in the residual cavities²⁴⁻²⁸. Postoperative complications were analyzed, such as fever, peritoneal fluid, presence of lobulated collections, pneumonia, pneumoperitoneum, pleural effusion, biliary fistulas. The hospital stay included two groups, and the follow-up was long term supervision on a sample of patients. As a result, control visits enabled the collection of medical histories and physical examination, while through a general ultrasound study the liver's morpho-volumetry and echotexture was evaluated. This helped to highlight the presence of hyperechoic areas, sign of potential outcomes of previous surgery and focal hypoechoic areas, and possible recurrences.

In addition, through Fisher's Exact Test it was examined whether the surgical technique (A: Radical, B: Conservative) applies according to the characteristics of cysts complexity (*H0: Complicated, large, contiguous with vascular or biliary structures, relapses, not on the left-lobe, H1: small or on the left lobe*), whether the surgical technique involves more or less post-operative morbidity (*H0:morbidity, H1:no-morbidity*), and whether it involves reappearances or not (*H0:Relapse, H1:Do not Relapse*).

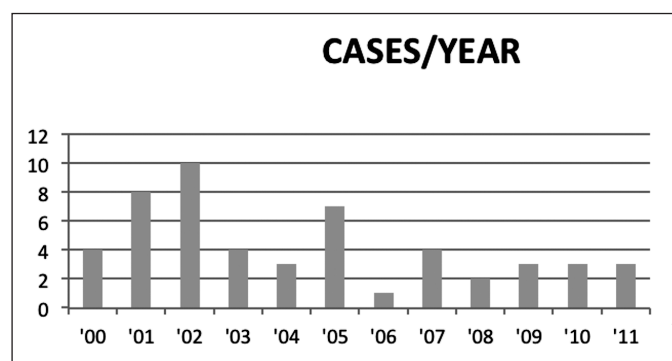


Fig. 1: Cases of hydatidic cyst in patients for year in the Operative Unit of Urgent and General surgery of the Policlinic of Palermo from 2000 to 2011.

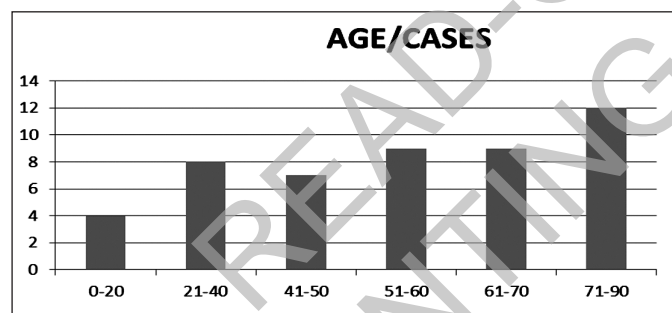


Fig. 2: Distribution for age of the patients with hydatidic cyst in the Operative Unit of Urgent and General surgery of the Policlinic of Palermo from 2000 to 2011.

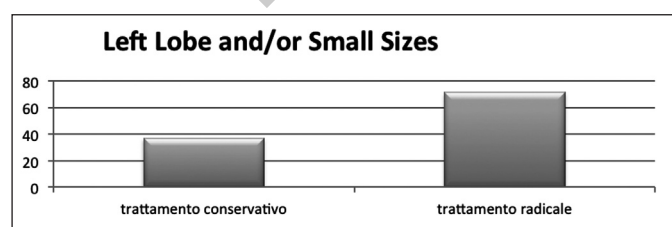


Fig. 3: Association between cysts in the left lobe and/or of small dimension and the chosen treatment.

Results

Patients involved in the study were 50, 24 males and 26 females. The rate decreased and then remained stable over the years, as Figure 1 depicts. The average age of patients surgically treated was 54 year old with a standard deviation of 18 year old. The frequency of submission of cases increases with age, as Fig. 2 shows, and this is closely related to the natural history of the disease. Therefore, in a man once the infestation starts it will be maintained by a constant or inconstant growth of cysts, which might continue throughout years until when the check up takes place with or without symptoms. Demographic data of the two sample examined concerned age, sex, region of provenience and work (Table I).

Both sexes were equally represented with 52% female and 48% male. Majority of all cases treated, 72%, came from small towns where they are likely to be in con-

TABLE I - Demographic data in the patients submitted to the conservative and radical surgical treatment for liver hydatidosis.

	Conservative treatment N 29		Radical treatment N 21		Tot. N 50	
	Average	Stand. Dev.	Average	Stand. Dev.	Average	Stand. Dev.
Age	51.4	19,6	56.8	15.8	53,6	18.4
	N	%	N	%	N	%
Female	14	48.3	12	57.4	26	52
Male	15	51.7	9	42.8	24	48
Residence in A						
Small Town	20	68.9	16	76	36	72
Farmer	3	10.3	2	9.5	5	10
Butcher	1	3.4	0	0	1	2
Breeder	1	3.4	0	0	1	2
Housewife	4	20.7	7	33.33	13	26
Worker	5	17.2	0	0	5	10
Student	2	6.9	1	4.76	3	6
Other	9	31.03	12	57.14	11	22

TABLE II - First symptoms of presentation of the liver hydatidosis in the two group of patients.

	Conservative treatment N 29		Radical treatment N 21		Tot. N 50	
	N	%	N	%	N	%
Pain	8	27.6	12	57.1	20	40
Fever	8	27.6	4	19.0	12	24
Icterus	4	13.8	1	4.7	5	10
Itch	2	6.9	0	0	2	4
Tot.	22	75.8	17	80.9	39	78

tacts with farms as well as grazing and domestic livestock. Only 28% of cases came from large urban areas in which the cycles of production and distribution of meat and plant foods are subjected of regulation. Among those cases studied, we found 7 patients who presented an occupational exposure as an additional risk factor (5 farmers, 1 butcher, 1 breeder). This demonstrates that the disease has a close relationship with the patients' professions and their geographical origin.

Patients came to the General and Urgent Surgery OU of Policlinic of Palermo with several admission diagnosis as such abdominal colic, biliary colic, obstructive jaundice, abdominal mass, cholangitis, and shock. First symptoms of the disease such as pain, fever, icterus and itching were taken into account as 42% of patients were symptomatic (Table II). 57.1% of patients operated with radical technique referred pain, 19% fever, 4% jaundice, while itching was missing. On the other hand, in the conservative techniques pain and fever were present at 27.6% respectively, while slightly lower percentage showed jaundice (13.8%) and itching (6.9%) (Table II). The shelters were performed in urgency at 24% of total cases. Among patients who subsequently underwent surgery with a radical technique, 33% experienced this type of admission, while 17% were operated with conservative techniques (Table III).

TABLE III - Hospital reception modality for the patient then treated with the two different treatments.

	Conservative treatment N 29		Radical treatment N 21		Tot. N 50	
	N	%	N	%	N	%
Urgency	5	17.2	7	33.3	12	24
Election	24	82.8	14	66.6	38	76

TABLE IV - Characteristics of the cysts.

	Conservative treatment N 29		Radical treatment N 21		Tot. N 50	
	N	%	N	%	N	%
Left	8	27.6	9	42.8	17	34
Right V-VIII	8	27.6	7	33.3	15	30
Right VI-VII	15	51.7	7	33.3	22	22
N.1	18	62.0	13	61.9	31	62
N. > 1	11	37.9	5	23.8	16	32
Dm<10	13	44.8	12	57.1	25	50
Dm>10	16	55.1	6	28.6	22	44
Active Cysts	21	72.4	10	47.6	31	62
Transitory Cysts	6	20.7	4	19.0	10	20
Inactive Cysts	5	17.2	7	33.3	12	24
Left Lobe+ < 10 Cm	10	34.5	15	71.4	25	50

Cyst characteristics in the two groups of patients included left or right lobe localization, number of cysts in the liver, their dimension, the WHO classification of these cysts in the state of active (transitory or inactive) (listed in Table IV). The correlation found between cysts in left lobe and small and the chosen technique was a variable highly useful for the analysis. The group that underwent surgery with conservative techniques mostly had a right location of the cysts (79.3%) and only 27.6% of total cases had a left location. Notably, exceptional cases presented double lobe localization of a single cyst or the presence of multiple cysts in different lobes. Among patients operated with radical technique, 42.8% of cysts were on the left and 66.6% on the right. There was presence of multiple cysts within the left lobe where 57% of cysts had a diameter less than 10 cm, while those bigger than 10 cm in diameter were located mostly on the left lobe (Table IV).

Table V describes the presence of complex cysts in relation with contiguity with vessels or biliary duct in both groups. Complex cysts included broken in mayor biliary ducts or in peritoneo, compressing surrounding organs, relapsed. Most of the patients operated with conservative techniques presented one or more cysts complicated by rupture into the biliary tract or the peritoneum (44.8%), while opposite results interested patients operated with radical technique, only 9.5%. The proximity to vascular and bile structures was presented in patients treated with conservative and radical technique, 37.9% and 13% respectively (Table V). Cysts were already relapses on 18% of treated patients that undergone surgery for hepatic hydatid disease in the segment where there was a new presentation of the cyst. A marked percentage of these patients were operated again choosing mostly the conservative techniques (78%). Among patients operated with this technique 31% had a relapse (Table V). Indeed, the first Fisher's Exact Test shows a $p \leq 0.001$ (thumb n. 9), which revealed that a specific surgical technique (A: Radical, B: Conservative) is chosen according to the characteristics of cysts complexity. In Table VI post-operative morbidity, hospital staying

TABLE V - The occurrence of complex cysts in the two series of patient.

	Conservative treatment N 29		Radical treatment N 21		Tot. N 50	
	N	%	N	%	N	%
Complex Cysts	13	44.8	2	9.5	15	30
Broken In Mayor Biliary Ducts	10	34.5	1	4.8	11	22
Broken In Peritoneo	3	1.03	1	4.8	4	8
Compression	4	13.8	2	9.5	6	12
Recurrent Cysts	7	31.0	2	9.5	9	18
Cysts In Contiguity	11	37.9	2	9.5	13	26

TABLE VI - Occurrence of post-operative morbidity, days of hospital stay, additional treatment including ERCP, drainage in cavity, insert of Kehr or protective cholecystectomies and Albendazole therapy in the patient submitted at the two different treatments.

	Conservative treatment N 29		Radical treatment N 21		Tot. N 50	
	Average	Stand. Dev.	Average	Stand. Dev.	Average	Stand. Dev.
Stay in Hospital	26.5	16	21	12	24	14
	N	%	N	%	N	%
Post-Operative Complicances	9	31.0	0	0	9	18
Ercp/Drainage in Cavity' Residual/ Kehr/Colecistectomia Therapy	10	34.5	6	19.1	16	32
	9	31.0	5	23.8	14	24

TABLE VII - Patients dead at the time of follow up about 40 patients called for a control in the last part of the study.

Follow-up	Conservative treatment N 24		Radical treatment N 16		Tot. N 40	
	N	%	N	%	N	%
Deads	2	8.3	5	31.3	7	17.5

TABLE VIII - Presence of recurrence of hydatidic cyst at the moment of the follow up.

Follow-up in alive	Conservative treatment N 22		Radical treatment N 11		Tot. N 33	
	N	%	N	%	N	%
Recurrence	9	40.9	2	18.2	11	33.3

and additional therapies are listed. By applying table of thumb n. 10, the second Fisher's exact test showed that radical techniques are not related to post-operative morbidity ($p \leq 0.004$). The follow up was performed on 40 out of 50 patients, as a consequence of some unknown deaths at the time of the follow up (Table VII). The relapses in this series of patients are included in Table 8. Patients operated with conservative techniques following a follow-up were doubled than those experienced a radical technique, 22 and 11 in turn. 7 patients out of 40 passed away for unrecognized reasons, 2 of these belonged to the group undergoing conservative surgery

TABLE IX - Contingency table for the Exact Fisher's Test for evaluate the relation of independence between the chosen technique and the characteristics of the cyst.

	Technique A	Technique B	Total
Group 0	3	26	29
Group 1	18	3	21
Total	21	29	50

TABLE X - Contingency table for the exact fisher's test for evaluate the relation of independence between the chosen technique and the occurrence of post-operative complications.

	Technique A	Technique B	Total
Group 0	0	9	9
Group 1	21	20	41
Total	21	29	50

TABLE XI - Contingency table for the Exact Fisher's Test for evaluate the relation of independence between the chosen technique and the recurrence of disease.

	Technique A	Technique B	Total
Group 0	2	9	11
Group 1	9	13	22
Total	11	22	33

and 5 radical surgery (Table VII). By applying table of thumb n. 11, the third Fisher's exact test depicted that there is not relationship between the surgical technique adopted and the presence or absence of relapse as $p \leq 0.14$.

Discussion

When a hydatid cyst is diagnosed, treatment should be instituted to prevent complications such as infection, rupture of the cyst to the adjacent structures, or anaphylaxis, although most patients with hydatid cysts of the liver are asymptomatic or have few symptoms. In this regard, as Moreno (2009) stated, percentages of the starting symptoms of the disease in question varied among patients. Therefore, pain (40%), fever (24%), jaundice (10%), pruritus (4%), dyspnea, dyspepsia, and oppressive weight in right upper quadrant (Table II). It is interesting to note that as in Akbulut's study (2010) only 42% of our patients were symptomatic which 24% of recovering took place in urgency. On the contrary, Malik (2010) and Tagliacozzo (2011) found higher percentages with only 9.4% were asymptomatic.

Although numerous therapeutic approaches have been developed, including medical therapy, PAIR, endoscopic, surgery, radio ablation⁷⁻¹⁴, there is no "best" treatment option for hepatic hydatidosis and no clinical trial has compared all the different treatment modalities, including "Watch and Wait." It is true that treatment indications are complex and are based on cyst characteristics, available medical/surgical expertise and equipment, and adherence of patients to long-term monitoring^{18,23}. However, surgery tends to be the most effective treatment especially in endemic areas where conservative approach is the most feasible^{8,33}. Ideally, the surgical approach should provide a refine study on the patient uniqueness and not approaching him/her in an uniquely way, correlating biological age, stage of disease according to prognostic classifications, size, location, proximity relationships, complications, compression in selecting the best surgical option.

It is generally accepted that surgery is indicated for no complicated cysts with a peripheral location in a fit patient. Small cysts (≤ 4 cm) deep located in the parenchyma of the liver, if no complicated, can be managed conservatively³⁴. This is mainly due to the difficulty of approaching these deeply located cysts. According to Sayek (2001) the Intraoperative ultra-sonography is a helpful tool in this situation and we had used when necessary.

Despite reporting good results with percutaneous drainage and some progress in medical treatment, surgery is still the treatment of choice for uncomplicated hydatid disease of the liver¹⁵. Thus, surgery tends to be the first choice for complicated cysts. In the liver, for instance, it is indicated for (1) removal of large CE2-CE3b cysts with multiple daughter vesicles, (2) single liver cysts situated superficially that may rupture spontaneously or as a result of trauma when PTs are not available, (3) infected cysts, again, when PTs are not available, (4) cysts communicating with the biliary tree (as alternative to PT) and (5) cysts exerting pressure on adjacent vital organs¹⁸. According to Brunetti (2010) et al.¹⁵⁻¹⁹, surgery is contraindicated in patients which general contraindications for surgery apply on inactive asymptomatic cysts, difficult to access cysts, and very small cysts. Moreover, the objectives of surgical treatment are (1) inactivating scolices, (2) preventing spillage of cyst contents, (3) eliminating of all viable elements of the cyst, and (4) managing the residual cavity of the cyst.

As aforementioned, different surgical treatments are adopted according to the disease, patient and surgeon. The spectrum of the surgical procedure varies from a radical respective approach (pericystectomy or hepatic resection) to a conservative approach (drainage or obliteration of the cavity, or both)¹⁸. The association of pre and post-operative medical therapy with albendazole is always related to intra-operative antibiotic prophylaxis. In addition, patients with jaundice were managed with pre-operative ERCP to resolve possible biliary obstruction²⁴⁻²⁸.

According to Akbulut (2010), conservative surgery is recommended for the elderly, those with high ASA levels, deeply located cysts (10 cm), more than one cyst at the same time, cysts located in both lobes and in the liver posterior segment. While radical surgery can be carried out, by experienced hepatobiliary surgeons, on younger patients, in cysts located in the anterior superior liver and in the left lobe lateral segment, in those with exophytic location and cysts ≥ 5 cm in diameter. The same Akbulut states that it is preferable to use a conservative approach when possible on patients who develop recurrence, as there are more problems associated with a second operation, such as mortality, damage to the gallbladder, and a lengthy post-operative stay. Hence, Brunetti (2010) finds that also conservative surgery is especially suited for endemic areas where the operations are performed by general surgeons. No special equipment is required and liver tissue is neither entered nor resected even though patients should be referred to recognized, reference and national/regional CE treatment centers, whenever available. Following these theories, 78% of these types of cysts were surgery through conservative techniques. Besides, results showed that cysts located in the left lobe along with small cysts are more frequently in patients operated with radical techniques, features typify 71% of presentations as figure n. 3 depicts. On the other hand, conservative techniques are adopted for complicated, large, contiguous, relapses cysts not on the left lobe. However, mostly had a right location of the cysts (79.3%), while only 27.6% had a left location. Notably, exceptional cases presented double lobe localization of a single cyst. Through years, more conservative techniques have been used since marsupialization, cystectomy and subtotal cysto-pericistectomy. These techniques are easy and fast due to lower intra-operative risks and sustainable operation costs. However, they are burdened by relatively high risks of post-operative complications¹⁷; results showed a 31% of the group surgery, and recurrences, estimated 41%. Opposite, radical treatment, including hepatectomy, may be justified due to the reduction of post-operative complications and relapses³⁵.

Careful preservation of the healthy liver parenchyma should be always pursued even in patients with good liver, as well as in hydatidic disease, where in most cases the parenchyma on which you work is healthy. Radical techniques which are the total cysto-pericistectomy and hepatic resection enable the entire excision of the parasite and fibrotic reaction of the liver, leaving only the healthy hepatic parenchyma where any bile and vascular connections are easier to control³⁶. This avoids post-operative complications and recurrences. Conversely, if the cleavage plane is not respected, lacerations and bleeding may occur. This is likely to happen when cyst close relations are in proximity to major vascular and/or bile structures. These techniques are easily to perform on surface cysts, as a consequence executive actions become more difficult than with conservative techniques³⁵.

In spite of resection is indicated for the treatment of large intrahepatic hydatid cysts with the advantage of achieving a radical treatment of the lesion without leaving any bile communications. Many specialists use the world unequal in regards to the treatment of a benign lesion which leads to specific levels of morbidity and mortality^{6,46}. Performing limited resections or anatomical resections depends on the disease, its anatomical location, the patient's hepatic reserve and the surgeon experience. Hence, complications tend to be bile leaks, bleeding, biliary stenosis or obstruction, liver failure.

Nevertheless, results proved no post-operative complications within the group treated with radical techniques. As aforementioned, proper surgical technique, including radical techniques should be chosen by reference related to the patient, disease, facilities for resuscitation/recovery and surgical team. In spite of most of the studies published find a prevalence towards conservative techniques to laparoscopy, developed in 1992³⁷⁻⁴⁰, we have been considering the possibility of using laparoscopic techniques alongside traditional open surgery as a possible option. This choice is based on those concerns about technical difficulties and risks that laparoscopic techniques involve, which have not allowed a large and shared use, mainly in early stages of surgery.

Generally speaking, post-operative mortality ranges from 0% to 8%, and this is related to the presence of complicated cysts. Patients being operated for hepatic hydatid disease have usually a prolonged hospital stay as morbidity is an important factor.

Several factors are likely to influence the occurrence of complications. A cyst more than 10 cm in diameter containing purulent bile and biliary fistulas, highly close to the dome liver or in areas where it is difficult to inspect, can be the case. Those complications are more frequent in cases of multiple or complicated cysts, usually treated with conservative technique³³. On one hand, the current study supports this thesis. Therefore, it found that cysts operated with conservative technique were especially complicated cysts (26% of total) or adjacent to vascular-biliary structures (22% of total), large (32% of total) or upper localized, close to the diaphragm (18% of total). On the other hand, results need to be contextualized and surgical skills considered⁴¹.

Tagliacozzo (2010) in his study states that post-operative morbidity is more than uncomplicated cysts, and long term results are equally good. This explains why radical techniques are likely to deliver good results when used on cysts of small size, easy to access, with thick and / or calcified pericystio³³. In our case, post-operative morbidity showed the highest percentage in the group of patients treated with conservative techniques showed higher percentage of post-operative morbidity rather than those treated with radical techniques, with 31% versus 0% ($p \leq 0.004$) (Table VI). Despite being in line with the results of the international literature^{30-32,35,41-43}, findings are closely related to the anatomi-

cal-clinical framework of the cysts, even though in some cases there is not a statistical difference in post-operative complications³⁰.

Recurrence was found likely possible and variable with a percentage between 2% and 10% after open interventions. Additionally, this may occur even after 10-15 years and it might be caused by unrecognized cysts at the time of the surgery, then not treated; sub-locations, from the presence of exophytic daughter cysts after conservative treatment; hydatid spillage of not sterile liquid. However, the recurrence of the disease was not easy to demonstrate in many cases. In fact, ETG and CT images may not always be of unique interpretation. Alternatively, the presence of these images, with persistently high levels of specific antibody title or their secondary elevation 6 - 12 months after surgery are indicative of recurrence in progress. Risk of relapse requires close clinical surveillance based on serology, chest X-ray and abdominal ETG, and the pace and duration of the surveillance are variable³³. Likewise, percentages regarding patients suffered the recurrence of the disease in a long term were higher in case of conservative surgery (41%) rather than for radical surgery (18%) (Table VIII). We found a statistical independence of the surgical technique with the presence or absence of relapse. As a result, data do not support completely Akbulut's theory (2010) which states that radical procedures are associated with lower risk of recurrence of the disease, while conservative procedures are easier to perform but have a higher likelihood of reappearance. Recurrence is usually a consequence of inadequate cyst removal or previously undetected cysts as percentages show from 2% to 25%¹⁰.

Botrugno (2010) states that radical surgery is the most effective treatment for complex hydatid cysts above all if it is used in specialized operative units. Interestingly, even though there is a low level of evidence to prefer one over the other (L 2, G a)⁸, radical techniques are considered an extreme technique for benign diseases¹⁵, while conservative techniques are considered less extreme and a way of selection by many specialists^{1,44}.

Conclusions

In a non-specialized HBP unit, in a medium endemicity region, the treatment of hepatic hydatidosis, could involve both radical and conservative surgical techniques, favoring the resection of small or in the left lobe cysts and operating more complex cysts with conservative techniques. Results obtained confirm what has been previously stated by other studies. Therefore, conservative techniques, more easy to perform as they not require special equipment, are more used in the treatment of cysts presenting complications from the outset, massive size, recurrent or in proximity to major vascular or bile structures, but they are also more correlated with the onset of post-operative morbidity. Interestingly, in con-

trast to previous studies, findings demonstrate that the number of relapses is not related to the technique used. However, both techniques should be implemented alongside each other to obtain the best possible results, in presence of surgical skill and intensive care services in continuously contact with surgical facilities, leading the surgical act to the eradication of the disease; this will give to our patients the possibility of living longer and longer disease-free without relapses.

Acknowledgments

We are thanks to the Dr Sergio Mazzola for the statistical assistance and to the Dr Sahara Seidita and Dr Roberto Canale for the English version revision

Riassunto

L'idatidiosi epatica continua ad essere un problema di salute pubblica, specialmente nell'area mediterranea. La chirurgia segue essendo il trattamento più efficace nella risoluzione delle complicanze e nella prevenzione delle recidive. Questo studio retrospettivo ha l'obiettivo di fornire indicazioni ragionate di trattamento chirurgico comparando le tecniche conservative e le radicali.

Tra il 2000 ed il 2011 sono stati operati per idatidiosi epatica 50 pazienti, 21 con trattamento radicale e 29 conservativo.

La tecnica chirurgica conservativa è stata adottata per cisti complicate, di grandi dimensioni, contigue, recidive e non a sinistra; mentre la tecnica chirurgica radicale si è adottata per cisti di piccole dimensioni o a sinistra ($p \leq 0,001$). Le complicanze post operatorie sono state percentualmente più alte nel gruppo di pazienti trattati con tecnica conservativa rispetto alla radicale, 31% vs 0% ($p \leq 0,004$). Al follow-up si è mostrata una indipendenza della tecnica chirurgica dalla presenza o meno di recidiva ($p \leq 0,14$) nella nostra serie.

In conclusione, in un centro non specialistico ed in un intorno di medio-alta endemia, suggeriamo trattamenti radicali per cisti localizzate nel lobo sinistro o di piccole dimensioni, mentre conservativi per cisti del lobo destro specialmente se complicate; dunque la presenza di maggiori complicanze post-operatorie nei trattamenti conservativi potrebbe essere correlato al più complesso quadro anatomo-clinico.

References

1. Budke CM: *Global socioeconomic impact of Cystic echinococcosis*. Emerg Infect Dis, 2006; 12(2):296-303.
2. Dakkak A: *Echinococcosis/hydatidosis: A severe threat in Mediterranean countries*. Veterinary Parasitology, 2010; 174:2-11.
3. Giannetto S, Poglayen G, Brianti E et al.: *An epidemiological updating on cystic echinococcosis in cattle and sheep in Sicily, Italy*. Parasitologia, 2004; 46(4):423-24.
4. Garippa G, Manfredi MT: *Cystic echinococcosis in Europe and in Italy*. Vet Res Commun, 2009; 33(1):35-39.
5. Punzo C, Mastrogiacomo M, Germinaro C, et al.: *Hepatic hydatidosis in Puglia: Analysis of the hospital discharge cards in the years 1996-2000*. Ann Ital Chir, 2002; 73(6):605-09.
6. Gruttadauria S, Basile F, Marino G, et al.: *Development in diagnosis and treatment of hepatic echinococcosis in a surgical department of a Mediterranean centre over a 20 years period*. Ann Ital Chir, 2000; 71(1):99-104.
7. Who-Iwge: *Guidelines for treatment of cystic and alveolar echinococcosis in humans*. Geneve: WHO 1996.
8. Dziri C, Haouet K, Fingerhut A: *Treatment of Hydatid Cyst of the Liver: Where is the Evidence?* World J Surg, 2004; 28:731-36.
9. Saimot AG: *Medical treatment of liver hydatidosis*. World J Surg, 2000; 25:15-20.
10. Dziri C, Haouet K, Zaouche A, et al: *Comment traiter un kyste hydatique du foie non compliqué?* Annales de chirurgie, 2005; 130: 249-51.
11. Vuitton DA, Who-Iwge: *Coordinating board of the WHO-IWGE*. Parasitologia, 1997; 39: 349.
12. Filice, WHO-IWGE: *Pair for the treatment of cystic echinococcosis*. WHO-IWGE meeting, Lisbon, 1997.
13. Neumayr A, Troia G, De Bernardis C, Tamarozzi F, Goblirsch S, et al: *Justified concern or exaggerated fear: The risk of anaphylaxis in percutaneous treatment of cystic echinococcosis. A systematic literature review*. PLoS Negl Trop Dis, 2011; 5(6):e1154.
14. Menendez Da Silva A: *Hydatid cyst of the liver-criteria for the selection of appropriate treatment*. Acta Tropica, Elsevier, 2003; 85:237-42.
15. Sayek, Onat D: *Diagnosis and treatment of uncomplicated hydatid cyst of the liver*. World Journal of Surgery, 2001; 25(1):21-27.
16. Dziri C, Haouet K, Fingerhut A, et al.: *Management of cystic echinococcosis complications and dissemination: Where is the evidence?* World J Surg, 2009; 33(6):1266-723. Review.
17. Brunetti E, Kern P, Vuitton DA, et al: *Expert consensus for the diagnosis and treatment of cystic and Alveolar Echinococcosis In Humans*. Acta Tropica, 2010; 114:1-16. Review.
18. Menendez Da Silva A: *Human Echinococcosis: A neglected Disease*. Gastroenterology Research and Practice, 2010; Article ID 583297.
19. Zaouche A, Haouer K: *Traitement chirurgical des kystes hydatiques du foie. EMC, Techniques chirurgicales*. Appareil digestif, 2006; 40-775.
20. Gharbi HA, Hassine W, Brauner MW, et al.: *Ultrasound examination of the hydatid liver*. Radiology, 1981; 139:459.
21. WHO IWGE: *International classification of ultrasound images in cystic echinococcosis for application in clinical and field epidemiological setting*. Acta Tropica, 2003; 85(2):253-61.
22. Kayaalp C, Bostanci B, Yol S, Akoglu M: *Distribution of hydatid cysts into the liver with reference to cystobiliary communications and cavity-related complications*. Am J Surg, 2003; 185:175-79.
23. Nardello O, Bortoletti G, Muggianu M, Conchedda M,

- Cagetti M: *Ecographic evaluation of the vitality/fertility in the hepatic hydatidosis as indication for pericystectomy*. Ann Ital Chir, 2006; 77(3):223-31.
24. Bouzidi A, Chehab F: *Traitement chirurgical des fistules bilio-kystiques d'origine hydatique. A propos de 83 cas*. J Chir, 1997; 134(3):114-18.
25. Skroubis G, Vagianos C, Polydorou A, Evangelos, et al: *Significance of bile leaks complicating conservative surgery for liver hydatidosis*. World J Surg, 2002; 26:704-08.
26. Sciumè C, Geraci G, Pisello F, Li Volsi F, Facella T, Modica G: *Treatment of complications of hepatic hydatid disease by ERCP: Our experience*. Ann Ital Chir, 2004; 75(5):531-53.
27. Sciumè C, Geraci G, Pisello F, Facella T, Vaglica R, Modica G: *Acute pancreatitis during liver hydatidosis: Treatment with ERCP and endoscopic sphincterotomy*. Ann Ital Chir, 2005;76(5):491-94.
28. Giordano G, Ialongo P, Amoruso M, Rizzo Mi, Divenere B, Bonomo Gm: *Obstructive jaundice caused by hydatid cyst rupture in main bile duct*. Ann Ital Chir, 1999; 70(5):763-66.
29. Moreno J, Tellez CJ, Pardo FJ: *Casos de hidatidosis en el departamento de salud 2 de la comunidad valenciana*. Rev Esp Quimioter, 2009; 22 (2):62-67.
30. Akbulut S, Senol A, Sezgin A, et al: *Radical vs conservative surgery for hydatid liver cysts: experience from single center*. World J Gastroenterology, 2010; 16(8):953-59.
31. Malik A, Bari S, Amin R, et al: *Surgical management of complicated hydatid cysts of the liver*. World J gastrointestinal Surgery, 2010; 27,2(3):78-84.
32. Tagliacozzo S, Miccini M, Bonapasta S, et al: *Surgical treatment of hydatid disease of the liver: 25 years of experience*. The American journal of surgery, 2011; 201:797-804.
33. Milicevic M: *Hydatid disease. Surgery of the Liver and Biliary Tract*, Blumgart, LH, 1994; 1121-150.
34. Filippou D, Tselepis G, Filippou V, et al: *Advances in Liver Echinococcosis: Diagnosis and Treatment*. Clinical Gastroenterology and Hepatology, 2007; 5:152-59.
35. Picardi N, Annunziata A, Bartolacci M, Di Rienzo M, Bottegoni G, Zuccarini F, Visini R: *The radical treatment of hepatic hydatidosis with deep and multiple locations. The role of new technologies particularly in the case of multiple locations*. Ann Ital Chir, 1999; 70(4): 529-38.
36. Botrugno I, Gruttadauria S, Li Petri S, et al: *Complex hydatid cysts of the liver: A single center's evolving approach to surgical treatment*. The American surgeon, 2010; 76(9):1011-15.
37. Chen W, Xusheng L: *Laparoscopic surgical techniques in patients with hepatic hydatid cyst*. The American Journal of Surgery, 2007; 194: 243-47.
38. Baltar Bolíve J, Baamonde De La Torre I, Concheiro Coello P, et al: *Tratamiento laparoscópico de los quistes hidatídicos hepáticos:técnicas y complicaciones postoperatorias*. Cir Esp, 2009; 86(1): 33-37.
39. Acarli K: *Controversies in the laparoscopic treatment of hepatic hydatid disease*. HBP, 2004; 6(4):213-21.
40. Foster EN, Hertz G: *Echinococcus of the Liver Treated with Laparoscopic Hepatectomy*. The Permanente Journal/Summer, 2010; 14:2.
41. Priego Priego P, Nuno J, López Hervàs P, et al: *Hepatic hidatidosis. Radical vs. Conservative surgery: 22 years of experience*. Revista española de enfermedades digestivas, 2008; 100(2):82-85.
42. Avgerinos ED, Pavlakis E, Stathoulopoulos A, et al: *Clinical presentation and surgical management of liver hidatidosis: Our 20 years' experience*. HBP, 2006; 8:189-93.
43. Fica A, Soto A, Slater J, et al: *Quince años de experiencia clínica con hidatidosis*. Rev Chil Infect, 2012; 29(2):183-91.
44. Ramia angel J M, Figueras Felip J: *Hidatidosis hepatica: Que cirugía debemos realizar?* CIR ESP, 2010; 88(1):1-2.
45. Yüksel O, Akyürek N, Çahin T, et al: *Efficacy of radical surgery in preventing early local recurrence and cavity-related complications in hydatid liver disease*. J Gastroenterol Surg, 2008; 12:483-89.
46. Nunnari G, Pinzone MR, Gruttadauria S, et al: *Hepatic echinococcosis: Clinical and therapeutic aspects*. World J Gastroenterol, 2012; 18(13):1448-458.