

An unexpected surprise at the end of a “Quiet” cholecystectomy.

A case report and review of the literature



Ann. Ital. Chir., 2012 83: 265-267

Vincenzo Fazio*, Giuseppe Damiano**, Vincenzo Davide Palumbo**, Gabriele Spinelli**, Antonio Scio**, Giovanni Tomasello**, Antonio Marrazzo**, Salvatore Buscemi**, Attilio Ignazio Lo Monte**

*Unità Operativa di Chirurgia d'Urgenza, ARNAS Civico, Palermo, Italy

**Dipartimento di Discipline Chirurgiche ed Oncologiche, Facoltà di Medicina e Chirurgia, Università degli Studi di Palermo, Italy

An unexpected surprise at the end of a “Quiet” cholecystectomy. A case report and review of the literature

BACKGROUND: *Anatomic unexpected variations in biliary tree may be discovered during laparoscopic cholecystectomy.*

CASE REPORT: *A 57-year-old man was admitted for abdominal pain, vomiting and mild jaundice. Abdominal ultrasonography revealed a gallbladder containing multiple stones and biliary sludge. All pre-operative investigations showed no anatomical variations in extrahepatic biliary tree. During surgical intervention an accessory extrahepatic duct, connecting the IV segment of the liver to the fundus of gallbladder, was discovered.*

CONCLUSIONS: *Pre-operative routine investigations for gall stones diseases may not reveal anatomic variations of biliary tree.*

KEY WORDS: Accessory cystic duct, Cholelithiasis, Laparoscopic cholecystectomy.

Introduction

Variations in the anatomy of the extrahepatic biliary tree have been recognized for a long time. However, a remarkable consideration of the surgical anatomy of the area started with the advent of cholecystectomy in 1882. It is difficult to estimate precisely the incidence of some of the common variations because the most them are not recognized because the surgical operation as often they are asymptomatic, and at autopsy they are easily overlooked unless pathologists seek them deliberately. The anatomic variations of intra- and extrahepatic bil-

itary ducts have been described as aberrant cystic ducts, aberrant hepatic ducts, accessory intrahepatic ducts, and accessory extrahepatic ducts, as depicted by Picardi at al¹. We report a case of a rare accessory cystic duct connecting the fundus of gallbladder to the medial segment of the left lobe of the liver (segment IV).

Case report

A 57-year-old man was admitted to the hospital with a 24 hours history of epigastric pain diffuse to the right upper abdominal quadrant, nausea, vomiting, and mild jaundice. Past medical history was unremarkable. Laboratory investigations confirmed the presence of jaundice. Abdominal ultrasonography revealed a gallbladder containing multiple stones and biliary sludge. Endoscopic ultrasonography (EUS) revealed a slightly increased-size common bile duct (7 mm) containing biliary sludge. A conventional magnetic resonance cholangiography (MRC) was performed: no anatomical abnormalities

Pervenuto in Redazione Ottobre 2010. Accettato per la pubblicazione Novembre 2010

Correspondence to: Attilio Ignazio Lo Monte, Associate Professor of Surgery, Dipartimento di Discipline Chirurgiche ed Oncologiche, Università degli Studi di Palermo, Facoltà di Medicina e Chirurgia, Via del Vespro, 129 90127 Palermo, Italy (E-mail: attilioignazio.lomonte@unipa.it)

resulted on. Computed tomography (CT) and endoscopic retrograde cholangiopancreatogram (ERCP) showed gallbladder stones, but no anatomical variations. Furthermore, a sphincterectomy was performed. During cholecystectomy an accessory cystic duct, connecting the IV segment of the liver to the fundus of gallbladder, was

discovered (Fig. 1), isolated (Fig. 2), clipped (Fig. 3), and divided. Recovery was uneventful and the patient was discharged at third post-operative day.

Discussion

Less than 10% of accessory ducts can be found near gallbladder body or fundus^{2,3}. Both aberrant and accessory ducts are considered as anomalies because they are not present in the most frequent anatomic arrangements. Aberrant ducts are located outside the prevailing anatomic location⁴; they are not supernumerary and their occlusion results in obstruction of bile flow from the part of the liver which they drain. Accessory bile ducts are auxiliary or supernumerary; consequently, their occlusion does not obstruct bile drainage. Accessory bile ducts are uncommon. Anatomical variations of biliary tree have been encountered in 10% of cases as a result of its complex embryological development^{1,5}. Anatomical variations of the cystic duct have usually no clinical significance, occurring in 18-23% of cases⁶. A review of world literature has classified anomalies of cystic duct anatomy into three types: "Y" type, "H" type and trabecular type^{7,8} (Fig. 4). The latter is the best model that fits in better our case. The use of different imaging techniques, such as CT-scan, PTC, ERCP, intraoperative cholangiography (IOC) and MRCP, permits the depiction of the normal anatomy as well as pathological aspects of the biliary tree. Although the visualization of the accessory extrahepatic ducts is possible with US and CT-scan, CT cholangiography is optimal in demonstrating biliary anomalies with a high success rate (97%)⁹. Recent studies have demonstrated that three-dimensional helical computed tomography - CT cholangiography is clinically useful in preoperative assessment of the anatomic variations, compared with ERCP and MRC, reducing the risk of complications and the operative time¹⁰. In a study of Hirao et al., MRC demonstrated a 56% of detection rate of aberrant bile ducts¹¹. More recently, the use of pre-operative conventional non-enhanced MRC in living donor liver transplantation has demonstrated a sensitivity of 95.5% in differentiating normal from variant anatomy of the biliary tree and a specificity

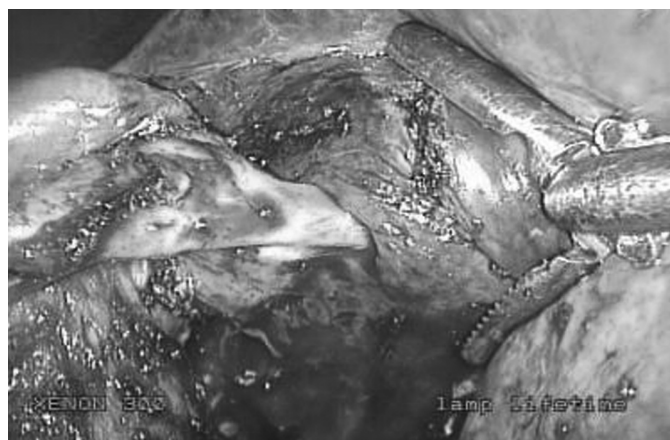


Fig. 1: The image shows the accessory cystic duct.



Fig. 2: Accessory cystic duct isolation.



Fig. 3: Accessory cystic duct clipping.

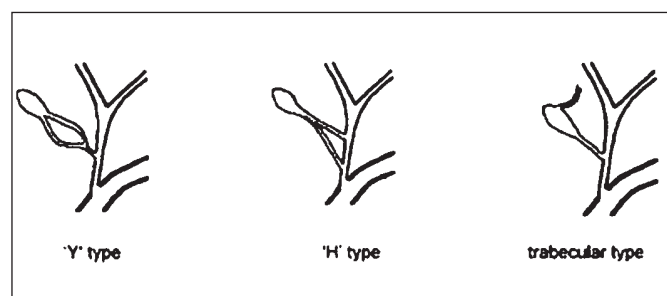


Fig. 4: Classification of double cystic ducts.

of 95.2%^{12,13}. In our case, CT-scan and MRC demonstrated absence of any anomaly in the anatomy of bile ducts. Furthermore, ERCP resulted negative, too. We suggest that these images were not sufficiently clear for the clinical purposes because the cystic duct or other biliary tree structure probably were so close to accessory bile duct that they overlapped each other. To date, there are persuasive population-based data indicating that the routine use of IOC reduces the risk of bile duct injuries by approximately 30%¹⁴. In our case IOC was impractical or could even cause injury. When the accessory bile duct was found, cystic duct was already clipped. Although cholangiography should have been performed, clips from cystic duct stump were not removed in order to avoid class I injury, according to Stewart-Way classification¹⁵. Recent studies confirm a controversial use of IOC with sensitivity of 95%, a specificity of 100%, a positive predictive value of 100%, and a negative predictive value of 99.4%¹⁶.

Conclusions

Routine investigations for gallstone disease do not detect all cases with variable anatomy. As in our case, ERCP and CT-scan did not reveal the accessory trabecular duct. IOC was not useful because accessory duct was identified after cystic duct was clipped. Besides pre-operative MRC was normal and morphology of accessory duct did not reveal any interruption of biliary tree. We suggest that a scrupulous dissection beyond the Calot's triangle should be performed during laparoscopic cholecystectomy in order to discover "Y" or "H" type double cystic duct and avoiding the potential risk of post operative bile leak. The same scrupulous dissection must be comply during the phase of separation of gallbladder from liver because of the potential presence of an accessory trabecular cystic duct. Finally the use of IOC must be limited only in selective case for the risk of bile duct injury.

Riassunto

INTRODUZIONE: Esistono molte imprevedibili varianti anatomiche dell'albero biliare che possono essere scoperte durante un intervento di colecistectomia laparoscopica.

CASO CLINICO: Un uomo di 57 anni viene ricoverato per dolori addominali, vomito e ittero lieve. L'ecografia addominale dimostra la presenza di calcoli e sabbia biliare in colecisti. Tutte le indagini pre-operatorie non hanno evidenziato variazioni anatomiche dell'albero biliare extraepatico. Durante l'intervento chirurgico viene scoperto un dotto accessorio extraepatico tra il IV segmento del fegato e il fondo della colecisti.

CONCLUSIONI: Le indagini di routine pre-operatoria per le litiasi possono fallire nel rivelare variazioni anatomiche dell'albero biliare.

References

1. Picardi N, Monti M, Pasta V, Nudo R, Costantini D, Cassano C: *Rare malformation of the bile ducts of surgical interest*. Ann Ital Chir, 1989; 60:399-404.
2. Ishikawa M, Tagami Y, Toyota T, et al.: *Can three-dimensional helical CT cholangiography before laparoscopic cholecystectomy be a substitute study for endoscopic retrograde cholangiography?* Surg Laparosc Endosc Percutan Tech, 2000; 10:351-56.
3. Schwartz SI: *Gall bladder and extrahepatic biliary system*. In: Schwartz SI, Shires GT, Spencer FC, editors. *Principles of surgery*. 6th ed. New York: McGraw-Hill, 1994, 1367-369.
4. Strasberg SM, Hawkins W: *Reconstruction of the bile duct: anatomic principles and surgical techniques*. In: Fischer JE, Bland KI, editors. *Mastery of surgery*. Vol. 1. Chapter 99. 5th ed. Philadelphia: Lippincott Williams & Wilkins; 2007.
5. Wu YH, Liu ZS, Mrikhi R, et al.: *Anatomical variations of the cystic duct: Two case reports*. World J Gastroenterol, 2008; 14:155-57.
6. Shaw MJ, Dorsher PJ, Vennes JA: *Cystic duct anatomy: An endoscopic perspective*. Am J Gastroenterol, 1993; 88:2102-106.
7. Lamah M, Karanjia ND, Dickson GH: *Anatomical variations of the extrahepatic biliary tree: Review of the world literature*. Clin Anat 2001; 14:167-72.
8. Todani T, Watanabe Y, Toki A, Ogura K, Wang ZQ: *Co-existing biliary anomalies and anatomical variants in choledochal cyst*. Br J Surg, 1998; 85:760-63.
9. Van Beers BE, Lacrosse M, Trigaux JP, de Cannière L, De Ronde T, Pringot J: *Noninvasive imaging of the biliary tree before or after laparoscopic cholecystectomy: Use of three-dimensional spiral CT cholangiography*. AJR Am J Roentgenol, 1994; 162:1331-335.
10. Izuishi K, Toyama Y, Nakano S, et al.: *Preoperative assessment of the aberrant bile duct using multislices computed tomography cholangiography*. Am J Surg, 2005; 189:53-55.
11. Hirao K, Miyazaki A, Fujimoto T, Isomoto I, Hayashi K: *Evaluation of aberrant bile ducts before laparoscopic cholecystectomy: helical CT cholangiography versus MR cholangiography*. AJR Am J Roentgenol, 2000; 175:713-20.
12. Song GW, Lee SG, Hwang S, et al.: *Preoperative evaluation of biliary anatomy of donor in living donor liver transplantation by conventional nonenhanced magnetic resonance cholangiography*. Transpl Int, 2007; 20:167-73.
13. Reinhold C, Taourel P, Bret PM, et al.: *Choledocholithiasis: Evaluation of MR cholangiography for diagnosis*. Radiology, 1998; 209:435-42.
14. Hobbs MS, Mai Q, Knuiman MW, Fletcher DR, Ridout SC: *Surgeon experience and trends in intraoperative complications in laparoscopic cholecystectomy*. Br J Surg, 2006; 93:844-53.
15. Way LW, Stewart L, Gantert W, et al.: *Causes and prevention of laparoscopic bile duct injuries: analysis of 252 cases from a human factors and cognitive psychology perspective*. Ann Surg, 2003; 237:460-69.
16. Machi J, Oishi AJ, Tajiri T, Murayama KM, Furumoto NL, Oishi RH: *Routine laparoscopic ultrasound can significantly reduce the need for selective intraoperative cholangiography during cholecystectomy*. Surg Endosc, 2007; 21:270-74.

