

## **Role of MDCT virtopsy in valuation of burned bodies and its comparison with traditional autopsy**

**Poster No.:** C-1156  
**Congress:** ECR 2014  
**Type:** Scientific Exhibit  
**Authors:** P. Carcione<sup>1</sup>, G. Lo Re<sup>2</sup>, A. Argo<sup>2</sup>, G. Carcione<sup>2</sup>, D. Picone<sup>2</sup>, S. Zerbo<sup>2</sup>, L. Scopelliti<sup>2</sup>, C. Sortino<sup>2</sup>, P. Procaccianti<sup>2</sup>; <sup>1</sup>PALERMO, PA/IT, <sup>2</sup>Palermo/IT  
**Keywords:** Forensics, Foreign bodies, Computer Applications-Virtual imaging, Computer Applications-Detection, diagnosis, CT, Forensic / Necropsy studies  
**DOI:** 10.1594/ecr2014/C-1156

Any information contained in this pdf file is automatically generated from digital material submitted to EPOS by third parties in the form of scientific presentations. References to any names, marks, products, or services of third parties or hypertext links to third-party sites or information are provided solely as a convenience to you and do not in any way constitute or imply ECR's endorsement, sponsorship or recommendation of the third party, information, product or service. ECR is not responsible for the content of these pages and does not make any representations regarding the content or accuracy of material in this file.

As per copyright regulations, any unauthorised use of the material or parts thereof as well as commercial reproduction or multiple distribution by any traditional or electronically based reproduction/publication method is strictly prohibited.

You agree to defend, indemnify, and hold ECR harmless from and against any and all claims, damages, costs, and expenses, including attorneys' fees, arising from or related to your use of these pages.

Please note: Links to movies, ppt slideshows and any other multimedia files are not available in the pdf version of presentations.

[www.myESR.org](http://www.myESR.org)

## Aims and objectives

The objective of virtopsy is not only to improve the objectivity of findings made by traditional autopsy but also to solve those cases that are difficult to solve with conventional post-mortem examination. Modern cross-sectional imaging and postprocessing techniques can provide strong forensic evidence for use in legal proceedings; particularly we want to show how it can supplement traditional autopsy of burned cadavers, helping finding the primary cause of the death, the presence of foreign bodies and the identification of the corpses.

## Methods and materials

To discover corpses identification and their cause of death represented a challenge for forensic pathologists, so it was decided to perform CT cross sectional imaging of the bodies.

We studied 4 burned cadavers (2 male and 2 female) with 128 row CT scan (SOMATOM Definition Flash 128, Siemens Healthcare) without contrast medium administration performed in cranio-caudal direction. The corpses underwent traditional autopsy before CT examination.

The results were examined at dedicated workstation with MPR and 3D reconstructions and compared with traditional autopsy data.

## Results

The correct examination of a burned or charred body is a challenge .

It is expected to give us objective information respect to:

- Identification
- Vital reactions indicating that the decedent had been alive when the fire started
- Cause of death and injuries
- Manner of death.

CT imaging particularly permitted us to correctly establish the cause of the death and to identify the bodies (Fig 1,2,3).

In two bodies death was caused by firearm wounds and burning was subsequent to death.

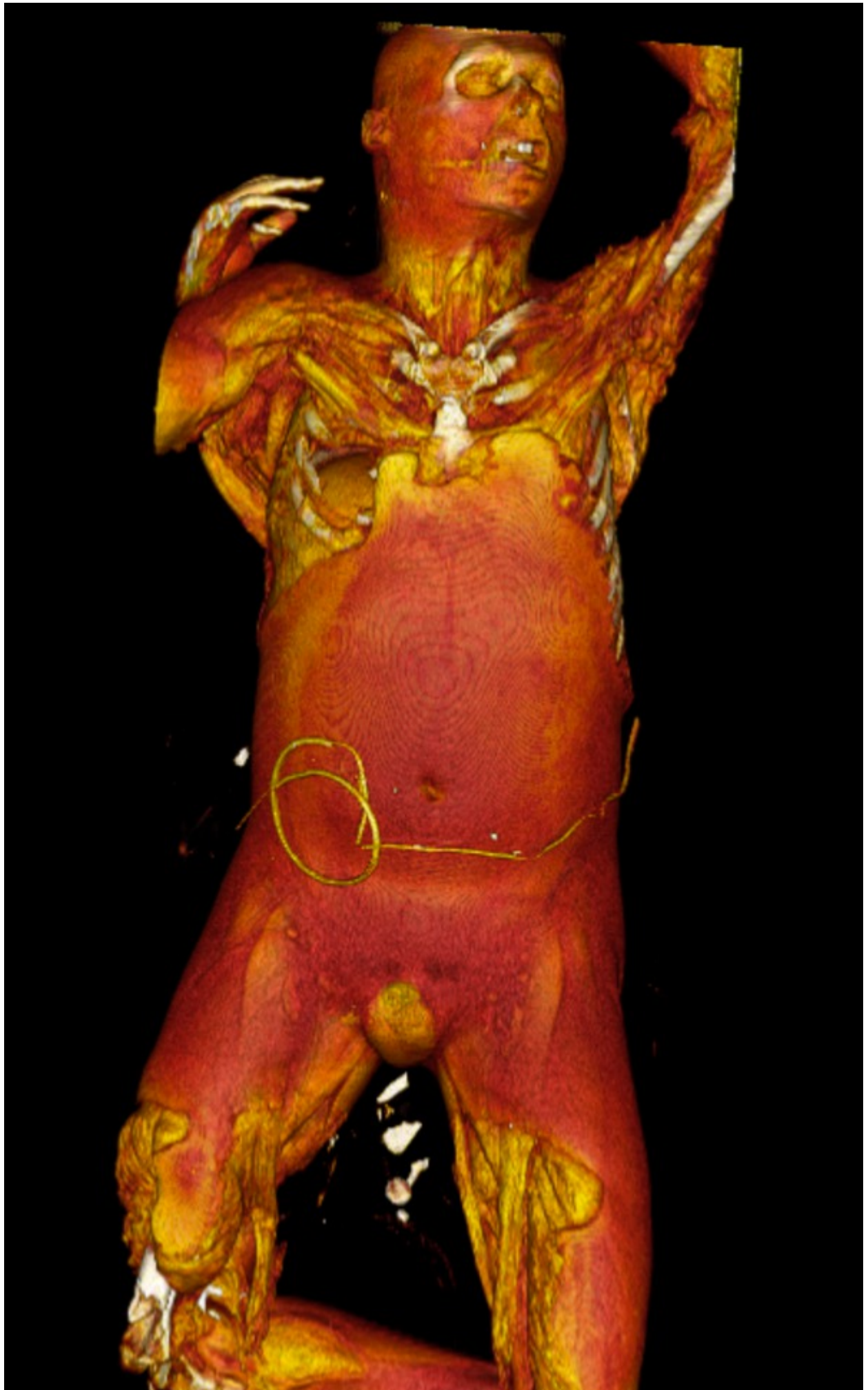
In every corpse CT findings were agreeing with traditional autopsy data, improving the detection of metallic foreign body in the two cadavers shot. Multidetector CT aided in correct identification of all wounds, and metallic fragment location was always precise.

In one corpse CT helped confirming body identification through a femur endoprosthesis recovery (multi-detector row CT can be of great help in the secure identification of charred bodies also thanks to other gross morphologic findings such as implants, plates, metal staples,

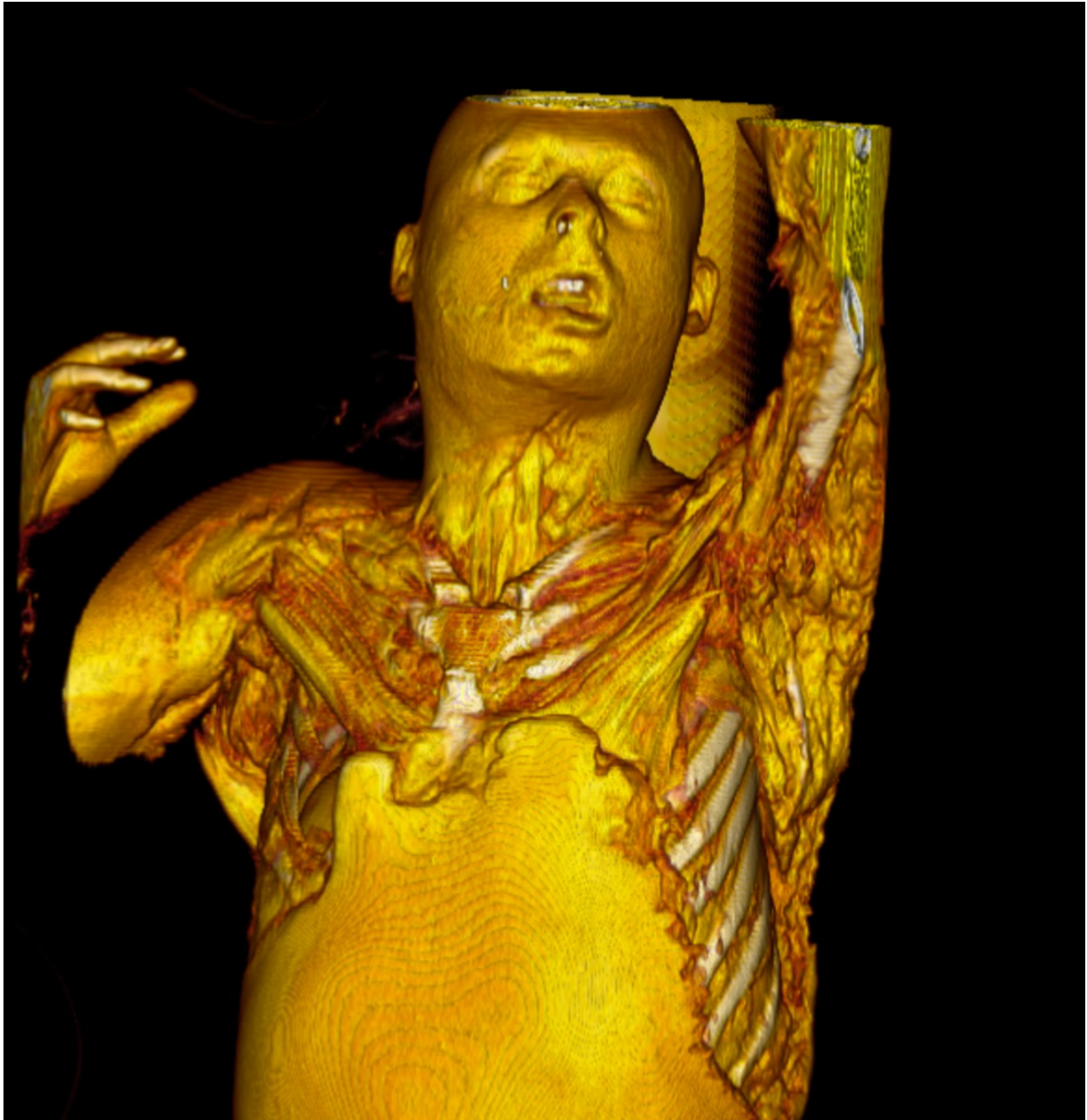and foreign bodies).

The gender designation of the charred bodies was easy based on the pelvic MSCT sections.

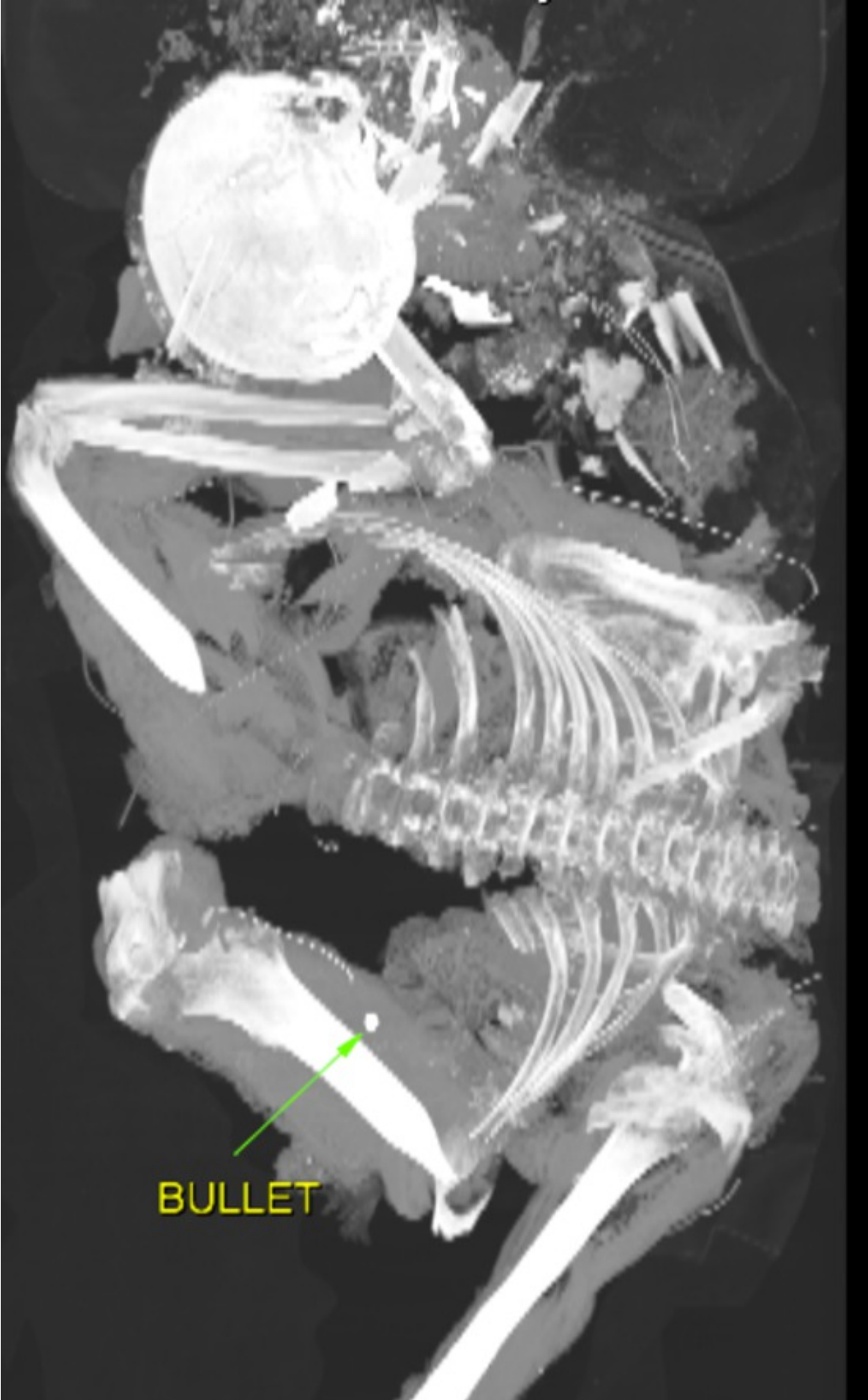**Images for this section:**



**Fig. 1:** Corpse 1: VR reconstruction of an unidentifiable burned body



**Fig. 2:** Corpse 1: particular of Fig.1



BULLET

**Fig. 3:** Corpse 2: discovery of the bullet and its precise location.

## Conclusion

It is important in forensic medicine to document and analyze in an objective way cause and manner of death and identification of deceased persons, in a comprehensible way for courtroom presentation, especially when traditional autopsy data are not conclusive.

Examination, interpretation and conclusion respect to identification, cause and manner of death are more difficult in burned bodies.

The documentation and analysis of postmortem findings with CT imaging and postprocessing techniques is investigator independent, objective, and noninvasive .

Post-mortem MSCT cross-sectional imaging helps traditional autopsy outdoing its limits, providing more information about primary cause of death and identification of the corpse, thus resulting useful in solving forensic disputation providing strong visual evidence for use in courtroom proceedings.

## Personal information

## References

VIRTOPSY: minimally invasive, imaging-guided virtual autopsy

Richard Dirnhofer, MD Christian Jackowski, MD Peter Vock, MD  
Kimberlee Potter, PhD Michael J. Thali, MD

RadioGraphics,2006, Vol 26: 1305-1333

Virtual autopsy: preliminary experience in high velocity gunshot wound victims

Angela D. Levy, Robert M. Abbott, Craig T. Mallak, John M. Getz, H. Theodore Harcke,  
Howard R. Champion, Lisa A. Pearse

Radiology, 2006, Vol.240: 522-528

Charred Body: Virtual Autopsy with Multi-slice Computed Tomography and Magnetic Resonance Imaging

Michael J. Thali, Kathrin Yen, Thomas Plattner, Wolf Schweitzer, Peter Vock, Christoph Ozdoba and Richard Dirnhofer



