

Laparoscopic management of an isolated left fallopian tube torsion due to twisted Morgagni Hydatid in a pre-menarcheal girl

Trattamento laparoscopico della torsione isolata della tuba uterina e dell'Idatide di Morgagni in epoca pre-menarcale

M. Cimador,¹ F. Siracusa,¹ M. Pensabene¹

Key words: *laparoscopy – tube torsion- premenarche.al age*

Abstract

Isolated torsion of fallopian tube, meanwhile uncommon, should be considered in diagnosis of pelvic and lower abdominal pain. US investigation is an useful diagnostic tool. A prompt diagnosis could avoid salpingectomy and preserve fertility. Laparoscopy, as the first approach, should be preferred.

We report a case of isolated tubal torsion occurring in a premenarcheal girl successfully managed by laparoscopy.

Riassunto

La torsione isolata della tuba di Falloppio, pur se di rara evenienza, dovrebbe essere considerata nella diagnosi differenziale del dolore acuto addominale e pelvico. L'ecografia gioca un ruolo di primaria importanza nella diagnostica di questi quadri clinici, in quanto una diagnosi precoce può evitare il ricorso alla salpingectomia e in casi selezionati preservare la fertilità. La laparoscopia diagnostica ed operativa dovrebbe essere preferita come primo approccio. Presentiamo un caso di torsione isolata della tuba in una giovane ragazza in fase di pre-menarca, trattata con successo con l'accesso laparoscopico.

Introduction

¹ Pediatric Surgical Unit, Dept. for Health Promotion and Mother & Child Care, Università di Palermo, Palermo, Italy

Indirizzo per la corrispondenza (Corresponding author):

MARCELLO CIMADOR

UO Chirurgia Pediatrica

Università di Palermo, Policlinico P.Giaccone,

Via A.Giordano,3

90127 Palermo

Phone +39 0916555466 Fax :+39 091-6555421

marcello.cimador@unipa.it

Isolated torsion of the Fallopian tube is an uncommon cause of abdominal pain, especially in non-reproductive age. Pain is mainly localized to the lower abdominal quadrants, and frequently occurs with nonspecific signs or symptoms. The torsion is usually unilateral, involving the right side more than the left one (ratio 3:1). The event shows a higher incidence in proximity of ovulation in postmenarcheal girls.

Ultrasound (US), magnetic resonance (MRI)^{1,2} and laparoscopic exploration^{3,4,5} are useful diagnostic tools. We report a case of isolated fallopian tube torsion due to a twisted Morgagni hydatid, laparoscopically managed, occurring in a 12-years old premenarcheal girl.

Case report

A 12-years-old girl was addressed to our attention because of severe abdominal pain occurred in preceding 24 h. The pain was localized in the right inferior abdominal quadrant, and appendicitis was suspected at history and clinical examination.

Her previous medical and surgical history was not significant. There was no history of abdominal trauma and no bowel or urinary symptoms. On physical evaluation, right abdominal pain and defense were present but no rebound tenderness was found. External genitalia were normally developed with Tanner stage-II features of breast and pubic hair, according to her age.

Body temperature of the patient was normal and white blood cell count was reported 9910/mL.

US investigation showed, on the right side, a cystic mass beneath the bladder measuring about 7 cm in transverse diameter. The evidence of minor cysts beside the mass suggested the diagnosis of acute right ovarian torsion. The left ovary was normal. The color-Doppler US clearly excluded anomalies of tubal blood flow on the right side, while blood flow was not detected on the left one. Tubal wall appeared thickened. Our patient underwent urgent explorative laparoscopy because right ovarian torsion was suspected.

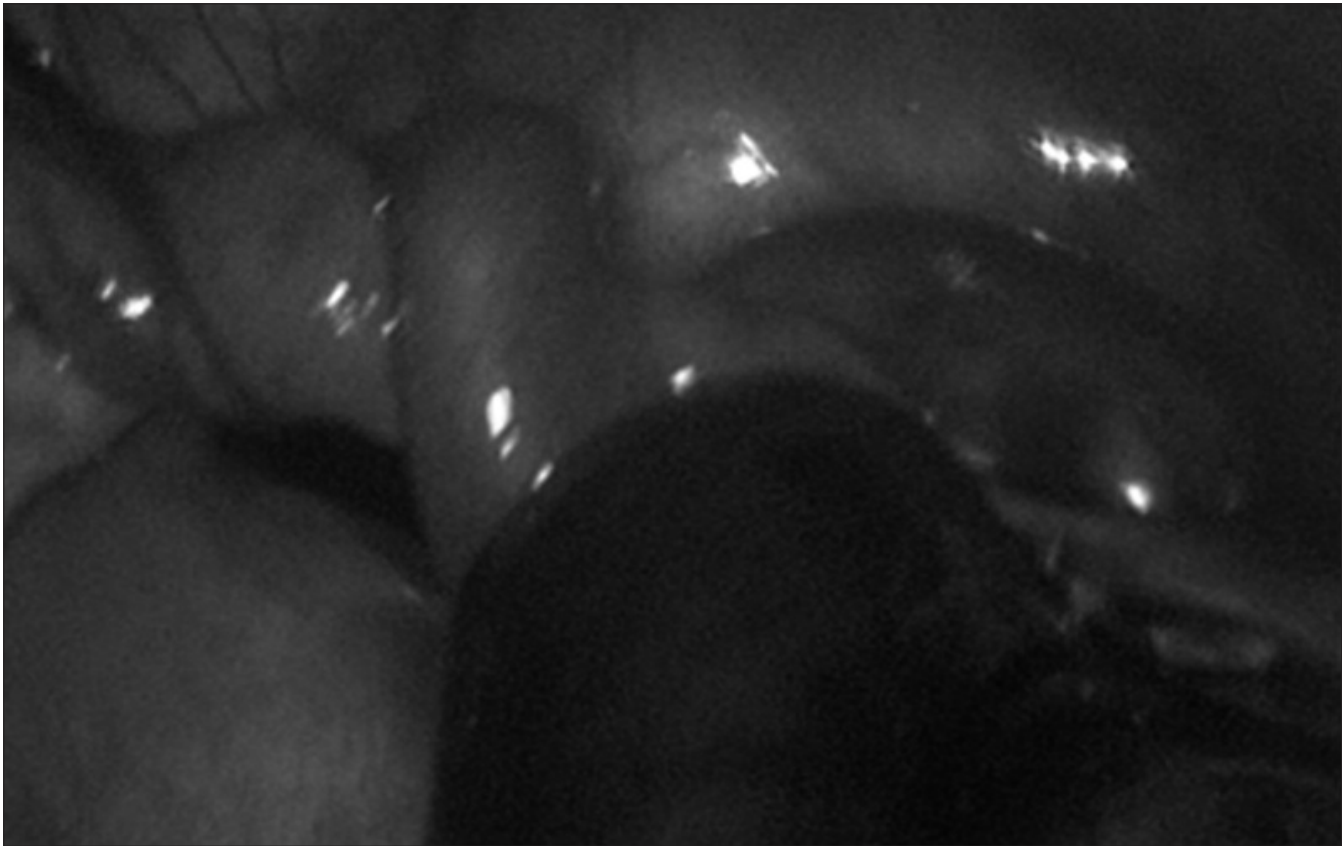


Figura 1.

Intra-abdominal hemorrhagic fluid was detected at laparoscopic exploration; this was found both in the Douglas and in the bladder-uterine space.

Unexpectedly, ovaries and right fallopian tube were normal.

The left fallopian tube was extremely long and the distal segment twice (720°) twisted (fig.1); moreover the twisted portion was also thickened for edema, hemorrhage and necrosis and it was found just on the right side, nearest the right ovary. Even the mesosalpinx was abnormally long. There were not any findings such as salpingitis, hydrosalpinx or inflammation, although necrotic degeneration of the fallopian tube might have changed the pathological pattern. Partial laparoscopic salpingectomy was performed because of the necrotic appearance of the mass.

Afterward, the laparoscopic exploration showed a small right paratubal Morgagni hydatid cyst (DT 1,5 cm). This was also removed. Post operative was uneventful, and patient was discharged on postoperative day 4. At 3-months follow-up, she remains well.

Hystopathology showed the presence of a Morgagni hydatid regarding the cystic formation at the end of the twisted fallopian tube associated to a hemorrhagic necrosis of the tubal walls.

Discussion

Adnexal torsion is a common gynecological emergency, with a prevalence of 3% in female population.⁶ Among these, isolated fallo-

pian tube torsion is rarely observed with the incidence being 1/1,5 per million cases.^{7,8}

The right tube is more frequently involved, with a 2-3:1 ratio; this is probably due to the cushioning effect exerted by sigmoid colon on the left fallopian tube.

The etiology of isolated tubal torsion is still uncertain. Different risk factors are involved. The most important anatomical intrinsic causes are the extreme tubal or mesosalpinx length, tubal abnormalities, hematosalpinx, hydrosalpinx, neoplasm. The presence of a Morgagni hydatid gives weight to the fallopian tube, so it is more susceptible to rotation. Other physiological abnormalities are abnormal peristalsis and hypermotility of the tube, tubal spasm due to drugs and intestinal peristalsis. Extrinsic causes are referable to neoplasm, pregnancy, adhesion due to previous abdominal surgery, trauma and inflammatory pelvic diseases.⁹ Episodes of tubal infection could be the cause of torsion due to venous congestion of tubal wall.

In most cases, teenaged patients report repeated episodes of abdominal pain in the lower quadrants, associated with nausea, vomiting, but without specific gastro-intestinal symptoms or signs. Similarly, urinary and gynecologic symptoms are infrequent.^{1,2,6,8}

The diagnostic approach is not standardized and differential diagnosis is therefore not always easy to implement. Differential diagnosis includes gastro-intestinal (acute appendicitis, inflammatory bowel disease) and genito-urinary tract diseases. The main pathologic differential picture includes hematosalpinx (due to obstructive

tubal dysplasia), tubal endometriosis, twisted ovary or twisted Morgagni hydatid, ruptured follicular cyst. Color-Doppler ultrasonography and MRI are important diagnostic tools, even if specificity is lacking. Color-Doppler US is helpful to detect the impaired tubal and/or ovarian blood flow. The maintenance of the flow, however, does not exclude the fallopian tube torsion,¹⁰ but suggests a more conservative surgical approach.

Laparoscopic exploration can be considered the best diagnostic and therapeutic approach, as in other adolescent and pediatric gynecological diseases.¹¹ In our case, laparoscopy allowed us to recognize tubal torsion and to easily perform a partial salpingectomy. This mini-invasive treatment reduced the postoperative pain and hospitalization, ensuring good cosmetic results. Our patients was discharged on postoperative day 4.

In conclusion, the isolated torsion of the fallopian tube is a rare occurrence, but it should be considered as a possible cause of abdominal pain in young girls, when intestinal or urinary anomalies are excluded. Color-Doppler study of ovarian and tubal blood flow should be always performed in case of abdominal pain in a premenarchal girls. The early diagnosis and treatment is necessary to avoid impairment of ovary and fallopian tube. In the presence of preserved tubal and ovarian blood flow at color-Doppler US study, conservative surgical treatment is advocated. Tubal and ovarian blood flow is partially preserved also when the tubal twist is not complete; in these case, if condition of adnexum seems preserved, conservative approach should be considered, but a careful await is needed. Surgical decision should be considered in order to preserve fertility especially in younger patients,¹² especially when blood flow is impaired, or when ovarian/tubal suffering is suspected. Laparoscopic exploration revealed as an useful tool to make the diagnosis and also to safely treat this condition. Laparoscopy should be considered as the first approach in case of suspected ovarian/tubal torsion.

References

- 1 Orazi C, Insera A, Lucchetti MC, Schingo PMS: Isolated tubal torsion: a rare cause of pelvic pain at menarche. Sonographic and MRI findings. *Pediatr Radiol* 2006; 36: 1316-18
- 2 Ghossain MA, Hachem K, Buy J-N, et al. Adnexal Torsion: magnetic resonance findings in the viable adnexa with emphasis on stromal ovarian appearance. *J Magn Reson Imaging* 2004; 20:451-462
- 3 Lineberry TD, Rodriguez H Isolated torsion of the fallopian tube in an adolescent: a case report. *J Pediatr Adolesc Gynecol* 2000;13:135-138
- 4 Rizk DE, Lakshminarasimha B, Joshi S Torsion of the fallopian tube in an adolescent female: a case report. *J Pediatr Adolesc Gynecol* 2002; 15:159-161
- 5 Goktolga U, Ceyhan T, Ozturk H, Gungor S, Zeybek N, Keskin U, Ciftipinar T, Baser I (): Isolated torsion of fallopian tube in a premenarcheal 12-years-old girl. *J. Obstet. Gynaecol. Res.* 2007; 33: 215-217
- 6 Longsdon VK Common problems in pediatrics and adolescent gynecology surgery. *Curr Opin Obstet Gynecol* 2001; 13:453-458.
- 7 Davis AJ, Feins NR: Subsequent asynchronous torsion of normal adnexa in children. *J Pediatric Surg.* 1990; 25:687
- 8 Dadhwal V, Gupta N, Gupta B, Deka D, Mittal S: Laparoscopic management of isolated fallopian tube torsion in a premenarchal 13-years-old adolescent girl. *Arch Gynecol Obstet* 2009; 279:909-910
- 9 Krissi H, Shalev J, Par-Hava I, Langer R, Herman A, Kaplan B. Fallopian tube torsion: laparoscopic evaluation and treatment of a rare gynecologic entity. *J Am Board Fam Pract* 2001;14:274-277
- 10 Pena J, Ufberg D, Cooney N, Denis AL: Usefulness of Doppler ultrasonography in the diagnosis of ovarian torsion. *Fertil Steril* 2000; 73:1047-50
- 11 Cimador M, Sireci F, Di Pace MR, De Grazia E. One-trocar, video-assisted stripping technique for use in the treatment of large ovarian cysts in infants. *J Pediatr Adolesc Gynecol.* 2010;23:168-71
- 12 Bider D, Mashlach S, Dulitzky M, et al: Clinical, surgical, and pathologic findings of adnexal torsion in pregnant and non-pregnant women. *Surg Gynecol Obstet* 1991; 173:363