

OXYTOCIN AND VASOPRESSIN EXPRESSION IN THE TURBINATES OF PATIENTS WITH CHRONIC SINUSITIS

Luana Lipari, Aldo Gerbino, Elvira Vittoria Farina

SUMMARY

Many peptides are present in the nasal mucosa, but few studies have investigated the presence or absence of the oxytocin and vasopressin peptides. This immunohistochemical study on the inferior turbinates of patients affected by chronic sinusitis shows, for the first time, that these peptides are present in the epithelium of both nasal mucosa and glands. Their presence could be related to the presence of atrial natriuretic peptide (ANP), like previously demonstrated in other organs such as heart and prostate, since in some circumstances they play in antagonism.

Introduction

Different neurotransmitters may change the nasal microenvironment and play important roles in the modification of some physical-chemical features of the inspired air.

Very little is known about the presence of neuropeptides in the nasal mucosa; to date, ANP (atrial natriuretic peptide) [1, 2], NPY (neuropeptide Y) [3], VIP (vasoactive intestinal peptide) [4] and SP (substance P) [5] expressions have been studied. The present study aimed to investigate the expression of oxytocin and vasopressin in this environment.

Oxytocin and vasopressin are mammalian hormones that act as neurotransmitters in the brain. Structurally, vasopressin and oxytocin are very similar, differing by only two amino acids; these peptides are synthesized in the hypothalamus by the magnocellular neurosecretory neurons of the supraoptic and paraventricular nuclei, and in the neurohypophysis by the axon terminals.

Oxytocin has peripheral actions such as the letdown reflex in lactating mothers and uterine contraction during labor; oxytocin is also involved in regulating the renal water reabsorption process [6]. Recently, it has been shown that oxytocin also plays an important role in social behavior; indeed, it has been shown to be involved in bonding, maternal behavior, sexual arousal, increasing trust and reducing fear [7, 8] couple interaction, close relationships in humans [9] and in social odor recognition [10]. Vasopressin has an antidiuretic action in decreasing diuresis in kidneys to restore the body fluid balance. This peptide is thus a critical regulator of water homeostasis; it acts by controlling the insertion of aquaporin 2 (AQP2) onto the apical membrane of the collecting duct principal cells in the short term, and regulating the gene expression of AQP2 in the long term [6]. Recent studies have shown that vasopressin is a hormone released by different stressors [11]. Furthermore, it has been demonstrated that vasopressin and ANP play opposite roles, and vasopressin also modulates ANP production by cultured neurons in the central nervous system; therefore, ANP and vasopressin may interact through the regulation of ANP production by the latter [12].

In earlier studies, the presence of ANP was established in rabbit airways and lung, and in human inferior turbinate [1, 2]; oxytocin has been demonstrated to be present in the

Address of the authors

Dipartimento di Biomedicina sperimentale e Neuroscienze cliniche, Università di Palermo.

Send correspondence to: *Elvira Vittoria Farina , farina.elviravitt@tiscali.it*

Received: *November 30th, 2012* — **Revised:** *December 16th, 2012* — **Accepted:** *January 4th, 2013*

olfactory bulbs and mucosa. Furthermore, vasopressin has been found to be localized in rat olfactory epithelium [13]. However, to date no studies have been published on the presence or absence of these peptides in the respiratory mucosa of the nasal cavity.

In view of these considerations, the present study was aimed to establish whether oxytocin and vasopressin are present in the nasal mucosa.

Material and Methods

Biopsies of inferior or middle turbinates were collected from subjects with chronic rhinosinusitis. Samples were fixed in Bouin's fluid, dehydrated and embedded in paraffin. Seven-micra sections were used to carry out the immunohistochemical characterization for oxytocin or vasopressin; detection was performed with the avidin-biotin complex. Endogenous peroxidases were blocked by incubation with PBS containing 0.3% hydrogen peroxide for 5 min at room temperature, followed by blockage of the specific binding by normal goat serum. The sections were treated with oxytocin or vasopressin polyclonal antibody (Chemicon USA (1:800 dilution) in 0.05M Tris buffer pH 7.2 for 12 hours at 4°C. The samples were rinsed in PBS pH 7.2 (three times each for 5 min). The reaction was demonstrated with amino-c-ethyl-carbazole as substrate.

Similarly treated sections, with the omission of the primary antibody, were used as negative controls. Slides were coverslipped using the 'Dako Cytomation Faramount Aqueous Mounting Medium'. The specimens were observed under a Leica DM1000 light microscope.

Results

The histological observations showed that the epithelium presents no morphological or significant alterations; in some biopsies the epithelium was hyperplastic.

Oxytocin immunopositivity was evident in the epithelium and its invaginations; in particular, the periciliary layer was immunopositive, and the epithelial ciliated cells showed intense immunopositivity in the perinuclear area; the basal cells were also immunopositive, with intense immunopositivity in their basal areas close to the basal lamina (Figure 1A, B). The glands were also strongly immunoreactive with oxytocin-immunopositivity noted only in proximity to the lumen; the myoepithelial cells were also immunopositive (Figure 1C). Vasopressin immunostaining evidenced immunopositivity in the apical layer of epithelium; basal cells were also immunopositive in their basal area.

Discussion

To the best of our knowledge, this is the

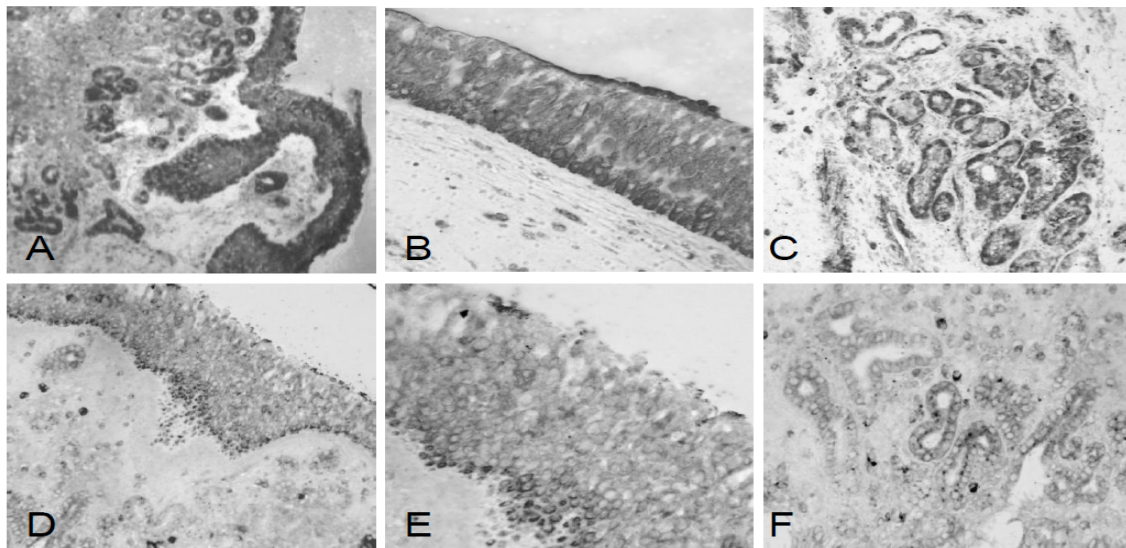


Figure 1: Human inferior turbinates stained for oxytocin (A, B, C) and vasopressin (D, E, F). The epithelium shows a strong oxytocin-immunoreactivity in the basal cells and in the apical area of cells (A, B). The glands show oxytocin-immunopositive cells in their apical area (C). The epithelium also shows vasopressin-immunopositivity in the epithelial cells and basal cells (D, E). Finally, also the glands show a vasopressin-immunopositivity (F).

first paper showing data on the presence or absence of oxytocin and vasopressin in the nasal mucosa; our results demonstrate that oxytocin is present in both the epithelium and glands; in some cases the immunopositivity is localized in the luminal area of cells whereas in other cases the basal cells are strongly immunopositive.

Previous studies have demonstrated that ANP is present in human inferior turbinates [2]. The presence of oxytocin may be related to some role it plays within the mucosa, analogously to what has been showed in other organs such as heart [14] and prostate [15], in which a relationship between oxytocin and ANP-release has been found. The presence of oxytocin induces us to hypothesize a possible relationship between these peptides also in the respiratory mucosa; in particular, the differing intracellular localization may indicate that a paracrine mechanism between the two peptides could occur in the context of the epithelium.

The presence of vasopressin in the basal area of basal cells may indicate that it has a role in the exchange processes between the cells and capillaries in the lamina propria; furthermore, vasopressin may be associated with the inter-relationship between vasopressin and ANP involving their antagonistic roles in the regulation of the homeostasis of body fluids and in the control that the vasopressin exerts on ANP production.

In conclusion, further studies are necessary in addition to the data obtained in the present study to verify whether oxytocin, vasopressin and ANP in the respiratory mucosa are independent or not.

References

1. Farina Lipari E, Valentino B, Lipari D, Dieli F. ANF immunolocation in rabbit airways and lung. *It J Anat Embryol* 1999;104 Suppl.1:185.
2. Valentino B, Lipari D, Restivo F, Speciale R, Gallina S, Farina Lipari E. Localization of the atrial natriuretic factor in the human inferior turbinates. An immunohistochemical study. *Acta Otorhinolaryngol Ital* 2003;3: 94-97.
3. Knipping S, Holzhausen HJ, Riederer A, Berghaus A. NPY in human nasal mucosa - an immunocytochemical and immunoelectron microscopical study. *Laryngorhinootologie*, 2003; 82(2):109-113.
4. Zhao C, Tao Z, Xiao J, Zhao S, Qiao J.

Histochemical and immunohistochemical studies of distribution of acetylcholinesterase-positive fibers and peptidergic terminals in the nasal mucosa of rats. *Chin Med J (Engl)* 1998;111(7):644-647.

5. Shi S and Zhou S. Study on the sense neuropeptides of nasal mucosa in the allergic rhinitis animal model. *Lin Chuang Er Bi Yan Hou Ke Za Zhi* 2006; 20 (11):508-510.

6. Cheng CY, Chu JY, Chow BK. Vasopressin-independent mechanisms in controlling water homeostasis. *J Mol Endocrinol* 2009;43(3):81-92.

7. Gimpl G and Fahrenholz F. The oxytocin receptor system: structure, function and regulation. *Physiol Rev* 2001;81(2):629-83.

8. Kosfeld M, Heinrichs M, Zak PJ, Fischbacher U, Fehr E. Oxytocin increases trust in humans. *Nature* 2005;435 (7042):673-676.

9. Ditzen B, Schaer M, Gabriel B, Bodenmann G, Ehlert U, Heinrichs M. Intranasal Oxytocin Increases Positive Communication and Reduces Cortisol Levels During Couple Conflict. *Biol Psychiatry* 2009;65 (9):728-731.

10. Wacker DW, Ludwig M. Vasopressin, oxytocin, and social odor recognition. *Horm Behav* 2012;61(3):259-265.

11. Katan M. and Chtris-Crain M. The stress hormone copeptin: a new prognostic biomarker in acute illness. *Swiss Med Wkly*; 2010;140: w13101

12. Levin ER, Hu RM, Rossi M, Pickart M. Arginine vasopressin stimulates atrial natriuretic peptide gene expression and secretion from rat diencephalic neurons. *Endocrinology* 1992;131(3):1417-1423.

13. Lévassieur G, Baly C, Grébert D, Durieux D, Salesse R, Caillol M. Anatomical and functional evidence for a role of arginine-vasopressin (AVP) in rat olfactory epithelium cells. *Eur J Neurosci* 2004;20(3):658-670.

14. Gutkowska J, Jankowski M, Lambert C, Mukaddam-Daher S, Zingg HH, McCann SM. Oxytocin releases atrial natriuretic peptide by combining with oxytocin receptors in the heart. *Proc Natl Acad Sci U S A*. 1997;94(21):11704-11709.

15. Farina-Lipari E, Lipari D, Bellafiore M, Anzalone R, Cappello F, Valentino B. Presence of atrial natriuretic factor in normal and hyperplastic human prostate and its relationship with oxytocin localisation. *Eur J Histochem*. 2003;47(2):133-138.