

## **Clinical and imaging findings of rare symptomatic giant Killian-Jamieson diverticulum**

**Poster No.:** C-0561  
**Congress:** ECR 2014  
**Type:** Educational Exhibit  
**Authors:** S. pardo, A. M. Maiorana, F. Cremona, F. Cupido, S. Poma, G. Agnello; Palermo/IT  
**Keywords:** Gastrointestinal tract, Ear / Nose / Throat, Conventional radiography, Fluoroscopy, Ultrasound, Surgery, Technical aspects, Diverticula, Eating disorders  
**DOI:** 10.1594/ecr2014/C-0561

Any information contained in this pdf file is automatically generated from digital material submitted to EPOS by third parties in the form of scientific presentations. References to any names, marks, products, or services of third parties or hypertext links to third-party sites or information are provided solely as a convenience to you and do not in any way constitute or imply ECR's endorsement, sponsorship or recommendation of the third party, information, product or service. ECR is not responsible for the content of these pages and does not make any representations regarding the content or accuracy of material in this file.

As per copyright regulations, any unauthorised use of the material or parts thereof as well as commercial reproduction or multiple distribution by any traditional or electronically based reproduction/publication method is strictly prohibited.

You agree to defend, indemnify, and hold ECR harmless from and against any and all claims, damages, costs, and expenses, including attorneys' fees, arising from or related to your use of these pages.

Please note: Links to movies, ppt slideshows and any other multimedia files are not available in the pdf version of presentations.

[www.myESR.org](http://www.myESR.org)

## Learning objectives

The present report describe a clinical case of old patient with symptomatic giant Killian-Jamieson diverticulum.

A KJD, described first by Killian, is a rare form of hypopharyngeal diverticulum (unfamiliar cervical esophageal disease)<sup>1</sup>.

This outpouching generally protrudes through a muscular gap in the antero-lateral wall of the proximal esophagus, on the lateral pharyngoesophageal junction area (the Killian-Jamieson space) below the cricopharyngeal muscle and lateral to the longitudinal muscle of the esophagus<sup>1, 2 and 3</sup>.

This rare disease entity is anatomically distinct from the more commonly known Zenker's diverticulum (ZD - muscular gap in the posterior portion of the cricopharyngeus, the Killian's triangle), which is the most commonly encountered diverticulum of the cervical esophagus<sup>1,3,4 and 5</sup>.

Studies describe KJDiverticula like seldom larger than 1.5 cm and usually asymptomatics<sup>1</sup>;

we report a rare case of symptomatic giant KJD with maximal dimension of 5 cm in a 97 year old female patient.

The Authors emphasize the importance of an accurate clinical and imaging studies, as a fundamental act for exclude other cervical esophageal disease.

Literature regarding Killian-Jamieson diverticulum and its suggested management is scarce<sup>3</sup> and to date, various treatment modality have been attempted, but only traditional surgical treatment has been recommended for a symptomatic giant KJD due to the concern of possible nerve injury.

We present here a rare case of a symptomatic KJD that was successfully treated with cervical incision, esophagomyotomy and diverticulopexy.

Following surgery, the patient's disease was resolved and she recovered well.

## Background

KJD is an uncommon esophageal type of hypopharyngeal pulsion diverticulum;

it appears through the Killian's dehiscence, resulting from herniation of mucosa and submucosa below the cricopharyngeal muscle wall (proximal lateral side of the cervical esophagus, Killian-Jamieson space), often unrecognized and misdiagnosed as a Zenker disease, diverticulum originates on the posterior wall of the pharyngoesophageal segment in a midline area of weakness just above the cricopharyngeus<sup>1,3,4 and 5</sup>.

Zenker's diverticulum is nearly four times as common as Killian-Jamieson diverticulum, and in literature, the two diseases have been observed simultaneously<sup>1</sup>.

KJDa are usually unilateral, only 25% are bilateral; furthermore, 75% of the Killian-Jamieson diverticula were left sided (like in our patient) and 25% were bilateral<sup>1</sup>.

The two diseases have similar symptoms (dysphagia, coughing and chest pain) but differ in location/mechanism and, according to previous studies, KJD has more non-specific symptoms than ZD; patients with a Zenker's diverticula are more likely to have symptoms (particularly suprasternal dysphagia) attributable to the underlying diverticulum than patients with Killian- Jamieson diverticula<sup>1</sup>, who usually are asymptomatic or have symptoms attributable to abnormal pharyngeal motility; in this publication we describe a symptomatic KJD.

Another feature that distinguish patient with a Zenker's diverticulum from patient with KJD is the greater risk of overflow aspiration or aspiration pneumonia, due the closure of the cricopharyngeus above the diverticulum<sup>1,3 and 5</sup>; our patient described, during the anamnestic examination, to have had episodes of overflow aspiration.

We also report that Zenker's diverticulum is more likely associate with gastroesophageal reflux than is Killian-Jamieson diverticulum<sup>1, 3 and 4</sup>; this high prevalence is not applicable in our case report, because our patient was for this condition, actually under treatment.

The pathogenesis of KJD is unclear and is an established fact the advanced age distribution of patients<sup>3 and 5</sup>.

Our studies, combining otolaryngological and general surgery experience, allow us to conclude that KJdiverticulum is the result of a functional outflow obstruction in the esophagus in much the same way that a Zenker's diverticulum, result from a functional outflow obstruction in the pharynx.

The circular muscle fibres of the proximal esophagus are believed to inappropriately constrict during the act of swallowing; this may create high intraluminal pressure, which is then transmitted to the weakened area within the Killian-Jamieson triangle<sup>1</sup>.

The pressure may be accentuated by the simultaneous closure of the cricopharyngeus muscle above the diverticulum.

The diagnosis of either Zenker's diverticulum or Killian-Jamieson diverticulum is based primarily on the radiographic findings, rather than on endoscopy.

Radiologists should be aware of the findings of Killian-Jamieson diverticulum on pharyngo-esophagography, so they are not mistaken for Zenker's diverticulum.

A left-sided Killian-Jamieson diverticulum can always be differentiated from a Zenker's diverticulum extending to the left of the midline on the basis of the radiographic anatomy; a Killian-Jamieson diverticulum is seen on the lateral wall of the pharyngoesophageal junction on anteroposterior view and below the cricopharyngeal muscle (methodic with RX-contrast may be useful).

A Zenker's diverticulum is seen in the posterior wall of the pharynx on lateral view, often with contrast retained within the diverticulum.

Whereas that endoscopist may visualize the opening of a Zenker's or Killian-Jamieson diverticulum, the location of the opening of the diverticulum in relation to the cricopharyngeus muscle is best shown on pharyngography when passage of the barium bolus outlines the protruding cricopharyngeal bar.

The size of the sac and its relationship with cervical esophagus are also best shown on barium studies.

At times, it may be difficult to distinguish between a Zenker's diverticulum and a Killian-Jamieson diverticulum with a barium esophagram. This occurs especially when the diverticulum is large and extends inferiorly. In such cases, an axial CT scan may be used to locate the origin of the diverticulum more precisely.

The Authors believe in the surgical therapy as only recommended treatment for a symptomatic KJD, especially if giant, due to its close proximity to the recurrent laryngeal nerve and the concern of possible nerve injury.

Only two reports regarding the treatment of Killian-Jamieson diverticula have been cited in the literature<sup>3</sup>.

The first was by Rogers et al., who approached the Killian-Jamieson diverticulum through a horizontal left neck incision and performing a diverticulotomy. The diverticulum was then mobilized and transected with a surgical stapling device. No esophagomyotomy was performed.

The second introduced by Tang et al. for the treatment of a symptomatic KJD, is primarily based upon a needle-knife incision of the esophageal circular muscle, who performed a distal vertical diverticulotomy with a flexible endoscope.

In our patient, we performed an esophagomyotomy (along and near the diverticular neck) in addition to a diverticulotomy to relieve the potential functional obstruction in the

circular esophageal muscle inferior to the diverticulum, that may contribute to or cause its formation.

Our surgery treatment of the KJD was successful with resolving the patient symptoms.

Furthermore, myotomy should be adopted as a treatment for KJD, since its treatment is closely related to the prevention of the recurrence from the perspective of the features of diverticular disease.

In summary, Palermo University Hospital experience indicates that Killian-Jamieson diverticulum is less common and considerably smaller than Zenker's diverticulum and appear on pharyngo- esophagography as persistent left-sided or, less frequently, bilateral outpouchings from the proximal cervical esophagus below the cricopharyngeus.

Killian- Jamieson diverticulum also is less likely to cause symptoms and is less likely to be associated with overflow aspiration or gastroesophageal reflux than is Zenker's diverticulum despite our case report, to be considered as isolated case of rare giant KJD in old patient.

## **Findings and procedure details**

A 97 year old female patient visited our University Hospital due to regurgitation, epigastric pain and progressive dysphagia when eating solids lasting 24 months before hospitalization.

She presented a lump sensation in the throat, mild oropharyngeal and suprasternal dysphagia for several months, globus sensation, heartburn, nighttime coughing and hoarseness, attributable to the diverticulum; history of aspiration pneumonia, no weight loss and she was nonsmoker.

According to her anamnesis, she was taking Captopril + Hydrochlorothiazide because she had hypertension for about 10 years; she was taking Rabeprazole Sodium (the patient suffered from gastroesophageal reflux disease, possible complicity causing the diverticulum) and taking Brimonidine Tartrate for cure a transitive ocular hypertension.

A clinical examination of the head and neck was unremarkable.

Evaluation of otorhinolaryngologist noted that the patient complained fetid halitosis, regurgitation with rumination in hypopharynx and dysphagia for solids; laryngoscopy didn't show anything abnormal except for the presence of mucous exudate level of the arytenoids.

Afterwards, during the hospitalization, barium-swallow-pharyngoesophagography was performed with the patient in the erect position, revealed a 5 cm left-sided KJD with a

wide neck (*Figure 1 and 2*), protruding through a muscular gap in the antero-lateral wall of the proximal esophagus, on the lateral pharyngoesophageal junction area, with smoothly marginated round-to-ovoid sacs.

The diverticulum opening was broader during swallowing than either before or after swallowing; was not revealed simultaneous presence of ZD, reflux of barium from the diverticulum into the hypopharynx or overflow aspiration; therefore, our patient had normal pharyngeal motility (except for incomplete opening of the cricopharyngeus).

An esophagogastroduodenoscopy was performed to confirm the suspected diagnosis and viewing the location of the opening of the diverticulum in relation to the cricopharyngeal muscle.

Sonographic examination demonstrated a heterogeneous, hyperechoic smooth wall with hypoechoic crouched lumen involving the anterolateral wall of the cervical esophagus; the lesion appeared to arise in continuity with the esophagus.

Intra-hospitalization specialist cardiology control, noted good hemodynamic compensation, sinus rhythm with right bundle branch block with PR interval 200 ms, normal for the age of our patient.

After consultation with the patient, she received surgical treatment for esophageal diverticulum under general anesthesia.

The left side location of the diverticulum on the esophagogram, has led us to decide a left cervical approach for surgeon's convenience.

The diverticulum was approached through an oblique incision along the anterior border of the left sternocleidomastoid muscle with the patient's head extended and slightly turned to the right.

After medialization of the thyroid gland, saving recurrent laryngeal nerve and lateralization of the omohyoid muscle, diverticulum was visualized to its emergence in the Killian-Jamieson space (*Figure 3*).

Diverticulum (5 × 5 cm sized) was found with a wide base and adhered to circumjacent tissues; in particular, it strongly adhered to the prevertebral fascia in the rear of the trachea.

Cervical esophagus proximal to the diverticulum was dissected cautiously and the diverticulum was dissected from adjacent tissues (following isolation of the left recurrent laryngeal nerve and carotid artery lateralization).

Antigravity diverticulopexy along the prevertebral band with three prolene® zero points and myotomy of the cricopharyngeal muscle extramucosal of about 3 cm along the

cervical esophagus was conducted (*Figure 4 and 5*). The esophageal patency was evaluated through the introduction of nasogastric tube. Surgical suture closed the breach.

The surgery was completed without the insertion of a drainage tube.

The patient was started on a clear fluid diet postoperative (day 1) and advanced to a soft diet on day 3.

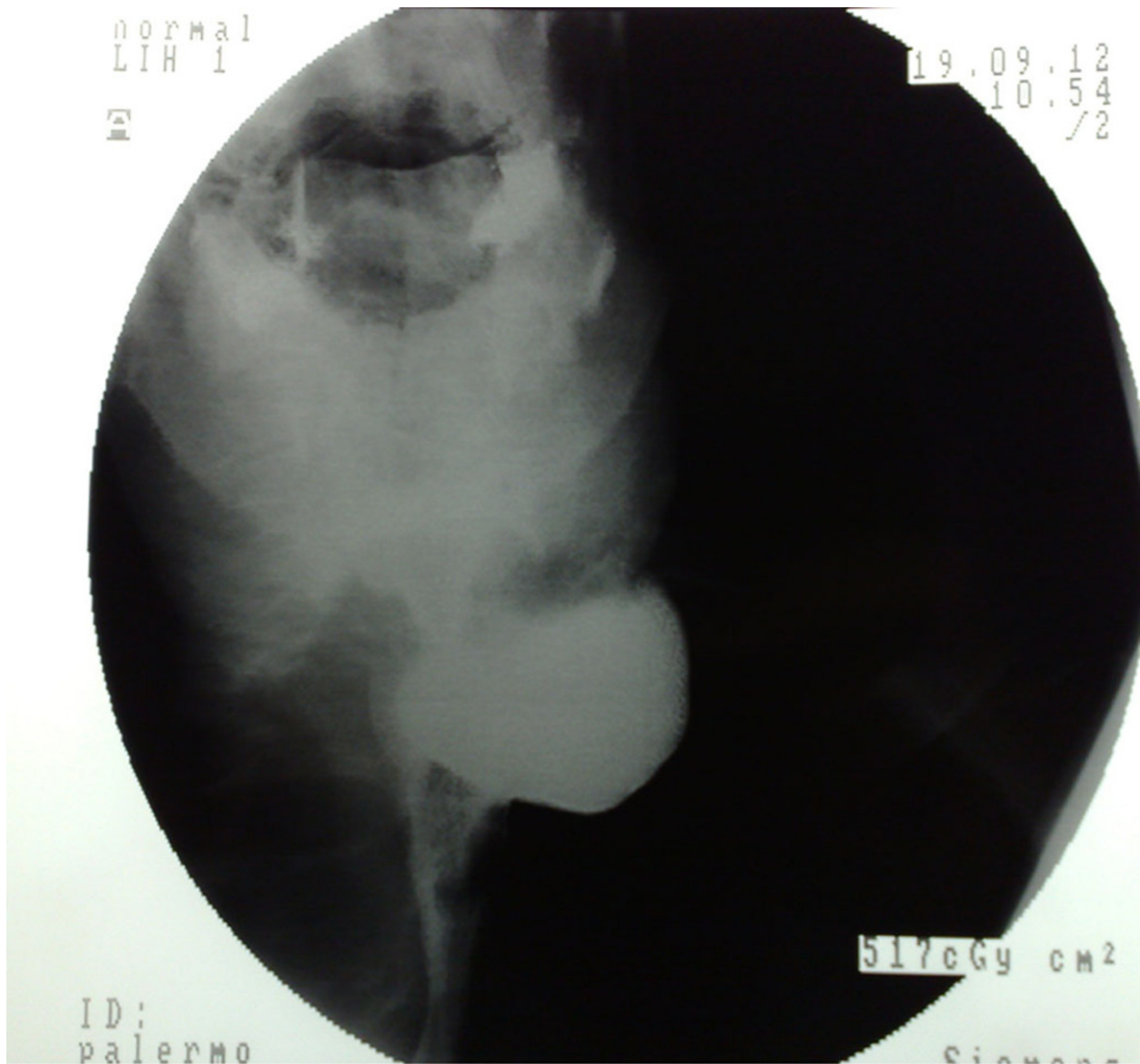
The patient was discharged from our University Hospital 6 days after the surgery procedure without complications such as nerve damage or hemorrhage.

The Rx pharyngoesophagography on the twenty day after the surgery showed that there were not abnormalities such as leakage or stenosis (*Figure 6*).

Follow-up observation has been performed for 3 months, during which the patient has not shown any abnormalities such as diverticulum relapse, dysphagia, regurgitation, nighttime cough or stenosis.

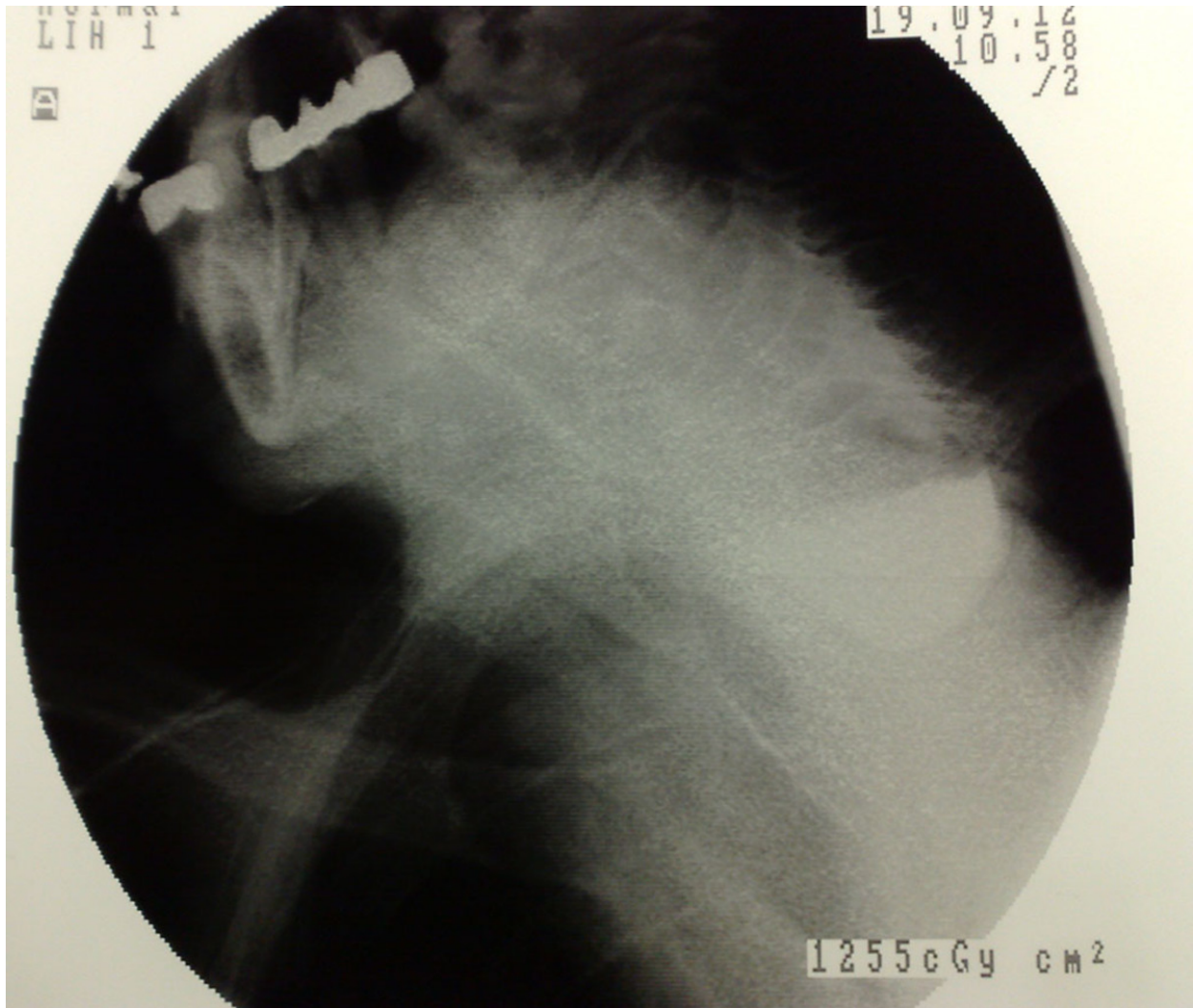
A follow up esophagoscopy was performed at three months after the procedure; it revealed a wide communication between the diverticular sac and the esophageal lumen without a significant tissue bridge.

**Images for this section:**

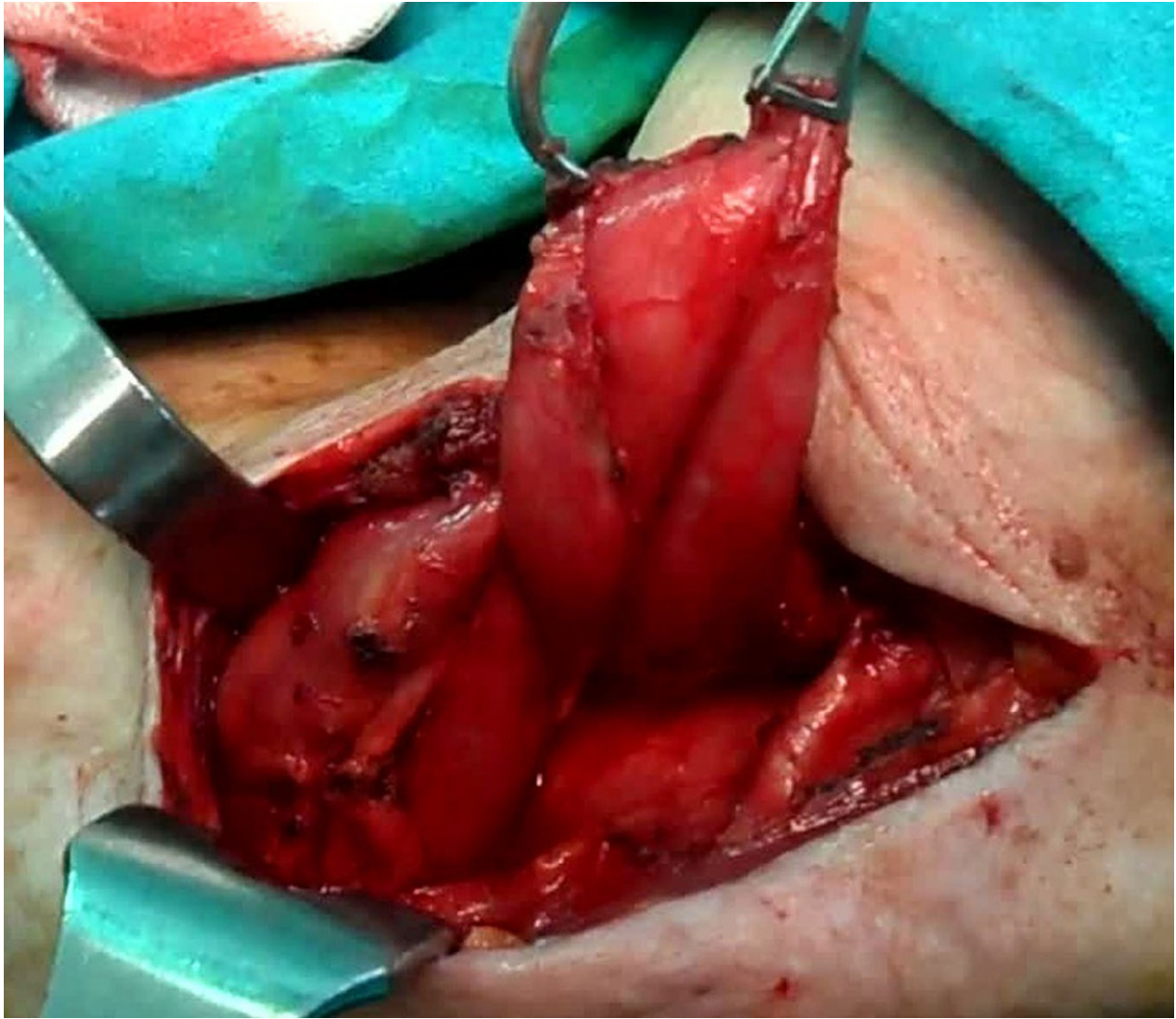


**Fig. 1:** Preoperative antero-posterior double-contrast pharyngoesophagram showed in left side a rare Killian-Jamieson diverticulum, protruding through a muscular gap in the antero-lateral wall of the proximal esophagus, on the lateral pharyngoesophageal junction area (the Killian-Jamieson space). The arrow indicates the diverticulum, with a maximum diameter of 5cm.

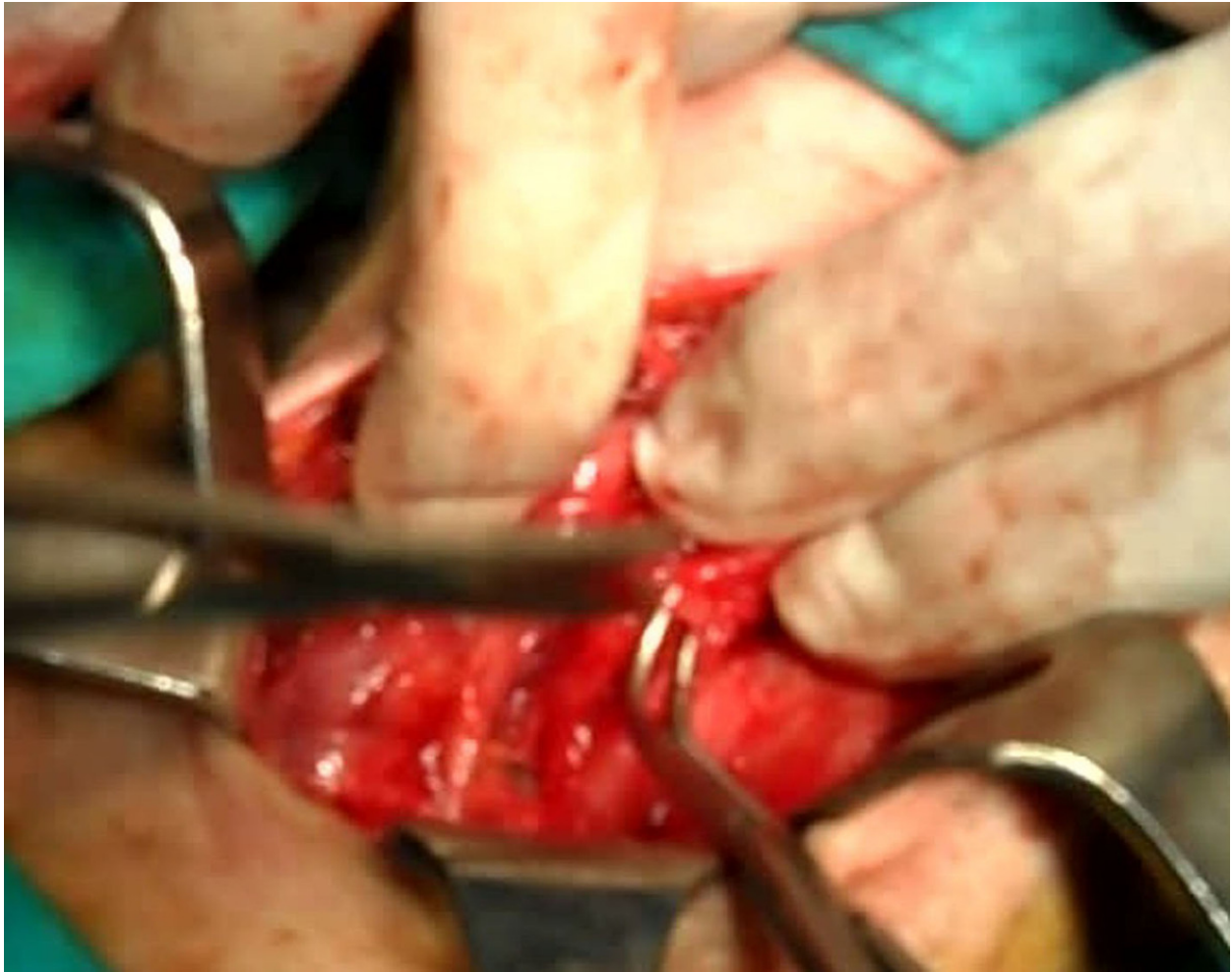



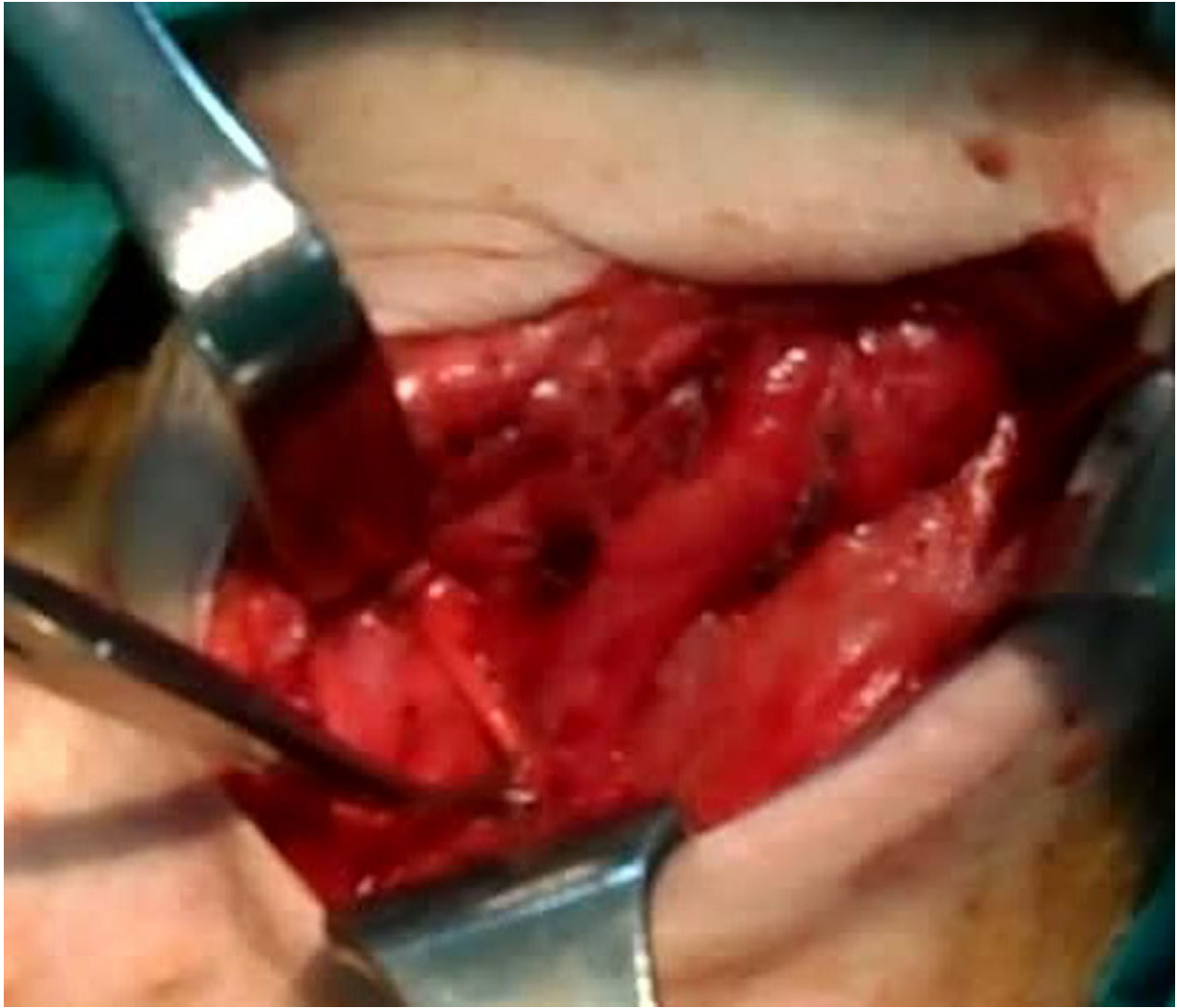**Fig. 2:** Preoperative latero-lateral double-contrast pharyngoesophagram showed in left side a rare Killian-Jamieson diverticulum, protruding through a muscular gap in the antero-lateral wall of the proximal esophagus, on the lateral pharyngoesophageal junction area (the Killian-Jamieson space). The arrow indicates the diverticulum, with a maximum diameter of 5cm.



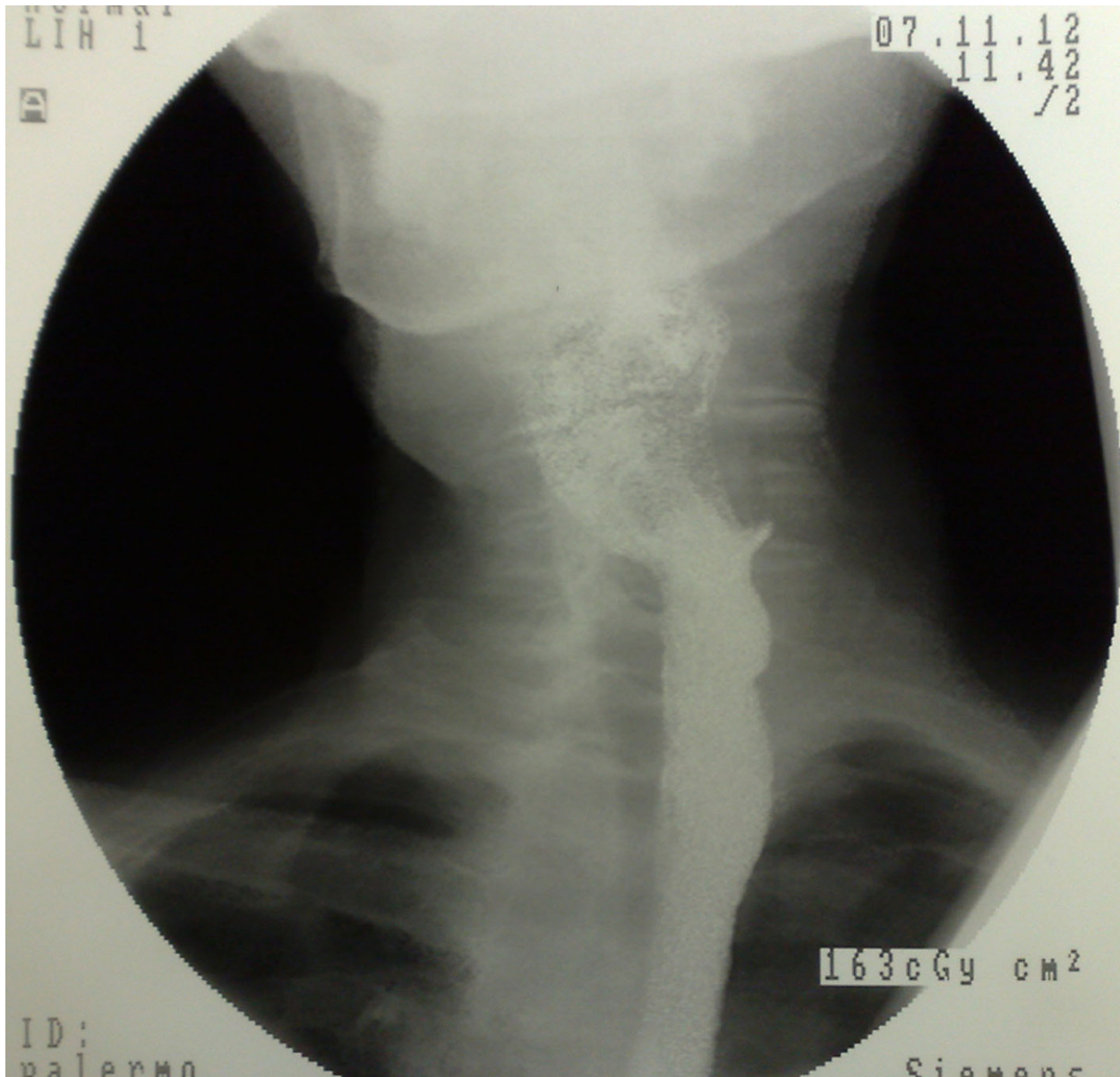
**Fig. 3:** Intraoperative image showing Killian - Jamieson diverticulum (arrow) approach through an oblique incision along the anterior border of the left sternocleidomastoid muscle with the patient's head extended and slightly turned to the right. After lateralization of the omohyoid muscle, diverticulum (5×5 cm sized) was found with a wide base and adhered to circumjacent tissues; cervical esophagus proximal to the diverticulum was dissected cautiously and the diverticulum was dissected from adjacent tissues.



**Fig. 4:** Intraoperative image showing extramucosal myotomy of the cricopharyngeal muscle that gets down to about 3 cm along the cervical esophagus, after isolation of the diverticulum until arriving at the collar



**Fig. 5:** Intraoperative image showing antigravity diverticulopexy along the prevertebral fascia with three points prolene® (one arrow) and saving the recurrent laryngeal nerve (two arrows).



**Fig. 6:** Post-operative antero-posterior double-contrast pharyngoesophagram showing restoring esophageal function, no clinical complications and not filled esophageal diverticulum

## Conclusion

The Authors emphasize the importance of an accurate clinical and imaging examination, as a fundamental act for exclude other cervical esophageal disease, principally the more commonly known Zenker's diverticulum, and help to clarify its etiology.

We believe its pathophysiology is similar to Zenker's diverticulum, which is to say that Killian-Jamieson diverticulum is the result of a functional esophageal obstruction.

The symptoms observed in our symptomatic old patient may be due to an underlying abnormal oral and or pharyngeal phase of swallowing.

We believe that an esophagomyotomy must be part of its surgical treatment, in addition to a diverticulopexy.

Furthermore, we recommend that this diverticulum be approached transcutaneously to prevent and protect recurrent laryngeal nerve injury and other surrounding tissue during dissection of the tissue bridge.

The Authors note that believe in the surgical treatment as the only procedure to the cure of the patients and, to date, our successful experience suggests that only surgical approach can be a safe and effective method for the treatment of symptomatic giant KJD.

Recently, traditional open surgery for a symptomatic KJD is being challenged by the development of new endoscopic techniques and devices.

The follow-up (on-going), up to now, showed no recurrence of the pathological and no complications, making sure the authors of the efficacy of the surgical treatment

## Personal information

Dr. Salvatore Pardo

Dipartimento Biotecnologie Mediche e Forensi

Università degli Studi di Palermo

Via del Vespro 127 - 90100 Palermo

office: +39 0931759422

fax: +39 0931753963

salvopardo@gmail.com

salvatore.pardo@unipa.it

**Images for this section:**



**Fig. 7:** The Autor in a relaxing moment

## References

- 1) Stephen E. Rubesin, Marc S. Levine. *Killian-Jamieson Diverticula: Radiographic Findings in 16 Patients*. July 2001; *AJR* 2001;177:85-89.
- 2) Fang Lee , Ching-Hsiang Leung , Wen-Chien Huang and Shih-Ping Cheng. *Killian-Jamieson Diverticulum Masquerading as a Thyroid Mass*. *Intern Med* 51: 1141-1142, 2012; DOI: 10.2169/internalmedicine.51.7219.
- 3) René D Boisvert, Drew CG Bethune, David Acton, Denis R Klassen. *Bilateral Killian-Jamieson diverticula: A case report and literature review*. *Can J Gastroenterol* 2010;24(3):173-174.
- 4) Dong Chan Kim, Jae Joon Hwang, Woo Surng Lee, Song Am Lee, Yo Han Kim, Hyun Keun Chee. *Surgical Treatment of Killian-Jamieson Diverticulum*. *Korean J Thorac Cardiovasc Surg* 2012;45:272-274.
- 5) Chang Kyun Lee, Il-Kwun Chung, Ji-Young Park, Tae Hoon Lee, Suck-Ho Lee, Sang-Heum Park, Hong-Soo Kim, Sun-Joo Kim. *Endoscopic diverticulotomy with an isolated-tip needle-knife papillotome (Iso-Tome) and a fitted overtube for the treatment of a Killian-Jamieson diverticulum*. *World J Gastroenterol* 2008 November 14; 14(42): 6589-6592.