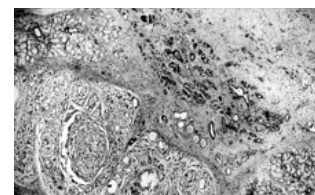


Salivary gland tumors in patients with necrotizing sialometaplasia: a case series



M. Dioguardi¹, A. Santarelli², D. Compilato³, G. Campisi³, L. Lo Muzio¹

¹Department of Sperimental and Clinical Medicine, University of Foggia, Italy; ²Department of Specialistic and Odontostomatological Sciences, Polytechnic University of Marche, Ancona, Italy; ³Department of Surgical, Oncologic and Stomatologic Sciences, University of Palermo, Italy

Necrotizing sialometaplasia (NS) is a benign, reactive, necrotizing lesion that may involve minor salivary glands, and, more rarely, major salivary glands and mucoserous glands of the upper respiratory tract. To date, about 220 patients have been reported in literature, harboring NS in the parotid gland, submandibular gland, incisive canal, lower lip, tongue, floor of mouth, retromolar area, mucoserous glands of the nasal cavity, maxilla, larynx and trachea¹. The majority of cases of NS, however, involve the hard and/or soft palate. Although benign and self-limiting, NS is significant because it might be clinically and histologically mistaken for malignancy². Furthermore, NS may accompany tumors of minor and major salivary glands³. In this series we reported 6 patients affected by NS associated with minor and major salivary gland tumours. 2 patients presented NS of the minor salivary glands of the palate, and had associated neoplasms (pleomorphic adenoma and adenoid cystic carcinoma) at the same site. Four patients had NS of the parotid gland associated with epithelial-myoepithelial carcinoma, adenoid cystic carcinoma, Warthin's tumor and oncocytoma. Necrotizing sialometaplasia is a self-limited disease with spontaneous resolution in most cases; even if regeneration of the affected ducts and acini is usually incomplete, the healing process includes repair of both the ulceration and regeneration of the damaged salivary tissue. During this regenerative process, the presence of ductal and acinar metaplasia, prominent nuclei, frequent mitotic figures and necrosis may lead to an incorrect diagnosis of malignancy. Although infrequently, NS has in fact been reported to obscure an underlying neoplasm, thus resulting in delays in referral or treatment. This further stresses the importance of performing an appropriate biopsy and carefully monitoring patients with NS of the minor salivary glands.

References

1. Pires FR, Chen SY, da Cruz Perez DE, de Almeida OP, Kowalski LP. Cytokeratin expression in central mucoepidermoid carcinoma and glandular odontogenic cyst. *Oral Oncol* 2004; 40(5):545.
2. Abrams AM, Melrose RJ, Howell FV. Necrotizing sialometaplasia. A disease simulating malignancy. *Cancer* 1973; 32:130-135.
3. Brannon RB, Fowler CB, Hartman KS. Necrotizing sialometaplasia. A clinicopathologic study of sixty-nine cases and review of the literature. *Oral Surg Oral Med Oral Pathol* 1991; 72:317-325.