

## New ideas - Aortic and aneurysmal

# Aortic valve-sparing root replacement from inside the aorta using three Dacron skirts preserving the native Valsalva sinuses geometry and stabilizing the annulus

Giovanni Ruvolo, Khalil Fattouch\*

Department of Cardiac Surgery, University of Palermo, Via Liborio Giuffrè, 5, 90127, Palermo, Italy

Received 9 July 2008; received in revised form 18 August 2008; accepted 20 August 2008

## Abstract

We present an alternative idea for valve-sparing technique combining the advantages of the reimplantation and the benefits of the remodeling techniques. We replace the sinuses of Valsalva using three Dacron skirts from inside of the aorta. The physiological anatomy of the Valsalva sinuses and their dynamic properties are preserved and the aortic commissures displacement avoided. The distal rim of each Dacron skirt was anchored to the aorto-ventricular junction using Ticron (2-0) U stitches placed from the ventricular side to the aortic side. We stabilize the base of the aortic annulus to prevent future dilation.

© 2009 Published by European Association for Cardio-Thoracic Surgery. All rights reserved.

**Keywords:** Aortic root aneurysm; Valve-sparing surgery; Easy procedure

## 1. Introduction

Aortic valve-sparing techniques, initially described in the early 1990s, allow the replacement of the aortic root while the native aortic valve is saved [1, 2].

Briefly, in the *reimplantation* technique, the native valve is re-suspended into a straight prosthesis, the aorto-ventricular junction is stabilized but the normal Valsalva sinuses anatomy is lost. In the last decade, several authors described different techniques and prostheses to create pseudo-sinuses [3–5].

In the *remodeling* technique, the Dacron graft is trimmed and tailored to mimic the three Valsalva sinuses morphology and sutured to the aorta kings crown; the aorto-ventricular junction is not stabilized by the prosthesis, that leads to progressive dilation and recurrent postoperative aortic valve insufficiency (AI).

Our alternative approach might join the advantages of both procedures: the aortic root is replaced from the inner side of the aorta using three separated Dacron skirts anchored to the aorto-ventricular junction using a sub-annular U stitch, coronary ostia are re-implanted in place from inside, and the ascending aorta is replaced using a Dacron prosthesis that must be sutured to the sinotubular junction (STJ) to remodel it.

## 2. Technique

We have performed this alternative valve-sparing technique in five patients. Four patients had anulo-aortic ecta-

sia and one patient had an ascending aortic aneurysm that abolished STJ with thin aortic root tissue. Preoperatively, no AI was found in one patient, moderate AI was found in two, and moderate-to-severe AI in two. Moreover, no aortic leaflets prolapse was found and the regurgitant jet was central in all patients. The preoperative mean annulus diameter was  $29 \pm 4$  mm.

A standard longitudinal median sternotomy and cardiopulmonary bypass (CPB) were applied. The aorta was transected one centimeter above the STJ. The three commissures were suspended with Prolene 4-0 and sutures were placed vertically to make the valve competent. The STJ was measured using a millimetric valve sizer and a Dacron prosthesis was chosen according to the STJ size measured.

Three vertical blue marks were made in the Dacron graft corresponding to the distance between the three aortic commissures, while keeping the valve in closed position; another three horizontal blue lines were made in the Dacron graft corresponding to the height from the base of the sinus until the sinotubular ridge. The Dacron prosthesis was trimmed following the marks and finally was cut into three separated skirts to simplify the implantation. Each Dacron skirt was sutured separately following the sinus silhouettes onto the inner of the aortic root (Fig. 1a). At the level of the annulus, sutures were placed from below the aortic valve leaflets to the inner side of the aorta using Ticron 2-0 sutures reinforced with pledgets (Fig. 1b). Two holes were made in two Dacron skirts at the level of the coronaries ostia, prior to implantation. Coronaries ostia were sewed to the Dacron holes from inside of the aorta

\*Corresponding author. Tel.: +39 091 6554713; fax: +39 091 6554710.

E-mail address: khalilfattouch@hotmail.com (K. Fattouch).

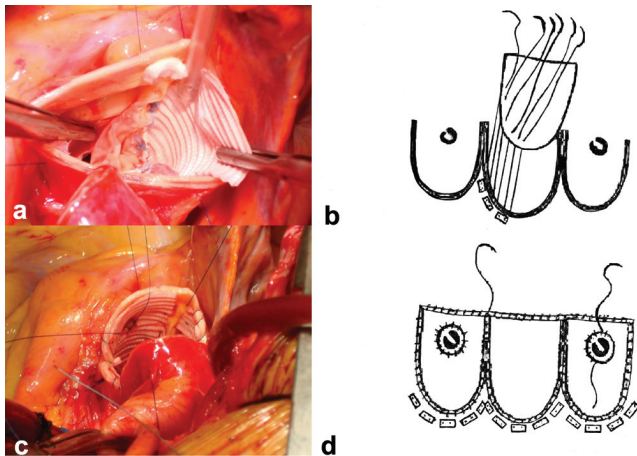


Fig. 1. U stitches were placed below the aortic valve leaflets from the ventricular side to the inner side of the aorta using Ticron 2-0 sutures reinforced with pledgets; a) intraoperative view and b) schematic illustration. Two holes were made in the Dacron skirts and sutured to the native coronaries ostia from inside of the aorta using Prolene 6-0 running sutures. The Dacron skirts were sutured to the aorta above the commissures and subsequently to the sinotubular junction using Prolene 5-0 running sutures; c) intraoperative view and d) schematic illustration.

using a Prolene 6-0 running suture as well (Fig. 1c). Laterally the Dacron skirts were sutured to the aorta above the commissures and subsequently to the STJ using Prolene 5-0 running sutures (Fig. 1d).

The new Dacron skirts reached the STJ ridge creating a collar. At this level the Dacron graft was anastomosed to replace the ascending aorta.

Postoperative transesophageal echocardiography (TEE) showed no AI in all cases. Our approach was able to correct AI in all patients by reduction of annulus diameter. The mean high of the leaflets coaptation was  $9 \pm 2$  mm and the plane of the leaflets coaptation was above the plane of the annulus. Postoperative mean annulus diameter was  $21 \pm 2$  mm. Postoperative, M-mode echocardiography showed a physiological valve opening and closing motion with normal distance between the Dacron skirt and the aortic leaflets. This shows that the Dacron skirts sutured like a film to the Valsalva sinuses from the inner of the aorta did not affect the valve motion. Data were confirmed by multi-slice computerized tomography images. A volume rendering reconstruction of the aortic valve plane showed the conservation of the anatomy of the Valsalva sinuses postoperatively, the symmetric aortic valve closure without leaflets prolapse and a good opening surface (Fig. 2a,b). A multi-planar parasagittal reconstruction of the heart showed a distance between the aortic leaflets and the Valsalva sinuses wall in opening phase that avoid contact between the two structures (Fig. 2c,d). Moreover, no pseudo-aneurysm or blood clots between the Dacron skirts and the aortic wall at the level of Valsalva sinuses were observed.

The mean cardiopulmonary bypass and cross-clamp times were  $105 \pm 15$  and  $95 \pm 12$  min, respectively. No bleeding was observed postoperatively. This technique was easy and safe and has promising results.

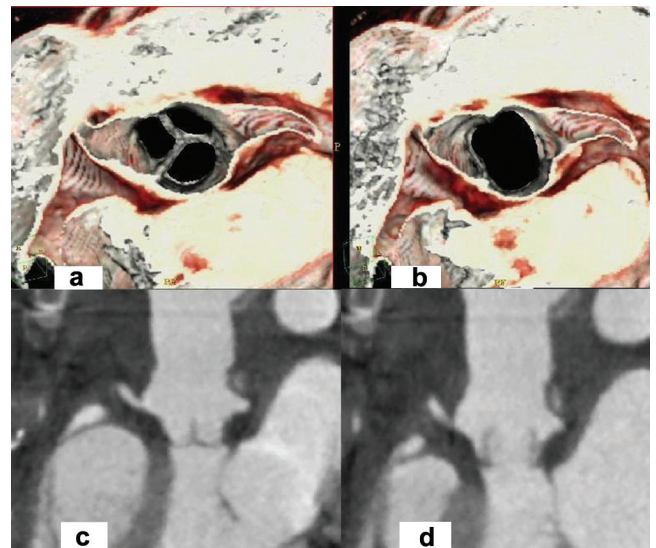


Fig. 2. Multi-slice computerized tomography images: (a) a volume rendering (VR) of the aortic valve plane showing the symmetric line of aortic leaflets closure without leaflet prolapse and (b) the maximum opening of the aortic valve. (c) A parasagittal multi-planar reconstruction (MPR) of the heart showing the median symmetric closure of the aortic valve in diastole and (d) the distance between the aortic valve leaflets and the aortic sinus wall in systole.

### 3. Comments

Valve-sparing techniques as described mainly by Mr David and Mr Yacoub are used worldwide aiming at aortic valve salvage [1, 2]. Flaws concerning the remodeling are, as mentioned, the lack of stabilization of the aortic annulus that can lead to progressive annular dilation and recurrent AI. Although the remodeling technique is a demanding surgical procedure, it provides a natural and physiological reconstruction of the aortic root indeed. Moreover, this procedure theoretically has more incidence in postoperative bleeding in respect to reimplantation.

The reimplantation technique has the advantage of anchoring the Dacron prosthesis to the aorto-ventricular junction to stabilize it, but in case of using a straight prosthesis the normal geometry of the Valsalva sinuses is lost. To avoid this problem, Demers et al. [3] described a variation of the reimplantation technique using a big Dacron graft for reimplantation of the valve and subsequently a small graft to replace the ascending aorta and remodeling the STJ, recreating pseudosinuses. De Paulis et al., to resemble the root anatomy while using the reimplantation technique, introduced a modified Dacron conduit with pseudosinuses [4]. Thubrikar et al. [5] and Urbanski [6] described their approach to recreate the sinuses.

Today, the Gelweave Valsalva graft (Vascutek, Terumo) is used widely to preserve the aortic root anatomy during the reimplantation procedures but this technique is still a challenge for several surgeons.

The goal of our alternative technique was to join and combine, in a easy and fast way, the benefits of both the reimplantation and remodeling techniques: to fix and downsize the annulus and preserve the normal anatomy of

the aortic root. Moreover, the three interleaflet triangles were kept free to move during the cardiac cycle that is crucial for the visco-elastic properties of the aortic root and valve, and thereby on long-term leaflets stress.

The sutures placed from below the aortic valve leaflets through the fibrous base of the aorto-ventricular junction stabilized the annulus with the Dacron skirts avoiding future dilation, reduced the length of the base of leaflet leading to reduction in annular diameter and abolished AI. The interleaflet triangles were not involved in the sutures and not fixed by prosthesis, thereby their physiological contractile functions are not compromised during the cardiac cycle.

Extreme care had to be taken while the new Dacron skirts were implanted into the root, and before, when holes were made in the left and right Dacron skirts just in front of the native coronaries ostia. Avoiding the coronaries ostia mobilization, their reimplantation can be considered as an extra advantage of our alternative technique.

The height of each Dacron skirt was tailored to reach the native STJ, creating at this level a collar, where the rest of the prosthesis was sutured to replace the ascending aorta and remodel the STJ. We believe that the Dacron skirts, sutured from inside, totally exclude the root from the blood flow and moreover seem to be more homeostatic than the traditional remodeling (Yacoub's procedure). In our experience no pseudo-aneurysm or blood clot was observed between the Dacron skirts and the sinuses wall.

In conclusion this approach appears to be safe and easy because:

1. It is simple and fast to suture the skirt inside the root meanwhile respecting the native geometry avoiding any potential distortion of the valve.
2. The diameter of annulus is reduced and stabilized by the prosthesis to avoid future dilation.
3. The suture lines being inside the native aortic root themselves are more homeostatic.
4. The coronaries ostia are not mobilized thus avoiding distortion or kinking.
5. The interleaflet triangles are kept free to move during cardiac cycle.

However, long-term follow-up is mandatory to validate our idea.

## References

- [1] David TE, Feindel CM. An aortic valve-sparing operation for patients with aortic incompetence and aneurysm of the ascending aorta. *J Thorac Cardiovasc Surg* 1992;103:617–621.
- [2] Sarsam LAJ, Yacoub M. Remodeling of the aortic valve annulus. *J Thorac Cardiovasc Surg* 1993;105:435–438.
- [3] Demers P, Miller C. Simple modification of «T David V» valve sparing aortic root replacement to create graft pseudosinuses. *Ann Thorac Surg* 2004;78:1479–1481.
- [4] De Paulis R, De Matteis GM, Nardi P, Scaffa R, Colella DF, Chiariello L. A new aortic Dacron conduit for surgical treatment of aortic root pathology. *Ital Heart J* 2000 Jul;1:457–463.
- [5] Thubrikar MJ, Robicsek F, Gong GG, Fowler BL. A new aortic root prosthesis with compliant sinuses for valve-sparing operations. *Ann Thorac Surg* 2001;71:S318–S322.
- [6] Urbanski PP. Valve-sparing aortic root repair with patch technique. *Ann Thorac Surg* 2005;80:839–844.