

LETTER TO THE EDITOR

Sorafenib as a feasible therapeutic option in haemophiliacs with hepatocellular carcinoma

M. LAPECORELLA,* M. NAPOLITANO,* M. TUDINI,† G. BRUERA,† A. LUCCHESI,*
A. V. GIORDANO,‡ G. MARIANI* and E. RICEVUTO†

*Haemophilia and Thrombosis Centre; †Medical Oncology, Department of Experimental Medicine; and ‡Department of Radiology, University of L'Aquila, Italy

Sorafenib (Nexavar®; Bayer, Leverkusen, Germany) is a multikinase inhibitor that shows efficacy in a variety of tumours and has been recently approved for the treatment of multifocal and surgically unresectable hepatocellular carcinoma (HCC). Sorafenib blocks the growth of tumour cells by inhibition of several pathways that both interfere with angiogenesis and induce apoptosis of HCC cells. Both in HCC cell lines and in murine models, sorafenib has been shown to antagonize the angiogenic effect of vascular endothelial growth factor (VEGF) and platelet-derived growth factor (PDGF) on their receptors VEGFR2 and PDGFR respectively. Furthermore, sorafenib has a direct effect on cell proliferation with mechanisms that are partly unknown but that involve the RAF/MEK/ERK signalling pathway, which plays a key role in the development of many tumours including HCC [1]. Antiangiogenic drugs show a variegated spectrum of both thrombotic and haemorrhagic complications. Among angiogenesis inhibitors, treatment with sorafenib is poorly complicated with thrombotic episodes. Conversely, bleeding has been extensively reported with an incidence of 2–3% of treated patients, ranging from frequent and mild [2] to rare severe haemorrhages, including intracranial [3].

Hepatocellular carcinoma frequently occurred in haemophiliacs as most patients became infected with HBV and HCV from concentrates before virus inactivation was available. Since infected concentrates were used in the early-mid 1980s, HCC emerged as a cause of death in haemophiliacs

beginning from the mid 1990s [4]. Liver transplantation and chemoembolization are the therapeutic options [5] while the use of sorafenib for HCC treatment has never been reported in haemophiliacs to date.

A 65 year-old severe haemophiliac A with chronic HBV/HCV-related liver co-infection referred to our Centre for a markedly increased serum alpha-fetoprotein (AFP) (4102 ng/mL). A liver ultrasound was performed, showing a nodular lesion (diameter 5 cm) between the 6th and 7th segments. A further superficial, extruding lesion (diameter 3 cm, 6th segment) was detected at MRI. Hilar lymphadenopathy was present. Clinical diagnosis of multifocal HCC was therefore made according to American Association for the Study of Liver Diseases (AASLD) diagnostic criteria (lesion >2 cm in cirrhotic liver, the typical pattern of vascularization, confirmed by two imaging studies, AFP >200 ng/mL). The patient was asymptomatic at the time of observation. The functional liver status, according to Child-Pugh score was CHILD A (6 points). The patient fell in the stage B, intermediate, thus surgically unresectable, according to the Barcelona Clinic Liver Cancer Criteria (BCLC) and chemoembolization of the nodular lesion between the 6th and 7th segments with doxorubicin (30 mg total dose) and Lipiodol was performed. As the patient's treatment regimen was on-demand basis, adequate peri-operative coverage with his plasma-derived factor VIII (FVIII) concentrate (Emoclot®; Kedrion, Castelveccchio Pascoli, Italy) was obtained. The subsequent CT scan, performed 4 weeks after the procedure, showed progression in size of the main lesion (Fig. 1a), expansion of hilar lymphadenopathy and the occurrence of new smaller hepatic lesions, with worsening of performance status (PS 2), thus determining a stage C, according to BCLC criteria. At this point, the only residual treatment option was a systemic therapy with the

Correspondence: Dr Mario Lapecorella, MD, Centro Emofilia e Trombosi - Unità Operativa Medicina Interna 2 - Ematologia, Università de L'Aquila - Ospedale San Salvatore, Via Vetoio 1, 67100 Coppito - L'Aquila, Italy.
Tel.: + 39 33 9758 5281; fax: + 39 08 0522 7253;
e-mail: emofilia.aq@cc.univaq.it

Accepted after revision 28 August 2009

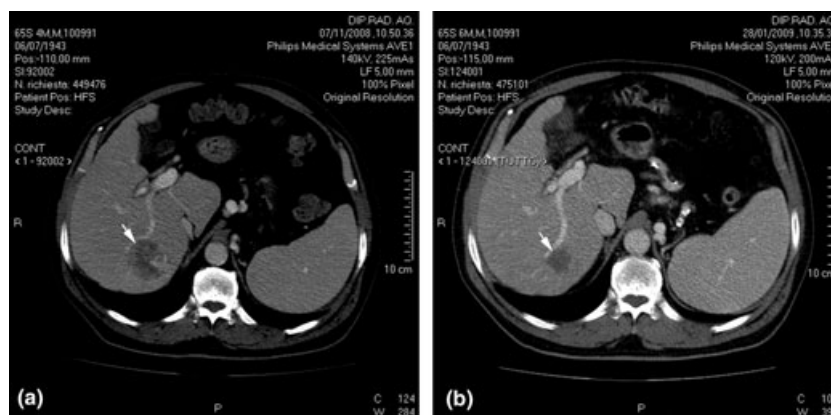


Fig. 1. (a) CT scan performed 4 weeks after chemoembolization shows progression in size of the nodular lesion between the 6th and 7th segments with persistence of viable tissue (arrow). (b) CT scan performed after 8-week course treatment with sorafenib shows marked reduction in size of the nodular lesion between the 6th and 7th segments with intra-lesional necrosis (arrow).

angiogenesis inhibitor sorafenib. Several co-morbidities were present, including hypertension and hypertrophic cardiomyopathy, type II diabetes, and especially haemorrhagic diathesis resulting from haemophilia A, in that the patient was characterized as 'unstable' according to the Cumulative Illness Rating Scale (CIRS) co-morbidity index score. Therefore, treatment with sorafenib was started at the 50% dose reduction of 400 mg/day. In order to prevent bleeding episodes, the regimen of substitution treatment with his plasma-derived FVIII concentrate was shifted to prophylaxis (40 U/Kg of body weight three times a week) as such regimen is associated with a better long-term outcome when compared with on-demand treatment. After 4 weeks of treatment, the patient only experienced transient diarrhoea, and both moderate asthenia and dyspnoea, while no bleeding episode was reported. Furthermore, a consistent reduction of AFP (26.5 ng/mL) was observed. Treatment was continued at the same dose for further 4 weeks. Then a complete restaging was performed. CT scan showed a good response consisting in 50% reduction with extensive central necrosis of the larger lesion (Fig. 1b), stability of the superficial lesion, and disappearance of the other satellite smaller nodules. AFP further decreased down to 8 ng/mL and no bleeding symptom was reported. Three months after discontinuing sorafenib treatment, our patient preserved his basic performance status and AFP still fell into the normal range (8.9 ng/mL). Prophylaxis with FVIII has not been discontinued.

This is, to date, the first report of the use of sorafenib for treatment of HCC in a haemophiliac.

Our experience suggests that Sorafenib may be a feasible therapeutic option in these patients. As a result of the bleeding complications described with the use of this drug, prophylaxis with FVIII concentrates is advised. The reasons for such an effective response when compared with the case of non-haemophiliac patients after an 8-week course therapy administered at half the full dose require further studies and sorafenib needs a large scale comparison with other treatment options in hemophiliac patients affected by HCC.

Disclosures

The authors stated that they had no interests which might be perceived as posing a conflict or bias.

References

- 1 Liu L, Cao Y, Chen C *et al.* Sorafenib blocks the RAF/MEK/ERK pathway, inhibits tumor angiogenesis, and induces tumor cell apoptosis in hepatocellular carcinoma model PLC/PRF/5. *Cancer Res* 2006; **66**: 11851–8.
- 2 Escudier B, Eisen T, Stadler WM *et al.* Sorafenib in advanced clear-cell renal-cell carcinoma. *N Engl J Med* 2007; **356**: 125–34.
- 3 Abou-Alfa GK, Schwartz L, Ricci S *et al.* Phase II study of sorafenib in patients with advanced hepatocellular carcinoma. *J Clin Oncol* 2006; **24**: 4293–300.
- 4 Rumi MG, De Filippi F, Santagostino E, Colombo M. Hepatitis C in haemophilia: lights and shadows. *Haemophilia* 2004; **10**(Suppl. 4): 211–5.
- 5 Santagostino E, Colombo M, Rivi M *et al.* A 6-month versus a 12-month surveillance for hepatocellular carcinoma in 559 hemophiliacs infected with the hepatitis C virus. *Blood* 2003; **102**: 78–82.